

611.9

H42

THE STATE MEDICAL AND PHARMACEUTICAL UNIVERSITY
NICOLAE TESTEMITANU

Department of Human Anatomy



**HEAD AND NECK
ANATOMY**

Basic course for students of Dentistry

*Collected and elaborated by
Lilian GLOBA*

CHISINAU
2011

THE STATE MEDICAL AND PHARMACEUTICAL UNIVERSITY
NICOLAE TESTEMITANU


Department of Human Anatomy

HEAD AND NECK ANATOMY

Basic course for students of Dentistry

*Collected and elaborated by
Lilian GLOBALA*

627904



bibliogr.

CHISINAU
Editorial-Polygraphic Center *Medicina*
2011

CZU: 611.9(075.8)

H 42

Recommended to print by Central Methodological Council of SMPHU *Nicolae Testemitanu*
proces-verbal nr. 1 from 05.11.2010

Lilian Globa, lecturer, Department of Anatomy

Reviewers: *Boris Topor*, PhD, university professor, Chairman of Department of Topography Anatomy and Surgical Techniques.

Oleg Solomon, MD, assistant professor, Department of Child Oromaxillar Surgery, Orthodontics and Pedodontics, Vice Dean of Dentistry Faculty

DESCRIEREA CIP A CAMEREI NAȚIONALE A CĂRȚII

Head and Neck Anatomy: basic course for students of Dentistry / The State Medical and Pharmaceutical Univ. *Nicolae Testemitanu*, Dep. Of Human Anatomy; collected and elab. by Lilian Globa. – Ch.: CEP *Medicina*, 2011. – 214 p.

70 ex.

ISBN 978-9975-913-44-7.

611.9(075.8)

H 42

CONTENTS

Introduction.....	6
Capitolul I. THE SKELETON OF THE HEAD	
The Bones of the Cerebral Cranium.....	7
<i>The Occipital Bone.....</i>	7
<i>The Sphenoid Bone.....</i>	8
<i>The Temporal Bone.....</i>	9
<i>The Parietal Bone.....</i>	11
<i>The Frontal Bone.....</i>	12
<i>The Ethmoid Bone.....</i>	13
The Bones of the Visceral Cranium.....	13
<i>The Upper Jaw Bone.....</i>	13
<i>The Palatine Bone.....</i>	14
<i>The Inferior Nasal Concha.....</i>	15
<i>The Nasal Bone.....</i>	15
<i>The Lacrimal Bone.....</i>	15
<i>The Vomer.....</i>	15
<i>The Zygomatic Bone.....</i>	15
<i>The Lower Jaw Bone.....</i>	15
<i>The Hyoid Bone.....</i>	17
Articulations of the Skull Bones.....	17
<i>The Temporomandibular Joint.....</i>	18
The Skull as a Whole.....	18
<i>Age Features of the Skull.....</i>	22
Sex Differences of the Skull.....	23
Pillars (Buttresses) of Cranium.....	23
Development of the Skull.....	24
Abnormalities of the Skull.....	26
Examination of the Skull on Alive Person.....	26
Craniology.....	27
Capitolul II. MUSCLES OF THE NECK AND HEAD MUSCLES OF THE NECK	
Superficial Muscles.....	29
The Middle Muscles, Or Muscles of the Hyoid Bone.....	29
<i>Muscles Located Above the Hyoid Bone.....</i>	29
<i>Muscles Located Below the Hyoid Bone.....</i>	30
The Deep Muscles.....	31
Lateral Muscles Attached to the Ribs, the Scalene Muscles.....	31
Prevertebral Muscles.....	31
Topography of the Neck.....	31
Fasciae of the Neck.....	32
The Muscles of the Head.....	33
Muscles of Mastication.....	33
Muscles of Facial Expression.....	34
Muscles of the Scalp.....	34
Muscles surrounding the Eyes.....	35
Muscles around the Mouth.....	35
Muscles surrounding the Nose.....	36
Fasciae of the Head.....	36
<i>Applied Anatomy.....</i>	37
Muscle Development.....	38
Capitolul III. THE SCIENCE OF THE VISCERA (SPLANCHNOLOGY)	
The Digestive System (Systema Digestorium).....	40

The Cavity of the Mouth	40
The Teeth	42
The Tongue	47
The Salivary Glands of the Oral Cavity	49
The Pharynx	49
Development of the Face And Formations of the Oral Cavity, Developmental Abnormalities and Age Peculiarities	51
The Respiratory System (Systema Respiratorium)	52
The Cavity of the Nose	53
The Larynx	54
<i>Cartilages of the Larynx</i>	54
<i>Ligaments and Joints of the Larynx</i>	55
<i>Muscles of the Larynx</i>	56
<i>The Cavity of the Larynx</i>	57
Topography, Projection and Examination of the Larynx on Alive Person, Age Peculiarities	58

Capitolul IV. THE SCIENCE OF THE VESSELS (ANGIOLOGY)

Branches of the Arch of the Aorta	59
<i>The Brachiocephalic Trunk</i>	59
<i>The Common Carotid Artery</i>	59
<i>The External Carotid Artery</i>	59
<i>The Internal Carotid Artery</i>	66
<i>The Subclavian Artery</i>	71
<i>The Veins of Systemic Circulation the System of Vena Cava Superior</i>	77
<i>The Innominate Veins</i>	78
<i>The Internal Jugular Vein</i>	78
<i>The External Jugular Vein</i>	79
<i>The Anterior Jugular Vein</i>	80
<i>The Subclavian Vein</i>	80
<i>Vertebral Venous Plexuses</i>	80
<i>X-Ray Examination of the Blood Vessels</i>	80
The lymphatic system	80
<i>The Lymphatics of the Head And Neck</i>	82
<i>The Collateral Flow of the Lymph</i>	83
<i>Anatomy of the Lymphatic System of a Living Person</i>	83
<i>Development of the Arteries</i>	84
<i>Development of the Veins</i>	85

Capitolul V. THE PERIPHERAL PART OF THE NERVOUS SYSTEM

Somatic Nerves	86
<i>The Spinal Nerves</i>	86
<i>The Posterior Branches Of The Spinal Nerves</i>	86
<i>The Anterior Branches Of The Spinal Nerves</i>	86
<i>The Cervical Plexus</i>	87
<i>The Cranial Nerves</i>	88
<i>Nn. Olfactorii; First Nerve</i>	89
<i>N. Opticus; Second Nerve</i>	89
<i>N. Oculomotorius; Third Nerve</i>	90
<i>N. Trochlearis; Fourth Nerve</i>	91
<i>N. Trigemini; Fifth Nerve</i>	91
<i>N. Abducens; Sixth Nerve</i>	99
<i>N. Facialis; Seventh Nerve</i>	99
<i>N. Vestibulo-Cochlearis; Eighth Nerve</i>	102
<i>N. Glossopharyngeus; Ninth Nerve</i>	103
<i>N. Vagus; Tenth Nerve</i>	104

<i>N. Accessorius; Eleventh Nerve</i>	107
<i>N. Hypoglossus; Twelfth Nerve</i>	107
<i>The Vegetative (Autonomic) Part of the Nervous System'</i>	108
<i>The Sympathetic Nervous System</i>	113
<i>The Central Part of the Sympathetic Nervous System</i>	113
<i>The Peripheral Part of the Sympathetic Nervous System</i>	113
<i>The Sympathetic Trunk</i>	114
<i>The Parasympathetic Nervous System</i>	115
<i>Innervation of Organs</i>	115
<i>Innervation of the Eye</i>	115
<i>Innervation of the Lacrimal and Salivary Glands</i>	116

Capitolul VI. AESTHESIOLOGY (SENSRY ORGANS)

<i>General Data</i>	118
<i>The Organ of Gravitation and Balance and the Organ of Hearing</i>	119
<i>The Organ Of Hearing</i>	121
<i>The External Ear</i>	121
<i>The Middle Ear</i>	122
<i>The Internal Ear</i>	123
<i>The Organ of Gravitation and Balance</i>	126
<i>The Organ of Vision</i>	128
<i>The Eyeball</i>	128
<i>The Coats of the Eyeball</i>	129
<i>The Refracting Media of the Eye</i>	131
<i>The Accessory Organs of the Eye</i>	131
<i>The Organ of Taste</i>	136
<i>The Organ of Smell</i>	136
Apendix	137

INTRODUCTION

The science of human anatomy is the study of the form and structure of the human body, with organs and systems which form it, and the rules of development of all structures in relation with its functions and external environment.

The head and neck comprise a highly specialized region of the body. The structures contained within this region are closely interrelated because they are compacted into a small, complicated area.

This course is accorded with academic program for dentistry students including Osteology, Muscular system, Internal organs, blood and lymphatic vessels, Peripheral somatic and vegetative nervous systems, Sense organs.

Modern anatomy has at its disposal a rich store of means for studying the structure of both the dead and alive human body.

There are two principal methods of study.

1. Examination of the cadaver by dissecting organs and tissues with surgical instruments. (anatomy means dissect)

2. Examination of a living person put in evidence the same: shape, position structure of the body organs. Any physician use 2 principal ways in patient exploration:

a. primary (observation, inspection, percussion, auscultation, with different modifications),

b. clinic instrumental investigation (X - ray examination, ultrasound instruments (USI), computer tomography (CT), magnetic resonance imaging (MRI), scintigraphic investigation, nuclear investigations etc.)

The course is divided into two parts: text core and appendix where collected pictures are used during reading. All pictures are notated in Latin, according to Anatomical Nomenclature.

Capitolul I. THE SKELETON OF THE HEAD

The head is related to the locomotor system only in part. Its skeleton **the skull**, (*cranium*) is primarily the receptacle for the most highly developed part of the nervous system, the brain and the sensory organs connected with it; moreover, it encloses the initial part of the digestive and respiratory tracts communicating with the external environment. In accordance with this, the skull of all vertebrates is divided into two parts: **the cerebral cranium** (*neurocranium*) and **the visceral cranium** (*cranium viscerale*). **The skull-cap**, or **vault** (*calvaria*) and **the base** (*basis*) are distinguished in the cerebral cranium.

The cerebral cranium consists of the **unpaired** *occipital*, *sphenoid*, *frontal*, and *ethmoid* bones and the **paired** temporal and parietal bones.

The visceral cranium is formed by the **paired** *maxilla*, *inferior turbinate*, *palatine*, *zygomatic*, *nasal*, and *lacrimal* bones and the **paired** *vomer*, *mandible*, and the *ethmoid* and *hyoid* bones.

THE BONES OF THE CEREBRAL CRANIUM

THE OCCIPITAL BONE

The occipital bone (*os occipitale*) forms the posterior and inferior walls of the brain case and is thus a part of *the calvaria* and a part of *the base of the skull*. In accordance with this, it (as a mixed bone) ossifies both as membrane bone in connective tissue (the squama of the occipital bone) and in cartilage (the remaining part of the bone). In man it forms from fusion of several bones that exist independently in some animals. It is thus made up of four parts, which are laid down separately and fuse to form a single bone only between the ages of 3 and 6. These parts, which form the borders of **the foramen magnum** (where the spinal cord is continuous with the medulla oblongata and passes from the vertebral canal into the cavity of the skull), are as follows: anteriorly, **the basilar part** (*pars basilaris*); laterally, **the lateral parts** (*partes laterales*); and posteriorly, **the squamous part** (*squama occipitalis*). The upper part of the squama, which is wedged between the parietal bones ossifies independently and is often separated by a transverse suture throughout life. In some animals, this also reflects the existence of an independent, interparietal bone (*os interparietale*), as the bone is also called in man.

1. **The squamous part** of the occipital bone (*squama occipitalis*) as a membrane bone is shaped like a plate, improperly rounded, with a **convex external surface** and a **concave internal surface**.

The attachment of muscles and ligaments lends it the external relief. **The external occipital protuberance** (*protuberantia occipitalis externa*) (the site of the appearance of the ossification nucleus) is in the centre of the external surface. A curved **superior nuchal line** (*linea nuchae superior*) passes laterally from the protuberance on each side. A less conspicuous **highest nuchal line** (*linea nuchae suprema*) is encountered a little higher. **The external occipital crest** (*crista occipitalis externa*) extends from the occipital protuberance downward on the midline to the posterior edge of the foramen magnum. **The inferior nuchal lines** (*lineae nuchae inferiores*) pass laterally from the middle of the crest.

The relief of the internal surface is determined by the shape of the brain and the attachment of its meninges; as a result this surface is divided by two crests intersecting at a right angle into four fossae. These two crests form **the cruciate eminence** (*eminentia cruciformis*) and **the internal occipital protuberance** (*protuberantia occipitalis interna*) at the site of their intersection. The lower half of the longitudinal crest is sharper and is called **the internal occipital crest** (*crista occipitalis interna*) while the upper half of this crest and both halves (or usually the right half) of the transverse crest are supplied with clearly pronounced sulci: **sagittal groove** (*sulcus sinus sagittalis superioris*) and **groove for the transverse sinus** (*sulcus sinus transversi*) (prints of venous sinuses of the same name which are lodged here).

2. **Each lateral part** (*pars lateralis*) contributes to the union of the skull with the spine and therefore carries on its inferior surface **the occipital condyle** (*condylus occipitalis*), the place of articulation with the atlas. The anterior – **the hypoglossal canal** (*canalis hypoglossi*) penetrates the bone approximately at the middle of the occipital condyle. Behind the condyle is **the condylar fossa** (*fossa condylaris*) on whose floor an opening of a posterior – **the condylar canal** (*canalis condylaris*) is sometimes present (for the

transmission of a vein). The **jugular process** (*processus jugularis*) projects laterally to the condyle; it is homologous with the transverse processes of the vertebrae. The **sigmoid groove** (*sulcus sinus sigmoidei*) (a mark left by the sigmoid venous sinus), is on the superior surface of pars lateralis, next to the jugular process, while the **jugular notch** (*incisura jugularis*) is on its margin.

3. The **basilar part** (*pars basilaris*) fuses with the sphenoid bone by the age of 18 to form a single bone in the centre of the cranial base (*os basillare*). A sloping area, *clivus*, made up of two fused parts, is located on the superior surface of this bone; it lodges the medulla oblongata. The **groove for the inferior petrosal sinus** (*sulcus sinus petrosi inferioris*) is seen on the lateral edges of the basilar part of the occipital bone; it lodges the inferior petrosal sinus. The inferior surface, which is a component of the superior pharyngeal wall, carries the **pharyngeal tubercle** (*tuberculum pharyngeum*) to which the fibrous capsule of the pharynx is attached.

THE SPHENOID BONE

The **sphenoid bone** (*os sphenoidale*) is an unpaired bone whose structure is even more complex than that of the occipital bone. The sphenoid bone resembles a bat or a flying insect, which explains the names of its parts (wings, pterygoid processes, Gk pterygoïn wing). The sphenoid bone forms as the result of fusion of several bones that in animals exist independently. It therefore develops as a mixed bone from several paired and unpaired foci of ossification merging by the time of birth into three parts, which, in turn, fuse to form a single bone by the end of the first year of life. The following parts can be distinguished: (1) the **body** (*corpus*); (2) the **greater wings** (*alae majores*); (3) the **lesser wings** (*alae minores*) and (4) the **pterygoid processes** (*processus pterygoidei*).

1. The **body** (*corpus*) has on the midline of its superior surface a depression, the shape of a **Turkish saddle**, the *sella turcica*, on the floor of which is a **depression for the cerebral hypophysis** (*fossa hypophysialis*). To the front of the depression is an elevation, the **tuberculum sellae**, on which the **sulcus chiasmatis** lodging the crossing (**chiasma**) of the fibres of the optic nerve passes transversely. The **optic foramina** (*canales optici*) transmitting the optic nerves from the orbital cavity into the cranial cavity, are found at the ends of the sulcus chiasmatis. The *sella turcica* is bounded posteriorly by a bony plate, the **dorsum sellae**. The lateral parts of the dorsum project forward in the form of the **posterior clinoid processes** (*processus clinoidae posteriores*). A curved **carotid groove** (*sulcus caroticus*) lodging the internal carotid artery passes on the lateral surface of the body. A ridge, the **crest of the sphenoid** (*crista sphenoidalis*) is seen on the anterior surface of the body, which is a part of the superior wall of the nasal cavity. The crest continues down to become a pointed vertical prominence, the **rostrum of the sphenoid** (*rostrum sphenoidale*), which fits between the wings of the vomer. The sphenoidal crest articulates in front with the perpendicular plate of the ethmoid bone. Irregularly shaped openings, apertures of the **sphenoidal sinus** (*aperturae sinus sphenoidalis*) are seen to the sides of the crest. They open into an air cavity; the **sphenoidal sinus** (*sinus sphenoidalis*) located in the body of the sphenoid bone and divided by a **septum of the sphenoidal sinus** (*septum sinuum sphenoidalium*) into two halves. The sinus communicates with the nasal cavity by means of these openings. These sinuses are very small in the newborn and start growing rapidly only at about 7 years of age.

2. The **lesser wings** (*alae minores*) are two flat triangular plates arising by two roots from the anterosuperior edge of the body of the sphenoid bone and extending forward and laterally. The optic canals mentioned above are located between the roots of the wings. The posterior edges of the lesser wings are free and carry on their medial ends the **anterior clinoid processes** (*processus clinoidae anteriores*) formed, just as the posterior clinoid processes, from the attachment of the process of the dura mater. The **superior orbital fissure** (*fissura orbitalis superior*) leading from the cranial into the orbital cavity, is between the lesser and greater wings.

3. The **greater wings** (*alae majores*) spring from the sides of the body laterally and upwards. A **round opening** (*foramen rotundum*) leading in front into the *pterygopalatine fossa*, is located close to the body, to the back of the superior orbital fissure; it transmits the second branch of the trigeminal nerve, n. trigemini. Posteriorly the greater wing is wedged between the squama and pyramid of the temporal bone as a sharp angle; a sharp projection, the **spine of the sphenoid** (*spina ossis sphenoidalis*) is found on the inferior surface of this angle. Close to it is the **spinous foramen** (*foramen spinosum*) through which the middle meningeal artery passes. A much **larger oval foramen** (*foramen ovale*) is seen to the front of it; it transmits the third branch of the trigeminal nerve.

The greater wings have the following four surfaces: **cerebral** (*facies cerebralis*); **orbital** (*facies orbitalis*); **temporal** (*facies temporalis*), and **maxillary** (*facies maxillaris*). Their names indicate which cranial surface they face. The last two surfaces are separated by the **infratemporal crest** (*crista infratemporalis*).

4. The **pterygoid processes** (*processus pterygoidei*), drop vertically downward from the junction of the greater wings and the body of the sphenoid bone. Their base is pierced by a **pterygoid canal** (*canalis pterygoideus*) directed sagittally, which transmits the pterygoid nerve and vessels. Its anterior opening communicates with the pterygopalatine fossa. Each process is made up of two plates, **one medial** and **one lateral** (*lamina medialis* and *lamina lateralis*), between which the **pterygoid fossa** (*fossa pterygoidea*) forms posteriorly. The inferior portion of this fossa is continuous with the **pterygoid fissure** (*fissura pterygoidea*). In the intact skull the pyramidal process of the palatine bone fits into this notch. The inferior part of the medial plate bends over to form a **hook-like process** called the *hamulus pterygoideus*. The tendon of m. tensor palatini (one of the muscles of the soft palate), which arises here, passes around the hamulus pterygoideus.

THE TEMPORAL BONE

The **temporal bone** (*os temporale*) is a paired bone whose structure is very complicated because it is concerned with all three functions of the skeleton and not only forms part of the lateral wall and base of the skull but houses the organs of hearing and equilibrium. It is the product of fusion of several bones (mixed bone), which exist independently in some animals, and therefore consists of three parts: (1) **squamous part** (*pars squamosa*); (2) **tympenic part** (*pars tympanica*) and (3) **petrous part** (*pars petrosa*) with **mastoid**.

Within the first year of life the parts fuse into a single bone and thus form the **external acoustic meatus** (*meatus acusticus externus*) with the squamous part to the top, the petrous part in a medial position, and the tympanic part to the back, bottom, and front. The traces of fusion of the separate parts of the temporal bone persist throughout life in the form of sutures and fissures, namely: **petrosquamous fissure** (*fissura petrosquamosa*) on the border between the squamous and petrous parts on the anterosuperior surface of the latter; the **tympenosquamous fissure** (*fissura tympenosquamosa*) in the depth of the mandibular fossa separated by the process of the petrous part into **fissura petrosquamosa**, and **petrotympanic fissure** (*fissura petrotympanica*), through which the chorda tympani nerve passes.

1. The **squamous part** (*pars squamosa*) contributes to the formation of the lateral walls of the skull. This membrane bone, which ossifies in connective tissue, has a relatively simple structure of a vertical plate with a rounded edge articulating with the corresponding edge of the parietal bone, **margo squamosa**, like the scales of fish, hence its name (L. squama - scale).

The **cerebral surface** (*facies cerebralis*) of the squamous part bears marks of the brain, **impressions for cerebral gyri** (*impressiones digitatae*) and an ascending groove lodging the **middle meningeal artery** (*a. meningea media*).

The **smooth external surface** of the squama contributes to the formation of the **temporal fossa** and is therefore called the temporal surface (*facies temporalis*). It gives rise to the **zygomatic process** (*processus zygomaticus*), which passes forward to join the zygomatic bone. The zygomatic process has two roots at its origin, **an anterior** and **a posterior root**, with a depression - **mandible fossa** (*fossa mandibularis*) for articulating with the lower jaw between them. The inferior surface of the anterior root carries an **articular tubercle** (*tuberculum articulare*), which prevents anterior dislocation of the head of the mandible when the mouth is opened very wide.

2. The **tympenic part** (*pars tympanica*) of the temporal bone forms the anterior, inferior, and part of the posterior border of the **external acoustic meatus**. It fuses with the mastoid process laterally and with the petrous part medially. It undergoes endesmal ossification and, as all membrane bones, resembles a plate, although in this case the plate is sharply bent.

The **external auditory meatus** (*meatus acusticus externus*) is a short canal directed medially and somewhat anteriorly and leading into the tympanic cavity. The superior edge of its **external opening** (*porus acusticus externus*) and part of the posterior edge are formed by the squama of the temporal bone. The other edges are formed by the tympanic part of the bone. The external acoustic meatus is incompletely formed in the newborn because the tympanic part is an **incomplete ring** (*anulus tympanicus*) closed by the tympanic membrane. Since the tympanic membrane is so near the external environment, newborns and infants often suffer from diseases of the membrane. The tympanic ring grows and is converted to a

tube during the first year of life; this tube pushes the petrous part medially and forms most of the bony external acoustic meatus whose roof is the squamous part. The tympanic membrane now moves deeper into the external acoustic meatus and separates it (i.e. the external ear) from the **tympanic cavity** (*cavum tympani*) (and becomes external in relation to the tympanic cavity). The floor of this cavity, just as the floor of the acoustic meatus, is formed by the tympanic part, while the superior and internal walls are formed by the petrous part.

3. The petrous part (*pars petrosa*) (Gk petros stone) is an important component of the temporal bone. It is so named because its bony substance is strong. It is a part of the base of the skull and at the same time is a bony encasement for the *organs of hearing and equilibrium*, which have a very fine structure and must be protected reliably from injuries. The petrous part develops in cartilage. This part is also called the **pyramid** because it is shaped like a trihedral pyramid with the **base** facing externally and the **apex** facing anteriorly and internally toward the sphenoid bone.

The **pyramid** has three surfaces: **anterior**, **posterior** and **inferior**. The anterior surface is part of the floor of the middle cranial fossa, the posterior surface faces posteriorly and medially and forms part of the anterior wall of the posterior cranial fossa; the inferior surface faces downward and is visible only on the external surface of the base of the skull. The complex external relief of the pyramid is determined by its structure as a receptacle for the middle (the tympanic cavity) and the internal ear (the bony labyrinth made up of the cochlea and the semicircular canals), as well as by the passage of nerves and vessels.

The **anterior surface** of the pyramid has a small depression near its apex. This is the **trigeminal impression** (*impressio trigemini*), which lodges the ganglion of the trigeminal nerve (n. trigeminus). Lateral to it pass two small grooves, a medial **sulcus of the greater petrosal nerve** (*sulcus n. petrosi majoris*) and a lateral **sulcus of the lesser petrosal nerve** (*sulcus n. petrosi minoris*). They lead to two openings of the same name, a medial **greater petrosal opening** (*hiatus canalis n. petrosi majoris*) and a lateral **lesser petrosal nerve opening** (*hiatus canalis n. petrosi minoris*). The **arcuate eminence** (*eminentia arcuata*) is lateral to these openings; it forms due to prominence of the vigorously developing labyrinth, particularly the superior semicircular canal. The bone surface between the petrosquamous fissure and the arcuate eminence forms the **roof of the tympanic cavity** (*tegmen tympani*).

In about the middle of the **posterior surface** of the pyramid is the **porus acusticus internus** (*porus acusticus internus*), leading into the **internal auditory meatus** (*meatus acusticus internus*), which transmits the facial and auditory nerves and the internal auditory artery and veins.

The **inferior surface** of the pyramid that faces the base of the skull gives off a slender tapering **styloid process** (*processus styloideus*) for attachment of the muscles forming the "anatomical bouquet" (m. styloglossus, m. stylohyoideus, m. stylopharyngeus) and also the ligaments (lig. Stylohyoideum and lig. stylomandibulare). The styloid process is part of the temporal bone of branchial origin. Together with the stylohyoid ligament, it is a remnant of the second visceral arch, the hyoid arch.

Sometimes the entire length of the stylohyoid ligament ossifies, which results in chronic developmental anomaly of the hyoid arch. Between the styloid and mastoid processes is the **stylomastoid foramen** (*foramen stylomastoideum*) transmitting the facial nerve and one of the arteries. The **deep jugular fossa** (*fossa jugularis*) is medial to the styloid process. To the front of the jugular fossa and separated from it by a sharp ridge is the **external opening of the carotid canal** (*foramen caroticum externum*).

The pyramid has three edges: anterior, posterior, and superior.

The short **anterior edge** forms a sharp angle with the squama, in which is found the **musculotubal canal** (*canalis musculotubarius*) leading to the tympanic cavity. The canal is divided by a septum into two parts: **superior** and **inferior**. The superior, smaller semicanal (**semicanalis m. tensoris tympani**) lodges the tensor tympani muscle, while the lower, larger semicanal (**semicanalis tubae auditivae**) is the bony part of the auditory tube for the conduction of air from the pharynx to the tympanic cavity.

The **superior edge** of the pyramid that separates the anterior and posterior surfaces bears a clearly detectable groove, **groove for the superior petrosal sinus** (*sulcus sinus petrosi superioris*) lodging the superior petrosal venous sinus.

The **posterior edge** of the pyramid joins the pars basilaris of the occipital bone to the front of the jugular fossa and together with this bone forms the **groove for the inferior petrosal sinus** (*sulcus sinus petrosi inferioris*) lodging the inferior petrosal sinus.

The **external surface** of the base of the pyramid provides attachment for the muscles; this determines its relief (process, notches, and areas of roughness). Its lower end stretches out to form the **mastoid process** (*processus mastoideus*) to which the sternocleidomastoid muscle is attached. This muscle ba-

lances the head, which is necessary for maintenance of the vertical posture of the body. The mastoid process is absent, therefore, in quadrupeds and anthropoid apes and develops only in man due to his erect posture. The medial surface of the mastoid process bears a deep **mastoid notch** (*incisura mastoidea*), the site of attachment of *m. digastricus*, and, still closer to the midline, a small **occipital artery groove** (*sulcus a. occipitalis*). A smooth triangle on the external surface of the base of the mastoid process is the operative approach to the *air cells* of the process when they are filled with pus that comes from tympanic cavity. The **suprameatal spine** (*spina suprameatum*) projects in front of the triangle.

The mastoid process contains compartments or **air cells** (*cellulae mastoidea*), which are air cavities separated by bone trabeculae. They receive air from the tympanic cavity with which they communicate by means of the **mastoid antrum** (*antrum mastoideum*). A deep **sigmoid groove** (*sulcus sinus sigmoidei*) is found on the cerebral surface of the base of the pyramid. The canal of the venous emissary opens into this sulcus; its external opening, **mastoid foramen** (*foramen mastoideum*), varying greatly in accordance with the size of the canal, is near to or in the occipitomastoid suture.

The canals of the temporal bone.

1. The largest is the **carotid canal** (*canalis caroticus*), which transmits the internal carotid artery. It begins as the **external carotid foramen** (*foramen caroticum externum*) on the interior surface of the pyramid, then ascends and bends at a right angle and opens by its **internal foramen** (*foramen caroticum internum*) at the apex of the pyramid medial to the *canalis musculotubarius*.

2. The **canal for the facial nerve** (*canalis facialis*) begins in the depth of *porus acusticus internus* and then passes at first forward and laterally to the hiatus in the anterior surface of the pyramid. There the *canalis facialis*, still horizontal, bends at a right angle laterally and backward to form the **knee of the facial canal** (*geniculum canalis facialis*); it then descends and ends as the **stylomastoid foramen** (*foramen stylomastoideum*) on the inferior surface of the pyramid of the temporal bone.

3. The **canalis musculotubarius** (see above).

4. The **canaliculi caroticotympanici**, two small canaliculi branching off from carotid canal and lead into tympanic cavity, its transmit the caroticotympanic nerves and arteries.

5. The **canaliculus chordae tympany**, runs off the lateral wall of the canal of facial nerve a few mm above the stylomastoid orifice. The canaliculus transmits the branch of facial nerve called *chorda tympani* which leaves the tympanic cavity through the petrotympanic fissure.

6. The **canaliculus tympanicus**, starts in fossula petrosa, passes to the inferior wall of tympanic cavity, pierces it and enters the cavity. The tympanic nerve, the content of this canaliculus, exits through hiatus nervi petrosi minoris.

7. The **mastoid canaliculus**, originates in jugular fossa opens into tympanomastoid fissure. It transmits the auricular branch of vagus nerve.

THE PARIETAL BONE

The **parietal bone** (*os parietale*) is a paired bone forming the middle part of the vault of the skull. It is better developed in man than in animals because of the higher development of man's brain. This is a typical membrane bone, which primarily performs a protective function. Its structure, therefore, is relatively simple; it is a **quadrangular plate** with convex **external** and concave **internal surfaces**. Its **four borders** articulate with the adjoining bones, namely: 1. the **frontal border** (*margo frontalis*) with the frontal bone; 2. the posterior, **occipital border** (*margo occipitalis*) with the occipital bone; 3. the superior, **sagittal border** (*margo sagittalis*) with the contralateral bone, 4. and the inferior, **squamosal border** (*margo squamosus*) with the squama of the temporal bone. The first three borders are serrated, while the last is adapted for the formation of a squamous suture.

The four angles are as follows: the **frontal angle** (*angulus frontalis*) unites with the frontal bone; the **sphenoidal angle** (*angulus sphenoidalis*) joins with the sphenoid bone; the **occipital angle** (*angulus occipitalis*) articulates with the occipital bone; and the **mastoid angle** (*angulus mastoideus*) unites with the mastoid process of the temporal bone.

The relief of the **external convex surface** is determined by the attachment of muscles and fasciae. In its centre is a prominence, the **parietal eminence** (*tuber parietalis*) (where ossification begins). Below it are two curved **temporal lines** (*linea temporalis superior* and *inferior*) for attachment of the temporal fascia and muscle. An opening, the **parietal foramen** (*foramen parietale*) for the artery and the venous emissary is seen near to the superior border.

The relief of the **internal concave surface** (*facies internus*) is determined by the brain and especially the dura mater, which fit close to it. The sites of attachment of the dura mater to the bone are marked by a **sagittal groove** (*sulcus sinus sagittalis superioris*) (lodging the superior sagittal sinus) on the superior border, and a **sigmoid groove** (*sulcus sinus sigmoidei*) (lodging the sigmoid sinus), in the region of the angulus mastoideus. The vessels of the dura mater have left imprints forming a pattern of branching grooves on almost the entire internal surface. Pits for **pacchionian granulations** (*foveolae granulares*) are seen on either side of the sulcus sinus sagittalis superioris.

THE FRONTAL BONE

The **frontal bone** (*os frontale*) an unpaired, membrane bone, contributes to the formation of the vault of the skull and develops in connective tissue. It is, moreover, associated with the organs of sense (smell and vision). In accordance with this double function, the frontal bone is made up of two parts: a vertical part, **squama** (*squama frontalis*) and a horizontal part. According to its relation to the organs of vision and smell, the **paired orbital part** (*pars orbitalis*) and an **unpaired nasal part** (*pars nasalis*) are distinguished in the horizontal part. As a result, the following four parts are distinguished in the frontal bone.

1. The **frontal squama** (*squama frontalis*) as any membrane bone, has the shape of a plate, externally convex and internally concave. It ossifies from two ossification points, which are apparent even in an adult as two **frontal tubers** (*tubera frontalia*) on the external surface (*facies extern*). They are pronounced only in man due to the development of the brain. They are absent not only in anthropoid apes but also in extinct forms of man. The inferior border of the squama is called the **supraorbital border** (*margo supraorbitalis*). Approximately at the junction of the medial and middle third of this border is the **supraorbital notch** (*incisura supraorbitalis*) (which transforms sometimes into a **foramen supraorbitale**), transmitting the supraorbital arteries and nerve. Eminences, the **superciliary arches** (*arcus superciliares*) varying greatly in size and length, are seen immediately above the supraorbital border; they are continuous medially on the midline with a more or less prominent area, the **glabella**, the superior part of the bridge of the nose. The glabella is an important feature in distinguishing the skull of modern man from a fossil skull. The lateral end of the supraorbital border stretches out to form the **zygomatic process** (*processus zygomaticus*), which articulates with the zygomatic bone. A clearly detectable **temporal line** (*linea temporalis*) extends upward from the process; this line delimits the **temporal surface** (*facies temporalis*) of the squama. A small groove, **sagittal groove** (*sulcus sinus sagittalis superioris*) runs on the midline of the **internal surface** (*facies interna*) from the posterior border and is continuous at the lower end with the **frontal crest** (*crista frontalis*). These structures provide attachment for the dura mater. Depressions for the **pacchionian granulations** (*arachnoid villi*) are seen near the midline.

2. The **orbital parts** (*partes orbitales*) are two horizontal plates whose inferior concave surface faces the orbit. The **superior surface** faces the cranial cavity, and the posterior border articulates with the sphenoid bone. The superior cerebral surface bears marks of the brain, namely **cerebral ridges** of cranium (*juga cerebralis*) (BNA) (L juga-yoke), and **digitate impressions** (*impressiones digitatae*). The **inferior surface** (*facies orbitalis*) forms the superior orbital wall and bears marks of adjacent accessories of the eye: the **lacrimal fossa** (*fossa glandulae lacrimalis*) near the zygomatic process; **trochlear fossa** (*fovea trochlearis*) near the supraorbital notch; and **trochlear spine** (*spina trochlearis*) where the trochlea for the tendon of the oblique superior muscles of the eye is attached. The orbital parts are separated by the **ethmoid notch** (*incisura ethmoidalis*), which in an intact skull is filled by the ethmoid bone.

3. The **nasal part** (*pars nasalis*) occupies the anterior part of the ethmoid notch on the midline. A projection ending as a sharp process, the **nasal spine** (*spina nasalis*), is found here; it helps to make up the nasal septum. On either side of the spine are depressions, which serve as the superior wall for the sinuses of the ethmoid bone. To the front of them is an opening leading into the **frontal sinus** (*sinus frontalis*) located in the thickness of the bone to the back of the superciliary arches; the sinus varies greatly in size. The frontal sinus contains air and is separated by the **septum of the frontal sinus** (*septum sinuum frontium*). Accessory frontal sinuses are sometimes encountered to the back of or between the main sinuses. Among all the skull bones, the frontal bone is most typical of man. It changed most in the process of evolution. In the earliest hominids (as in the anthropoid apes), it was sloped sharply backward, forming a forehead sloping to the back. Beyond the orbital narrowing it was sharply divided into the squama and the orbital parts. A continuous thick elevation stretched on the edge of the orbit from one zygomatic process to the contralateral one. The elevation diminished considerably in modern man, and only the superci-

liary arches remained. In accordance with the development of the brain, the squama straightened out to a vertical position. The frontal tubers developed at the same time; as the result the shape of the forehead changed from sloping to convex, lending the skull its characteristic appearance.

THE ETHMOID BONE

The **ethmoid bone** (*os ethmoidale*) is an unpaired bone usually described in the group of bones of the cerebral cranium, although most of it helps to make up the visceral cranium. The ethmoid bone is located centrally between the bones of the face and comes in contact with most of them to form the nasal cavity and orbit. In an intact skull it is covered by them. It develops in connection with the nasal capsule in cartilage. Formed of thin bone plates surrounding the air sinuses, it is light and fragile.

The bony plates of the ethmoid bone are arranged in the form of the letter "T" in which the vertical line is the **perpendicular plate** (*lamina perpendicularis*) and the horizontal is the **cribriform plate** (*lamina cribrosa*). From the lamina cribrosa, on either side of the perpendicular plate, hang the **ethmoidal labyrinths** (*labyrinthi ethmoidales*). As a result four parts are distinguished in the ethmoid bone.

1. **Lamina cribrosa** is a rectangular plate fitting into the ethmoid notch of the frontal bone. It is perforated by small openings like a sieve, hence its name (Gk ethmos sieve, eidos form). These perforations transmit the branches of the olfactory nerve (about 30 of them). The **crista galli** with its wings projects upward from the midline of the cribriform plate (for attachment of the dura mater).

2. **Lamina perpendicularis** is a part of the nasal septum.

3. **Labyrinthi ethmoidales** make up a paired complex of bony **air cells** (*cellulae ethmoidales*) covered laterally by a thin **orbital plate** (*lamina orbitalis*), which forms the medial wall of the orbit. The upper border of the orbital plate articulates with the orbital part of the frontal bone, the anterior border with the lacrimal bone, the posterior border with the orbital process of the palatine bone, and the inferior border with the upper jaw; all these bones cover the laterally located cellulae ethmoidales. On the medial surface of the labyrinth are two **nasal conchae** (*conchae nasales superior* and *media*), although sometimes there is a third, **highest nasal concha** (*concha nasalis suprema*).

The conchae (Gk konche shell) are thin, curved plates; as the result of such a shape, the surface of the nasal mucosa covering them increases.

THE BONES OF THE VISCERAL CRANIUM

The bones of the visceral cranium form bony receptacles for the organs of sense (vision, olfaction) and for the initial parts of the alimentary (oral cavity) and respiratory (nasal cavity) systems, which determines their structure. They reflect the changes which occurred in the soft tissues of the head in the process of humanization of the ape, i.e. the leading role of labour, the partial transference of the grasping function from the jaws to the hands, which became the tools of work, the development of articulate speech, the development of the brain and its tools, the organs of sense, and, finally, the preparation of food which made the work of the masticatory apparatus easier.

THE UPPER JAW BONE

The **upper jaw bone** (*maxilla*) is a paired bone of a complex structure determined by the diversity of its functions: it takes part in the formation of cavities for the organs of sense, the orbit and nose, in the formation of the septa between the cavities of the nose and mouth, and in the work of the masticatory apparatus. The maxilla consists of a **body** and **four processes**.

A. The **body** (*corpus maxillae*) contains a **large maxillary air sinus** (*sinus maxillaris s. antrum Highmori*, BNA) (hence highmoritis, inflammation of the maxillary sinus), which communicates with the nasal cavity by a wide opening, the **maxillary hiatus** (*hiatus maxillaris*). The following **four surfaces** are distinguished on the body.

The **anterior surface** (*facies anterior*), is concave in modern man since his food is prepared and the function of mastication is consequently weaker. Inferiorly it is continuous with the **alveolar process**, in which a series of depressions between the ridges of the tooth roots (*juga alveolaria*) are seen. The ridge corresponding to the canine tooth is most pronounced. The **canine fossa** (*fossa canina*) is above and lateral to it. Superiorly the anterior surface of the maxilla is separated from the orbital surface by the **infraorbital margin** (*margo infraorbitalis*). Immediately below it is the **infraorbital foramen** (*foramen infraorbitale*) through which the infraorbital nerve and artery leave the orbit. The medial border of the

anterior surface is formed by the **nasal notch** (*incisura nasalis*) whose edge extends forward to form the **anterior nasal spine** (*spina nasalis anterior*).

The **infratemporal surface** (*facies infratemporalis*) is separated from the anterior surface by the zygomatic process and carries several small perforations (**foramina alveolaria**), transmitting the nerves and vessels to the upper teeth, the **maxillary tuber** (tuberosity of maxilla) (*tuber maxillae*) and the **greater palatine sulcus** (*sulcus palatinus major*).

The **nasal surface** (*facies nasalis*) is continuous inferiorly with the superior surface of the palatine process. The **conchal crest** (*crista conchalis*) is seen on it. To the back of the frontal process is the **nasolacrimal groove** (*sulcus lacrimalis*) which, with the lacrimal bone and the inferior nasal concha, is converted into the **nasolacrimal canal** (*canalis nasolacrimalis*) by means of which the orbit communicates with the inferior nasal concha. Still farther back is a large opening that leads to the maxillary sinus. In an intact skull this opening is made somewhat smaller by parts of bones overlapping it, namely the lacrimal, ethmoid, and palatine bones and the inferior concha.

The smooth, flat **orbital surface** (*facies orbitalis*) is triangular. On its medial border, behind the frontal process, is the **lacrimal notch** (*incisura lacrimalis*) lodging the lacrimal bone. The **infraorbital groove** (*sulcus infraorbitalis*) originates near the posterior border of the orbital surface and is converted anteriorly into the **infraorbital canal** (*canalis infraorbitalis*), which opens onto the anterior surface of the maxilla by means of the infraorbital foramen mentioned above. The **alveolar canals** (*canales alveolares*) arise from the infraorbital canal; they transmit nerves and vessels passing in the thickness of the anterior maxillary wall to the anterior teeth.

B. Processes.

1. The **frontal process** (*processus frontalis*) projects upward and joins the pars nasalis of the frontal bone. Its lateral surface is divided into two parts by a vertical lacrimal crest (*crista lacrimalis anterior*), which is continuous downward with the infraorbital margin. The medial surface carries the ethmoidal crest (*crista ethmoidalis*) for attachment of the middle nasal concha.

2. The **alveolar process** (*processus alveolaris*) carries on its inferior border, alveolar arch (*arcus alveolaris*), dental sockets (*alveoli dentales*) for the eight upper teeth; the sockets are separated by septa interalveolaria.

3. The **palatine process** (*processus palatinus*) forms most of the **hard bony palate** (*palatum osseum*) by joining the contralateral process in the mid-line. Where they meet, the **nasal crest** (*crista nasalis*) rises on the superior surface facing the nasal cavity and articulates with the inferior edge of the vomer. Near the anterior end of the nasal crest on the superior surface is an opening that leads into the **incisive canal** (*canalis incisivus*). The superior surface of the process is smooth, whereas the inferior surface, facing the oral cavity, is rough (impressions of the mucosal glands) and carries longitudinal **palatine grooves** (*sulci palatini*) lodging the nerves and vessels. The **incisive suture** (*sutura incisiva*) is often seen in the anterior part. It delimits the os incisivum which fuses with the maxilla. In many animals this bone exists as an independent bone (**os intermaxillare**), but in man it is rarely encountered.

4. The **zygomatic process** (*processus zygomaticus*) articulates with the zygomatic bone to form a thick support through which pressure produced during mastication is transmitted to the zygomatic bone.

THE PALATINE BONE

The **palatine bone** (*os palatinum*) is a paired bone. Though it is small, it nevertheless contributes to the formation of some of the cranial cavities, namely the cavities of the nose, mouth, orbits, and the pterygopalatine fossa. This determines its peculiar structure: it is a thin bone consisting of two plates uniting at a right angle and supplementing the maxilla.

1. The **horizontal plate** (*lamina horizontalis*) complements the maxillary palatine process posteriorly to form the **hard palate** (*palatum osseum*). Its medial border meets the medial border of the contralateral bone to form the **nasal crest** (*crista nasalis*). On the inferior surface of the horizontal plate is the greater palatine foramen (*foramen palatinum majus*), through which palatine vessels and nerves leave the **canalis palatinus major**.

2. The **perpendicular plate** (*lamina perpendicularis*) adjoins the nasal surface of the maxilla. Along its lateral surface runs the **greater palatine sulcus** (*sulcus palatinus major*), which together with the maxillary sulcus of the same name forms the **canalis palatinus major**. The medial surface has two crests for two **nasal conchae**, the **middle** (*crista ethmoidalis*) and the **inferior** (*crista conchalis*). The palatine bone has three processes. One of them, the **pyramidal process** (*processus pyramidalis*) projects backward

and laterally from the junction of the horizontal and perpendicular plates. In an intact skull the pyramidal process fits into the pterygoid fissure of the sphenoid bone. Nerves and vessels penetrate it vertically through **the lesser palatine canals** (*canales palatini minores*). The other two processes project from the superior edge of the perpendicular plate and form **the sphenopalatine notch** (*incisura sphenopalatina*), which meets the body of the sphenoid bone to form **the sphenopalatine foramen** (*foramen sphenopalatinum*) transmitting the sphenopalatine vessels and nerves. The anterior process forms the posterior corner of the orbit and is therefore known as **the orbital process** (*processus orbitalis*); the posterior process adjoins the inferior surface of the body of the sphenoid bone and is called **the sphenoid process** (*processus sphenoidalis*).

THE INFERIOR NASAL CONCHA

The inferior nasal concha or inferior turbinate bone (*concha nasalis inferior*) is a paired bone. As distinct from the superior and middle nasal conchae, which are components of the ethmoid bone, the inferior nasal concha is an independent bone. It is a thin, curled plate of bone whose upper edge is attached to the lateral wall of the nasal cavity; it isolates the middle nasal meatus from the inferior meatus. Its inferior edge is free, while the upper edge articulates with the conchal crests of the maxilla and the palatine bone.

THE NASAL BONE

The nasal bone (*os nasale*) joins the contralateral bone to form the ridge of the nose at its root. In man the nasal bone is underdeveloped in comparison to that in animals.

THE LACRIMAL BONE

The lacrimal bone (*os lacrimale*), a paired bone, is a thin plate found in the medial wall of the orbit immediately behind the frontal process of the maxilla. Its lateral surface carries the crest of the lacrimal bone (*crista lacrimonalis posterior*). To the front of the crest runs **the lacrimal groove** (*sulcus lacrimonalis*), which meets the sulcus of the frontal process of the maxilla to form the fossa of **the lacrimal sac** (*fossa sacculi lacrimonalis*). The lacrimal bone of man is similar to that of anthropoid apes, which is evidence that these apes are closely related to hominids.

THE VOMER

The vomer, an unpaired bone, is an irregularly quadrangular plate, which resembles a plowshare (hence its name: L vomer plowshare) and forms part of the bony nasal septum. Its superior border is split into **two wings** (*alae vomeris*), which fit over the rostrum of the sphenoid bone. The upper half of the anterior edge articulates with the perpendicular plate of the ethmoid bone, and the lower part with the cartilaginous nasal septum. The inferior edge articulates with the nasal crests of the maxilla and palatine bone. The free, posterior edge is the posterior border of the bony nasal septum separating the posterior openings of the nasal cavity, choanae, by means of which the nasal cavity communicates with the nasopharynx.

THE ZYGOMATIC BONE

The zygomatic bone (*os zygomaticum*) is a paired bone, the strongest bone of the skull. The zygomatic bone is important to the architecture of the face because it connects the frontal and temporal bones and the maxilla by articulating with their zygomatic processes and thus strengthening the bones of the visceral skull in relation to the cerebral skull. It is also an extensive surface for the origin of the masseter muscle. According to the location of the bone, three surfaces and two processes are distinguished in it. **The lateral surface** (*facies lateralis*) is shaped like a four-point star and bulges slightly. **The smooth posterior surface** faces the temporal fossa and is called the temporal surface (*facies temporalis*). **The third orbital surface** (*facies orbitalis*) takes part in the formation of the orbital walls. **The superior frontal process** of the zygomatic bone (*processus frontalis*) articulates with the zygomatic process of the frontal bone and the greater wing of the sphenoid bone. An eminence for attachment of the muscles and ligaments of the eyelids is often found on its orbital surface. **The lateral temporal process** (*processus temporalis*) articulates with the zygomatic process of the temporal bone to form the zygomatic arch, the site of origin of the masseter muscle.

THE LOWER JAW BONE

The lower jaw bone or **the mandible** (*mandibula*) is a mobile skull bone. Its horseshoe shape is determined both by its function (the most important part of, the masticatory apparatus) and by its develop-

ment from the first visceral (mandibular) arch whose shape it retains to a certain extent. In mammals, including the lowest primates, the mandible is a paired bone. In accordance with this, in man the mandible develops from two germs which, growing gradually, fuse in the second year after birth into an unpaired bone; the mark of the fusion of the two halves, however, remains (*symphysis mandibulae*). The bone develops in connective tissue. The masticatory apparatus consists of a passive part, i.e. the teeth, concerned with mastication, and an active part, i.e. the muscles. Accordingly, the mandible consists of a **horizontal part or body** (*corpus mandibulae*), which carries the teeth, and a **vertical part in the form of two branches of the mandibulae** (*rami mandibulae*), which serve for the formation of the temporomandibular joint and for attachment of the muscles of mastication. The horizontal and the vertical parts meet at an angle called the **angle of the mandible** (*angulus mandibulae*), on the external surface of which the masseter muscle is inserted into the **masseteric tuberosity** (*tuberositas masseterica*). On the inner surface of the angle is the **pterygoid tuberosity** (*tuberositas pterygoidea*) for insertion of another muscle of mastication, m. pterygoideus medialis.

The activity of the masticatory apparatus, therefore, has an effect on the size of this angle. It is close to 150 degrees in the newborn, diminishes to 130-110 degrees in an adult, and again increases in old age with the loss of teeth and weakening of the masticating act.

The structure and relief of **the body of the mandible** are determined by the teeth and by the fact that the mandible takes part in the formation of the mouth. For instance, the upper, alveolar part of the body (*pars alveolaris*) bears teeth as a consequence of which its border, **the alveolar arch** (*arcus alveolaris*) has **sockets for the teeth** (*alveoli dentales*), with **interalveolar septa** (*septa interalveolaria*) and corresponding depressions on the external surface (*juga alveolaria*). The rounded massive and thick inferior border of the body forms **the base of the mandible** (*basis mandibulae*). At old age when the teeth are lost, the alveolar part atrophies and the whole body of the mandible becomes thin and low. The ridge on the symphysis on the midline of the body is continuous with a triangular **mental protuberance** (*protuberantia mentalis*), the presence of which is characteristic of modern man. Among all mammals only man, and modern man at that, has a pronounced chin. The anthropoid ape, the Pithecanthropus man, and the Heidelberg man have no mental protuberance; their jaw instead has a border that curves to the back. The Neanderthal man also lacks a protuberance, but the mandibular border here is rectangular. A true chin forms only in modern man. On each side of this protuberance is a **mental tubercle** (*tuberculum mentale*). On the lateral surface of the body, in the space between the first and second premolars, is **the mental foramen** (*foramen mentale*), which is an opening of **the mandibular canal** (*canalis mandibulae*), transmitting a nerve and vessels. **An oblique line** (*linea obliqua*) runs to the back and upward from the mental tubercle. Two **mental spines** (*spinae mentales*) project from the inner surface of the symphysis; these are the sites of attachment of the tendon of the genioglossus muscle. In anthropomorphic apes the spine here is replaced by a fossa because the genioglossus muscle is attached not by a tendon but by muscular tissue. All transient forms were found in a series of fossil skulls, from those with a fossa typical of the skull of apes (due to muscular attachment of m. genioglossi) and without a chin to those with a spine determined by attachment of the muscle by means of a tendon and with a protruding chin. A change in the means of attachment of the genioglossus muscle from muscular to tendinous thus caused the formation of a spine and the consequent development of a chin. Since the tendinous method of attachment of the tongue muscles was conducive to the development of articulate speech, the transformation of the bone relief in the region of the chin, a purely human feature, should, therefore, also be associated with the faculty of speech. On both sides of the mental spine, nearer to the inferior border of the mandible is the site for attachment of the digastric muscle, **the digastric fossa** (*fossa digastrica*). Further to the back is **the mylohyoid line** (*linea mylohyoidea*), running backward and upward; it serves for attachment of the mylohyoid muscle.

The ramus of the mandible (*ramus mandibulae*) rises on each side from the posterior part of the body of the mandible. On its inner surface is **the mandibular foramen** (*foramen mandibulae*), leading into the mandibular canal mentioned above. The medial edge of this foramen projects as **the lingula of the mandible** (*lingula mandibulae*), to which is attached the sphenomandibular ligament; the lingula is developed more in man than in apes. **The mylohyoid groove** (*sulcus mylohyoideus*) originates behind the lingula and runs downward and forward; it lodges the mylohyoid nerve and vessels. Superiorly the ramus of the mandible terminates as two processes, anterior **coronoid process** (*processus coronoideus*) (it forms under the effect of traction exerted by the strong temporal muscle) and a posterior **condylar process** (*processes condylaris*). A crest for the attachment of **the buccinator muscle** (*crista buccinatoria*) runs on the

inner surface of the ramus upward from the surface of the alveoli of the last molars towards the coronoid process.

The condylar process has a **head** (*caput mandibulae*) and a **neck** (*collum mandibulae*). On the anterior surface of the neck is the **pterygoid pit** (*fovea pterygoidea*) for attachment of the lateral pterygoid muscle. The head of the condylar process is stretched out in the transverse direction, but the medial end of its axis slants to the back so that the longitudinal axes of both heads, when continued, intersect at the anterior border of the foramen magnum at an angle of 140-150 degrees.

In summary of the description of the mandible, it should be pointed out that its shape and structure characterize modern man. During the process of labour, which was responsible for the transformation of the ape into a human being, the function of grasping changed from the jaws to the hands which became organs of labour. Man's diet of prepared food made the work of his masticatory apparatus easier. All this led to diminished activity of the teeth and sharp reduction of the lower jaw, as compared with that of anthropoid apes and even with the lower jaw of fossil humans, for instance, with that of the Heidelberg man. At the same time, articulate speech developed in man; it was associated with increased and fine work of the tongue muscles attached to the mandible. The mental region of the mandible which is connected with these muscles, functioned intensely and withstood the factors of regression. Spines and a protuberance formed on it. Their formation was also promoted by distension of the mandibular arch as a consequence of the increased transverse dimension of the cerebral cranium under the effect of the growing brain. Thus, the shape and structure of man's lower jaw formed under the effect of the development of labour, articulate speech, and the brain, i.e. properties characteristic of man.

THE HYOID BONE

The hyoid bone (*os hyoideum*) is situated at the base of the tongue, between the mandible and the larynx. It belongs to the visceral skull and develops from the hyoid and first branchial arches. In accordance with this development, it acquires the shape of an arch. It consists of a **body** (*corpus*) and **two pairs of horns** (*cornua*). **The greater horns** (*cornua majora*) are continued from both ends of the body and extend backwards and somewhat laterally; they are at first joined to the body by cartilage which later is replaced by bone. **The lesser horns** (*cornua minora*) arise from the junction of the body and the greater horns and project upward and backward. The lesser horns ossify only in the elderly and fuse with the body after the age of 50. The hyoid bone is suspended from the base of the skull by means of two long fibrous cords, **stylohyoid ligaments** (*lig. stylohyoideum*), stretching from the lesser horns to the styloid processes of the temporal bones.

ARTICULATIONS OF THE SKULL BONES

The bones of the skull articulate mainly by syndesmosis: manifested by **sutures** on the skulls of adults and **interosteal membranes** (*fontanelles*) on the skull of the newborn, which reflects the development of the bones of the vault in connective tissue and its principal function of protection. Almost all bones forming the vault of the skull, with the exception of the squama of the temporal bone, articulate by means of a **serrate suture** (*sutura serrata*). The squama of the temporal bone joins with the squamous border of the parietal bone by means of a **squamous suture** (*sutura squamosa*). The bones of the visceral skull fit together at relatively smooth borders to form a **plane suture** (*sutura plana*). The difference in the type of the sutures is associated with the different mechanisms of the actions exerted on the separate parts of the skull (the traction or pressure of muscles, the weight of the visceral skull, etc.). The sutures are designated by the names of the two articulating bones, e.g. sutura sphenofrontalis, sphenoparietalis, etc. The base of the skull has **synchondroses** of fibrous cartilage lodged in the fissures between the bones: **synchondrosis petrooccipitalis** in the petrooccipital fissure between the pyramid of the temporal bone and the basilar part of the occipital bone; **synchondrosis sphenopetrosa** is the sphenopetrosal fissure. **The sphenoccipital synchondrosis** (*synchondrosis sphenoccipitalis*) between the body of the sphenoid bone and the basilar part of the occipital bone and synchondroses between the four parts of the occipital bone are encountered at early age. The synchondroses in the base of the skull are remnants of cartilaginous tissue in which the bones of the base develop, which is associated with its functions of support, protection, and movement. Besides the sutures and synchondroses always found in man's skull some persons have accessory sutures: a **frontal suture** (*sutura metopica*) (Gk metopon forehead of L glabella), in non-fusion of both halves of the squama of the frontal bone (in 9.3 %); **sagittal** and **transverse sutures** in the

697904

Universitatea de Stat de
Medicină și Farmacie
«Nicolae Testemițanu»

Biblioteca Științifică Medicală

squama of the occipital bone, sometimes (0.55 %) with full separation of the squama into an upper and lower part, in which case the upper part is called **the interparietal bone** (*os interparietale*) on account of its position; separation of the parietal bone at the squama of the temporal bone (0.1 %) or at the greater wing of the sphenoid bone (1.1 %); synchondrosis between the squama and the lateral parts of the occipital bone (4 %); and a mastosquamous synchondrosis (0.5 %).

Skull bones are sometimes encountered in the sutures; these are the bones of the fontanelles and bones of the sutures, **sutural (wormina) bones, ossa suturarum Wormiana**.

During X-ray examination all these irregular bones and articulations of bones must be distinguished from injuries to the skull bones.

The paired **temporomandibular articulation** joining the mandible with the base of the skull is the **only diarthrosis** of the skull.

THE TEMPOROMANDIBULAR JOINT

The temporomandibular joint (*articulatio temporomandibularis*) is formed by the head of the mandible and the mandibular fossa of the temporal bone. The articulating surfaces are complemented by **a fibrous articular disc** (*discus articularis*) located between them. The edges of the disc are joined to the articular capsule as a result of which the joint cavity is separated into two isolated compartments. The articular capsule is attached along the border of the mandibular fossa up to the petrotympanic fissure and thus encloses the articular tubercle and embraces the neck of the mandible inferiorly. Near the temporomandibular joint are three ligaments only one of which, **the lateral ligament** (*lig. laterale*), is directly related to the joint. It passes obliquely backward on the lateral side of the joint from the zygomatic process of the temporal bone to the neck of the condylar process of the mandible. The lateral ligament prevents excessive movement of the articular head to the back. The remaining two ligaments (*lig. sphenomandibulare* and *lig. stylomandibulare*) are at a distance from the joint and are actually not ligaments but artificially separated areas of fascia, which form a loop-like structure to help to suspend the mandible.

Both temporomandibular joints function simultaneously and are therefore **a single combined** articulation from the mechanical standpoint. The temporomandibular articulation is a **condyloid joint**, but because of the articular disc, it permits movements in three directions. The mandible makes the following movements: (1) downward and upward movements with opening and closure of the mouth; (2) forward and backward movements; (3) lateral movements (rotation of the mandible to the right and to the left as it occurs in chewing). The first of these movements is made in the lower compartment of the joint, between the articular disc and the articular head. When the mandible moves downward, its heads first glide together with the discs (first phase) and then rotate on the transverse axis passing through both heads (second phase). To open the mouth wide, the heads glide forward and downward with the discs onto the articular tubercles that prevent dislocation of the jaw.

Movements of the second type occur in the upper compartment of the joint, also in two phases: the head glides forward with the disc to the articular tubercle (phase one) and then glides on the tubercle and at the same time rotates about the transverse axis (phase two). In lateral movements (third type) the articular head and disc of only one side leave the articular fossa and approach the articular tubercle, while the contralateral head remains in the articular fossa and rotates on the vertical axis.

THE SKULL AS A WHOLE

The external surface of the skull. Part of the external surface of the skull examined from the front (*norma facialis s. frontalis*) consists of the forehead superiorly and **two orbits**, with the **piriform aperture** of the nose between them; below the orbits and lateral to the opening of the nose is the anterior surface of the upper jaw with the upper teeth. The orbit is bounded laterally by the zygomatic bone, which articulates both with the frontal bone and with the maxilla. Below is attached the mobile lower jaw carrying the lower teeth on its superior border.

The orbits, or eyesockets (*orbitae*) contain the organ of vision and are cavities in the shape of somewhat rounded, four-sided pyramids. The base of the pyramid corresponds to the opening into **the orbit** (*aditus orbitae*), while **the apex** is directed backward and medially. **The medial orbital wall** (*paries medialis*) is formed by the frontal process of the maxilla, the lacrimal bone, the orbital plate of the ethmoid bone, and the body of the sphenoid bone to the front of the optical canal. The orbital surfaces of the zygomatic bone and greater wings of the sphenoid bone form **the lateral wall** (*paries lateralis*). **The su-**

perior wall (*parses superior*) or the roof of the orbit is formed by the orbital part of the frontal bone and lesser wings of the sphenoid bone; **the inferior wall** (*parses inferior*) or floor of the orbit is made up of the zygomatic bone and maxilla, and in the posterior portion by the orbital surface of the orbital process of the palatine bone. Two openings are seen at the apex of the pyramid: a large lateral opening, **the superior orbital fissure** (*fissura orbitalis superior*), and a smaller round medial opening, **the optic canal** (*canalis opticus*); by means of both openings the orbit communicates with the cranial cavity. In the corner formed by the lateral and inferior orbital walls is **the inferior orbital fissure** (*fissura orbitalis inferior*), which is bounded laterally by the greater wing of the sphenoid bone and medially by the edge of the maxilla; its posterior end leads into the pterygopalatine fossa and the anterior end into the infratemporal fossa. The fossa of **the lacrimal sac** (*fossa sacci lacrimalis*) is in the anterior part of the medial wall; it is bounded by the frontal process of the maxilla in front and by the lacrimal bone in the back and leads into **the nasolacrimal canal** (*canalis nasolacrimalis*). The other end of the lacrimal canal opens into the inferior nasal meatus. Further to the back, in the suture between the frontal and ethmoid bones, are two openings, **the anterior and posterior ethmoidal foramina** (*foramina ethmoidale anterius* and *posterius*), transmitting the anterior and posterior ethmoidal vessels and nerves. The anterior foramen leads into the cranial cavity, the posterior foramen into the nasal cavity.

The anterior bony **aperture of the nose** (*apertura piriformis nasi*) is below and partly between the orbits. Laterally and inferiorly it borders on the maxilla and superiorly and partly laterally on the free edges of the nasal bones. **The anterior nasal spine** (*spina nasalis anterior*) projects forward on the midline on the inferior margin of the piriform aperture. It is continuous posteriorly with the bony septum of the nose.

On examination of the skull from the side (*norma lateralis*), **the temporal lines** (*lineae temporales*) (*superior* and *inferior*), strike the eye first of all. Each line rises at the zygomatic process of the frontal bone, curves upward and to the back to intersect the coronary suture, and then passes over to the parietal bone on which it runs in the direction of the mastoid angle and, curving anteriorly, extends to the temporal bone. It marks the attachment of temporal muscle and fascia.

The following depressions merit special description because of their important topographical relations: (1) **the temporal fossa** (*fossa temporalis*); (2) **the infratemporal fossa** (*fossa infratemporalis*); and (3) **the pterygopalatine fossa** (*fossa pterygopalatina*).

The temporal fossa (*fossa temporalis*) is bounded superiorly and posteriorly by the temporal line, inferiorly by the infratemporal crest and the inferior margin of the zygomatic arch, and anteriorly by the zygomatic bone. Thus the frontal and parietal bones, the greater wing of the sphenoid bone, the squama of the temporal bone, and the zygomatic bone take part in its formation. The temporal fossa lodges the temporal muscle.

The infratemporal fossa (*fossa infratemporalis*) is continuous downward with the temporal fossa, and their borderline is the infratemporal crest of the greater wing of the sphenoid bone. The medial wall of the infratemporal fossa is formed by the lateral plate of the pterygoid process. The anterior wall is formed by the infratemporal surface of the maxilla and the lower part of the zygomatic bone. The superior wall is formed by the inferior surface of the greater wing of the sphenoid bone and the oval and spinous foramina in it, as well as by a small area of the squamous part of the temporal bone. The infratemporal fossa is covered partly on the external surface by the mandibular ramus. It communicates with the orbit through the inferior orbital fissure and with the pterygopalatine fossa through the pterygomaxillary fissure.

The pterygopalatine fossa (*fossa pterygopalatina*) is located between the back of the maxilla (anterior wall) and the front of the pterygoid process (posterior wall). Its medial wall is the vertical plate of the palatine bone isolating the pterygopalatine fossa from the cavity of the nose.

The following five openings are found in the pterygopalatine fosse: (1) a medial opening, **the sphenopalatine foramen** (*foramen sphenopalatinum*) leading into the nasal cavity and transmitting the sphenopalatine nerve and vessels; (2) a round posterosuperior opening (*foramen rotundum*) leading into the middle cranial fossa and transmitting the second branch of the trigeminal nerve which leaves the cranial cavity; (3) anterior opening, **the inferior orbital fissure** (*fissura orbitalis inferior*) leading into the orbit and transmitting the nerves and vessels; (4) an inferior opening, **the greater palatine canal** (*canalis palatinus major*) leading into the oral cavity; it is formed by the maxilla and the greater palatine sulcus of the palatine bone and is a funnel-shaped narrowing of the lower part of the pterygopalatine fossa and transmits the nerves and vessels leaving this fossa; (5) a posterior opening, **the pterygoid canal** (*canalis pterygoideus*) transmitting the vegetative nerves (n. canalis pterygoidei) and leading to the base of the skull.

On examination of the skull from above (*norma verticalis*), its roof and the sutures are seen: **the sagittal suture** (*sutura sagittalis*) between the medial border of the two parietal bones; **the coronal suture** (*sutura coronalis*) between the frontal and the two parietal bones; and **the lambdoid suture** (*sutura lambdae*) (from its resemblance to the Greek letter lambda) between the two parietal bones and the occipital bone.

The external surface of the base of the skull (*basis cranii externs*) is made up of the inferior surfaces of the visceral (without the mandible) and the cerebral cranium. It extends from the incisors anteriorly to **the superior nuchal line** (*linea nuchae superior*) posteriorly; its lateral border stretches from the infratemporal crest to the base of the mastoid process. Three parts are distinguished in the external surface of the base of the skull: anterior, middle, and posterior. The anterior part is formed of **the hard palate** (*palatum osseum*) and the alveolar arch of the maxilla; **a transverse suture** (*sutura transversa*) is seen in the posterior part of the hard palate at the junction of its components, the palatine process of the maxilla and the horizontal plate of the palatine bone. **A median palatine suture** (*sutura mediana*) joining the paired parts of the hard palate runs on the midline and its anterior end is continuous with the incisive foramen. In the posterior part of the hard palate, near to the alveolar arch, is **the greater palatine foramen** (*foramen palatinum majus*), the exit from the greater palatine canal; still further to the back, on the inferior surface of the pyramidal process, are the openings of the lesser palatine canals.

The middle part extends from the posterior edge of the hard palate to the anterior margin of foramen magnum. On the anterior border of this part are openings, choanae. They are isolated from each other by the vomer; they are bounded above by the body of the sphenoid bone, below by the horizontal plates of the palatine bones, and laterally by the medial plates of the pterygoid processes. In the posterior part of the base of the skull is **the jugular foramen** (*foramen jugulare*), formed by the jugular fossa of the temporal bone and the jugular notch of the occipital bone. The jugular foramen transmits the ninth, tenth, and eleventh cranial nerves, and the jugular vein originates here.

The upper surface of **the base of the skull** (*basis cranii interns*) can be examined only on a horizontal or sagittal section of the skull. The internal or superior surface of the base of the skull is separated into **three fossae**. **The anterior and middle fossae** lodge the cerebrum, while the **posterior fossa** lodges the cerebellum. The posterior edges of the lesser wings of the sphenoid bone are the borderline between the anterior and middle fossae, and the superior edge of the pyramids of the temporal bones is the borderline between the middle and posterior fossae.

The anterior cranial fossa (*fossa cranii anterior*) is formed by the orbital part of the frontal bone, the cribriform plate of the ethmoid bone, and the lesser wings of the sphenoid bone. It is distinguished by pronounced digitate impressions and cerebral ridges (*juga cerebralia*).

The middle cranial fossa (*fossa cranii media*) is located deeper than the anterior fossa. Its median part is formed by the sella turcica. The lateral parts are made up of the greater wings of the sphenoid bone, the squamous part of the temporal bones, and the anterior surface of their pyramids. The openings of the middle fossa are as follows: the optic canal, the superior orbital fissure, foramen rotundum, the oval foramen, and the spinous foramen.

The posterior cranial fossa (*fossa cranii posterior*) is the deepest and largest of the three fossae. Its components are the occipital bone, the posterior parts of the body of the sphenoid bone, the petrous part of the temporal bone, and the inferoposterior angle of the parietal bone. The following openings are found in it: foramen magnum, hypoglossal canal, jugular foramen, condylar canal (sometimes absent), mastoid foramen (occurring most regularly), *porus acusticus internus* (on the posterior surface of the pyramid).

A sagittal section of the skull. Examination of a cranial section made in the midsagittal plane or, better, in the direct vicinity of this plane (so as to leave the bony septum of the nose intact in one of the cranial halves) allows study of certain structures that are less visible on other bone specimens. In the region of the frontal bone, it can be seen that the external and internal plates of the compact substance separate and form an air-filled space, the frontal sinus (*sinus frontalis*), which opens on each side into the middle nasal meatus. **The sphenoidal sinus** (*sinus sphenoidalis*) is found in the body of the sphenoid bone. Vascular sulci, impressions of the vessels of the dura mater, are easily detectable on the inner surface of the parietal and frontal bones and the squama of the temporal bone.

A sagittal section shows the striking predominance of the size of the cranium lodging the brain over the size of the visceral cranium, in contrast to the opposite situation in the skull of animals. The bony foundation of the nasal cavity can also be examined more closely on a sagittal section.

The cavity of the nose (*cavum nasi*) is the initial part of the respiratory tract and lodges the organ of olfaction. The piriform aperture leads into the cavity in front, and the paired openings, **the choanae**, connect it with the cavity of the pharynx. **The bony septum of the nose** (*septum nasi osseum*) divides the nasal cavity into two halves, which are not quite symmetrical, in most cases the septum deviates to one of the sides from the sagittal plane. Each half of the nasal cavity has five walls: superior, inferior, lateral, medial, and posterior.

The lateral wall is the most complex in structure; it is formed of the following (from front to back) bones: the nasal bone, the nasal surface of the body and frontal process of the maxilla, the lacrimal bone, the labyrinth of the ethmoid bone, the inferior concha, the perpendicular plate of the palatine bone, and the medial plate of the pterygoid process of the sphenoid bone.

The medial wall, or **the osseous nasal septum** (*septum nasi osseum*) is formed by the perpendicular plate of the ethmoid bone and the vomer, above by the nasal spine of the frontal bone, posteriorly by the rostrum of the sphenoid bone, and inferiorly by the nasal crests of the maxilla and palatine bone.

The superior wall is made up of a small area of the frontal bone, the cribriform plate of the ethmoid bone, and partly the sphenoid bone.

The inferior wall, or *floor*, is formed by the palatine process of the maxilla and the horizontal plate of the palatine bone which make up **the bony hard palate** (*palatum osseum*); the opening of **the incisive canal** (*canalis incisivus*) is seen in its front part.

The posterior wall is very short and is found only in the superior part because the choanae are located below it. It is formed by the nasal surface of the body of the sphenoid bone with the paired aperture of the sphenoid sinus.

Three nasal conchae project downward into the nasal cavity from the lateral wall; they separate the **three nasal meatuses** - superior, middle, and inferior—from each other. **The superior nasal meatus** (*meatus nasi superior*) is between the superior and middle conchae of the ethmoid bone; it is half the length of the middle meatus and is found only in the posterior part of the nasal cavity; it communicates with the sphenoid sinus and sphenopalatine foramen and the posterior air cells of the ethmoid bone open into it. **The middle nasal meatus** (*meatus nasi medius*) passes between the middle and inferior conchae. The anterior and middle cells of the ethmoid bone and the maxillary sinus open into it and a projection of **the ethmoidal labyrinth** (*bullae ethmoidalis*) (a rudiment of an accessory concha) is seen lateral to the middle concha. To the front of and a little below the bulla is a **funnel-shaped passage** (*infundibulum ethmoidale*) by means of which the middle nasal meatus communicates with the anterior ethmoidal cells and the frontal sinus. These anatomical communications explain the spread of the inflammatory process to the frontal sinus (frontitis) in rhinitis. **The inferior nasal meatus** (*meatus nasi inferior*) is between the inferior nasal concha and the floor of the nasal cavity. The nasolacrimal canal opens into its anterior part; through this canal the tears flow into the nasal cavity. That is the reason the amount of nasal discharge increases when a person cries and, conversely, the eyes "water" in rhinitis. The space between the conchae and the nasal septum is known as the common meatus of the nose (*meatus nasi communis*).

The X-ray image of an adult skull. To understand the superimpositions of the skull bones on the radiograph, the following circumstances must be borne in mind: (1) the cranial bones and their parts formed of bone substance that is more compact than other bone substance (e.g. the petrous part of the temporal bone) produce shadows on the radiograph of greater density; (2) bones and their parts, which are made up of substance that is less compact (e.g. diploe), produce shadows of lesser density; (3) air cavities are seen as unshadowed areas; (4) shadows cast by parts of the skull bones that are nearer to the X-ray film are contrasted more sharply than the shadows of remote parts. The anterior parts of bones, therefore, are more sharply contrasted on an anteroposterior radiograph, and vice versa. An anteroposterior radiograph demonstrates dense shadows of the skull bones and teeth and clear areas at the site of the air sinuses. A lateral radiograph shows different parts of the cerebral and visceral skull. The bones of the vault are separated by sutures from which wave-like bands of low density corresponding to the canals of the diploic veins must be distinguished. These bands do not have the serrate character typical of the sutures and stretch in other directions. Knowledge of the X-ray picture of sutures and vascular canals helps to differentiate them from infractions of the skull. The "X-ray joint cavity" of the temporomandibular joint is demonstrated clearly as a curved band of low density corresponding to the intra-articular disc. X-ray examination is the only method of examination of the sella turcica in a living person. It is clearly demonstrated on a lateral radiograph. Since the sella lodges the cerebral hypophysis, the dimensions of this endocrine gland may be judged from the shape and size of the sella. Three types of sella turcica are distinguis-

hed: (1) foetal, a small sella in the form of a "prone" oval; (2) infantile, a large sella the shape of a "standing" oval; (3) adult, a large sella in the form of a "prone" oval. The process of pneumatization of the sphenoid sinus is also important. It begins from the age of 3 or 4 years in the anterior part of the body of the sphenoid bone and spreads from front to back with age with involvement of the dorsum sellae at old age.

AGE FEATURES OF THE SKULL

The skull of the newborn is characterized by a small visceral cranium as compared to the cerebral part. The **fontanelles** (*fonticuli*) are another characteristic feature of a newborn's skull.

The skull of a newborn infant carries traces of the three stages of ossification which are not yet completed. The fontanelles are remnants of the first, membranous stage; they occur at the intersection of sutures where remnants of non-ossified connective tissue are found. Their presence is of high functional importance because they permit the bones of the vault of the skull to be displaced considerably as the skull adapts to the shape and size of the birth canal during delivery. The following fontanelles are distinguished: (1) a **rhomboid anterior fontanelle** (*fonticulus anterior*) located on the midline at the intersection of four sutures (sagittal, frontal, and two halves of the coronary sutures); it closes in the second year of life; (2) a **triangular posterior fontanelle** (*fonticulus posterior*), at the posterior end of the sagittal suture between the two parietal bones in front and the squama of the occipital bone at the back; it closes in the second month after birth; (3) **paired lateral fontanelles**, two on each side; the anterior one is called **sphenoidal** (*fonticulus sphenoidalis*) and the posterior one is called **mastoid** (*fonticulus mastoideus*). The sphenoidal fontanelle is at the junction of the mastoid angle of the parietal bone, the greater wing of the sphenoid bone, and the squama of the temporal bone; it closes in the second or third month of life. The mastoid fontanelle is between the mastoid angle of the parietal bone, the base of the pyramid of the temporal bone, and the squama of the occipital bone. The sphenoidal and mastoid fontanelles are mostly found in premature infants; some full-term infants may also have no occipital (posterior) fontanelle.

Remnants of the second, cartilaginous stage of the development of the skull are the cartilaginous layers between some parts of the bones of the base which have not yet fused. As a result the number of these bones is greater in the newborn than in an adult. The air sinuses in the skull bones are still not developed. The different muscular tuberosities, crests, and lines are not pronounced because the muscles do not function yet and are therefore weakly developed. Weakness of the muscles due to absence of the masticating function causes weak development of the jaws: the alveolar processes are hardly formed and the mandible consists of two non-united halves. As a result the visceral cranium is less prominent in relation to the cerebral skull and is only one-eighth the size of the latter, whereas in an adult their ratio is 1 : 4.

Three periods are distinguished in the growth of the skull: the first period (the first 7 years) is characterized by intensive growth, mainly of the posterior part; the second (from the age of 7 to the beginning of puberty) is the period of relative rest; the third period, from the beginning of puberty (13-16 years of age) to the end of skeletal growth (20-23 years of age), is again one of intensive growth, but now mainly of the anterior part. The skull grows slowly later, too, which makes the sutures very important because they make it possible for the plane of the cranial bones to increase.

At mature age, the cranial sutures disappear (obliterate) because the syndesmoses between the bones of the vault are converted to synostosis. At old age, the bones of the skull are often thinner and lighter. As the result of the loss of teeth and the atrophy of the alveolar margins of the jaw bones, the face becomes shorter and the lower jaw protrudes forward, while the angle formed by the ramus and the body increases. The described age changes of the skull are demonstrated well by X-ray examination, which is important from the standpoint of diagnosis. The radiograph of the skull of the newborn shows, for instance, that: (1) some of the bones (the frontal, occipital, and the mandible) are not fused into a single whole; (2) pneumatization of the air bones is absent; (3) the spaces between the bones of the vault, in the region of the fontanelles in particular, are wide. An anteroposterior radiograph shows a clear space in place of the frontal suture, which separates the frontal bone into two parts, as well as evidence of incomplete union of both halves of the mandible. A posteroanterior radiograph demonstrates spaces between the interparietal bone and the inferior part of the squama of the occipital bone, and between the lateral parts and squama of this bone. A clear space corresponding to sphenoccipital synchondrosis is seen on a lateral radiograph. The age changes found on radiographs later are as follows. 1. Fusion of separate parts of bones to form a single whole, namely: (a) union of both halves of the mandible (1,2 years of age); (b) fusion of both halves of the frontal bone at the site of the frontal suture (2 years); (c) fusion of all parts of the occipital bone; (d)

synostosis between the body of the occipital bone and the sphenoid bone to form a single os basilare at the site of the spheno-occipital synchondrosis; with the development of this synostosis (between the ages of 18 and 20) growth of the base of the skull in length ceases. 2. Disappearance of the fontanelles and the formation of sutures with typical serrated contours (2-3 years of age). 3. Appearance and further development of pneumatization. X-ray examination is the only method for studying the developing air sinuses of the skull in a living person: (a) the frontal sinus is detectable on a radiograph at the end of the first year of life, after which it grows gradually. In some cases it is small and does not extend beyond the medial segment of the superciliary arch; in others it extends along the entire supraorbital margin, while in still others it may be absent completely; (b) the bony cells of the ethmoid bone are already discernible in the first years of life; (c) the maxillary sinus is demonstrated on the radiograph of the skull at birth as an elongated clear space the size of a pea. It reaches full development in the period of replacement of deciduous teeth by the permanent teeth and is distinguished by great variability; (d) the sphenoidal sinus is discussed above. 4. Replacement and loss of teeth. 5. Disappearance of the sutures and fusion of bones beginning at mature age.

SEX DIFFERENCES OF THE SKULL

The skull of a man is larger than the skull of a woman on the average; its capacity is greater than that of the female skull by approximately 10 %, which is determined by the sex difference in the body dimensions. The surface of the female skull is smoother because the roughnesses at the sites of muscle attachment are less pronounced. The superciliary arches are less prominent, the forehead more vertical, and the vertex flatter. In some cases, however, the sex signs on the skull are so indistinct that the sex of the individual cannot be determined from them, especially since in approximately 20 % of cases the capacity of the female skull is no less than the average capacity of the male. The smaller size of the female skull does not signify poorer development of the brain but corresponds to the smaller dimensions and proportions of the female body.

SHAPES OF THE SKULL

The shape of the skull is oval and the volume is from 1400 to 1600cm³. According to its capacity the following types of the skull can be distinguished:

- 1) **Microcephalic cranium**, when the brain is smaller than usually, its capacity is lower than 1300cm³. This type of cranium is characteristic for Australian and some African tribes.
- 2) **Mesocephalic cranium**, when the brain capacity is from 1300 cm³ to 1450cm³. This type of cranium is characteristic for Africans and Chinese.
- 3) **Megacephalic cranium**, when the brain capacity is more than 1450cm³. Such a skull is characteristic for European and Japanese.
- 4) **Hidrocephalic cranium** is a very voluminous skull, this type of skull is not normal, because of pathological condition of the brain.

PILLARS (BUTTRESSES) OF CRANIUM

The bony substance of the cranium is unequally distributed. Relatively thin (but mostly curved) flat bones provide the necessary strength to maintain cavities and protect their contents. However, in addition to housing the brain, the bones of the neurocranium (and processes from them) provide proximal attachment for the strong muscles of mastication that attach distally to the mandible; consequently, high traction forces occur across the nasal cavity and orbits that are sandwiched between. Thus thickened portions of the cranial bones form stronger **pillars or buttresses** that transmit forces, bypassing the orbits and nasal cavity. The main buttresses are the frontonasal buttress, extending from the region of the canine teeth between the nasal and the orbital cavities to the central frontal bone, and the zygomatic arch lateral orbital margin buttress from the region of the molars to the lateral frontal and temporal bones. Similar buttresses transmit forces received lateral to the foramen magnum from the vertebral column. Perhaps to compensate for the denser bone required for these buttresses, some areas of the cranium not as mechanically stressed become pneumatized (air-filled). The strong muscles of mastication extending between the neurocranium and mandible produce high traction forces across the nasal cavity and orbits. Thickened portions of the bones of the cranium form stronger pillars or buttresses that transmit forces, bypassing the orbits and nasal cavity. Occipital buttresses transmit forces received lateral to the foramen magnum from

the vertebral column. The strong muscles of mastication extending between the neurocranium and mandible produce high traction forces across the nasal cavity and orbits. Thickened portions of the bones of the cranium form stronger pillars or buttresses that transmit forces, bypassing the orbits and nasal cavity. Occipital buttresses transmit forces received lateral to the foramen magnum from the vertebral column.

DEVELOPMENT OF THE SKULL

The development of the skull as the skeleton of the head is determined by the organs of animal and vegetable life pointed out above.

The cerebral cranium develops in connection with the brain and organs of sense. Animals who have no brain also have no skull. The brain of the chordata (lancelot), which is in a rudimentary form, is enclosed in a membrane of connective tissue (membranous skull).

With the development of the brain in fish, a protective receptacle forms around it which in elasmobranch fish (sharks) acquires cartilaginous tissue (cartilaginous skull) and in bony fish, a bony tissue (the beginning of the formation of a bony skull).

When animals begin leaving the water for land (amphibians), the cartilaginous tissue is further replaced by bony tissue which is necessary for protection, support, and movement under conditions of terrestrial existence. In all the other classes of vertebrates, the connective and cartilaginous tissues are almost fully replaced by bony tissue, and a bony skull forms, marked by great strength. The development of the various skull bones is also determined by the same factors. This explains the relatively simple structure of the calvarial bones (e.g. the parietal bone) and the very complex structure of the base, e.g. the temporal bone which takes part in all functions of the skull and is a receptacle for the organ of hearing and equilibrium. The cerebral cranium of fish is made up of many bones which fuse with the gradual formation of the bony skull. The number of bones in terrestrial animals reduces, therefore, but their structure becomes more complex because some of the bones are the product of fusion of previously independent bone structures. In mammals the cerebral and visceral parts of the skull are closely joined. In man the neurocranium is very large and predominates over the visceral skull because the brain and organs of sense are most highly developed.

The visceral cranium develops from the material of the paired visceral arches contained in the lateral walls of the cranial part of the primary gut. In lower aquatic vertebrates, the visceral, or branchial, arches are located metamerically between the branchial clefts, through which water reaches the gills, the respiratory organs of the aquatic phylum.

The first visceral arch, bordering on the mouth, is called the **mandibular arch**. It is made up of two parts: an upper part connected with the cerebral cranium and called the palatoquadrate cartilage (palatoquadratum), and a lower part, Meckel's cartilage. Both parts serve as jaws. **The second visceral arch, the hyoid arch**, is also separated into two parts, the upper hyomandibular and the lower hyoid cartilages. The remaining visceral arches, beginning with the third, are called branchial arches proper: **the third visceral arch** is called the first branchial arch, the fourth visceral is called the second branchial arch, and so on.

As the animals start leaving water for land, the organs for respiration out of the water, the lungs, develop, whereas the gills lose their importance. In view of this, terrestrial vertebrates, man among others, have gills only in the embryonic period, and the cartilages of the visceral arches are used in the building of the visceral cranium. Thus, the motive forces of the evolution of the skeleton of the head are the change from aquatic to a terrestrial form of life (amphibians), adaptation to environmental conditions on land (all the other classes of vertebrates, mammals in particular), and the highest development of the brain and its tools, the organs of sense, as well as the appearance of the capacity of speech (man).

The principal line of evolution comprises the following:

- (1) replacement of the membranous and cartilaginous skull by a bony skull;
- (2) fusion of the bones of the cerebral cranium and a reduction in their number and simultaneous complication of their structure and development as mixed bones;
- (3) conversion of the visceral arch cartilages to bones of the visceral skull;
- (4) union of the cerebral skull with the visceral skull;
- (5) progressive development of the cerebral cranium and its predominance over the visceral skull which is most pronounced in man.

In reflection of this line of evolution, the human skull goes through three developmental stages in ontogenesis: (1) connective-tissue; (2) cartilaginous, and (3) bony. The change from the second to the third

stage, i.e. the formation of secondary bones in cartilage, occurs throughout man's life. Remnants of cartilaginous tissue persist between the bones as their cartilaginous joints (synchondroses) even in adults. The calvaria, which serves only for protection of the brain, develops directly from the membranous skull without going through the cartilage stage. The conversion of connective tissue to bony tissue also occurs here throughout man's life. The remnants of unossified connective tissue persist between the skull bones as fontanelles in the newborn and as sutures in children and adults (see below). The cerebral skull is continuous with the vertebral column and develops from the sclerotomes of the cephalic somites three or four pairs of which are laid down in the occipital region around the cranial end of the notochord.

The mesenchyme of the sclerotomes surrounds the cerebral vesicles and the developing organs of sense and forms a cartilaginous capsule (*cranium primordiale*) (early), which, in contrast to the vertebral column, remains unsegmented. The notochord penetrates the skull to the cerebral hypophysis (hypophysis cerebri), as a result of which the chordal and prechordal parts are distinguished in the cerebral skull according to their relationship to the notochord. Another pair of cartilages, cranial trabeculae (*trabeculae cranii*) is laid down in the prechordal part to the front of the hypophysis; the cartilages are connected to the anteriorly located cartilaginous nasal capsule enveloping the olfactory organ. Cartilaginous plates (*parachordalia*) flank the notochord on both sides. The trabeculae cranii fuse later with the parachordalia to form a single cartilaginous plate while the parachordalia fuse with the cartilaginous auditory capsules investing the germs of the organ of hearing. A recess is formed for the organ of vision between the nasal and auditory capsules on each side of the skull. Traces resembling the fusion of several vertebrae can sometimes be seen in the chordal part in the posterior region of the parachordal cartilages; in contrast, even minimum traces of segmentation cannot be detected in the prechordal part, especially since this part is located beyond the region of the cephalic somites. On the strength of this, the "vertebral theory of the skull" (according to which it is made up of vertebrae fused one to another) advanced first by Goethe and Oken is of importance only in reference to the chordal part of the skull. The absence of segmentation in the cerebral cranium is, of course, explained by its role as a protective accommodation for the brain, which must be absolutely immobile in all its parts.

In reflection of fusion to form larger structures in the process of evolution, the bones of the base of the cerebral cranium arise from separate, previously independent bony structures uniting to form mixed bones. This is discussed below in the description of the different bones of the base.

The cartilages of the visceral arches also undergo changes: the palatine part of the palatoquadratic cartilage (the first visceral or mandibular arch) contributes to the formation of the upper jaw. The lower jaw forms on Meckel's cartilage and articulates with the temporal bone by means of the temporomandibular joint. The remaining parts of the cartilages of the first visceral arch are converted to the auditory ossicles: the posterior part of Meckel's cartilage (articulare of lowest vertebrates) transforms into the malleus, while the palatoquadratum is converted to the incus. The upper part of the second visceral arch (hyoid arch) gives rise to the third auditory ossicle, the stirrup. All three auditory ossicles are not related to the visceral skull and are located in the tympanic cavity developing from the third branchial cleft (the spiracle of sharks) and forming the middle ear. The remaining part of the hyoid arch forms the basis for the hyoid bone (the lesser horns and part of the body) and the styloid processes of the temporal bone together with the ligamentum stylohyoideum.

The third visceral (first branchial) arch gives rise to the remaining parts of the body of the hyoid bone and its greater horns. The laryngeal cartilages which are not related to the skeleton are derived from the remaining branchial arches.

The bones of the human skull may, therefore, be separated into three groups according to their development.

1. Bones forming the cerebral capsule:

(a) those developing in connective tissue, the bones of the calvaria, namely the parietal and frontal bones, the squama of the occipital bone, the squamous and tympanic parts of the temporal bone;

(b) bones developing in cartilage, the bones of the base, namely the sphenoid bone (except for the medial plate of the pterygoid process), the body and lateral parts of the occipital bone, the petrous part of the temporal bone.

2. Bones developing in association with the nasal capsule:

(a) those developing in connective tissue, namely the lacrimal and nasal bones and the vomer;

(b) bones developing in cartilage, namely the ethmoid and the inferior turbinate bones.

3. Bones developing from the visceral arches:

(a) immobile (fixed) bones, namely the upper jaw, the palatine and zygomatic bones;

(b) mobile bones, namely the lower jaw, hyoid bone, and auditory ossicles.

The bones of almost all groups unite to form a single whole, and no movement occurs at their union; the bones of the third group (b), in contrast, are joined to the skull by articulations permitting movements: the lower jaw by a joint and the hyoid bone by ligaments. The bones of the second group delimit the nasal cavity and contribute to the formation of the orbits which contain the organs of vision; the jaw bones carry the dental apparatus. Bones developing from the brain capsule form the cerebral cranium, whereas the bones of the other two groups, except for the ethmoid bone, form the visceral cranium (bones of the face).

The configuration of the skull is mainly determined by the development of the brain and masticatory apparatus and the relationship between the brain capsule and the masticatory apparatus. The nasal cavity is at first located in front of the cerebral cavity in the skull. In mammals the cerebral cavity, gradually growing with the enlargement of the brain, approaches the nasal cavity; in man, the nasal cavity, together with the facial part of the skull, moves under the brain case not only because the brain is enlarged but also because the masticatory apparatus (the jaws and teeth) reduce. As a result the foramen magnum is displaced. In lowest mammals it is located laterally and faces posteriorly. In monkeys it is in an oblique position. In man it lies almost horizontally and faces downward. The vertical position of the body axis in man is also conducive to the displacement of the foramen magnum. The calvaria of the human skull is raised above the other parts of the skull as a consequence of the powerful development of the brain and is convex and rounded.

These features sharply distinguish the human skull from the skulls of not only the lowest mammals but also of anthropoid apes; the capacity of the cranial cavity is visual proof of this. Its volume is approximately 1500 cm³ in man, only 400-500 cm³ in anthropoid apes, and about 900 cm³ in the Pithecanthropus. The surface of the human cranium is even and smooth. In anthropoid male apes, in contrast, the cranial surface has sharply pronounced ridges consequent upon powerfully developed muscles of mastication. The skull of a very young anthropoid ape is more like the human skull in shape, although it is distinguished by greatly protruding jaws. Moreover, the superciliary elevations stand out noticeably in monkeys but are reduced in man. They still protrude markedly in fossil skulls (of Neanderthal man).

ABNORMALITIES OF THE SKULL

Ancephalia – the absence of the cerebral extremity of the trunk.

Craniostenosis – premature ossification of the fontanelles and of the sutures.

Scaphocephalia – earlier ossification of the sagittal suture, being a condition of appearance of a long and narrow skull.

Acrocephalia – closure of the coronary suture.

Plagiocephalia – premature closure of the sutures and fontanelles only from one side.

Microcephalia – the skull does not grow because the brain stops its development.

Cranioschisis – the absence of the vault of the skull.

Macrocephalia – great disproportional dimensions of the skull.

Persistence of the craniopharyngeal canal in the Turkish saddle (it contains remnants of the pharyngeal recess).

Common spinous and oval orifices.

Clinoidocarotid foramen (when the anterior clinoid process is connected with the body of the sphenoid bone).

Assimilation of the atlas by the occipital bone (occipitalization).

Presence of the paramastoidean process (when there is additional process in close relationship with the mastoidean one).

EXAMINATION OF THE SKULL ON ALIVE PERSON

The bones of the skull can be examined by X-rays methods, by somatoscopy and palpation. The supra-orbital borders of the frontal bones, the frontal and parietal tubers, can be seen by a simple inspection. The glabella, the supraorbital notch, the metopic suture, the superior temporal line, the external occipital protuberance, the supraciliary arch, the superior nuchal lines, the can be examined by palpation.

On the sphenoid bone can be palpated the temporal surface of the greater wings. By rhinoscopy can be examined the perpendicular plate of the ethmoid bone and the nasal conchae.

In children until two years age can be palpated the great fontanelle and the small one can be palpated until two - three months.

The bones of the viscerocranium also can be examined by somatoscopic method and by palpation. On the temporal bone can be palpated its squama, the mastoid process, the spina suprameatum, which is used as an reference point in trepanation of the mastoidean antrum, and initial portion of the external auditory meatus (the other part of the external auditory meatus can be examined by otoscopy).

At the level of the viscerocranium can be seen the cheek bones, caused by the zygomatic bones, the zygomatic arch, the head of the mandible, the mandibular angle, and the inferior margin of the body of the mandible.

By palpation also can be examined the nasal bones, the margins of the piriform aperture, the anterior nasal spine, the mental protuberance, the inferior margin of the mandible, the posterior margin of the mandibular branch, the angle of the mandible, and all the mentioned above formations.

The mandibular head can be palpated by a finger, which is introduced into the external acoustic meatus. Through the vestibulum of the mouth and the oral cavity proper can be palpated the alveolar arches and juga alveolares, the hard palate, the inferior margin of the mandible, the canine fosa, which in case of trigeminal neuralgy, in stomatological practice the infraorbital and mental orifices are used for the trigeminal anaesthesia.

CRANIOLOGY

The skull is one of the most important objects of anthropological research because of its proximity to such significant organs as the brain, the organs of sense, and the initial parts of the alimentary and respiratory systems. Fossil skulls, moreover, remain intact for long periods of time and serve as sources of information about races long extinct. The human skull generally takes one of three main shapes, although the shape of the individual skull may vary greatly. Skulls are classified according to the cephalic index (the ratio of the maximum diameter to the maximum length of the skull):

- (1) short or brachycephalic (cephalic index above 80);
- (2) average or mesocephalic (cephalic index of 79-76);
- (3) long or dolichocephalic (cephalic index less than 75).

An efficient method of examination of the skull shape, its dimensions and modifications of its configuration in anthropology and medicine is the craniometry, or establishment of the dimensions and diameters of the skull.

For this aim are used reference points, named craniometrical points. The craniometrical are divided into **median** (impar) and **lateral** (pair) points.

MEDIAN CRANIOMETRICAL POINTS:

1. **Gnathion** - the lowest point from of the chin.
 2. **The mental (symphysian) point** - the most prominent point of the mental eminence.
 3. **The inferior incisive point** (infradental) - situated on the alveolar arch, between the median incisors.
 4. **The superior incisive point** (prosthion) - which is situated on the alveolar process of the maxilla between medial incisors.
 5. **Nasospinal point** (spinal) - located on the anterior nasal spine.
 6. **Rhinion** - the inferior point of the suture between the both nasal bones.
 7. **Nasion** - the point of intersection of the fronto-nasal suture with the median line.
 8. **Glabella** - corresponds to the median area, which is situated between the superciliar arches.
 9. **Ofrion** - the point of intersection of the frontal minimal diameter with the median line; (the frontal minimal diameter is the list distance between the both temporal crests of the frontal bone).
 10. **Bregma** - the point of intersection of the coronarian suture with the sagittal one, and it corresponds to the vertex of the vault, or to the highest point of the skull.
 11. **Obelion** - is the point in which the sagittal suture is intersected by the line which unites to each other both parietal orifices.
 12. **Lambda** - the point which unite the sagittal suture with the lambdoid one.
 13. **Opistocranium** - the most posterior point of the sagittal plane of the skull.
 14. **Innion** - the point which corresponds to the external occipital protuberance.
-

15. **Opistion** – the median point of the posterior border of the foramen magnum.

16. **Basion** – the median point of the anterior border of the foramen magnum.

LATERAL CRANIOMETRICAL POINTS:

1. **The maxillofrontal point** – is situated at the level of the suture between the frontal process of the maxilla and the frontal bone.

2. **Dacrion** – is the point where the lacrimofacial and lacrimofrontal sutures meet each other.

3. **The malar point** – is the most prominent point of the zygomatic bone.

4. **Pterion** – is the point where the squama of the temporal bone, the parietal bone and the greater wing of the sphenoid bone and the frontal bone meet each other.

5. **The coronarian point** – is the most lateral point of the coronarian suture.

6. **Stefanion** – is the point where the coronary suture meets the superior temporal line.

7. **Gonion** – corresponds to the angle of the mandible.

8. **The auricular point** – is situated in the middle of the external auditory meatus.

9. **Eurion** – is the highest point of the parietal eminence.

10. **Asterion** – is the point where the temporal bone, the parietal one and the occipital bone meet each other.

The establishment of the variants of configuration of the skull can be appreciated taking into account the cranial indexes, the diameters, angles etc.

For the appreciation of the longitudinal and vertical cranial indexes it is necessary to measure the maximal anteroposterior and transversal diameters, and of the auricular height of the head.

➤ **The transversal diameter** – is the distance in centimeters between the most far-off points of the both parietal bones (or between the two eurions).

➤ **The anteroposterior diameter** – is the distance in centimeters between the glabella and the opistocranium.

➤ **The auricular height** – is the distance in centimeters between the vertex and the superior margin of the external auditory meatus on the vertical line that intersects perpendicularly the Frankfurt's horizontal line.

Frankfurt's horizontal line is the line which passes through the most inferior point of the infraorbital margin and through the superior margin of the external auditory meatus.

The longitudinal cranial index:

The *transversal diameter* (in cm) X 100 reported to the *anteroposterior diameter* (in cm). If the obtained value is 75 or less it is characteristic for the **dolichocephalic skull**; When the value is from 77,5 to 80,5 the skull is considered to be **mesocephalic**; The value of 83 and more is characteristic for the **brachycephalic skull**.

The **vertical cranial index** can be determined by the following account:

The auricular height of the head (in cm) X 100 reported to the anteroposterior diameter (in cm). If the obtained value is 75 and more it denotes a **hypsicephalic skull**; when the value is from 70 to 75 the skull is of a **middle height, or orthocephalic skull**; If the value is lower than 70 it characterizes the **platycephalic skull, or platicephalic skull**.

The facial index is determined:

Ofrioalveolar line (in cm) X 100 reported to the bizygomatic diameter, (the ofrioalveolar line is the distance between the ofrion and mental points).

The facial index has a value from 62 to 74. An index with a value more than this indicates an elongated face, and an index with a value less than this indicates a wide face.

Position of the facial cranium reported to the cerebral one may be characterized by **facial angle**. The facial angle represents the profile line (traced between the nasion and prosthion) and the horizontal line (traced through the inferior point of the profile line) measured in degrees. The facial angle lesser than 80° characterizes prognathias or prognathismus; a right facial angle is registered in orthognathismus; the most common values for the facial angle are values from 80° to 90°, and are characteristic for **mesognathismus** or **nasognathismus**. Two forms of prognathismus can be distinguished: 1. **total prognathismus**, when there is a protrusion both of the maxilla and of the mandible; 2. **inferior prognathismus**, when only the mandible protrudes anteriorly.

Capitolul II. MUSCLES OF THE NECK AND HEAD MUSCLES OF THE NECK

Topographically, the muscles of the neck are grouped as follows.

1. **Superficial muscles** (platysma, m. sternocleidomastoideus).
2. **Medial muscles**, or muscles of the hyoid bone: (a) muscles located above the hyoid bone (mm. mylohyoideus, digastricus, stylohyoideus, geniohyoideus); (b) muscles located below the hyoid bone (mm. sternohyoideus, sternothyroideus, thyrohyoideus, omohyoideus).
3. **Deep muscles**: (a) lateral, attached to the ribs (mm. scaleni anterior, medius and posterior); (c) prevertebral muscles (m. longus colli, m. longus capitis, m. rectus capitis anterior and lateralis).

SUPERFICIAL MUSCLES

1. **Platysma** is a subcutaneous muscle of the neck lying directly under the fascia as a thin sheet. It arises on the level of the second rib from the pectoral and deltoid fascia, runs upward over the clavicle, and then attaches to the edge of the mandible and the parotid and masseteric fascia and is partly continuous with the muscles of the mouth. A triangular space not covered with the muscle remains on the mid-line. Innervation: n. facialis.

Action. Pulling the skin of the neck, the muscle protects the subcutaneous veins from compression; it can also depress the angle of the mouth, which is important for facial expression.

2. **The sternocleidomastoid muscle** (*m. sternocleidomastoideus*) lies immediately under the platysma and is separated from it by the cervical fascia. It originates from the sternal manubrium and the sternal end of the clavicle. Both heads fuse proximally, and the muscle is attached to the mastoid process and Linea nuchae superior of the occipital bone. This muscle originated as part of the trapezius muscle, and it, therefore, has innervation in common with the trapezius (n. accessorius and C2).

Action. In unilateral contraction, the muscle flexes the cervical segment of the spine to the same side; the head is raised at the same time, and the face turned to the opposite side. In bilateral contraction, the muscles hold the head in a vertical position (head-holder); that is why the muscle itself and the place of its attachment (the mastoid process) are most developed in man, who walks erect. Bilateral contraction may also bend the cervical spine forward and simultaneously raise the face. When the head is fixed, the muscle can raise the chest in respiration (an accessory muscle of inspiration).

THE MIDDLE MUSCLES, OR MUSCLES OF THE HYOID BONE

MUSCLES LOCATED ABOVE THE HYOID BONE

These muscles of suprahyoid localization lie between the mandible and the hyoid bone.

1. **The mylohyoid muscle** (*m. mylohyoideus*) is a flat muscle with parallel fibres that arise from the mandibular mylohyoid line, run medially, and terminate on the tendinous line, raphe, stretching from the inner surface of the chin to the body of the hyoid bone on the midline along the border between both mylohyoid muscles. The posterior part of the muscle is attached to the body of the hyoid bone. Both mylohyoid muscles meet and form the floor of the mouth (*diaphragma oris*) which closes the bottom of the oral cavity.

2. **The digastric muscle** (*m. digastricus*) consists of two bellies connected by a round intermediate tendon. The whole muscle is shaped like an arch concave upwards. The anterior belly, venter anterior, located on the inferior surface of the oral diaphragm, arises in the digastric fossa of the mandible and runs back and laterally to the hyoid bone. The posterior belly, venter posterior, arises in the mastoid notch of the temporal bone and descends obliquely forward and medially, gradually narrowing, to the tendon by means of which it is joined to the anterior belly. The intermediate tendon is attached to the body and greater horn of the hyoid bone by a fascial loop.

3. **The stylohyoid muscle** (*m. stylohyoideus*) descends obliquely from the styloid process of the temporal bone to the body of the hyoid bone and embraces the intermediate tendon of the digastric muscle with two slips.

4. The geniohyoid muscle (*m. geniohyoideus*) lies above the mylohyoid muscle laterally of the raphe. It stretches from the spina mentalis of the mandible to the body of the hyoid bone. It is a derivative of the anterior longitudinal muscle of the trunk.

Action. All the four muscles described above raise the hyoid bone. When the bone is steadied, three muscles (mylohyoid, geniohyoid, and digastric) lower the mandible and thus are antagonists of the muscles of mastication. The hyoid bone is steadied by muscles lying below it (sternohyoid, omohyoid, etc.). Without this steadying the mandible cannot be lowered since the hyoid bone, which is lighter and more mobile than the mandible, will be raised. The same three muscles, the mylohyoid in particular, on contraction during swallowing raise the tongue and press it to the palate, as a result of which food is pushed into the pharynx.

Muscles situated above the hyoid bone are components of a complex apparatus including the mandible, hyoid bone, larynx, and trachea. This apparatus plays an important role in the act of articulate speech. Since articulate speech developed under the influence of labour as a means of communication between people, these muscles changed morphologically during the evolution of man. The changes were associated, on the one hand, with the reduced grasping activity of the jaws, which became the function of the hands, and, on the other hand, with the appearance of articulation movements. On comparing the skulls of a Neanderthal man with the skull of modern man, it can, therefore, be seen that the sites of attachment of the corresponding muscles have altered as follows: (a) the site of attachment of the posterior belly of the digastric muscle, the mastoid notch, was flat in the Neanderthal man but became deep in modern man; (b) the site of attachment of the anterior belly of this muscle, the digastric fossa, has moved medially in modern man; (c) the site of attachment of the mylohyoid muscle, the mylohyoid line, is more conspicuous and lower, as a result of which the oral diaphragm is situated lower in modern man; (d) the site of attachment of the geniohyoid muscle, the mental spine, was hardly present in the Neanderthal man and occurs only in modern man in whom the mental protuberance has also appeared. These changes in the bones occurred with the development of the muscles that take part in the act of articulate speech, inherent only to man.

MUSCLES LOCATED BELOW THE HYOID BONE

These muscles of infrahyoid localization are related to the system of the straight muscles of the neck and are situated on both sides of the midline directly under the skin, in front of the larynx, trachea, and thyroid gland. They stretch between the hyoid bone and the sternum. An exception is the omohyoid muscle which extends to the scapula and in origin is a muscle displaced from the trunk to the shoulder girdle (truncofugal).

1. The sternohyoid muscle (*m. sternohyoideus*) originates from the posterior surface of the sternal manubrium, sternoclavicular joint, and the sternal end on the clavicle, runs upward as a flat band, and joins its contralateral fellow. and attaches to the inferior edge of the hyoid bone. Between the medial borders of both sternohyoid muscles is a narrow vertical space closed by fascia; this is *the linea alba cervicalis*.

Action. Pulls the hyoid bone downward. Innervation: C1-3.

2. The sternothyroid muscle (*m. sternothyroideus*) lies under the sternohyoid muscle and is broader. It arises from the posterior surface of the manubrium sterni and the cartilage of the first rib; its medial border touches that of its fellow. It then ascends and attaches to the lateral surface of the thyroid cartilage (to its linea obliqua).

Action. Lowers the larynx. Innervation: C1-3.

3. The thyrohyoid muscle (*m. thyrohyoideus*) seems to be a continuation of the sternothyroid muscle from which it is separated by a tendinous intersection. It stretches from the oblique line of the thyroid cartilage to the body and greater horn of the hyoid bone.

Action. Pulls the larynx upwards when the hyoid bone is steadied. Innervation: C1-3.

4. The omohyoid muscle (*m. omohyoideus*) is a long narrow muscle consisting of two bellies joined almost at a right angle by an intermediate tendon. The inferior belly arises medially of the scapular notch, overlaps the spatium antescalenum under cover of sternocleidomastoid muscle where it joins the superior belly by means of the intermediate tendon; the superior belly rises almost perpendicular and is attached to the body of the hyoid bone.

Action. The omohyoid muscle lies in the thickness of the cervical fascia which it tightens on contraction and thus aids in dilation of the large veins situated under the fascia. It also pulls the hyoid bone downwards. Innervation: C1-3.

THE DEEP MUSCLES

LATERAL MUSCLES attached to the ribs, the scalene muscles

The three scalene muscles are altered intercostal muscles, which explain their attachment to the ribs).

1. **The scalenus anterior muscle** (*m. scalenus anterior*) arises from the anterior tubercles of the transverse processes of the third to sixth cervical vertebrae and is attached to the scalene tubercle of the first rib and the sulcus of the subclavian artery. Innervation: C 5-7.

2. **The scalenus medius muscle** (*m. scalenus medius*) is the largest scalene muscle. It originates from the anterior tubercles of the transverse processes of all the cervical vertebrae and is attached to the first rib behind the sulcus of the subclavian artery. Innervation: C2-8.

3. **The scalenus posterior muscle** (*m. scalenus posterior*) arises from the posterior tubercles of the three lower cervical vertebrae and is attached to the outer surface of the second rib. Innervation: C5-8.

Action. The scalene muscles raise the upper ribs and act as muscles of inspiration. When the ribs are steadied, bilateral contraction of the muscles accomplish forward flexion of the cervical spine; in unilateral contraction, they flex and rotate this segment of the spine to their side.

PREVERTEBRAL MUSCLES

1. **The longus cervicis muscle** (*m. longus colli*) is triangular and lies on the anterior surface of the spine, on both sides of it. Three portions are distinguished in it: (1) **vertical portion** corresponding to the base of the triangle stretching from the anterior surface of the bodies of the upper three thoracic and the lower three cervical vertebrae to the anterior surface of the bodies of the second, third, and fourth cervical vertebrae; (2) **superior oblique portion** stretching from the anterior tubercles of the transverse processes of the third, fourth, and fifth cervical vertebrae to the anterior tubercle of the atlas and the body of the axis; (3) **inferior oblique portion** arising from the bodies of the upper thoracic vertebrae and attached to the anterior tubercles of the transverse processes of the fifth and sixth cervical vertebrae. Innervation: C3-8.

2. **The longus capitis muscle** (*m. longus capitis*) overlaps the upper part of longus colli. It originates from the anterior tubercles of the transverse processes of the third, fourth, fifth, and sixth cervical vertebrae and is attached to the basilar part of the occipital bone. Innervation: C1-3.

3 **The rectus capitis anterior** and 4. **The rectus lateralis muscles** (*mm. recti capitis anterior and lateralis*) stretch from the lateral mass of the atlas (anterior muscle) and its transverse process (lateral muscle) to the occipital bone. Innervation: C1.

Action. Rectus capitis anterior and longus capitis flex the head forward. Longus colli flexes the cervical spine on bilateral contraction of all its fibres; in unilateral contraction the spine is flexed laterally; the oblique portions take part in rotation and flexion of the head to the side; rectus capitis lateral-is helps this muscle.

TOPOGRAPHY OF THE NECK

The neck (*collum*) is divided into four regions: posterior, lateral, the region of the sternocleidomastoid muscle, and the anterior region.

The posterior region (*regio colli posterior*) is behind the lateral border of the trapezius muscle and is the nape, or nucha.

The lateral region (*regio colli lateralis*) is behind the sternocleidomastoid muscle and is bounded in front by this muscle, below by the clavicle, and behind by the trapezius muscle.

The sternocleidomastoid region (*regio sternocleidomastoidea*) corresponds to the projection of this muscle.

The anterior region (*regio colli anterior*) is in front of the sternocleidomastoid muscle and is bounded posteriorly by this muscle, in front by the midline of the neck, and above by the border of the mandible. A small area behind the mandibular angle and in front of the mastoid process is called the fossa retromandibularis. It lodges the posterior part of the parotid gland, nerves, and vessels.

The anterior and lateral regions are divided into a number of triangles by the omohyoid muscle descending obliquely from front to back and crossing the sternocleidomastoid muscle.

The **omoclavicular triangle** or **subclavian triangle** (*trigonum omoclaviculare*) is distinguished in the lateral region of the neck; it is bounded by the sternocleidomastoid muscle in front, the inferior belly of the omohyoid muscle above, and the clavicle below.

Two triangles are distinguished in the anterior region of the neck: (1) the **fossa carotica**, or **carotis trigone** (*trigonum caroticum*) (transmitting the carotid artery), formed by the sternocleidomastoid muscle posteriorly, the posterior belly of the digastric muscle in front and above, and the superior belly of the omohyoid muscle in front and below and (2) the **submandibular trigone** (*trigonum submandibulare*) (lodging the submandibular gland), formed by the inferior border of the mandible above and the two bellies of the digastric muscle.

Triangular slits or spaces form between the scalene muscles; they transmit nerves and vessels of the upper limb.

1. Between the anterior and middle scalene muscles is **spatium interscalenum**, bounded by the first rib below (it transmits the subclavian artery and the brachial plexus).

2. In front of the anterior scalene muscle is **spatium antescalenum** covered in front by the sternothyroid and sternohyoid muscles (it transmits the subclavian vein, the suprascapular artery, and the omohyoid muscle).

FASCIAE OF THE NECK

The **fasciae of the neck** reflect the topography of organs located in the cervical region. That is why textbooks on topographic anatomy describe these fasciae after Shevkunenko; this is most convenient for surgical purposes. **Five fascial layers** are distinguished.

1. The **first fascia**, or the **superficial cervical fascia** (*fascia colli superficialis*) is part of the common superficial (subcutaneous) fascia of the body and is continuous with the fasciae of the neighbouring areas. It is distinguished from the superficial fascia of the other parts of the body in that it contains the platysma muscle for which it is the perimysium.

2. The **second fascia**, or the **superficial layer of the cervical fascia proper** (*lamina superficialis fasciae colli propriae*) encloses the whole neck like a collar and covers the suprahyoid and infrahyoid group of muscles, the salivary glands, the vessels, and the nerves. It is attached above to the mandible and the mastoid process and is continuous on the face with the parotid and masseteric fasciae which cover the parotid gland and the masseter muscle. Below, the superficial layer is attached to the anterior border of the manubrium sterni and the clavicle. In front, on the midline, it fuses with the deep layer of the cervical fascia proper to form the **linea alba cervicalis** (2-3 mm in width). On each side of the neck, the superficial layer passes from the linea alba posteriorly to the spinous processes of the cervical vertebrae. On reaching the *sternocleidomastoid* and the *trapezius* muscles it separates into two lamellae, encloses the muscles and again fuses, thus forming fascial sheaths for each of these muscles separately. Where the superficial layer of the cervical fascia proper passes over the transverse processes, it is attached to them for which purpose it gives off a fascial branch in the form of a frontally situated lamina separating the entire fascial space of the neck into two parts, anterior and posterior (Pirogoff). As a result, suppurative processes develop in both parts of the fascial space independently of one another.

3. The **third fascia**, or the **deep layer of the cervical fascia proper** (*lamina profunda fasciae colli propriae*) is manifest only in the middle part of the neck behind the sternocleidomastoid muscle where it is stretched like a trapezium over a triangular space bounded above by the hyoid bone, on both sides by the omohyoid muscles, and below by the clavicles and the sternum. Since the deep layer of the cervical fascia proper is attached below to the posterior border of the manubrium sterni and the clavicles, while the superficial layer is attached to the anterior border of these bones, a narrow space is left between these layers; this is **spatium interaponeuroticum suprasternale** containing loose fatty tissue and the superficial veins of the neck, the jugular venous arch (*arcus venosus juguli*), injury to which is fraught with danger. Laterally this space communicates with **recessus lateralis**, a blind space behind the inferior end of the sternocleidomastoid muscle into which pus may penetrate. The deep layer, separating and again fusing, forms fascial sheaths for the infrahyoid muscles (the sternohyoid, sternothyroid, and thyrohyoid muscles). It unites these muscles to form a thick connective-tissue muscular expansion, like their aponeurosis (*aponeurosis omoclavicularis*), which tenses when the omohyoid muscles contract and thus facilitates the flow of blood in the cervical veins perforating it and fusing with it. This tension and the triangular shape suggested the image-bearing name of the aponeurosis, the "cervical sail".

4. The fourth fascia, or the endocervical fascia (*fascia endocervicalis*) encloses the organs located in the neck (larynx, trachea, thyroid gland, pharynx, oesophagus, and the large vessels). It consists of two layers, a **visceral layer** which invests each of these organs and forms a capsule for them and a **parietal layer** which encloses all these organs in the aggregate and forms a sheath for the important vessels, the common carotid artery and the internal jugular vein.

The space between the parietal and visceral layers of the endocervical fascia lies in front of the viscera and is therefore called **previsceral space** (*spatium previscerale*), that in front of the trachea, in particular, is called **pretracheal space** (*spatium pretracheale*). The latter contains, in addition to fatty tissue and lymph nodes, the isthmus of the thyroid gland and blood vessels (arteria thyroidea ima and plexus thyroideus impar) which can be injured during tracheotomy. Spatium pretracheale extends into the anterior mediastinum. Enclosing the cervical viscera, the parietal layer is in front and to the sides of them, but at the same time it is behind the infrahyoid group of muscles (the sternohyoid, sternothyroid, thyrohyoid, and omohyoid muscles).

5. The fifth, prevertebral fascia (*fascia prevertebralis*) covers anteriorly the prevertebral and scalene muscles stretching on the spine, and by fusing with the transverse processes of the vertebrae forms sheaths for these muscles. Above, the prevertebral fascia arises from the base of the skull behind the pharynx, descends through the entire length of the neck, and enters the posterior mediastinum where it merges with the endothoracic fascia.

Between the fourth and fifth fasciae, behind the pharynx and oesophagus, is a narrow space filled with loose fatty tissue; this is **retrovisceral space** (*spatium retroviscerale*), which is continuous downwards with the posterior mediastinum.

The five fasciae described differ in origin: some are reduced muscles (the first fascia is the perimysium of platysma muscle, the third fascia is the reduced cleidohyoideus muscle of which only the aponeurosis remains); others are the products of thickening of the fatty tissue surrounding the organs (the parietal and visceral layers of the fourth fascia), and still others originate in a manner common to fasciae (the second and fifth fasciae).

According to the Paris Nomina Anatomica (PNA), all fasciae of the neck are embraced under the term **fascia cervicalis**, which is divided into **three layers** as follows.

1. The superficial layer (fascia) (*lamina superficialis*) corresponding to the first fascia, fascia colli superficialis.

2. The pretracheal layer (fascia) (*lamina pretrachealis*) covering the salivary glands, muscles, and other structures located in front of the trachea, hence its name. It corresponds to the second and third fasciae (after Shevkunenko), i.e. the superficial and deep layers of fascia colli propriae.

3. The prevertebral layer (fascia) (*lamina prevertebralis*) corresponding to the fifth fascia, i. e. fascia prevertebralis (after Shevkunenko).

The fourth fascia (fascia endocervicalis) is omitted in PNA.

The cervical fasciae are firmly connected with the walls of the veins by means of connective-tissue strands which prevent them from collapsing in injuries. Damage to even the small cervical veins is therefore fraught with danger because due to the closeness of the right atrium and the suction action of the chest air can enter the blood flow, i.e. air embolism can occur.

THE MUSCLES OF THE HEAD

With the exception of the striated muscles of the sight and hearing organs and the upper part of the digestive system (described in respective sections of this volume), all the muscles of the head can be divided into the following two groups:

1. Muscles of mastication: derivatives of the first visceral (mandibular) arch. Innervation: nervus trigeminus.

2. Muscles of facial expression: derivatives of the second visceral (hyoid) arch. Innervation: nervus facialis.

MUSCLES OF MASTICATION

The four muscles of mastication on each side are related genetically (they originate from a single visceral arch, the mandibular arch), morphologically (they are all attached to the mandible which they move

when they contract), and functionally (they accomplish the chewing movements of the mandible, which determines their location).

1. **The masseter muscle** (*m. masseter*) is thick and quadrangular. It arises from the inferior border of the zygoma and the zygomatic arch and is attached to the masseteric tuberosity and the external surface of the mandibular ramus.

2. **The temporal muscle** (*m. temporalis*) is wide at its origin and occupies the whole temporal fossa of the skull up to the temporal line. The muscle fibres converge like a fan and form a strong tendon which passes under the zygomatic arch and is attached to the coronoid process of the mandible.

3. **The lateral pterygoid muscle** (*m. pterygoideus laterally*) arises from the inferior surface of the greater wing of the sphenoid bone and the pterygoid process. It is directed almost horizontally backward and laterally and is attached to the neck of the mandibular condylar process and to the capsule and articular disk of the temporomandibular joint.

4. **The medial pterygoid muscle** (*m. pterygoideus medialis*) arises in the pterygoid fossa of the pterygoid process, passes downward and laterally, and attaches to the medial surface of the mandibular angle, symmetrically with the masseter muscle, at the pterygoid tuberosity.

Action. The temporal, masseter, and medial pterygoid muscles pull the mandible to the maxilla when the mouth is open and thus close the mouth. On simultaneous contraction of both lateral pterygoid muscles the mandible protrudes forward. Movement in the opposite direction is accomplished by the posterior fibres of the temporal muscle which pass almost horizontally forward. Unilateral contraction of the lateral pterygoid muscle displaces the mandible to the contralateral side of the mouth. The temporal muscle is associated with articulate speech; it sets the mandible in a definite position when a person speaks.

MUSCLES OF FACIAL EXPRESSION

Part of the visceral musculature of the head, which was formerly related to the head and neck viscera, gradually transformed into the skin musculature of the neck and from this musculature, by differentiation into separate thin bundles, to the muscles of facial expression. This pattern of development explains the close relation of these muscles to the skin for whose movements they are responsible. This also explains the other specific features of their structure and function.

For instance, the muscles of facial expression, as distinct from the skeletal muscles, are not doubly attached to the bones but always interlace at one or both ends with the skin or mucous membrane. As a result **they are devoid of fasciae** and move the skin upon contraction. When they relax, the skin returns to its former state due to its elasticity. The role of antagonists is much less important here than in the case of the skeletal muscles.

The muscles of facial expression are small, thin muscle bundles grouped around the natural orifices (the mouth, nose, palpebral fissure, and ear). These muscles take part in closing or widening the orifices.

Sphincters are usually arranged **annularly** around the orifices they close, while the dilators, which widen the orifices, are arranged **radially**. By changing the shape of the orifices and moving the skin with the formation of various folds, the muscles lend the face various emotional expressions. In addition to expressing feeling, which is their main function, these muscles take part in speech, mastication, and so on.

In the human being, the shortening of the jaws and the use of the lips in articulate speech led to finer development of the muscles of facial expression around the mouth. The ear musculature, in contrast, which is well developed in animals, reduced in the human and survives as rudimentary muscles.

MUSCLES OF THE SCALP

1. Almost the whole skull cap is covered by a thin **epicranial muscle** (*m. epicranius*), which has a wide tendinous part, the **epicranial aponeurosis** (*galea aponeurotica*) (*aponeurosis epicranialis*), and a muscular part separating into three bellies: (1) **the anterior, or frontal belly** (*venter frontalis*) arises from the skin of the eyebrows and interlaces with the aponeurosis in front; (2) **the posterior, or occipital belly** (*venter occipitalis*) originates from the superior nuchal line and interlaces with the aponeurosis posteriorly, and (3) **the lateral belly** separates into **three small muscles** approaching the auricle anteriorly (*m. auricularis anterior*), superiorly (*m. auricularis superior*), and posteriorly (*m. auricularis posterior*). The three auricular muscles interlace with the aponeurosis laterally. The galea aponeurotica invests the middle part of the dome of the skull to form the central part of the epicranial muscle.

Action. Loosely connected to the periosteum of the skull bones, the epicranial aponeurosis fuses closely with the skin, which can, therefore, move with it during contraction of the frontal and occipital bellies. When the epicranial aponeurosis is steadied by the occipital belly of the muscle the frontal belly raises the eyebrow (arches it) and wrinkles the skin of the forehead transversely.

The auricular muscles (the lateral belly of the epicranial muscle) are very poorly developed in most humans and have no function. The remnants of the human auricular musculature are a classical example of rudimentary organs. Persons who can literally move their ears, as in the figurative expression "to prick up one's ears", are very rare.'

MUSCLES SURROUNDING THE EYES

2. The procerus muscle (*m. procerus*) arises from the bones of the ridge of the nose and the aponeurosis of the nasal muscle and is inserted into the skin of the glabella where it interlaces with the frontal belly of the epicranium. By drawing down the skin of this region, it causes transverse wrinkling of the skin above the bridge of the nose.

3. The orbicularis oculi muscle (*m. orbicularis oculi*) surrounds the eyelids; its wide peripheral **orbital part** (*pars orbitalis*) is on the bony margin of the orbit, while the central **palpebral part** (*pars palpebralis*) is on the eyelids. A small third, **lacrimal part** (*pars lacrimalis*) can also be distinguished. It is a part of the pars palpebralis, which arises from the wall of the lacrimal sac and, by dilating the sac, contributes to the absorption of the tears through the lacrimal canaliculi. The palpebral part closes the lids gently, while strong contraction of the orbital part closes them tightly. Isolated contraction of the upper fibres of this part draws the skin of the forehead and the eyebrow downward; as a result the eyebrow is straightened out, and the transverse wrinkles on the forehead are smoothed out. In this respect it is an antagonist of the venter frontalis.

Still another small part of the orbicular muscle of the eye lodged under the pars orbitalis can be distinguished; this is **5. the corrugator muscle of the eyebrow** (*m. corrugator supercillii*), which draws the eyebrows toward each other and causes the formation of vertical wrinkles in the space between the eyebrows above the bridge of the nose. In addition to the vertical wrinkles, short transverse wrinkles often form above the bridge of the nose in the middle one third of the forehead as the result of simultaneous action by the venter frontalis. This position of the eyebrows indicates suffering, pain, or other strong emotions.

MUSCLES AROUND THE MOUTH

4. The levator labii superioris muscle (*m. levator labii superioris*) arises as a quadrangular plate from the infraorbital border of the maxilla; its slips converge and most of them are inserted into the skin of the nasolabial fold. It gives off a slip to the ala of the nose, and is classified separately as **the levator muscle of the upper lip** and **the ala of the nose** (*m. levator labii superioris alaeque nasi*). When contracted, the muscle raises the upper lip and thus makes the nasolabial sulcus deeper; it pulls the ala of the nose upward and dilates the nares.

5. The zygomatic minor muscle (*m. zygomaticus minor*) arises from the zygomatic bone and is inserted into the nasolabial fold which it deepens during contraction.

6. The zygomaticus major muscle (*m. zygomaticus major*) passes from the lateral surface of the zygomatic bone to the angle of the mouth and partly to the upper lip. It pulls the angle of the mouth upward and laterally, as a result of which the nasolabial sulcus becomes much deeper. The action of the zygomaticus major muscle is perhaps the most important in the expression of laughter on the face.

7. The risorius muscle (*m. risorius*) is another muscle important in the expression of laughter (L risus laughter). This small transverse slip arises from the parotid and masseteric fasciae and passes to the angle of the mouth. It is often absent. It stretches the mouth in laughing; in some persons it is attached to the skin of the cheeks and when it contracts, a small depression (dimple) forms laterally to the angle of the mouth.

8. The depressor anguli oris muscle (*m. depressor anguli oris*) is a triangular muscular plate. Its base arises from the inferior border of the mandible laterally of the mental tubercle. Its apex is inserted into the skin of the angle of the mouth and the upper lip. It pulls down the angle of the mouth and straightens out the nasolabial fold. Depression of the angles of the mouth produces the expression of grief.

9. **The levator anguli oris muscle** (*m. levator anguli oris*) is quadrangular and is situated under the levator labii superioris and zygomaticus. It arises from the canine fossa (and was formerly called *m. caninus*) below the infra-orbital foramen and is inserted into the angle of the mouth. It raises the angle of the mouth.

10. **The depressor labii inferioris muscle** (*m. depressor labii inferioris*) lies directly on the bone. It arises on the border of the mandible where it is a continuation of the platysma muscle, passes obliquely, and is inserted into the skin of the whole lower lip including its border. It pulls the lip down and a little laterally, as occurs, for example, in expressions of disgust.

11. **The mentalis muscle** (*m. mentalis*) is one of the strongest in the group of muscles of facial expression. It arises from the juga alveolaria of the lower incisors and the canine tooth and is inserted into the skin of the chin. It raises the skin of the chin (with the formation of small dimples in it) and pushes the lower lip upward, pressing it to the upper lip.

12. **The buccinator muscle** (*m. buccinator*) is a wide quadrangular muscle forming the lateral wall of the oral cavity and directly adjoining the mucous membrane. It arises from the maxillary alveolar process along a distance from the first molar posteriorly to the pterygoid process and then descends along the **pterygomandibular raphe** (a fibrous strand stretching between the hamulus pterygoideus and the crista buccinatoria mandibulae) to the mandible, where it passes on **the crista buccinatoria** and the lateral wall of the sockets of the premolars and molars forward to the angle of the mouth. At the level of the second maxillary molar the muscle is pierced by **the parotid duct** (*ductus parotideus*). The external surface of the buccinator muscle is covered by *the buccopharyngeal fascia* on which there is a pad of fat. The action of this muscle consists in the expulsion of the contents of the vestibule of the mouth, as, for example, the expulsion of air when playing a trumpet; hence the name of the muscle, buccinator (L trumpeter).

13. **The orbicularis oris muscle** (*m. orbicularis oris*) lies in the thickness of the lips around the rima oris. In both the upper and lower lips the fibres of the muscle pass from the angle of the mouth to the midline and interlace with the contralateral fibres. Numerous slips from the adjoining muscles join them. Contraction of the peripheral part of the orbicularis oris purses the lips and pushes them forward, as in kissing. During contraction of the part under the vermilion border, the lips are drawn tightly together and inverted; as a result the vermilion border is hidden. The orbicularis oris, which is arranged around the mouth, functions as a **sphincter**, i.e. a muscle that closes the mouth. This action is antagonistic to the action of the radial muscles of the mouth, i.e. muscles which radiate from it and open it (*mm. levator labii superioris* and *levator anguli oris*, *depressor labii inferioris* and *depressor anguli oris*, etc).

MUSCLES SURROUNDING THE NOSE

14. **The nasal muscle** (*m. nasalis*) is poorly developed and partly covered by the levator muscle of the upper lip. It arises on the maxilla from the wall of the socket of the maxillary lateral incisor and immediately separates into **three parts**: *pars transversa*, *pars alaris*, and *m. depressor septi (nasi)*. The most laterally located transverse part (*pars transversa*) ascends to the bridge of the nose in the nasal cartilage and is continuous here with an aponeurotic expansion which joins the contralateral expansion; contraction of the *pars transversa* compresses the cartilaginous part of the nose. **The alar part of the nasal muscle** (*pars alaris*) forms the short segment of the nasal muscle proper passing to the ala; its contraction draws the ala downward. **The medial part** of the muscle, which passes to the cartilaginous part of the nasal septum and depresses it when contracted, is called **the depressor septi muscle** (*m. depressor septi nasi*).

FASCIAE OF THE HEAD

The epicranial aponeurosis covering the dome of the skull becomes very thin on the lateral parts of the dome to become a loosely fibrous lamina, under which is a **strong temporal fascia** (*fascia temporalis*) shining like a tendon that covers the temporal muscle and arises above from the temporal line. Below the temporal line it attaches to the zygomatic arch and separates into two layers: a superficial layer, which fuses with the external surface of the arch, and a deep layer, which fuses with the internal surface of the arch. The space between the two layers is filled with fatty tissue. The temporal fascia closes the cranial fossa temporalis in the osteo-fibrous receptacle that lodges the temporal muscle with fatty tissue. The masseter muscle is covered by **the masseteric fascia** (*fascia masseterica*), which invests the muscle and

attaches to the zygomatic arch above, to the mandibular border below, and to the mandibular ramus posteriorly and anteriorly. Posteriorly and partly externally, this fascia is connected with the **parotid fascia** (*fascia parotideae*), which forms a capsule around the gland. Fasciae do not exist on the face because the muscles of the facial expression lie directly under the skin. The only exception is the buccinator muscle; its posterior section is covered with the thick **buccopharyngeal fascia** (*fascia buccopharyngea*), which becomes loose anteriorly and blends with the fatty tissue of the cheek, fuses posteriorly with the pterygo-mandibular raphe, and is continuous with the connective-tissue covering of the pharyngeal muscles.

APPLIED ANATOMY

To define some wrinkles of the mimicry, the muscles of facial expression interfere in the modeling of the physiognomy. For the very beginning the wrinkles are temporary but in course of time they become permanent because the skin loses its elasticity and the muscular fibers shorten.

The physiognomy is the static appearance, in resting, of the face. The **mimicry** is determined by the contraction of the muscles of facial expression, but the physiognomy is more complex. The **physiognomy** is determined by the number of consisting elements such as:

- particular configuration of the head;
- properties of the skin;
- abundance or absence of the fat subcutaneous tissue and its distribution;
- development of the muscles of mastication which have a superficial location;
- development of the cutaneous muscles especially of grooves which are determined by them;
- shape of the nose;
- degree of opening of the palpebral fissure (the space between the two eyelids);
- the peculiar modus of utilization of the muscles of facial expression, is dependent on the psychological status and nervous system of a person.

Some common linearly depressions (inherited or formed due to the contraction of muscles of facial expression) have a great importance for physiognomy and are called **grooves**, but not wrinkles.

THE MAIN GROOVES OF THE FACE

1. **The nasolabial groove** is the most common and it is inherited. It is slightly curved and begins from the nasal wing having a downward oblique direction toward the angle of the mouth.
2. **The mentolabial groove** it has a transverse direction and separates the lower lip from the chin.
3. **The jugal or mentomalar groove** unites the zygomatic bone with the chin.
4. **The submental groove** separates the chin from the eventually "doubled chin".
5. **The superior palpebral groove** separates the palpebral portion of the upper eyelid from the orbital one.
6. **The inferior palpebral groove** separates the palpebral portion of the lower eyelid from the orbital one.
7. The radial wrinkles located on the lateral angle of the eye.

The physiognomy can be modified in a characteristic manner in different diseases such as typhus, tuberculosis, peritonitis (*facies hypocratica*). Knowledge of these facts is important in medical practice. The intellectual states are expressed better in the forehead and eyes regions, while the emotional states are more expressed in the oral region, (mouth region).

• **In laugh** the mouth commissures are traced upward and laterally (contraction of the zygomatic major muscle); the oral fissure is enlarged, and the upper teeth can be well seen. The nasolabial grooves become S-shaped. The eyelids approach each other due to the contraction of the orbicular muscle of the eye and in the lateral angle of the eyes appear some radial wrinkles.

• **In crying** the labial commissures are traced downward (contraction of the depressor of the lower lip muscle), the upper lip raises (contraction of the levators muscles of the upper lip and angle of the mouth), the oral fissure is curved downward. Contractions of the levators muscles assure to the nasolabial groove a medial concavity. The palpebral fissure narrows (contraction of the orbicular oculi muscle) and the eyebrow is depressed (contraction of the corrugator muscle of the eyebrow).

• **In high concentration of attention** a transverse wrinkle forms on the forehead (contraction of the occipitofrontal muscle) and the palpebral fissure widely opens.

• **Thinking** is expressed by the narrowing of the palpebral fissures and depression of the eyebrows.

• **The contempt** is expressed by the depression of the angle of the mouth and by the stretching of the nasolabial groove that has a straight-line shape (contraction of the depressor of the lower lip muscle).

MUSCLE DEVELOPMENT

The group of cervical muscles includes muscles of different origin.

1. Derivatives of the visceral arches: (a) derivatives of the first visceral arch: *m. mylohyoideus*, venter anterior *m. digastrici*. Innervation: *n. trigeminus*; (b) derivatives of the second visceral arch: *m. stylohyoideus*, venter posterior *m. digastrici*, *platysma*. Innervation: *n. facialis*; (c) derivatives of the branchial arches: *m. sternocleidomastoideus*. Innervation: *n. accessorius* and *plexus cervicalis*.

2. Autochthonous muscles of the neck: (a) anterior muscles: *m. sternohyoideus*, *m. sternothyroideus*, *m. thyrohyoideus*, and *m. omohyoideus*, as well as *m. geniohyoideus*; (b) lateral muscles: *mm. scaleni anterior, medius* and *posteriori* (c) prevertebral muscles: *m. longus colli*, *m. longus capitis* and *m. rectus capitis anterior*. The autochthonous cervical muscles are rudiments of the ventral musculature on whose distribution two important circumstances had an effect: reduction of the ribs and reduction of the body cavity. As a result some of the autochthonous muscles of the neck disappeared in man, and only the scalene, vertebral, and geniohyoid muscles remained. According to their development, they are innervated by the anterior branches of the cervical spinal nerves. The muscles located below the hyoid bone are connected with the sublingual apparatus and innervated from the *ansa cervicalis*.

The muscles of the trunk develop from the dorsal part of the mesoderm found on the sides of the notochord and neural tube; this part of the mesoderm is divided into primary segments, or somites. After the sclerotome, which gives rise to the spinal column, is separated, the remaining laterodorsal part of the somite forms the myotome whose cells (myoblasts) become elongated in the longitudinal direction and transform later into symplasts of the muscle fibres. Some myoblasts differentiate into special cells, myosatellites, located next to the symplasts. The myotomes grow ventrally and are divided into the dorsal and ventral parts. The dorsal part gives rise to the dorsal musculature (on the back of the trunk), the ventral part to the ventral musculature on the anterior and lateral surfaces of the trunk.

Branches of the corresponding spinal nerve (neuromere) penetrate each myotome (myomere). In accordance with the division of the myotome into two parts, the nerve gives off two branches, a dorsal (posterior) branch, which enters the dorsal part of the myotome, and a ventral (anterior) branch, which enters the ventral part. All muscles derived from one and the same myotome are supplied with one and the same spinal nerve. Adjacent myotomes may merge, but each of the merged myotomes retains the nerve related to it. Muscles originating from several myotomes (e.g. the *rectus abdominis* muscle) are therefore innervated by more than one nerve. The myotomes on each side are primarily separated one from the other by transverse connective-tissue septa, myosepta. This segmented arrangement of the muscles of the trunk remains throughout life in lower animals. The more elaborate differentiation of the muscular mass in higher vertebrates and man smooths away the segmentation considerably, though traces of it remain both in the dorsal (the short muscles between the vertebrae) and in the ventral musculature (the intercostal muscles and the *rectus abdominis* muscle). Some of the muscles remain in the place of their formation on the trunk and form the local, native, autochthonous musculature (*Gk. autos self, chthon earth*). Others move from the trunk to the limbs in the process of development. These muscles are called truncifugal (*trunc + L. fugeo fleo*). Finally, a third group of muscles arises on the limbs and migrates to the trunk; these are truncipetal muscles (*L. petere to go, to seek*). Autochthonous muscles (i.e. those developing in the given place) can always be differentiated, according to innervation, from the new muscles which moved there.

The musculature of the limbs is a derivative of the ventral trunk musculature and is supplied with nerves from the ventral branches of the spinal nerves through the brachial and lumbosacral plexuses. In lower fish (*Selachii*) muscle buds grow from the myotomes of the trunk, which are divided into two layers, one lying on the dorsal and the other on the ventral side of the skeleton of the fin. Similarly, in terrestrial vertebrates the muscles are primarily arranged dorsally and ventrally (extensors and flexors) in relation to the germ of the limb skeleton. In further differentiation the muscle buds of the anterior limb also grow proximally (truncopetal muscles) and cover the autochthonous musculature of the trunk on the chest and back (the *pectoralis major* and *minor* muscles, the *latissimus dorsi* muscle). Besides this primary musculature of the anterior limb, truncifugal muscles join the shoulder girdle; these are derivatives of the ventral musculature which are concerned with locomotion and fixation of the shoulder girdle and have moved to the shoulder girdle from the head (the *trapezius* and *sternocleidomastoid* muscles) and trunk

(the rhomboid, levator scapulae, anterior serratus, subclavius, and omohyoid muscles). Secondary muscles do not develop at the girdle of the posterior (hind) limb because the joint between it and the spine does not allow any movement. The complicated differentiation of the limb muscles in terrestrial vertebrates, particularly in the highest forms, is explained by the functions of the limbs, which are transformed into complex levers to accomplish different types of movements.

The muscles of the head arise partly from the cephalic somites, but mainly from the mesoderm of the visceral apparatus. The visceral apparatus in the lower fish consists of an entire muscular layer (a common constrictor), which, according to innervation, is separated into areas coinciding with the metameric arrangement of the visceral arches: the fifth pair of cranial nerves (the trigeminal nerve) corresponds to the first visceral (mandibular) arch; the seventh pair (the facial nerve) to the second visceral (hyoid) arch; and the ninth pair (the glossopharyngeal nerve) to the third visceral (first branchial) arch. The remaining part of the common constrictor is supplied with the branches of the tenth pair (the vagus nerve). Behind the common constrictor a bundle is set apart which is attached to the shoulder girdle (the trapezius muscle). When the lower vertebrates stopped living in water and adapted to life on dry land, they lost their ability to breathe branchially, an adaptation to aquatic life. The muscles of the visceral apparatus (visceral muscles), therefore, spread to the skull where they transformed into the muscles of mastication and facial expression although they retained their connection with those parts of the skeleton which had developed from the visceral arches. The masticatory muscles, arising from the mandibular arch, and the muscles of the floor of the mouth are thus located on and attached to the mandible and are innervated by the trigeminal nerve (fifth pair). The musculature corresponding to the second visceral (hyoid) arch mainly gives rise to the subcutaneous muscles of the neck and head, which are innervated by the facial nerve (seventh pair).

Muscles derived from the material of both visceral arches are marked by double attachment and double innervation, for instance, the digastric muscle whose anterior belly is attached to the mandible (innervated from the trigeminal nerve) and the posterior belly to the hyoid bone (innervated from the facial nerve). The visceral musculature innervated by the ninth and tenth pairs of the cranial nerves is partly reduced in terrestrial vertebrates and partly gives rise to the muscles of the pharynx and larynx. The trapezius muscle loses all connection with the visceral arches and becomes exclusively a muscle of the shoulder girdle. The independent sternocleidomastoid muscle separates from it in mammals. The posterior branch of the vagus innervating the trapezius muscle transforms in highest vertebrates to an independent cranial nerve, the accessory nerve (eleventh pair). Since the cerebral cranium is immobile in all its parts, no development of muscles can be expected on it. Therefore, only some remnants of musculature formed from the cephalic somites are found on it. Among these are the ocular muscles derived from the preauricular myotomes (innervation from the third, fourth, and sixth pairs of cranial nerves).

The occipital myotomes and the anterior truncal myotomes usually form by their ventral processes a special sub-branchial or hypoglossal musculature located under the visceral skeleton. In terrestrial vertebrates this musculature, penetrating anteriorly to the mandible, gives rise to the muscles of the tongue, which, because of their origin from the occipital somites, are supplied with a complex of nerves forming the hypoglossal nerve, which has become a true cranial nerve only in the highest vertebrates. The remainder of the hypoglossal musculature (below the hyoid bone) is a continuation of the ventral musculature of the trunk innervated by the anterior branches of the spinal nerves. Thus, to understand the arrangement and attachment of muscles, it is necessary to take into account both their function and their development.

Capitolul III. THE SCIENCE OF THE VISCERA (SPLANCHNOLOGY)

THE DIGESTIVE SYSTEM (SYSTEMA DIGESTORIUM)

The digestive (alimentary) system (systema digestorium) is a complex of organs whose function consists in mechanical and chemical treatment of food, absorption of the treated nutrients, and excretion of undigested remnants of the food. The structure of the digestive (alimentary) canal (canalis digestorius, s. alimentarius) is determined in the different animals and in man in the process of evolution by the shape-forming effect of the environment (nutrition). The human alimentary canal is about 8-10 m long and is subdivided into the following parts:

1. the cavity of the mouth,
2. the pharynx,
3. the oesophagus,
4. the stomach,
5. the small and large intestine.

The upper three parts located in the head, neck and chest and maintain a relatively straight direction. In the pharynx the alimentary canal intersects with the respiratory tract. After the oesophagus passes through the diaphragm, the digestive tube dilates and thus forms the stomach; the next in order after the stomach, the small intestine, is in turn composed in the duodenum, jejunum, and ileum. The large intestine consists of the caecum with the vermiform process, the ascending, transverse, descending, and sigmoid colon, and, finally, the rectum.

The entodermal primary alimentary canal is subdivided into three parts: (1) anterior (the foregut), from which develop the posterior part of the mouth, the pharynx (except for the superior area close to the choanae which is of ectodermal origin), the oesophagus, the stomach, and the initial part of the duodenum (the bulb); (2) middle part (the midgut) communicating with the yolk sac and developing into the small intestine, and (3) the posterior part (hindgut), from which the large intestine develops.

According to the different function of the different segments of the digestive tract, the three membranes of the primary alimentary canal, mucous, muscular, and connective-tissue, acquire different structure in the different parts of the canal.

THE CAVITY OF THE MOUTH

The cavity of the mouth, **oral cavity** (*cavitas oris*) is divided into two parts, the **vestibule** of the mouth (*vestibulum oris*) and the **cavity of the mouth proper** (*cavitas oris proprium*). The vestibule of the mouth is the space bounded by the lips and cheeks externally and by the teeth and gingivae internally. By means of the opening of the mouth, the oral fissure (*rima oris*), the vestibule opens into the external environment.

The **lips** (*labia oris*) are fibres of the orbicular muscle of the mouth covered on the outside by the skin and lined inside with mucous membrane. At the angles of the oral fissure the lips come together by means of commissures (*commissurae labiorum*). The skin on the lips is continuous with the mucous membrane of the mouth; extending from the upper lip to the surface of the gum (*gingiva*) the mucous membrane forms on the midline a rather conspicuous fold, frenulum labii superioris. Frenulum labii inferioris is usually hardly noticeable. Epithelial villi (*torus villosus*) are seen in the region of the angle of the mouth and on the posterior margin of the vermilion border of the lip in the newborn; they help the infant to grasp and hold in the mouth the mother's nipple during sucking.

The **cheeks** (*buccae*) are similar to the lips in structure but instead of m. orbicularis oris, the buccinator muscle (m. buccinator) is situated here. The fat lodged in the thickness of the cheeks (*corpus adiposum buccae*) is developed much better in the child than in an adult and is conducive to a decrease of pressure on the part of the atmosphere during sucking.

Cavitas oris proprium extends from the teeth anteriorly and laterally to the entry into the pharynx posteriorly. The oral cavity is bounded superiorly by the hard palate and the anterior part of the soft palate; the floor is formed by the diaphragm of the mouth (*diaphragma oris*) (the paired mylohyoid muscles) and is occupied by the tongue. When the mouth is closed, the tongue comes in contact with the palate so that the oral cavity becomes narrow slit-like space between them. The mucous membrane extending to the inferior surface of the tip of the tongue forms on the midline the frenulum of the tongue (*frenulum linguae*). On each side of the frenulum is a noticeable eminence, *caruncula sublingualis*, with the openings of the ducts of the sub-mandibular and sublingual salivary glands. The sublingual fold (*plica sublingualis*) stretches on each side laterally and posteriorly of the sublingual caruncle; it is formed by the sublingual salivary gland situated here.

The palate (*palatum*) consists of two parts. Its anterior two thirds have a bony foundation, *palatum osseum* (the palatine process of the maxilla and the horizontal plate of the palatine bone); this is the **hard palate** (*palatum durum*). The posterior third, the **soft palate** (*palatum molle*) is a muscular structure with a fibrous foundation. During quiet breathing through the nose it hangs obliquely downward and separates the oral cavity from the pharynx. A ridge, *raphe palati*, is seen on the midline of the palate. At the anterior end of the raphe is a row of transverse ridges (about six of them), *plicae palatinae transversum* (rudiments of palatine ridges contributing in some animals to the mechanical treatment of the food). The mucous membrane covering the inferior surface of the hard palate adheres closely to the periosteum by means of dense fibrous tissue. The soft palate is a duplication of the mucous membrane in which muscles are lodged together with a fibrous plate, the palatine aponeurosis, as well as glands. Its anterior margin is attached to the posterior edge of the hard palate, while the posterior part of the soft palate (*velum palatinum*) extends freely downward and to the back and has on the midline a tongue-like projection, **the uvula**. Laterally, the soft palate is continuous with folds, or arches. The anterior **palatoglossal arch** (*arcus palatoglossus*) passes to the lateral surface of the tongue, the posterior **palatopharyngeal arch** (*arcus palatopharyngeus*) stretches for some distance on the lateral wall of the pharynx. A depression forms between the anterior and posterior arches which lodges the **palatine tonsil** (*tonsilla palatina*). Each palatine tonsil is an oval-shaped mass of lymphoid tissue. The tonsil occupies the greater inferior part of a triangular depression between the arches (*sinus tonsillaris s. fossa tonsillaris*). The vertical dimension of the tonsil is 20 to 25 mm, the anteroposterior 15 to 20 mm, and the transverse dimension 12 to 15 mm. The medial surface of the tonsil is covered with epithelium, has an irregular, nodular, contour, and contains crypts (depressions). The lateral surface is covered by a fibrous capsule separating it from the pharyngeal wall. According to recent data, the entire tonsil is invested in a very thin capsule. The nearest important blood vessel in the facial artery which sometimes (when it is tortuous) comes very close to the pharyngeal wall at this level. This must be kept in mind in operation for removal of the tonsils. The internal carotid artery passes at a distance of about 1 cm from the tonsil.

The soft palate is composed of the following muscles.

1. **M. palatopharyngeus** arises from the aponeurosis of the soft palate and from hamulus pterygoideus, descends to the pharynx in the thickness of arcus palatopharyngeus, and is inserted in the posterior margin of the thyroid cartilage and the pharyngeal wall. It pulls the velum palatinum downwards and the pharynx upwards, in which case the pharynx becomes shorter and presses the soft palate to the posterior pharyngeal wall.

2. **M. palatoglossus**, arises on the inferior surface of the soft palate, descends in the thickness of arcus palatoglossus and is inserted on the side of the tongue where it is continuous with m. transversus linguae. It lowers velum palatinum and during this movement both palatoglossal arches become tense and the opening of the fauces is narrowed.

3. **M. levator veli palatini** originates on the inferior surface of the base of the skull and on the inferior surface of the cartilaginous part of the auditory tube and passes downwards and medially to the soft palate. It raises velum palatinum.

4. **M. tensor veli palatini** arises from spina ossis sphenoidalis and from the lateral surface of the membranous part of the auditory tube, descends vertically, its tendon curves around hamulus processus pterygoidei, turns medially almost at a right angle, and is inserted into the aponeurosis of the soft palate. It tenses velum palatinum in the transverse direction.

5. **M. uvulae** arises from spina nasalis posterior and from the aponeurosis of the soft palate and is inserted in the uvula. It shortens the uvula.

The uvula is present only in man because it is necessary to create a condition of air-tightness in the oral cavity, which prevents the jaw from hanging in the erect position of the body.

The aperture by means of which the oral cavity communicates with the pharynx is called the **fauces**, *s. isthmus faucium*. It is bounded on the sides by the palatoglossal arches, above by the soft palate, and below by the back of the tongue.

THE TEETH

The teeth (*dentes*) are ossified papillae of the mucous membrane concerned with the mechanical treatment of food. Phylogenetically, the teeth are derived from the scales of fish which grow along the edge of the jaws but acquire here new functions. Since teeth wear away they are shed and replaced by new ones; this occurs repeatedly many times in lower vertebrates and only twice in man: (1) **deciduous teeth** (*dentes decidui*) and (2) **permanent teeth** (*dentes permanentes*). Sometimes the teeth are replaced for the third time (replacement of the teeth for the third time was encountered in a 100-year-old man).

The most important parts of the tooth are **enamel** and **dentin**. During evolution, the teeth took a firmer position in the jaws, as a result of which two parts became distinguishable in the tooth: the part lodged in the alveoli of the jaws, **the root**, and the external part, **the crown**, concerned with mechanical treatment of the food. In this case, the diversity of food eaten by terrestrial animals and the development of their masticatory apparatus determine the development and specialization of the teeth. As a consequence, different shapes adapted to different types of food grasping and treating, namely: cutting (**the incisor teeth**), the tearing (**the canine teeth**), crushing (**the premolars**), and grinding of food (**the molars**).

Man, being omnivorous, has preserved all these types of teeth. Since the function of grasping changed from the jaws to the hands, however, the jaws became smaller and the teeth less in number, the development of the third molar (the "wisdom tooth") is sharply delayed, which reflects the tendency of regression of the teeth. A toothless man has been described as a case of anomaly.

Development of the teeth. Development of the teeth in man begins approximately on the seventh week of embryonic life. By this time, thickening of the epithelium lining the oral cavity appears in the region of the future upper and lower jaws and projects as an arch-like lamina into the underlying mesenchyma. Soon this epithelial lamina, still penetrating deeper, divides longitudinally into two secondary laminae situated almost at a right angle to each other. The anterior, or buccolabial, lamina splits eventually and transforms into an open epithelial fold separating the lip and the cheek from the gingiva and leading, consequently, to the formation of the vestibule of the oral cavity. The posterior, dental, lamina passes almost horizontally at first, but as it gradually grows and penetrates deeper it becomes more vertical. Epithelial growths appear on the edge of the lamina; they take the shape of flask-like protrusions and are the germs of the deciduous teeth. They are called dental "flasks", or the **enamel organs**. After the enamel organs form, the dental lamina continues penetrating deeper so that the enamel organs prove to be situated on its anterior (i.e. facing the lip or cheek) surface. Soon after its origin, the developing enamel organ acquires the shape of a bowl or bell with the corresponding depression being filled by mesenchyme forming the papilla of the tooth germ. The enamel organs gradually lose their connection with the dental lamina because the mesenchyme proliferates into their necks, which disintegrate to form separate nests of epithelial cells. As result the tooth germs are isolated absolutely. With the further development of the isolated tooth germs, the components of the tooth develop in them in such a manner that the epithelial cells give rise to the enamel, the mesenchymal tissue of the papilla gives origin to the dentine and the pulp, while the mesenchyme initially investing the enamel organ as the dental sac gives rise to the cement and the root sheath. Differentiation of the cells and the formation of dentine and enamel begin at the apex of the tooth germ and spread gradually to its base. Therefore, during the entire period of the development of the tooth germ more advanced stages are encountered at its apex while the nearer to its base the earlier are the developmental stages. With the gradual growth of the tooth germ in length, the bony walls of the alveolus become higher.

The teeth are located in the alveolar processes of the maxilla and mandible and are jointed by means of **gomphosis** (Gk *gomphos*, belting together). The tissue covering the alveolar process is called the **gums** (*gingivae*). The mucous membrane is closely jointed to the periosteum here by means of fibrous tissue; the gingival tissue is rich in blood vessels but poor in nerves. The grooved depression between the tooth and the free margin of the gum is called the **gingival pocket**.

Each tooth (*dens*) consists of:

(1) a **crown** (*corona dentis*), (2) a **neck** (*collum dentis*), (3) a **root** (*radix dentis*).

The crown is elevated above the gum, the neck (the slightly narrowed part of the tooth) is embraced by the gum, while the root sits in the dental alveolus and terminates in an **apex** (*apex radialis*), on which a small opening, the **apical foramen** (*foramen apicis*) is seen even with the naked eye. Vessels and nerves enter the tooth through this opening. Inside the tooth crown is a **cavity** (*cavum dentis*), in which are distinguished the crown part, the widest part of the cavity, and the root part, the narrowed part of the cavity called the **root canal** (*canalis radialis dentis*). The canal opens at the apex by means of the above mentioned apical foramen. The cavity of the tooth is filled with the **tooth pulp** (*pulpa dentis*) rich in vessels and nerves. The tooth roots fuse tightly with the surface of the tooth alveoli by, means of the alveolar **periosteum** (*periodontium*) supplied richly with blood vessels.

The tooth, the periodontium, the alveolar wall, and the gingiva compose the **tooth organ**. The hard material of the tooth consists of: (1) **dentine** (*dentinum*), (2) **enamel** (*enamelum*), and (3) **cement** (*cementum*). The bulk of the tooth enclosing the cavity of the tooth is dentine. The crown is coated with enamel, while the root is covered with cement.

The teeth are so fitted into the jaws that the crowns are above the gums and form the dental rows, the upper (maxillary) and the lower (mandibular) rows. Each row consists of 16 teeth arranged in the form of dental arch.

Five surfaces are distinguished in each tooth: (1) **facies vestibularis**, facing the vestibule of the mouth; in the anterior teeth it comes in contact with the lip mucosa and is called **facies labialis**, while in the posterior teeth it touches the mucosa of the cheeks and is called **facies buccalis**; (2) **facies lingualis**, s. *oralis*, facing the oral cavity, the tongue; (3) and (4) **facies contactus**, the surfaces coming in contact with the surfaces of the adjacent teeth. The contact surfaces directed towards the centre of the dental arch are designated **facies approximalis mesialis** (Gk *mesos* middle). This surface is medial in the anterior teeth but anterior in the posterior teeth. The contact surfaces directed away from the centre of the dental row are called **facies distalis**. In the anterior teeth this is the lateral surface, and in the posterior teeth, the posterior surface; (5) the masticating surface (**facies masticatoria**), or the surface for occlusion with the teeth of the opposite row (**facies occiusalis**).

To determine the location of a pathological process on a tooth, stomatologists use terms corresponding to the surfaces listed above: vestibular, oral, mesial, distal, occlusal, apical (towards the apex radialis).

The following three signs are used in determining to which side, right or left, a tooth belongs: (1) the root sign; (2) the crown angle sign, and (3) the crown curvature sign.

The root sign: the longitudinal root axis is inclined distally and forms an angle with a line passing through the middle of the crown.

The crown angle sign: the line of the masticating edge of the tooth forms a smaller angle where it passes to the mesial surface than where it passes to the distal surface.

The crown curvature sign: the vestibular surface of the crown is continuous more abruptly with the mesial than with the distal surface. Consequently, the mesial segment of the vestibular surface is more convex in the transverse direction than the distal segment. This is explained by the fact that the mesial part of the crown is developed more powerfully than the distal part. The mesiodistal slope of the crown is thus formed.

Whether a tooth belongs to the upper or lower jaw is established from the shape of the crown and the shape and number of the roots. It is therefore necessary to know the shape and the number of roots not only of a definite group of teeth but also of each separate tooth of the given group.

1. The incisors (*dentes incisivi*), four on each jaw, have a crown shaped like a cutting chisel; they cut food to the needed size. The crown of the upper incisors is wide, twice the width of that of the lower incisors. Each tooth has a single root, which in the lower incisors is flattened from the sides. The apex of the root deviates a little laterally.

The upper (maxillary) medial (central) incisor is the largest in the group of incisors. The labial surface of the crown is convex in the transverse and longitudinal directions. It has three longitudinal ridges each terminating on the mastication edge of the tooth in a small projection. On each side of the medial ridge is a longitudinal depression. The lingual surface of the crown is concave in the longitudinal and transverse directions. In the region of the neck it has a small tubercle (*tuberculum dentale*) from which ridges arise and pass along the lateral and medial margins of the lingual surface to the masticating edge of

the tooth. Of the three tooth signs, the crown curvature sign is pronounced best. The root is conical and longer than the crown; the ridges on its sides are weakly pronounced. It has three surfaces, one labial and two contacting.

The upper lateral incisor is smaller than the medial (central), incisor from which it is distinguished by the following features: the labial surface of the crown often bears a medial longitudinal groove on each side of which on the cutting edge in non-eroded teeth is a small nodular eminence. The ridges on the sides of the lingual surface are usually pronounced better than those on the medial incisors. A depression (*foramen cecum*) is often seen on this surface below the dental tubercle. The mesial surface is longer than the distal (lateral) surface and meets the cutting edge almost at a right angle, while the junction of the lateral surface with the cutting edge is rounded. The crown angle sign is well pronounced. The root is shorter than that of the medial incisor and is flattened in the mesiodistal direction; in most cases it is straight and has grooves on the sides. Its lateral surface is more convex than the medial.

The lower (mandibular) medial incisor is the smallest teeth in both jaws. The medial incisor is smaller than its distal neighbour. Both teeth possess the features characteristic of all incisors. The crown has the most typical shape of a chisel. Its anterior surface is slightly convex in the longitudinal direction and flattened transversely; the posterior surface is concave longitudinally and flattened transversely. The ridges are weakly pronounced or are absent in some cases. The root is greatly flattened.

2. The canines (*dentes canini*), two on each jaw, have a long single root flattened and grooved on its sides. The crown has two cutting edges which meet at an angle; a tubercle is seen on its lingual surface at the neck. The crown is so flattened that the lingual and labial surfaces converge toward the cutting edge. The vestibular surface is convex transversely and longitudinally. The cutting edge of the crown consists of two halves, a smaller mesial and a larger distal halves, which converge towards its apex. The distal half descends towards the corresponding contacting surface more steeply than the mesial half. All the tooth signs are characteristic of the canines.

The crown of the upper (maxillary) canine is massive. Its contacting surfaces diverge considerably towards the cutting edge. A powerful middle ridge passes on the lingual surface; it arises from the dental tubercle and becomes considerably thicker and wider in the direction of the cutting edge. The contacting surfaces are wide at the base but are relatively short. The root is massive and the longest of all the tooth roots. Its contacting surfaces are wide. In comparison with the lingual edge, the labial edge is blunt and wide.

The lower (mandibular) canine is smaller than its upper fellow. The longitudinal ridges on the labial and lingual surfaces of the crown are less conspicuous. The labial surface is slightly convex, the lingual surface is slightly concave. The contacting surfaces are almost parallel, the mesial does not converge towards the neck, while the distal contacting surface is slightly inclined towards it. The cutting edge of the crown is shorter than that of the upper canine but its mesial segment hardly differs from the distal in length. The root is shorter than the root of the upper canine, flatter, and has longitudinal grooves that are more pronounced. The root may bifurcate at the apex and a double root may form.

Teeth set in the jaw in front of the canines changed in one way: their crown became flat and a cutting edge formed; the teeth situated to the back of the canines changed in a different way; they acquired a well developed crown serving for the crushing and grinding of food. The canines, meanwhile, proved to be as if in a neutral zone and maintained the initial conical shape and the ancient function of the tooth, i.e. the cutting and tearing of food. That is why they are set on the boundary between the anterior (incisors) and the posterior (premolars and molars) teeth.

3. The premolars (*dentes premolares*), four on each jaw, are set immediately distal to the canines. The first premolar is located mesially and the second distally. A characteristic feature is the presence on the masticating surface of the crown of two masticating or occlusal eminences, or **cusps** (*tuberculum masticatoria*, s. *tuberculum occlusalia*). That is why these teeth are also called **bicuspid** (*dentes bicuspidati*). One of the cusps is vestibular (buccal) and the other lingual. The premolars have a single root, but that of the upper first premolar usually bifurcates; it is flattened anteroposteriorly.

The buccal surface of the crown of the upper (maxillary) first premolar resembles the labial surface of the canine. Its masticating edge is formed of a mesial and distal segments converging on the apex of the buccal cusp. The mesial segment is usually longer and almost horizontal, as a rule; the distal segment descends more steeply. A ridge descends from the cusp to the buccal surface; it is bounded by longitudinal grooves. The crown curvature sign is reverse. The lingual surface of the crown is narrower and more convex than the buccal surface and its junction with the lingual cusp is more rounded. Its contacting sur-

faces are almost quadrangular and slightly convex. The largest convexity is in the buccal half of the surface at the occlusal edge and serves for contact with the adjacent teeth. The masticating surface is trapezoid; the buccal cusp on it is somewhat higher than the lingual cusp. The root is compressed mesiodistally. Each contacting surface has a deep longitudinal groove and is continuous smoothly with the lingual and at an angle with the buccal surfaces. Bifurcation of the root at the apex is encountered in more than half of cases.

The upper (maxillary) second premolar is smaller than the first premolar, as a rule. They little differ in shape. The buccal cusp is less developed in the second than in the first premolar. The root is usually conical and single. Deep grooves are seen on the contacting surfaces. The root canal may be single or bifurcate.

The upper first premolar is distinguished from the second premolar by several signs: in the first premolar the buccal cusp is higher than the lingual cusp; the root is greatly compressed and usually bifurcate; in the second premolar the root is conical and may bifurcate only at the apex; the cusps on the crown are set almost at the same level. The buccal surface of the first premolar is triangular and more often than the buccal surface of the first premolar resembles the corresponding surface of the canine.

The lower premolars are distinguished from the upper premolars by a smaller size and a spherical crown whose transverse section has the contours of a circle. The buccal surface of the first premolar is inclined lingually; the lingual surface is narrower and shorter than the buccal; the contacting surfaces are convex and converge slightly towards the neck. The convexity is largest at the sites of contact with the adjacent teeth. The lingual cusp on the masticating surface of the crown is much smaller than the buccal cusp and this surface is consequently tilted lingually. The root is straight, rarely curved, and its circumference is even as a consequence of which rotation may be applied in extraction of the tooth. The root sign is demonstrated best.

The crown of the lower (mandibular) second premolar is a little larger than that of the first tooth. The crown axis meets the root axis at an angle open in the direction of the floor of the oral cavity. The masticating surface is quadrangular and inclined slightly toward the floor of the mouth. The groove separating the buccal cusp from the lingual cusp may give rise to accessory grooves, in which case the tooth is tricuspid. This shape of the crown enables the premolars to grind the food to small fragments. The root has a more apparent conical shape than the root of the first lower premolar. Besides, it is more massive and longer. All the signs determining the side to which the tooth belongs are clearly seen.

4. The molars (*dentes molares*). There are six molars on each jaw and they are smaller in the order from front to back; the first premolar is the largest, the third premolar is the smallest. The latter erupts late and is called the **wisdom tooth** (*dens serotinus s. dens sapientia*). The crown is cuboid and the masticating surface is more or less square (that of the upper molars is almost rhomboid), and has three or more cusps. This shape of the crown determines the function of the molars – they grind the food.

The upper molars have *three roots*, two *buccal* and one *lingual*; the lower molars have only two roots, *anterior* and *posterior*. The three roots of the wisdom tooth may fuse to form a single conical root. This group of teeth is characterized by the crown curvature sign.

The crown of the upper (maxillary) first molar is massive; the masticating surface is shaped like a rhombus with the long diagonal passing obliquely from the anterobuccal point to the distal lingual point of the surface. The four cusps on this surface are separated by three grooves forming the letter H. The mesial (buccal and lingual) cusps are larger than the distal cusps. The lingual surface of the crown is narrower and more convex than the buccal surface. The contacting surfaces are more convex at the masticating edge, at the site of contact of the teeth. The tooth has three roots, two buccal (a longer mesial cusp and distal cusp) and one lingual.

The upper (maxillary) second molar is smaller than the first one. Several variants are distinguished according to the appearance of the tooth and the character of the masticating surface of the crown. The most common variant: the masticating surface bears three cusps, two buccal and one lingual; it is triangular with the apex facing the tongue.

The upper (maxillary) third molar is the smallest of all the molars and the shape of its crown greatly varies. It usually has three masticating cusps, two buccal and one lingual. The number of cusps may be more or less than three. The tooth has three roots, but in most cases they fuse to form a blunt conical stem with longitudinal grooves at their fusion. Often this tooth does not develop at all or does not erupt.

The crown of the lower (mandibular) first molar is shaped like a cube. The masticating surface is square and has five cusps: two lingual, two buccal, and one distal. The buccal cusps are more massive and

lower than the lingual cusps; the distal cusp is small. The masticating surface is conspicuously inclined distally. Two grooves, transverse and longitudinal, pass on the masticating surface to form a cross at their intersection. The ends of the transverse groove stretching between the two buccal and the two lingual cusps descend onto the lingual and buccal surfaces of the crown. The longitudinal groove separates the buccal cusps from the lingual cusps. The distal cusp occupies the posterior part of the crown in the buccal half. The tooth has two roots, mesial (the wider one) and distal. Two tooth signs are conspicuous: the crown curvature and the root signs.

The lower (mandibular) second molar resembles the first molar but it is smaller. The crown is of a regular cubic shape. It has four cusps on the masticating surface. The roots are like those of the first molar. All the signs indicating the side to which the tooth belongs are clearly seen.

The lower (mandibular) third molar varies greatly. It is smaller than the second molar, the masticating surface of the crown bears four or five cusps. Their roots are usually two in number but may fuse for a greater or lesser length to form a single conical root. Not infrequently, the root curves considerably, usually distally.

The deciduous (milk) teeth are marked by some features: they are smaller and have less cusps and diverging roots between which are lodged the germs of the permanent teeth. The deciduous and permanent teeth have the same number of roots.

Eruption, or cutting, of the deciduous teeth, i.e. thinning of the gum and the appearance of the tooth crown in the mouth, begins in the seventh month of extrauterine life (the lower central incisors erupt first) and ends by the beginning of the third year. There are 20 deciduous teeth. Their dental formula is as follows: 2.1.0.2. The numbers indicate the amount of teeth on one half of each jaw (upper and lower): two incisors, one canine tooth, and two molars. The deciduous teeth are replaced by the permanent teeth after the age of six. The process consists in the eruption of new teeth, in addition to the 20 deciduous teeth, and the replacement of each milk tooth by a permanent tooth. Eruption of the permanent teeth begins with the first molar (the 6-year-old molar) and by the age of 12-13 all the teeth have erupted, except the third molar, which erupts between the ages of 18 and 30. The dental formula of a human adult for one side of the jaw is 2.1.2.3 total of 32 teeth. A more convenient formula is used in the stomatological clinic: the teeth are indicated in the order of their numbers beginning with the first (central) incisor and ending with the last (third) molar: 1, 2 (incisors), 3 (canine tooth), 4, 5 (premolars), 6, 7, 8 (molars).

When the upper and lower teeth come in contact (*occlusion*) the upper incisors overlap the lower incisors and partially cover them. This occurs because the maxillary dental arch is a little larger than the mandibular arch and because the maxillary teeth are inclined labially, whereas the mandibular teeth are directed lingually. As a consequence, the lingual cusps of the upper molars fit into the groove between the lingual and buccal cusps of the lower molars. There is no full congruence between the upper and lower teeth: each tooth comes in contact not with one but with two teeth of the other jaw. The teeth which meet in occlusion (articulate) are called antagonists (main and accessory); the lower central incisor and the upper third molar each have only one antagonist. As the result of such articulation, with the loss of a tooth the activity of the antagonist and the adjacent teeth articulating with the lost tooth is impaired. This should be borne in mind after the extraction of a bad tooth.

Two variants of normal occlusion (bite) are distinguished according to the relations of the upper anterior teeth to the lower anterior teeth in the vestibule-oral direction.

The first variant is called the scissor-like bite (*psalidodontia*) (Gk psalis scissors, odus tooth). It is encountered in most individuals (in 79.6 % according to certain data). In this type of occlusion, the cutting edges of the upper teeth overlap the cutting edges of the lower anterior teeth and cover 1.5-3.0 mm of the labial surface of the lower teeth with their lingual surface.

The second variant is called the tong-like bite (*labidodontia*). In this bite the cutting edges of the upper anterior teeth meet the cutting edges of the lower anterior teeth. It is encountered much less frequently than the bite of the first type; it mostly occurs in childhood (in attrition of the teeth) and in the elderly.

Pathological bites and abnormalities.

1. Hiatorodontia, gap-like (hiatus gap, cleft), a gap remains between the upper and lower anterior teeth.
 2. Stegodontia, roof-like (Gk stegos roof), the upper incisors protrude forward and cover the lower incisors like the slope of a roof.
 3. Opisthodontia (Gk opisthen behind), the upper anterior teeth are behind the lower anterior teeth.
-

4. Anomalous position of teeth. The adjacent teeth may exchange their position; a tooth may be set outside the dental arch, closer to the hard palate or the vestibule of the mouth. Teeth may sometimes erupt in the cavity of the nose, on the hard palate, in the maxillary sinus.

5. Anomalous number of teeth. The upper lateral incisors or the second premolars may be absent.

6. Anomalous shape of crown or root. Elongated or shortened roots or roots curved at different angles are encountered. The molars may have more roots than usually found. The number of cusps on the masticating surface of the crown may vary.

X-ray examination of the teeth is mostly made intraorally, i.e. the film is inserted into the mouth and pressed to the lingual surface of the teeth with the finger or the teeth are closed upon it. The teeth may also be examined on extraoral radiographs and on radiographs of the facial skull. The radiograph clearly demonstrates all the anatomical details of the tooth with an area of low density at the site of the dental cavity. A narrow band of low density corresponding to the pericementum (periodontal membrane) is noticeable on the periphery of the part of the tooth that is embedded in the dental socket. Germs of the deciduous teeth located in the jaw are seen on the radiographs of the facial skull of the newborn. Radiographs taken later show the X-ray picture of the development, eruption and shedding of the deciduous teeth, the appearance of the germs of the permanent teeth, the development of these teeth, and the age changes in them.

THE TONGUE

The tongue (*lingua*) (Gk *glossa* tongue) is mainly a muscular organ (striated fibres). The changes in its shape and position are significant in the acts of mastication and speech, while due to the presence of specific nerve endings in the mucous membrane the tongue is also the organ of taste. Three parts are distinguished in the tongue: the larger part, or **the body** (*corpus linguae*) facing anteriorly, **the tip** (*apex*) and the postero-inferior part, or **the root** (*radix linguae*) by means of which the tongue is attached to the mandible and the hyoid bone. Its convex superior surface faces the palate and pharynx and is called **the back** (*dorsum*). The inferior surface of the tongue (*facies inferior linguae*) is free only in the anterior part; the posterior part is occupied by muscles. On the sides the tongue is bounded by **margins** (*margo linguae*). Two parts are distinguished on the dorsum of the tongue: **the anterior**, larger (accounting for about two thirds of the tongue), part is situated almost horizontally on the floor of the oral cavity; the **posterior part** is almost vertical and faces the pharynx.

At the junction of the anterior and posterior parts of the tongue on the midline is a **depression** (*foramen caecum linguae*), which is the remnant of the tubular projection from the floor of the primary pharynx, from which the thyroid isthmus develops. Forward and lateralward from this foramen extends on either side the **terminal sulcus of the tongue** (*sulcus terminalis linguae*).

The two parts of the tongue differ in development and structure of the mucous membrane. The tongue mucosa is a derivative of the first, second and, probably, the third visceral arches (to be more precise, the branchial pockets), evidence of which is its innervation by the nerves of these arches (the fifth, seventh, ninth, and tenth pairs of cranial nerves). The first visceral (mandibular) arch gives rise to two lateral areas, which fuse on the midline to form the anterior part. The trace of the fusion of the paired germ remains through out life on the dorsum of the tongue in the form of a median sulcus (*sulcus medianus linguae*) and within the tongue as a fibrous septum of the tongue (*septum linguae*). The posterior part arises from the second, third, and, evidently, the fourth visceral arches and fuses with the anterior part on *linea terminalis*.

The mucous membrane of the anterior part of the tongue is supplied with numerous **papillae** and bears the median sulcus mentioned above. In the posterior part, the mucous membrane is thicker and smoother because there are no papillae, but it has a bulging appearance due to the presence of lymphoid follicles. The aggregation of the lymphoid structures of the posterior part of the tongue is called the **lingual tonsil** (*tonsilla lingualis*). Three folds of the mucous membrane, **glosso-epiglottic fold** (*plica glosso-epiglottica mediana*) and two **pharyngo-epiglottic folds** (*plicae glosso-epiglotticae laterales*) stretch from the posterior part of the tongue to the epiglottis; two depressions, **valleculae epiglotticae**, are seen between the median and lateral folds. **The tongue papillae** (*papillae lingualis*) are of the following types.

1. **Filiform and conical papillae** (*papillae filiformis* and *conicae*) are the smallest but most numerous. They occupy the superior surface of the anterior part of the tongue and lend its mucous membrane a rough or velvety appearance. The filiform and conical papillae evidently act as tactile organs.

2. **Fungiform papillae** (*papillae fungiformes*) are less in number and are found mainly at the apex and on the margins of the tongue. They are supplied with taste buds and it is therefore accepted that they are concerned with the sense of taste.

3. **Vallate (walled) papillae** (*papillae vallatae*) are surrounded by a bank. They are the largest and are arranged in the shape of the letter V immediately in front of the foramen cecum and the terminal sulcus, with the apex facing posteriorly. Their number varies between 7 and 12. Each papilla consists of a central cylindrical part (1.0-2.5 mm in diameter) and a surrounding deep narrow groove. Very many taste buds are embedded in each papilla.

4. **Foliate papillae** (*papillae foliatae*) are located on the margins of the tongue.

The taste papillae are also encountered on the free edge and nasal surface of the palate and on the posterior surface of the epiglottis. Peripheral nerve endings, the receptors of the taste analyser, are embedded in the taste papillae.

The muscles of the tongue constitute its muscular bulk, which is divided into two symmetric halves by a longitudinal **fibrous septum** (*septum linguae*). The superior edge of the septum does not reach the dorsum of the tongue. The muscles of the tongue are separated into two groups:

(1) **extrinsic**, skeletal, muscles, i.e. those the punctum fixum of which is on the bones and which alter its position on contraction: the genioglossus, hyoglossus and styloglossus muscles;

(2) **intrinsic** muscles, which have no insertion on bones and are embedded within the tongue itself and change its shape: the superior and inferior longitudinal muscles and the transversus linguae and verticalis linguae muscles.

According to developmental classification it is more correct, to distinguish **three groups** of muscles according to structure and action:

(1) muscles arising on the derivatives of the first visceral arch (on the mandible), these are the genioglossus muscle and its continuation, the vertical muscle;

(2) muscles arising on the derivatives of the second visceral arch (on the styloid process and lesser horns of the hyoid bone): these are the styloglossus and the superior and inferior longitudinal muscles;

(3) muscles arising on the derivatives of the third visceral (first branchial) arch (on the body and greater horns of the hyoid bone): these are the hyoglossus and the transverse muscles. The palatoglossus muscle is also related to this group.

The genioglossus muscle is the largest of all the tongue muscles and achieves highest development only in man due to the appearance of articulate speech. It arises from the mental spine, which is also most conspicuous in man due to the effect of the muscle, and its discovery in fossil hominids is therefore accepted as a sign that this family was capable of speech. From the mental spine the muscular fibres irradiate fanwise, the lower fibres being inserted into the body of the hyoid bone, the intermediate fibres into the root of the tongue, and the upper fibres curving forwards to be inserted into the tip of the tongue. The continuation of the muscle in the thickness of the skull are vertical fibres (**m. verticalis**) stretching between the inferior surface and the dorsum of the tongue. The muscle fibres of the genioglossus muscle and its continuation—the vertical muscle—are predominantly vertical. As a result their contraction moves the tongue forward and flattens it.

The styloglossus muscle originates on the styloid process and the stylomandibular ligament, descends medially, and inserts into the side and inferior surface of the tongue; at the site of insertion it intersects with the fibres of the hyoglossus and palatoglossus muscles. It pulls the tongue upward and to the back.

The superior longitudinal muscle (*m. longitudinalis superior*) arises on the lesser horns of the hyoid bone and on the epiglottis and stretches under the mucosa of the dorsum of the tongue on either side of septum linguae to the tip.

The inferior longitudinal muscle (*m. longitudinalis inferior*) arises from the lesser horns of the hyoid bone and stretches on the inferior surface of the tongue between the genioglossus and hyoglossus muscles to the tip of the tongue. The bundles of this group of muscles are mainly directed sagittally, as a result their contraction moves the tongue backward and shortens it.

The hyoglossus muscle arises from the greater horn and the nearest part of the body of the hyoid bone, stretches forward and upward and is inserted into the margins of the tongue together with the fibres of the styloglossus and transverse muscles. It pulls the tongue backward and downward.

The transverse muscle of the tongue (*m. transversus linguae*) stretches in the horizontal plane between the superior and inferior longitudinal muscles from the septum to the margins of the tongue. Its pos-

terior part is attached to the hyoid bone. The transverse muscle of the tongue is continuous with the palatoglossus muscle described above. The slips of this muscle are mainly directed frontally with the result that their contraction reduces the transverse dimension of the tongue. In unilateral contraction, the tongue moves to the side of the contracting muscles, in bilateral contraction it moves downward and backward.

The origin of the tongue muscles on three bone points located posteriorly and superiorly (the styloid process), posteriorly and inferiorly (the hyoid bone), and anteriorly of the tongue (the mental spine of the mandible), and the arrangement of the muscle fibres in three mutually perpendicular planes enable the tongue to change its shape and move in all three directions.

THE SALIVARY GLANDS OF THE ORAL CAVITY

The ducts of three pairs of **large salivary glands** open into the oral cavity: the parotid, submandibular, and sublingual glands. Besides these, there are numerous **small glands** in the mucous membrane of the mouth, which, according to their location, are called as follows: the labial, buccal, palatine, and lingual glands. According to the character of the secretion, the glands may be serous, mucous or mixed. The three pairs of large salivary glands (glandulae salivales) attain considerable size and are located beyond the mucous membrane and retain connection with the oral cavity by their ducts.

The parotid (*glandula parotis*) is the largest of the salivary glands and is a serous gland. It is situated on the lateral side of the face in front of and a little below the ear and penetrates into the retromandibular fossa. On the surface, the tissue of the gland extends upward almost to the zygomatic arch and downward to the mandibular angle, in front it lies on the masseter muscle, and at the back it reaches the external acoustic meatus and the anterior border of the sternocleidomastoid muscle. The gland has a lobular structure and consists of seven lobules. The parotid is invested in a fascia (*fascia parotideae*). **The duct of the gland** (*ductus parotideus*) is 5-6 cm long and arises from the anterior border of the gland, passes on the surface of the masseter muscle, curves around its anterior border, and after passing through the fatty tissue of the cheek pierces the buccinator muscle. It then enters the oral cavity under the mucous membrane and opens into the vestibule of the mouth by a small opening opposite the second upper molar. The course of the duct varies greatly and it may be straight, arched, genual, S-shaped, descending, and bifurcate. In structure, the parotid is a compound racemous gland.

The submandibular gland (*glandula submandibularis*) is of a mixed character, compound alveolar-tubular in structure, and the second largest after the parotid. It consists of ten lobules. The sub-mandibular gland is situated in the submandibular fossa, emerges from under the border of the mandible and is covered here by the skin, the platysma muscle, and the fascia of the neck; the fascia invests the gland and forms a thin-walled capsule. The posterior part of the gland extends a little beyond the posterior border of the mylohyoid muscle. On the posterior border of this muscle a process of the gland curves over to its anterior surface; from this process extends the **submandibular duct** (*ductus submandibularis*), which passes over the mylohyoid muscle on the floor of the oral cavity and opens on *caruncula sublingualis*.

The sublingual gland (*glandula sublingualis*) is of the mucous type and alveolar-tubular in structure. It is situated over the mylohyoid muscle on the floor of the oral cavity, and, covered only by the mucous membrane, forms a **sublingual fold** (*plica sublinguales*) between the tongue and the inner surface of the mandible. In front of the frenulum of the tongue it comes in contact with the contralateral gland. The ducts of some lobules (18-20 in number) open independently into the oral cavity along the sublingual fold; they are called the **smaller sublingual ducts** (*ductus sublinguales minores*). **The principal duct of the sublingual gland** (*ductus sublingualis major*) passes next to the duct of the submandibular gland and opens by means of a single opening common to both ducts or by its own opening alongside the opening of the submandibular duct.

THE PHARYNX

The pharynx is that part of the alimentary canal and respiratory tract, which is a connecting link between the cavity of the nose and mouth and the oesophagus and trachea. It stretches from the level of the base of the skull to that of the sixth or seventh cervical vertebra. The space within the pharynx is the **pharyngeal cavity** (*cavitas pharyngis*). The pharynx is situated behind the nasal and oral cavities and the larynx and in front of the basilar part of the occipital bone and the upper six cervical vertebrae. In accordance with the organs situated in front of the pharynx, *three parts* can be distinguished in it: **pars nasalis**,

pars oralis, and **pars laryngea**. The superior wall of the pharynx, which adjoins the base of the skull, is called the **vault of the pharynx** (*fornix pharyngis*).

The **nasal part of the pharynx**, or the **nasopharynx**, or the **rhynopharynx** (*pars nasalis pharyngis*) is a purely respiratory part functionally. As distinct from the other parts of the pharynx, its walls do not collapse because they are immobile. The anterior wall of the nasal part is occupied by the *choanae*. On either lateral wall is a funnel-shaped pharyngeal **opening of the auditory tube** (part of the middle ear), *ostium pharyngeum tubae*. Superiorly and posteriorly the opening of the tube is bounded by *torus tubarius* formed due to the projection of the cartilage of the auditory tube here. At the junction of the superior and posterior pharyngeal walls on the midline is an accumulation of lymphoid tissue, the **pharyngeal tonsil**, or **adenoids** (*tonsilla pharyngea s. adenoidea*) (in adults it is hardly noticeable, or disappears entirely). Another accumulation of lymphoid tissue, but paired, is located between the pharyngeal opening of the tube and the soft palate; this is the **tube tonsil** (*tonsilla inbaria*).

Thus, almost a complete ring of lymphoid structures is found at the entry into the pharynx: the lingual tonsil, two palatine tonsils, two tube tonsils, and one pharyngeal tonsil (pharyngeal Pirogov's lymphoepithelial ring).

The **oral part**, or the **oropharynx** (*pars oralis*) is the middle part of the pharynx communicating with the oral cavity in front through the *isthmus faucium*, its posterior wall corresponds to the third cervical vertebra. The oral part is mixed in function because the alimentary and respiratory tracts intersect here.

The intersection formed during the development of the respiratory organs from the wall of the primary gut. The nasal and oral cavities originated from the primary naso-oral bay, the nasal cavity being situated superiorly or as if dorsally in relation to the oral cavity, whereas the pharynx, trachea, and lungs arose from the ventral wall of the foregut. The cephalic part of the alimentary tract is, consequently, located between the nasal cavity (superiorly and dorsally) and the respiratory tract (ventrally). As a result the alimentary and respiratory tracts intersect in the pharynx.

The **laryngeal part**, or the **laryngopharynx** (*pars laryngea*) begins behind the trachea and extends from the opening into the larynx to the opening into the oesophagus. In a state of rest, when there is no swallowing, the anterior and posterior walls of this part remain in contact and separate only when food passes in it, that is why the laryngeal part cannot be seen during laryngoscopy if the larynx is not pulled forward. On the anterior wall is the opening into the larynx bounded in front by the epiglottis and on the sides by the aryepiglottic folds (*plicae aryepiglotticae*). On either side of the folds lie **paired pear-shaped fossae** in the pharyngeal wall (*recesses piriformes*).

The foundation of the pharyngeal wall is a well developed layer of fibrous tissue. This fibrous coat is lined inside with **mucous membrane** (*mucous coat*) and covered from the outside by a **muscular coat**. The muscular coat is in turn covered by a thinner layer of fibrous tissue connecting the pharyngeal wall with the adjoining organs; superiorly this fibrous tissue passes on to the buccinator muscle and is called the *buccopharyngeal fascia*. The fibrous coat of the **pharynx**, **pharyngobasilar fascia** (*fascia pharyngobasilaris*) is attached above to the basal part of the occipital bone and to the other bones of the base of the skull and stretches forward to the medial pterygoid plate. The fibrous coat is particularly well developed in the upper part where it is only partly covered by the superior constrictor. The mucous coat of the nasal part of the pharynx is covered with ciliated epithelium in accordance with the respiratory function of this part of the pharynx, whereas in the inferior parts it is covered with stratified squamous epithelium. The mucous coat of the inferior parts of the pharynx fuses with the underlying tissue and acquires a smooth surface, which promotes gliding of the bolus during swallowing and is also aided by the secretion of mucous glands embedded in the mucosa.

Pharyngeal muscles are arranged **longitudinally** (*dilators*) and **circular** (*constrictors*).

The circular layer is much stronger and consists of three constrictors arranged in three storeys: the **superior constrictor muscle of the pharynx** (*m. constrictor pharyngis superior*), the **middle constrictor muscle of the pharynx** (*m. constrictor pharyngis medius*), and the **inferior constrictor muscle of the pharynx** (*m. constrictor pharyngis inferior*). Arising on different points, namely on the bones of the base of the skull (pharyngeal tubercle of the occipital bone and the pterygoid process of the sphenoid bone), on the mandible (the mylohyoid line), on the root of the tongue, on the hyoid bone, and on the pharyngeal cartilages (thyroid and cricoid) the fibres of the muscles on each side pass backward and join each other to form a seam on the midline of the pharynx, the **raphe of the pharynx** (*raphe pharyngis*). The

lower fibres of the inferior pharyngeal constrictor are, closely connected with the muscle fibres of the oesophagus.

The longitudinal muscle fibres of the pharynx run in the following two muscles.

The stylopharyngeus muscle (*m. stylopharyngeus*) arises from the styloid process and descends to be inserted partly in the pharyngeal wall itself and partly on the superior edge of the thyroid cartilage.

The palatopharyngeus muscle (*m. palatopharyngeus*) is described above.

The act of swallowing, deglutition. Since the respiratory and digestive tracts intersect in the pharynx, special devices exist, which separate these two tracts during swallowing. By contraction of the tongue muscles the bolus is pressed against the hard palate by the dorsum of the tongue and then pushed through the fauces. During this process, the soft palate is pulled upward (by contraction of the levator veli palatini and the tensor veli palatini muscles) and brought nearer to the posterior pharyngeal wall (by contraction of the palatopharyngeus muscle). In this manner, the nasal (respiratory) part of the pharynx is completely separated from the oral part. At the same time, the suprahyoid muscles pull the pharynx upward, while the root of the tongue is pulled downward by contraction of the hyoglossus muscle; the root of the tongue presses against the epiglottis and depresses it and closes the opening into the larynx (into the respiratory tract) in this way. Then the pharyngeal constrictors contract in succession as a result of which the bolus is pushed toward the oesophagus. The longitudinal pharyngeal muscles act as elevators, they pull the pharynx to meet the bolus.

DEVELOPMENT OF THE FACE AND FORMATION OF THE ORAL CAVITY, DEVELOPMENTAL ABNORMALITIES

On the 4 week of embryonal development the primary gut, which derives from entoderm it is closed on both its ends: the cranial is closed by pharyngeal membrane and the caudal end by the anorectal membrane.

At the end of the first month of embryonic life a pouch (**Rathke's pouch**) forms as a protrusion towards the brain. It invaginates and reaches the pharyngeal membrane, which consists of two layers and it forms between the oral pit and the primary gut.

Layers of the pharyngeal membrane

- The outer layer is of ectodermal origin;
- The inner layer is of entodermal origin.

On the 4-5 week the pharyngeal membrane ruptures and the cavity of the primary oral pit communicates with the cavity of the primary gut.

FACE

The face is formed by three swellings, which are derivatives of the pharyngeal arch (**I arch**).

1. The frontonasal process (unpaired);
2. Maxillary process (paired);
3. Mandibular process (paired).

The **mandibular processes** fuse on the midline to form the mandible and the corresponding to it parts of face.

From the **maxillary process** develops the maxilla with the palate and the corresponding soft tissues of the face and the lateral segments of the upper lip.

On the midline between the two maxillary processes, which do not fuse, the frontonasal process is interposed and by joining the maxillary process forms the upper wall of the oral cavity.

From the **frontonasal process** develop the nasal septum, the incisive part of the hard palate and the middle part of the upper lip (the strainer).

Between the internal surfaces of the maxillary processes forms a palatine plate, which grows toward the median plane. At first the right and left palatine plates do not fuse and a cleft forms between them, but later they fuse to each other to form the palate.

ABNORMALITIES

- The **maxillary** and mandibular processes on each side fuse to form the angles of the mouth. If they fail to unite it results in macrostomia (very large oral orifice, *rima oris*). If they unite very close, then it results in microstomia (very small oral orifice, *rima oris*).

- Failure of fusion of the frontonasal process with the maxillary processes results in **hare-lip**, *labium leporinum*.

- **Cleft palate** results as a failure of fusion of the palatine plates.
- Cleft lip and cleft palate are distinct malformations which often occur together.

AGE SPECIFIC FEATURES OF THE ORAL CAVITY ORGANS

In new-born the oral cavity is of small size. The vestibule of the mouth is bounded by the gingival margin (there are no teeth). The lips are thick, their mucous membrane is covered by papillae and on the internal surface of the lips there are transverse folds. The intermediate part of the lips is narrow, but the orbicular muscle is well developed.

The hard palate is flat and is situated at the level of the pharyngeal fornix. The soft palate is short and has a horizontal position. The *velum palatinum* does not touch the posterior wall of the pharynx and due to this fact the child can freely breathe during sucking. The mucous membrane of the hard palate is pour in glands and the transverse ridges of the hard palate are weakly seen.

The tongue in new-born is wide, short, thick and hardly mobile. It fills the entire oral cavity. The papillae of the tongue and the lingual tonsil are not well developed.

During eruption of the teeth the alveolar processes grow in size.

The palatine tonsil in new-born is small but well seen, because the palatine arches are not well developed. The maximal development of the palatine tonsil is accounted at the age of 16.

DEVELOPMENT OF THE TONGUE, DEVELOPMENTAL ABNORMALITIES

The oral part of the tongue appears in embryo at approximately 4 weeks in form of **two lateral and one median lingual swellings** (buds). They originate from the first pharyngeal arch. The lateral tongue buds overgrow the median tongue bud and fuse in the midline, forming the median sulcus, to which within the tongue corresponds the septum of the tongue.

The **pharyngeal part** of the tongue forms from a second median swelling, the hypobranchial eminence (or copula), which derives from the mesoderm of the second, third and fourth arches.

At the boundary between the oral part and pharyngeal part of the tongue forms a ventral invagination of epithelium, called thyroglossal duct, from which the thyroid gland develops. On the dorsal surface of the tongue, as a remnant of the thyroglossal duct remains the foramen *caecum linguae*.

ABNORMALITIES

- **Ankyloglossia (tongue-tie)** occurs when the frenulum of the tongue extends to the tip of the tongue, and the tongue is not freed from the floor of the mouth.
- **Bifurcated tongue** occurs when there is a failure of fusion of the tongue buds.
- **Persistence of the thyroglossal duct** when instead of the foramen *caecum linguae* the tongue is united with the thyroid gland by the hypoglossal duct.

THE RESPIRATORY SYSTEM (SYSTEMA RESPIRATORIUM)

The respiratory organs are concerned with the supply of oxygen to the blood, by which it is brought to the tissues of the body, and with the removal of carbon dioxide into the atmosphere. In aqueous animals the gills are the organs of respiration; these are special adjustments of the primary gut. On both sides of it form gill slits on whose edges are leaflets with a great number of blood capillaries. The water passing through the slits flows around the gills as a result of which oxygen is extracted from it and enters directly into the blood, and carbon dioxide is discharged into the water. With the evolution of animals to terrestrial life respiratory organs of the aqueous type (the gills) are replaced by those of the air type (the lungs) that are adapted to respiration in the atmosphere. This replacement occurs gradually. The amphibians, for instance, breathe with the gills in a larval state but with the lungs in an adult state. In animals living on the ground, beginning with the reptiles, the gills lose their importance and become the source of the formation of other organs, while the respiratory function is accomplished by the lungs alone, which, like the gills, are derived from the primary guts. The respiratory organs in mammals develop from the ventral wall of the foregut and retain their connection with it throughout life. This explains the existence of the intersection of the respiratory and digestive tracts in the pharynx also in man a fact mentioned above. To accomplish the act of respiration, an adjustment providing for the flow of fresh air current along the respiratory surface, i.e. the circulation of air, is necessary. In view of this, air passages exist, in addition to the lungs,

namely the nasal cavity and pharynx (upper air passage) and then the larynx, trachea, and bronchi (the lower air passage). The formation of their walls of inflexible tissues (bone and cartilage) is a specific feature of these passages; as a result the walls do not collapse and, despite the sharp change of pressure from positive to negative, air freely circulates in both directions on inspiration and expiration. The inspired air passes to the larynx by way of the cavity of the nose (or mouth) and the pharynx. The structure of the mouth and pharynx is described above in the chapter dealing with the digestive system, and that of the bone foundation of the nasal cavity in the chapter on osteology.

THE CAVITY OF THE NOSE

Before coming in contact with the fine tissue of the lungs the inspired air must be cleansed of dust, warmed, and humidified. This is accomplished in **the nasal cavity** (*cavitas nasi*). There is also **the external nose** (*nasus externus*) whose skeleton is partly osseous and partly cartilaginous. As it is indicated in the chapter concerned with osteology, the cavity of the nose is separated by the nasal septum (osseous at the back and cartilaginous in front) into two symmetric halves, which communicate anteriorly with the atmosphere through the external nose by means of the nostrils and posteriorly with the pharynx by means of the choanae. The walls of the cavity as well as the septum and conchae are lined with mucous membrane, which is continuous with the skin in the region of the nostrils and with the pharyngeal mucosa posteriorly.

The nasal mucosa contains a series of adjustments for treatment of the inspired air: (1) it is covered with **ciliated epithelium** whose cilia form a carpet on which dust settles. The vibration of the cilia in the direction of the choanae drives out the settled dust; (2) the mucous membrane contains **mucous glands** (*glandulae nasi*) whose secretions wrap around the dust and make its expulsion easier and also humidify the air; (3) **the submucous tissue** is rich in veins, which form thick networks (resembling **cavernous bodies**) on the inferior concha and the lower border of the middle concha; under different conditions these networks may swell and be the cause of nose bleeding. These structures are concerned with warming the current of air passing through the nose.

The described adjustments of the mucous membrane for the mechanical treatment of the air are situated on the level of the middle and inferior conchae and **nasal passages** (*meatuses*). This part of the nasal cavity is therefore called **the respiratory region** (*regio respiratoria*). In the upper part of the nasal cavity, at the level of the superior concha, is an adjustment for the control of the inspired air, namely **the olfactory organ** that is why the upper part of the internal nose is called **the olfactory region** (*regio olfactoria*). The peripheral endings of the olfactory nerve, the olfactory cells composing the receptor of the olfactory analyser, are embedded here. A person cannot perceive odours when his nostrils are destroyed by some pathological process and the current of inspired air is directed along the inferior nasal passage, i.e. does not come in contact with the olfactory region. An additional adjustment for ventilation of the air are **the paranasal sinuses** (*sinus paranasales*), which are also lined with mucous membrane, a direct continuation of the nasal mucosa. These are the structures described as: (1) **the maxillary sinus** (*sinus maxillaris s. Highmori*) whose orifice (wide on a skeletonized skull) is closed by mucous membrane except for a small slit; (2) **the frontal sinus** (*sinus frontalis*); (3) **the air spaces of the ethmoid bone** (*cellulae ethmoidales*) composing the ethmoidal sinus (*sinus ethmoidalis*); (4) **the sphenoidal sinus** (*sinus sphenoidalis*).

On inspection of the nasal cavity of a live person (rhinoscopy) the mucous membrane is pink. The nasal conchae, nasal passages (*meatuses*), air spaces of the ethmoid bone, and the orifices of the frontal and maxillary sinuses are visible. The conchae and paranasal sinuses increase the surface of the mucous membrane, contact with which improves the treatment of the inspired air. Free circulation of air, necessary in breathing, is ensured by the inflexibility of the walls of the nasal cavity composed of bones complemented by cartilages.

The cartilages of the nose are remnants of the cartilaginous nasal capsule and are **hyaline** in structure.

The unpaired cartilage of **the nasal septum**, septal cartilage (*cartilago septi nasi*) is a component of the anterior part of the septum, its posterior edge adjoining the vomer and the anterior edge, the perpendicular plate of the ethmoid bone.

The other cartilages are paired. **The upper nasal cartilage** (*cartilago nasi lateralis*) is a triangular plate in the middle part of the side of the nose. It forms the foundation of the dorsum of the nose. **The lower and small cartilages of the nose** (*cartilago alaris major and cartilago alaris minor*) form the cartilaginous

foundation of the ala, the nostril, and the movable part of the septum. The bones and cartilages, covered with skin, form the **external nose** (*nasus externus*). In it are distinguished the **root** (*radix nasi*), which is at the top, the **apex** (*apex nasi*) directed downward, and **two lateral walls**, which unite to form the dorsum of the nose (dorsum nasi) facing anteriorly. The inferior parts of the lateral walls separated by grooves form the **alae of the nose** (*alae nasi*) whose inferior margins bind the **nostrils**, or **nares**, through which air passes into the nasal cavity. The nostrils of all animals, including primates, are directed to the front, while the nostrils of man, in distinction, are directed downward. As a result, the current of inspired air instead of passing straight to the back, like in monkeys, flows upward to the olfactory region and follows a long and arched path to the nasopharynx, which facilitates its treatment. The expired air passes on a straight line in the inferior nasal meatus. The protruding nose is, in general, a specific feature of man because even anthropoid apes do not have a nose; this is evidently linked with the upright position of the human body and the changes in the facial skeleton due to the weaker masticating activity, on the one hand, and to the development of speech, on the other.

The inspired air passes from the nasal cavity through the choanae into the nasopharynx, into the oral part of the pharynx, and then into the larynx. Respiration can also occur through the mouth, but the absence in the oral cavity of adjustments for controlling and treating the air causes frequent development of diseases in such instances. (Some animals, for instance rabbits, die of infection if they are forced to breathe through the mouth by plugging the nostrils with cotton wool). It is therefore necessary to see to it that breathing occurs through the nose.

THE LARYNX

The **larynx** is situated on the level of the fourth, fifth, and sixth cervical vertebrae immediately below the hyoid bone, on the anterior surface of the neck and form here a clearly visible eminence. To the back of it is the pharynx with which it communicates directly through an opening called the **inlet of the larynx** (*aditus laryngis*). On both sides of the larynx pass large vessels of the neck while in front it is covered with muscles of the infrahyoid group (sternohyoid, sternothyroid, and omohyoid muscles), the cervical fascia, and the superior parts of the lateral lobes of the thyroid. Below the larynx is continuous with the trachea.

The human larynx is an amazing musical instrument, a combination of a wind instrument and stringed instrument. The air expired through the larynx causes vibration of the vocal cords, which are stretched tight like strings. As a result a sound forms. Unlike musical instruments, in the larynx the degree of stretching of the strings and the size and shape of the cavity, in which the air circulates, alter due to contraction of the muscles of the oral cavity, tongue, pharynx and the larynx itself; the contraction of the muscles is controlled by the nervous system. In this man differs from the anthropoids that are absolutely incapable of regulating the current of the expired air that is necessary in singing and speaking. Only the gibbon can to some measure produce musical sounds with its voice ("the scale of the gibbon"). Besides, "vocal sacs", continuing under the skin and serving as resonators, are greatly developed in the monkeys. In man they are rudimentary structures (ventricles of the larynx). Thousands of years were needed for the undeveloped larynx of the monkey to be transformed into the human larynx by gradually intensifying modulations and "the organs of the mouth gradually learned to pronounce one articulate letter after another". Being a peculiar musical instrument, the larynx is at the same time built according to the principle of a motor apparatus and is therefore marked by a skeleton in the form of cartilages, unions in the form of ligaments and articulations, and muscles which move the cartilages as a result of which the size of the rima vocalis and the degree of stretching of the vocal cord change.

CARTILAGES OF THE LARYNX

1. The **cricoid cartilage** (*cartilago cricoidea*) is hyaline and shaped like a signet ring with a wide plate (lamina) at the back and an arch (arcus) in front and on the sides. The border of the lamina and its lateral surface bear articular fossae for uniting with the arytenoid and thyroid cartilages.

2. The **thyroid cartilage** (*cartilago thyroidea*) is the largest of the laryngeal cartilages; it is hyaline in structure and consists of **two laminae**, which fuse in front at an angle. The site of union of the laminae (the thyroid angle) in children and females is rounded and there is, therefore, no conspicuous prominence in them as in adult males (Adam's apple). In the superior border on the midline is the **thyroid notch** (*incisura thyroidea superius*). The posterior, thickened border of each plate is continuous with a larger

superior horn (*cornu superius*) and a **shorter inferior horn** (*cornu inferius*). The inferior horn bears on the inner surface of its apex an area for articulating with the cricoid cartilage. An **oblique line** (*linea obliqua*) is visible on the outer surface of each lamina; it descends from the posterior part of the superior border of the cartilage obliquely and medially (the site of attachment of the sternothyroid and thyrohyoid muscles).

3. **The arytenoid cartilages** (*cartilagine arytenoideae*) are directly related to the vocal cords and muscles. They are pyramidal in shape with the **base** (*basis*) sitting on the superior border of the cricoid cartilage while the **apex** faces upward. Of the **three surfaces** of the arytenoid cartilage, the **dorsal** is concave and the transverse arytenoid muscle lies on it. The **medial surface** is covered by the laryngeal mucosa. The **anterolateral surface** is the largest of the three surfaces. **Two processes** arise from the base: (1) an **anterior process** (of elastic cartilage) is the site of attachment of the vocal cord and is therefore called **vocal** (*processus vocalis*) and (2) a **lateral, muscular, process** (of hyaline cartilage) for the attachment of muscles (*processus muscularis*).

4. **The corniculate cartilages** (*cartilagine corniculatae*) are seated on the apices of the arytenoid cartilages in the thickness of the aryepiglottic folds.

5. **The cuneiform cartilages** (*cartilagine cuneiformes*) are directly in front of the corniculate cartilages, also in the aryepiglottic folds. Sometimes they are absent.

6. **The epiglottis cartilage** (*cartilago epiglottica*) is a leaf-shaped lamina of elastic cartilaginous tissue situated in front of aditus laryngis and directly behind the root of the tongue. It narrows downward to form the **stalk of the epiglottis** (*petiolus epiglottidis*). The opposite wide end faces upward. The convex-concave dorsal surface facing the larynx is entirely covered with mucous membrane; the inferior concave part protrudes into the laryngeal cavity and is called the **epiglottic tubercle** (*tuberculum epiglotticum*). The anterior, or ventral, surface facing the tongue has no ligaments attached to it only in its upper part.

LIGAMENTS AND JOINTS OF THE LARYNX

The larynx appears to be suspended from the hyoid bone on the **thyrohyoid membrane** (*membrana thyreochoidea*) stretching between this bone and the thyroid cartilage. The membrane consists of an unpaired **median thyrohyoid ligament** (*lig. thyreochoideum medianum*) and the paired **lateral thyrohyoid ligaments** (*ligamenta thyreochoidea*) stretched between the ends of greater horns of the hyoid bone and the superior horns of the thyroid cartilage in the thickness of which a **small cartilago triticea**, resembling a grain of wheat, is embedded. The hyoid bone is also connected with the epiglottis by the **hyoepiglottic ligament** (*lig. hyoepiglotticum*); the epiglottis is in turn attached to the thyroid cartilage by the **thyroepiglottic ligament** (*lig. thyreoepiglotticum*).

Between the arch of the cricoid cartilage and the margin of the thyroid cartilage stretches on the midline a strong **cricothyroid ligament** (*lig. cricothyroideum*) composed of elastic fibres. The lateral fibres arising from the superior margin of the cricoid cartilage pass medially and unite posteriorly with the arytenoid cartilage; these bundles together with the cricothyroid ligament form the **cricovocal membrane** (*comus elasticus*) which narrows toward the top; its superior free margin is the **vocal ligament** (*lig. Vocale*).

The **vocal ligament** (*lig. vocale*) is attached anteriorly to the angle of the thyroid cartilage in close vicinity to its contralateral fellow, and posteriorly to the vocal process of the arytenoid cartilage. The ligament is formed of yellowish elastic fibres passing parallel to one another. Children and young boys have in addition intersecting elastic fibres, which disappear in adults. The medial margin of the vocal ligament is pointed and free; laterally and downward the ligament is continuous with the cricovocal membrane mentioned above.

Above and parallel to the vocal ligament is the **paired vestibular ligament** (*lig. vestibulare*). It is so called because it bounds inferiorly the vestibule of the larynx.

Besides ligaments, there are **joints** between the cartilages at the junction of the thyroid and arytenoid cartilages with the cricoid cartilage.

1. **The paired combined cricothyroid joint** (art. cricothyroidea) forms between the inferior horns of the thyroid cartilage and the cricoid cartilage; it has a transverse pivotal axis. In this joint the thyroid cartilage moves forward and to the back, drawing further away from or coming nearer to the arytenoid cartilages. As a result the vocal ligament stretched between them is now tensed (when the thyroid cartilage is tilted forward), now relaxed.

2. **The paired cricoarytenoid joints** (*articulationes cricoarytenoideae*) form between the base of each arytenoid cartilage and the cricoid cartilage; it has a vertical axis about which the arytenoid cartilage

accomplishes lateral rotation. Sliding movements, with the arytenoid cartilages now coming together now moving apart, can also occur in this joint.

3. The corniculate cartilages articulate with the apices of the arytenoid cartilages by means of small joints or synchondroses (synchondrosis arycorniculata).

MUSCLES OF THE LARYNX

The muscles of the larynx move its cartilages and thus change the width of its cavity and the width of the rima glottidis bounded by the vocal ligaments. According to function, they may, therefore, be grouped as follows: (1) constrictors; (2) dilators; (3) muscles altering the tension of the vocal ligaments. Some of the muscles can be related to more than one group because of their mixed character.

The following muscles form the first group (1) constrictors.

1. The lateral cricoarytenoid muscle (*m. cricoarytenoideus lateralis*) originates on the arch of the cricoid cartilage, passes upward and to the back, and is inserted on the muscular process of the arytenoid cartilage. It pulls the muscular process forward and downward as the result of which the vocal process swings medially, the vocal ligaments approximate and the opening between them becomes narrower (in which instance the vocal ligaments are rather tensed).

2. The thyroarytenoid muscle (*m. thyrearytenoideus*) is quadrate in shape. It originates from the inner surface of the laminae of the thyroid cartilages, passes posteriorly and upward and is inserted into the muscular process of the arytenoid cartilage. On contraction of the muscles on both sides, the part of the laryngeal cavity directly above the vocal ligaments (regio supraglottica) narrows and at the same time the vocal process is pulled ventrally as the result of which the vocal ligaments slightly relax.

3. The transverse arytenoid muscle (*m. arytenoideus transversus*) is an unpaired muscle lying on the dorsal concave surfaces of the arytenoid cartilages. On contraction it approximates the arytenoid cartilages and thus narrows the posterior part of the rima glottidis.

4. The oblique arytenoid muscles (*mm. arytenoidei obliqui*) are a pair of muscle fascicles lying directly behind the transverse muscle and intersecting one another at an acute angle. At the apex of the arytenoid cartilage the oblique muscle is continuous with muscle fascicles, which pass forward and upward in the aryepiglottic fold and are inserted on the margin of the epiglottis, thus forming the aryepiglottic muscle. On simultaneous contraction, the oblique arytenoid and aryepiglottic muscles narrow the laryngeal inlet and vestibule. The aryepiglottic muscle also pulls the epiglottis downward.

(2) The group of dilators is formed of the following muscles.

1. The posterior cricoarytenoid muscle (*m. cricoarytenoideus posterior*) is triangular in shape. It lies on the dorsal surface of the lamina of the cricoid cartilage and is inserted on the muscular process. On contraction it pulls the muscular process posteriorly and medially so that the vocal process swings laterally and the rima glottidis becomes wider.

2. The thyroepiglottic muscle (*m. thyroepiglotticus*) is situated laterally of the thyroepiglottic ligament. It originates from the inner surface of the lamina of the thyroid cartilage and is inserted on the margin of the epiglottis and is partly continuous with the aryepiglottic fold. It acts as the dilator of the laryngeal inlet and vestibule.

(3) The muscles related to the group, which alters the **tensity of the vocal ligaments**, are as follows.

1. The cricothyroid muscle (*m. cricothyreoideus*) is short but rather thick. It arises from the arch of the cricoid cartilage and is inserted on the lamina and inferior horn of the thyroid cartilage. The cricothyroid muscle tenses the vocal ligaments by pulling the thyroid cartilage forward. As a result the distance between the cartilage and the vocal process of the arytenoid cartilage increases.

2. The vocalis muscle (*m. vocalis*) is embedded in the vocal fold and closely adjoins the vocal ligament. Its fibres blend laterally with the fibres of the thyroarytenoid muscle. It originates from the inferior part of the angle of the thyroid cartilage and, passing posteriorly, is inserted on the lateral surface of the vocal process. On contraction it pulls the vocal process forward causing the vocal ligaments to relax.

According to the latest data, the main constrictors of the rima glottidis are the cricothyroid muscles, while its main dilators are the posterior cricoarytenoid muscles. All these muscles are innervated from the vagus nerve, but from its different branches: the former from the superior and the latter from the inferior laryngeal nerves.

The transverse and oblique arytenoid and the lateral cricoarytenoid muscles are assistant muscles and each receives motor innervation from both of the above-named nerves.

In the group of muscles regulating the vocal ligaments, the vocal and thyroarytenoid muscles are relaxers, while the cricothyroid muscle is a tensor. They are innervated similarly, but from different laryngeal nerves: the relaxers from the inferior and the tensors from the superior laryngeal nerves.

Muscles regulating the mobility of the larynx, the aryepiglottic, oblique arytenoid, and thyroepiglottic, are innervated in the same manner as the assistant muscles, i.e. each is supplied with nerve fibres from the superior and inferior laryngeal nerves.

THE CAVITY OF THE LARYNX

The cavity of the larynx (*cavum laryngis*) opens by means of an **inlet of the larynx** (*aditus laryngis*) bounded anteriorly by the free margin of the epiglottis, posteriorly by the apices of the arytenoid cartilages and the fold of mucosa, **interarytenoid fold** (*plica interarytenoidea*) stretching between them, and laterally by mucosal folds stretched between the epiglottis and the arytenoid cartilages, **the aryepiglottic fold** (*plica aryepiglottica*). The cavity itself resembles an hourglass in shape; it is narrowed in the middle but expands upward and downward. **The upper**, expanded part of the cavity is called **the vestibule of the larynx** (*vestibulum laryngis*). It extends from the laryngeal inlet to a paired mucosal fold on the lateral wall of the cavity; this is **the vestibular fold** (*plica vestibularis*), or **the false vocal cord**, in the thickness of which is the vestibular ligament. The walls of the vestibule are formed: anteriorly, by the dorsal surface of the epiglottis, posteriorly, by the upper parts of the arytenoid cartilages and the interarytenoid fold, and laterally, by a paired **elastic membrane of the larynx** (*membrana fibroelastica laryngis*) extending from the vestibular fold to the aryepiglottic fold.

The middle, constricted part of the laryngeal cavity is most complex in structure. It is bounded above and below by mucosal folds situated on the lateral walls of the larynx. The upper fold is the paired vestibular fold mentioned above. The free margins of these folds form the boundaries of an unpaired rather wide rima vestibuli. The lower, **vocal fold** (*plica vocalis*), or **true vocal cord**, protrudes into the cavity more than the upper fold does and contains the vocal ligament and the vocal muscle. The recess between the vestibular and vocal folds is **the sinus of the larynx** (*ventriculus laryngis*).

A sagittally lying **fissure of the glottis**, *rima glottidis*, is formed between the two vocal folds; it is the narrowest part of the laryngeal cavity. In it are distinguished an anterior, larger part between the folds themselves, the intermembranous part (*pars intermembranacea*), and a posterior, smaller one, between the vocal processes of the arytenoid cartilage, the intercartilaginous part (*pars intercartilaginea*).

The lower expanded part of the larynx, **the infraglottic cavity** (*cavum infraglotticum*) gradually narrows inferiorly and is continuous with the trachea.

The shape of the rima glottidis and the changes in it can be seen in a live person during laryngoscopy (examination of the larynx with a laryngeal mirror). During the act of phonation (the formation of vocal sounds), the intermembranous part takes the shape of a narrow fissure, while the intercartilaginous part becomes triangular; in quiet breathing, the intermembranous part widens and the whole rima glottidis is shaped like a triangle with the base lying between the arytenoid cartilages. On inspection, the laryngeal mucosa is smooth, evenly pink, and with no changes in its relief or mobility. In the region of the vocal cords the mucosa is pink, in the region of the vestibular folds it is reddish.

The laryngeal mucosa above the vocal cords is highly sensitive; a foreign body coming in touch with it induces immediately a reaction in the form of severe coughing.

Vocal sounds are produced during expiration as the result of vibration of the vocal cords. Until recently it was thought that the vocal cords vibrate under the effect of the respiratory air stream absolutely passively, just like a flag waving in the wind. It has been recently established, however, that due to the close relationship with the vocal muscle the human vocal cords contract actively under the effect of rhythmic impulses arriving along nerves from the cerebral centres with sound frequency. It is not that the air causes vibration of the vocal cords, on the contrary, it is the vocal cords that on vibrating rhythmically impart the air stream a vibrating character.

The sound produced by the vocal cords has, in addition to the main tone, a series of overtones. This "cord-produced" tone, however, still in no way resembles the sounds of a voice; the voice acquires the natural human timbre only due to a system of resonators. Since nature is a very economical constructor, the role of the resonators is played by the different air cavities of the respiratory tract, which surround the vocal cords. The larynx and the oral cavity are the most important resonators.

TOPOGRAPHY, PROJECTION AND EXAMINATION OF THE LARYNX ON ALIVE PERSON

In adults the larynx projects in the median region of the neck in the area limited by two horizontal planes:

- The **upper horizontal plane** passes at the level of the IV cervical vertebra.
- The **lower one** passes at the level of the VI or VII cervical vertebrae.

The prominence of the larynx is well seen on the median plane of the neck and it is more prominent in men.

Above the area of projection of the larynx, projects the hyoid bone and below it at a distance of 1.5 - 2 cm projects the upper border of the thyroid cartilage. On the both lateral parts of the thyroid angle can be palpated the lamellae of the thyroid cartilage and its horns, and a little lower can be palpated the arch of the cricoid cartilage.

AGE PECULIARITIES OF THE LARYNX

The larynx in new born is short, wide, funnel-like in shape and is situated higher then in adult. It is located at the level of the II-IV cervical vertebrae. The hyoid bone as well has a higher position then in adult. The larynx is not prominent. The epiglottis is located higher then the root of the tongue and this fact is important during sucking, because the milk from the oral cavity passes into the oesophagus through the piriform recesses of the pharynx and the child can breath and eat at the same time. The inlet of the larynx is larger then in adult. The vestibule of the larynx is short and the *rima glottidis* has a higher position. The elastic conus is narrow and short. The muscles of the larynx in new born are slightly developed. The larynx grows intensively during the first 4 years of age. As well an intensive growth is characteristic for period of puberty. At 17-20 years old the larynx obtains the position characteristic for adults. In men the larynx is more prominent, but in women it is more rounded shaped. The vocal folds in men are longer then in women. The cartilages of the larynx are thinner in new born, but become thicker with the growth of the person. In old people the cartilages ossify and become fragile.

Capitulum IV. THE SCIENCE OF THE VESSELS (ANGIOLOGY)

BRANCHES OF THE ARCH OF THE AORTA

The concavity of the aortic border gives off arteries to the bronchi and thymus, whereas the convexity gives rise to three trunks, which stretch upward. From right to left, these are the truncus brachiocephalicus s. a. anonyma, a. carotis communis sinistra, and a. subclavia sinistra.

THE BRACHIOCEPHALIC TRUNK

The brachiocephalic trunk, innominate artery (*truncus brachiocephalicus*), about 3-4 cm in length, is a remnant of the embryonic right ventral aorta. It runs obliquely upward, backward, and to the right, anteriorly of the trachea, where it gives off a branch to the thyroid gland, **a. thyroidea ima** (*the lowest thyroid artery*), and divides behind the right sternoclavicular joint into its terminal branches, the right common carotid and right subclavian arteries.

THE COMMON CAROTID ARTERY

The common carotid artery (*a. carotis communis*) (Gk *kayos* heavy sleep), develops from the ventral aorta between the third and fourth branchial arteries. It arises from the brachiocephalic trunk on the right and independently from the arch of the aorta on the left side. Both common carotid arteries run upward on the side of the trachea and oesophagus. The right common carotid artery consists only of a cervical section and is, thus, shorter than the left, which consists of a thoracic section (from the arch of the aorta to the left sternoclavicular joint) and a cervical section. The common carotid artery passes in the trigonum caroticum and, at the level of the superior border of the thyroid cartilage or body of the hyoid bone, divides into its terminal branches, **the external and internal carotid arteries** (*a. carotis extern and a. carotis interna*) (**bifurcation**). To arrest bleeding, the common carotid artery is pressed to the tuberculum caroticum of the sixth cervical vertebra at the level of the inferior border of the cricoid cartilage. Sometimes the external and internal carotid arteries arise not from a common trunk but separately from the aorta, which reflects the character of their development. Along its entire length the common carotid artery gives off small branches to the surrounding vessels and nerves (**vasa vasorum** and **vasa nervorum**), which may play a role in the development of collateral circulation on the neck.

THE EXTERNAL CAROTID ARTERY

The external carotid artery begins opposite the upper border of the thyroid cartilage, and, taking a slightly curved course, passes upward and forward, and then inclines backward to the space behind the neck of the mandible, where it divides into the superficial temporal and maxillary arteries. It rapidly diminishes in size in its course up the neck, owing to the number and large size of the branches given off from it. In the child, it is somewhat smaller than the internal carotid; but in the adult, the two vessels are of nearly equal size. At its origin, this artery is more superficial, and placed nearer the middle line than the internal carotid, and is contained within the carotid triangle.

Relations.—The external carotid artery is *covered by* the skin, superficial fascia, Platysma, deep fascia, and anterior margin of the Sternocleidomastoideus; it is crossed by the hypoglossal nerve, by the lingual, ranine, common facial, and superior thyroid veins; and by the Digastricus and Stylohyoideus; higher up it passes deeply into the substance of the parotid gland, where it lies deep to the facial nerve and the junction of the temporal and maxillary veins. *Medial* to it are the hyoid bone, the wall of the pharynx, the superior laryngeal nerve, and a portion of the parotid gland. *Lateral* to it, in the lower part of its course, is the internal carotid artery. *Posterior* to it, near its origin, is the superior laryngeal nerve; and higher up, it is separated from the internal carotid by the styloglossus and Stylopharyngeus, the glossopharyngeal nerve, the pharyngeal branch of the vagus, and part of the parotid gland.

Branches.—The branches of the external carotid artery may be divided into four sets.

<i>Anterior</i>	<i>Posterior</i>	<i>Ascending</i>	<i>Terminal</i>
Superior Thyroid	Occipital	Ascending Pharyngeal	Superficial Temporal
Lingual	Posterior Auricular		Maxillary
Facial			

1. The superior thyroid artery (*a. thyroidea superior*) arises from the external carotid artery just below the level of the greater cornu of the hyoid bone and ends in the thyroid gland.

Relations.—From its origin under the anterior border of the Sternocleidomastoideus it runs upward and forward for a short distance in the carotid triangle, where it is covered by the skin, Platysma, and fascia; it then arches downward beneath the Omohyoideus, Sternohyoideus, and Sternothyroideus. To its medial side are the Constrictor pharyngis inferior and the external branch of the superior laryngeal nerve.

Branches.—It distributes twigs to the adjacent muscles, and numerous branches to the thyroid gland, anastomosing with its fellow of the opposite side, and with the inferior thyroid arteries. The branches to the gland are generally two in number; one, the larger, supplies principally the anterior surface; on the isthmus of the gland it anastomoses with the corresponding artery of the opposite side; a second branch descends on the posterior surface of the gland and anastomoses with the inferior thyroid artery.

Besides the arteries distributed to the muscles and to the thyroid gland, the branches of the superior thyroid are:

- The **Hyoid Branch** (*ramus hyoideus; infrahyoid branch*) is small and runs along the lower border of the hyoid bone beneath the Thyreohyoideus and anastomoses with the vessel of the opposite side.

- The **Sternocleidomastoid Branch** (*ramus sternocleidomastoideus; sternomastoid branch*) runs downward and lateralward across the sheath of the common carotid artery, and supplies the Sternocleidomastoideus and neighboring muscles and integument; it frequently arises as a separate branch from the external carotid.

- The **Superior Laryngeal Artery** (*a. laryngea superior*), larger than either of the preceding, accompanies the internal laryngeal branch of the superior laryngeal nerve, beneath the Thyreohyoideus; it pierces the hyothyroid membrane, and supplies the muscles, mucous membrane, and glands of the larynx, anastomosing with the branch from the opposite side.

- The **Cricothyroid Branch** (*ramus cricothyroideus*) is small and runs transversely across the cricothyroid membrane, communicating with the artery of the opposite side.

2. The lingual artery (*a. lingualis*) arises from the external carotid between the superior thyroid and Facial; it first runs obliquely upward and medialward to the greater cornu of the hyoid bone; it then curves downward and forward, forming a loop which is crossed by the hypoglossal nerve, and passing beneath the Digastricus and Stylohyoideus it runs horizontally forward, beneath the Hyoglossus, and finally, ascending almost perpendicularly to the tongue, turns forward on its lower surface as far as the tip, under the name of the **profunda linguae**.

Relations.—Its first, or oblique, portion is superficial, and is contained within the carotid triangle; it rests upon the Constrictor pharyngis medius, and is covered by the Platysma and the fascia of the neck. Its second, or curved, portion also lies upon the Constrictor pharyngis medius, being covered at first by the tendon of the Digastricus and by the Stylohyoideus, and afterward by the Hyoglossus. Its third, or horizontal, portion lies between the Hyoglossus and Genioglossus. The fourth, or terminal part, under the name of the **profunda linguae** (*ramine artery*) runs along the under surface of the tongue to its tip; here it is superficial, being covered only by the mucous membrane; above it is the Longitudinalis inferior, and on the medial side the m. Genioglossus. The hypoglossal nerve crosses the first part of the lingual artery, but is separated from the second part by the m. Hyoglossus.

Branches.—The branches of the lingual artery are:

- The **Hyoid Branch** (*ramus hyoideus; suprahyoid branch*) runs along the upper border of the hyoid bone, supplying the muscles attached to it and anastomosing with its fellow of the opposite side.

- The **Arteriaes Dorsales Linguae** (*rami dorsales linguae*) consist usually of two or three small branches which arise beneath the Hyoglossus; they ascend to the back part of the dorsum of the tongue, and supply the mucous membrane in this situation, the glossopalatine arch, the tonsil, soft palate, and epiglottis; anastomosing with the vessels of the opposite side.

- The **Sublingual Artery** (*a. sublingualis*) arises at the anterior margin of the Hyoglossus, and runs forward between the Genioglossus and Mylohyoideus to the sublingual gland. It supplies the gland and

gives branches to the Mylohyoideus and neighboring muscles, and to the mucous membrane of the mouth and gums. One branch runs behind the alveolar process of the mandible in the substance of the gum to anastomose with a similar artery from the other side; another pierces the Mylohyoideus and anastomoses with the submental branch of the Facial artery.

- The **Arteria Profunda Linguae** (*ranine artery; deep lingual artery*) is the terminal portion of the lingual artery; it pursues a tortuous course and runs along the under surface of the tongue, below the Longitudinalis inferior, and above the mucous membrane; it lies on the lateral side of the Genioglossus, accompanied by the lingual nerve. At the tip of the tongue, it is said to anastomose with the artery of the opposite side, but this is denied by Hyrtl. In the mouth, these vessels are placed one on either side of the frenulum linguae.

3. The Facial artery (*a. facial artery*), arises in the carotid triangle a little above the lingual artery and, sheltered by the ramus of the mandible, passes obliquely up beneath the Digastricus and Stylohyoideus, over which it arches to enter a groove on the posterior surface of the submandibular gland. It then curves upward over the body of the mandible at the antero-inferior angle of the Masseter; passes forward and upward across the cheek to the angle of the mouth, then ascends along the side of the nose, and ends at the medial commissure of the eye, under the name of the **angular artery**. This vessel, both in the neck and on the face, is remarkably tortuous: in the former situation, to accommodate itself to the movements of the pharynx in deglutition; and in the latter, to the movements of the mandible, lips, and cheeks.

Relations.—*In the neck*, its origin is superficial, being covered by the integument, Platysma, and fascia; it then passes beneath the Digastricus and Stylohyoideus muscles and part of the submandibular gland, and frequently beneath the hypoglossal nerve. It lies upon the Constrictores pharyngis medius and superior, the latter of which separates it, at the summit of its arch, from the lower and back part of the tonsil. *On the face*, where it passes over the body of the mandible, it is comparatively superficial, lying immediately beneath the Platysma. In its course over the face, it is covered by the integument, the fat of the cheek, and, near the angle of the mouth, by the Platysma, Risorius, and Zygomaticus. It rests on the Buccinator and Caninus, and passes either over or under the infraorbital head of the Quadratus labii superioris. The anterior facial vein lies lateral to the artery, and takes a more direct course across the face, where it is separated from the artery by a considerable interval. In the neck it lies superficial to the artery. The branches of the facial nerve cross the artery from behind forward.

Branches.—The branches of the artery may be divided into two sets: those given off in the neck (*cervical*), and those on the face (*facial*).

- The **Ascending Palatine Artery** (*a. palatina ascendens*) arises close to the origin of the Facial artery and passes up between the Styloglossus and Stylopharyngeus to the side of the pharynx, along which it is continued between the Constrictor pharyngis superior and the Pterygoideus medialis to near the base of the skull. It divides near the Levator veli palatini into two branches: one follows the course of this muscle, and, winding over the upper border of the Constrictor pharyngis superior, supplies the soft palate and the palatine glands, anastomosing with its fellow of the opposite side and with the descending palatine branch of the maxillary artery; the other pierces the Constrictor pharyngis superior and supplies the palatine tonsil and auditory tube, anastomosing with the tonsillar and ascending pharyngeal arteries.

- The **Tonsillar Branch** (*ramus tonsillaris*) ascends between the Pterygoideus medialis and Styloglossus, and then along the side of the pharynx, perforating the Constrictor pharyngis superior, to ramify in the substance of the palatine tonsil and root of the tongue.

- The **Glandular Branches** (*rami glandulares; submaxillary branches*) consist of three or four large vessels, which supply the submandibular gland, some being prolonged to the neighboring muscles, lymph glands, and integument.

- The **Submental Artery** (*a. submentalis*) the largest of the cervical branches, is given off from the facial artery just as that vessel quits the submandibular gland: it runs forward upon the Mylohyoideus, just below the body of the mandible, and beneath the Digastricus. It supplies the surrounding muscles, and anastomoses with the sublingual artery and with the mylohyoid branch of the inferior alveolar; at the symphysis menti it turns upward over the border of the mandible and divides into a superficial and a deep branch. The superficial branch passes between the integument and Quadratus labii inferioris, and anastomoses with the inferior labial artery; the deep branch runs between the muscle and the bone, supplies the lip, and anastomoses with the inferior labial and mental arteries.

- The **Inferior Labial Artery** (*a. labialis inferior; inferior coronary artery*) arises near the angle of the mouth; it passes upward and forward beneath the Triangularis and, penetrating the Orbicularis oris, runs in a tortuous course along the edge of the lower lip between this muscle and the mucous membrane. It supplies the labial glands, the mucous membrane, and the muscles of the lower lip; and anastomoses with the artery of the opposite side, and with the mental branch of the inferior alveolar artery.

- The **Superior Labial Artery** (*a. labialis superior; superior coronary artery*) is larger and more tortuous than the inferior. It follows a similar course along the edge of the upper lip, lying between the mucous membrane and the Orbicularis oris, and anastomoses with the artery of the opposite side. It supplies the upper lip, and gives off in its course two or three vessels which ascend to the nose; a **septal branch** ramifies on the nasal septum as far as the point of the nose, and an **alar branch** supplies the ala of the nose.

- The **Lateral Nasal branch** is derived from the Facial as that vessel ascends along the side of the nose. It supplies the ala and dorsum of the nose, anastomosing with its fellow, with the septal and alar branches, with the dorsal nasal branch of the ophthalmic, and with the infraorbital branch of the maxillary.

- The **Angular Artery** (*a. angularis*) is the terminal part of the Facial; it ascends to the medial angle of the orbit, imbedded in the fibers of the angular head of the Quadratus labij superioris, and accompanied by the angular vein. On the cheek it distributes branches which anastomose with the infraorbital; after supplying the lacrimal sac and Orbicularis oculi, it ends by anastomosing with the dorsal nasal branch of the ophthalmic artery.

- The **Muscular Branches** in the neck are distributed to the Pterygoideus medialis and Stylohyoideus, and on the face to the Masseter and Buccinator. The anastomoses of the Facial artery are very numerous, not only with the vessel of the opposite side, but, *in the neck*, with the sublingual branch of the lingual, with the ascending pharyngeal, and by its ascending palatine and tonsillar branches with the palatine branch of the maxillary; *on the face*, with the mental branch of the inferior alveolar as it emerges from the mental foramen, with the transverse facial branch of the superficial temporal, with the infraorbital branch of the maxillary, and with the dorsal nasal branch of the ophthalmic.

Peculiarities.—The Facial artery not infrequently arises in common with the lingual. It varies in its size and in the extent to which it supplies the face; it occasionally ends as the submental, and not infrequently extends only as high as the angle of the mouth or nose. The deficiency is then compensated for by enlargement of one of the neighboring arteries.

4. The **occipital artery** (*a. occipitalis*) arises from the posterior part of the external carotid, opposite the Facial, near the lower margin of the posterior belly of the Digastricus, and ends in the posterior part of the scalp.

Course and Relations.—At its origin, it is covered by the posterior belly of the Digastricus and the Stylohyoideus, and the hypoglossal nerve winds around it from behind forward; higher up, it crosses the internal carotid artery, the internal jugular vein, and the vagus and accessory nerves. It next ascends to the interval between the transverse process of the atlas and the mastoid process of the temporal bone, and passes horizontally backward, grooving the surface of the latter bone, being covered by the Sternocleidomastoideus, Splenius capitis, Longissimus capitis, and Digastricus, and resting upon the Rectus capitis lateralis, the Obliquus superior, and Semispinalis capitis. It then changes its course and runs vertically upward, pierces the fascia connecting the cranial attachment of the Trapezius with the Sternocleidomastoideus, and ascends in a tortuous course in the superficial fascia of the scalp, where it divides into numerous branches, which reach as high as the vertex of the skull and anastomose with the posterior auricular and superficial temporal arteries. Its terminal portion is accompanied by the greater occipital nerve.

Branches.—The branches of the occipital artery are:

- The **Muscular Branches** (*rami musculares*) supply the Digastricus, Stylohyoideus, Splenius, and Longissimus capitis.

- The **Sternocleidomastoid Artery** (*a. sternocleidomastoidea; sternomastoid artery*) generally arises from the occipital close to its commencement, but sometimes springs directly from the external carotid. It passes downward and backward over the hypoglossal nerve, and enters the substance of the muscle, in company with the accessory nerve.

- The **Auricular Branch** (*ramus auricularis*) supplies the back of the concha and frequently gives off a branch, which enters the skull through the mastoid foramen and supplies the dura mater, the diploë,

and the mastoid cells; this latter branch sometimes arises from the occipital artery, and is then known as the **mastoid branch**.

- The **Meningeal Branch** (*ramus meningeus; dural branch*) ascends with the internal jugular vein, and enters the skull through the jugular foramen and condyloid canal, to supply the dura mater in the posterior fossa.

- The **Descending Branch** (*ramus descendens; arteria princeps cervicis*), the largest branch of the occipital, descends on the back of the neck, and divides into a superficial and deep portion. The superficial portion runs beneath the Splenius, giving off branches which pierce that muscle to supply the Trapezius and anastomose with the ascending branch of the transverse cervical: the deep portion runs down between the Semispinales capitis and colli, and anastomoses with the vertebral and with the a. profunda cervicalis, a branch of the costocervical trunk. The anastomosis between these vessels assists in establishing the collateral circulation after ligation of the common carotid or subclavian artery.

- The terminal branches of the occipital artery are distributed to the back of the head: they are very tortuous, and lie between the integument and Occipitalis, anastomosing with the artery of the opposite side and with the posterior auricular and temporal arteries, and supplying the Occipitalis, the integument, and pericranium. One of the terminal branches may give off a meningeal twig which passes through the parietal foramen.

5. The posterior auricular artery (*a. auricularis posterior*) is small and arises from the external carotid, above the Digastricus and Stylohyoideus, opposite the apex of the styloid process. It ascends, under cover of the parotid gland, on the styloid process of the temporal bone, to the groove between the cartilage of the ear and the mastoid process, immediately above which it divides into its auricular and occipital branches.

Branches.—Besides several small branches to the Digastricus, Stylohyoideus, and Sternocleidomastoideus, and to the parotid gland, this vessel gives off three branches:

- The **Stylomastoid Artery** (*a. stylomastoidea*) enters the stylomastoid foramen and supplies the tympanic cavity, the tympanic antrum and mastoid cells, and the semicircular canals. In the young subject a branch from this vessel forms, with the anterior tympanic artery from the maxillary, a vascular circle, this surrounds the tympanic membrane, and from which delicate vessels ramify on that membrane. It anastomoses with the superficial petrosal branch of the middle meningeal artery by a twig which enters the hiatus canalis facialis.

- The **Auricular Branch** (*ramus auricularis*) ascends behind the ear, beneath the Auricularis posterior, and is distributed to the back of the auricula, upon which it ramifies minutely, some branches curving around the margin of the cartilage, others perforating it, to supply the anterior surface. It anastomoses with the parietal and anterior auricular branches of the superficial temporal.

- The **Occipital Branch** (*ramus occipitalis*) passes backward, over the Sternocleidomastoideus, to the scalp above and behind the ear. It supplies the Occipitalis and the scalp in this situation and anastomoses with the occipital artery.

6. The ascending pharyngeal artery (*a. pharyngea ascendens*), the smallest branch of the external carotid, is a long, slender vessel, deeply seated in the neck, beneath the other branches of the external carotid and under the Stylopharyngeus. It arises from the back part of the external carotid, near the commencement of that vessel, and ascends vertically between the internal carotid and the side of the pharynx, to the under surface of the base of the skull, lying on the Longus capitis.

Branches.—Its branches are:

- The **Pharyngeal Branches** (*rami pharyngei*) are three or four in number. Two of these descend to supply the Constrictores pharyngis medius and inferior and the Stylopharyngeus, ramifying in their substance and in the mucous membrane lining them.

- The **Palatine Branch** varies in size, and may take the place of the ascending palatine branch of the facial artery, when that vessel is small. It passes inward upon the Constrictor pharyngis superior, sends ramifications to the soft palate and tonsil, and supplies a branch to the auditory tube.

- The **Prevertebral Branches** are numerous small vessels, which supply the Longi capitis and colli, the sympathetic trunk, the hypoglossal and vagus nerves, and the lymph glands; they anastomose with the ascending cervical artery.

- The **Inferior Tympanic Artery** (*a. tympanica inferior*) is a small branch which passes through a minute foramen in the petrous portion of the temporal bone, in company with the tympanic branch of the

glossopharyngeal nerve, to supply the medial wall of the tympanic cavity and anastomose with the other tympanic arteries.

- The **Meningeal Branches** are several small vessels, which supply the dura mater. One, the **posterior meningeal**, enters the cranium through the jugular foramen; a second passes through the foramen lacerum; and occasionally a third through the canal for the hypoglossal nerve.

7. The **superficial temporal artery** (*a. temporalis superficialis*), the smaller of the two terminal branches of the external carotid, appears, from its direction, to be the continuation of that vessel. It begins in the substance of the parotid gland, behind the neck of the mandible, and crosses over the posterior root of the zygomatic process of the temporal bone; about 5 cm. above this process it divides into two branches, a frontal and a parietal.

Relations.—As it crosses the zygomatic process, it is covered by the Auricularis anterior muscle, and by a dense fascia; it is crossed by the temporal and zygomatic branches of the facial nerve and one or two veins, and is accompanied by the auriculotemporal nerve, which lies immediately behind it.

Branches.—Besides some twigs to the parotid gland, to the temporomandibular joint, and to the Masseter muscle, its branches are:

- The **Transverse Facial Artery** (*a. transversa faciei*) is given off from the superficial temporal before that vessel quits the parotid gland; running forward through the substance of the gland, it passes transversely across the side of the face, between the parotid duct and the lower border of the zygomatic arch, and divides into numerous branches, which supply the parotid gland and duct, the Masseter, and the integument, and anastomose with the Facial, masseteric, buccinator, and infraorbital arteries. This vessel rests on the Masseter, and is accompanied by one or two branches of the facial nerve.

- The **Middle Temporal Artery** (*a. temporalis media*) arises immediately above the zygomatic arch, and, perforating the temporal fascia, gives branches to the Temporalis, anastomosing with the deep temporal branches of the maxillary. It occasionally gives off a **zygomaticoorbital branch**, which runs along the upper border of the zygomatic arch, between the two layers of the temporal fascia, to the lateral angle of the orbit. This branch, which may arise directly from the superficial temporal artery, supplies the Orbicularis oculi, and anastomoses with the lacrimal and palpebral branches of the ophthalmic artery.

- The **Anterior Auricular Branches** (*rami auriculares anteriores*) are distributed to the anterior portion of the auricula, the lobule, and part of the external meatus, anastomosing with the posterior auricular.

- The **Frontal Branch** (*ramus frontalis; anterior temporal*) runs tortuously upward and forward to the forehead, supplying the muscles, integument, and pericranium in this region, and anastomosing with the supraorbital and frontal arteries.

- The **Parietal Branch** (*ramus parietalis; posterior temporal*) larger than the frontal, curves upward and backward on the side of the head, lying superficial to the temporal fascia, and anastomosing with its fellow of the opposite side, and with the posterior auricular and occipital arteries.

8. The **maxillary artery** (*a. maxillaris*), the larger of the two terminal branches of the external carotid, arises behind the neck of the mandible, and is at first imbedded in the substance of the parotid gland; it passes forward between the ramus of the mandible and the sphenomandibular ligament, and then runs, either superficial or deep to the Pterygoideus lateralis, to the pterygopalatine fossa. It supplies the deep structures of the face, and may be divided into **mandibular, pterygoid, and pterygopalatine portions**.

The **first or mandibular portion** passes horizontally forward, between the ramus of the mandible and the sphenomandibular ligament, where it lies parallel to and a little below the auriculotemporal nerve; it crosses the inferior alveolar nerve, and runs along the lower border of the Pterygoideus lateralis.

The **second or pterygoid portion** runs obliquely forward and upward under cover of the ramus of the mandible and insertion of the Temporalis, on the superficial (very frequently on the deep) surface of the Pterygoideus lateralis; it then passes between the two heads of origin of this muscle and enters the fossa.

The **third or pterygopalatine portion** lies in the pterygopalatine fossa in relation with the sphenopalatine ganglion.

Branches of the First or Mandibular Portions.

- The **Anterior Tympanic Artery** (*a. tympanica anterior; tympanic artery*) passes upward behind the temporomandibular articulation, enters the tympanic cavity through the petrotympanic fissure, and ramifies upon the tympanic membrane, forming a vascular circle around the membrane with the stylomas-

toid branch of the posterior auricular, and anastomosing with the artery of the pterygoid canal and with the caroticotympanic branch from the internal carotid.

- The **Deep Auricular Artery** (*a. auricularis profunda*) often arises in common with the preceding. It ascends in the substance of the parotid gland, behind the temporomandibular articulation, pierces the cartilaginous or bony wall of the external acoustic meatus, and supplies its cuticular lining and the outer surface of the tympanic membrane. It gives a branch to the temporomandibular joint.

- The **Middle Meningeal Artery** (*a. meningea media; medidural artery*) is the largest of the arteries which supply the dura mater. It ascends between the sphenomandibular ligament and the Pterygoideus lateralis, and between the two roots of the auriculotemporal nerve to the foramen spinosum of the sphenoid bone, through which it enters the cranium; it then runs forward in a groove on the great wing of the sphenoid bone, and divides into two branches, anterior and posterior. The **anterior branch**, the larger, crosses the great wing of the sphenoid, reaches the groove, or canal, in the sphenoidal angle of the parietal bone, and then divides into branches which spread out between the dura mater and internal surface of the cranium, some passing upward as far as the vertex, and others backward to the occipital region. The **posterior branch** curves backward on the squama of the temporal bone, and, reaching the parietal some distance in front of its mastoid angle, divides into branches which supply the posterior part of the dura mater and cranium. The branches of the middle meningeal artery are distributed partly to the dura mater, but chiefly to the bones; they anastomose with the arteries of the opposite side, and with the anterior and posterior meningeal.

- The middle meningeal on entering the cranium gives off the following branches: (1) Numerous small vessels supply the semilunar ganglion and the dura mater in this situation. (2) A **superficial petrosal branch** enters the hiatus of the facial canal, supplies the facial nerve, and anastomoses with the stylomastoid branch of the posterior auricular artery. (3) A **superior tympanic artery** runs in the canal for the Tensor tympani, and supplies this muscle and the lining membrane of the canal. (4) **Orbital branches** pass through the superior orbital fissure or through separate canals in the great wing of the sphenoid, to anastomose with the lacrimal or other branches of the ophthalmic artery. (5) **Temporal branches** pass through foramina in the great wing of the sphenoid, and anastomose in the temporal fossa with the deep temporal arteries.

- The **Accessory Meningeal Branch** (*ramus meningeus accessorius; small meningeal or parvidural branch*) is sometimes derived from the preceding. It enters the skull through the foramen ovale, and supplies the semilunar ganglion and dura mater.

- The **Inferior Alveolar Artery** (*a. alveolaris inferior; inferior dental artery*) descends with the inferior alveolar nerve to the mandibular foramen on the medial surface of the ramus of the mandible. It runs along the mandibular canal in the substance of the bone, accompanied by the nerve, and opposite the first premolar tooth divides into two branches, incisor and mental. The **incisor branch** is continued forward beneath the incisor teeth as far as the middle line, where it anastomoses with the artery of the opposite side; the **mental branch** escapes with the nerve at the mental foramen, supplies the chin, and anastomoses with the submental and inferior labial arteries. Near its origin the inferior alveolar artery gives off a **lingual branch** which descends with the lingual nerve and supplies the mucous membrane of the mouth. As the inferior alveolar artery enters the foramen, it gives off a **mylohyoid branch** which runs in the mylohyoid groove, and ramifies on the under surface of the Mylohyoideus. The inferior alveolar artery and its incisor branch during their course through the substance of the bone give off a few twigs which are lost in the cancellous tissue, and a series of branches which correspond in number to the roots of the teeth: these enter the minute apertures at the extremities of the roots, and supply the pulp of the teeth.

Branches of the Second or Pterygoid Portion.

- The **Deep Temporal Branches**, two in number, **anterior** and **posterior**, ascend between the Temporalis and the pericranium; they supply the muscle, and anastomose with the middle temporal artery; the anterior communicates with the lacrimal artery by means of small branches which perforate the zygomatic bone and great wing of the sphenoid.

- The **Pterygoid Branches** (*rami pterygoidei*), irregular in their number and origin, supply the Pterygoidei.

- The **Masseteric Artery** (*a. masseterica*) is small and passes lateralward through the mandibular notch to the deep surface of the Masseter. It supplies the muscle, and anastomoses with the masseteric branches of the Facial and with the transverse facial artery.

- The **Buccinator Artery** (*a. buccinatoria; buccal artery*) is small and runs obliquely forward, between the Pterygoideus medialis and the insertion of the Temporalis, to the outer surface of the Buccinator, to which it is distributed, anastomosing with branches of the Facial and with the infraorbital.

Branches of the Third or Pterygopalatine Portion.

- The **Posterior Superior Alveolar Artery** (*a. alveolaris superior posterior; alveolar or posterior dental artery*) is given off from the maxillary, frequently in conjunction with the infraorbital just as the trunk of the vessel is passing into the pterygopalatine fossa. Descending upon the tuberosity of the maxilla, it divides into numerous branches, some of which enter the alveolar canals, to supply the molar and premolar teeth and the lining of the maxillary sinus, while others are continued forward on the alveolar process to supply the gums.

- The **Infraorbital Artery** (*a. infraorbitalis*) appears, from its direction, to be the continuation of the trunk of the maxillary, but often *arises* in conjunction with the posterior superior alveolar. It runs along the infraorbital groove and canal with the infraorbital nerve, and emerges on the face through the infraorbital foramen, beneath the infraorbital head of the Quadratus labii superioris. While in the canal, it gives off (*a*) **orbital branches** which assist in supplying the Rectus inferior and Obliquus inferior and the lacrimal sac, and (*b*) **anterior superior alveolar branches** which descend through the anterior alveolar canals to supply the upper incisor and canine teeth and the mucous membrane of the maxillary sinus. On the face, some branches pass upward to the medial angle of the orbit and the lacrimal sac, anastomosing with the angular branch of the Facial artery; others run toward the nose, anastomosing with the dorsal nasal branch of the ophthalmic; and others descend between the Quadratus labii superioris and the Caninus, and anastomose with the Facial, transverse facial, and buccinator arteries. The four remaining branches *arise* from that portion of the maxillary which is contained in the pterygopalatine fossa.

- The **Descending Palatine Artery** (*a. palatina descendens*) descends through the pterygopalatine canal with the anterior palatine branch of the sphenopalatine ganglion, and, emerging from the greater palatine foramen, runs forward in a groove on the medial side of the alveolar border of the hard palate to the incisive canal; the terminal branch of the artery passes upward through this canal to anastomose with the sphenopalatine artery. Branches are distributed to the gums, the palatine glands, and the mucous membrane of the roof of the mouth; while in the pterygopalatine canal it gives off twigs which descend in the lesser palatine canals to supply the soft palate and palatine tonsil, anastomosing with the ascending palatine artery.

- The **Artery of the Pterygoid Canal** (*a. canalis pterygoidei; Vidian artery*) passes backward along the pterygoid canal with the corresponding nerve. It is distributed to the upper part of the pharynx and to the auditory tube, sending into the tympanic cavity a small branch which anastomoses with the other tympanic arteries.

- The **Pharyngeal Branch** is very small; it runs backward through the pharyngeal canal with the pharyngeal nerve, and is distributed to the upper part of the pharynx and to the auditory tube.

- The **Sphenopalatine Artery** (*a. sphenopalatina; nasopalatine artery*) passes through the sphenopalatine foramen into the cavity of the nose, at the back part of the superior meatus. Here it gives off its **posterior lateral nasal branches** which spread forward over the conchac and meatuses, anastomose with the ethmoidal arteries and the nasal branches of the descending palatine, and assist in supplying the frontal, maxillary, ethmoidal, and sphenoidal sinuses. Crossing the under surface of the sphenoid the sphenopalatine artery ends on the nasal septum as the **posterior septal branches**; these anastomose with the ethmoidal arteries and the septal branch of the superior labial; one branch descends in a groove on the vomer to the incisive canal and anastomoses with the descending palatine artery.

THE INTERNAL CAROTID ARTERY

The **internal carotid artery** supplies the anterior part of the brain, the eye and its appendages, and sends branches to the forehead and nose. Its size, in the adult, is equal to that of the external carotid, though, in the child, it is larger than that vessel. It is remarkable for the number of curvatures that it presents in different parts of its course. It occasionally has one or two flexures near the base of the skull, while in its passage through the carotid canal and along the side of the body of the sphenoid bone it describes a double curvature and resembles the italic letter *S*.

Course and Relations.—In considering the course and relations of this vessel it may be divided into four portions: **cervical, petrous, cavernous, and cerebral.**

Cervical Portion.—This portion of the internal carotid begins at the bifurcation of the common carotid, opposite the upper border of the thyroid cartilage, and runs perpendicularly upward, in front of the transverse processes of the upper three cervical vertebrae, to the carotid canal in the petrous portion of the temporal bone. It is comparatively superficial at its commencement, where it is contained in the carotid triangle, and lies behind and lateral to the external carotid, overlapped by the Sternocleidomastoideus, and covered by the deep fascia, Platysma, and integument: it then passes beneath the parotid gland, being crossed by the hypoglossal nerve, the Digastricus and Stylohyoideus, and the occipital and posterior auricular arteries. Higher up, it is separated from the external carotid by the Styloglossus and Stylopharyngeus, the tip of the styloid process and the stylohyoid ligament, the glossopharyngeal nerve and the pharyngeal branch of the vagus. It is in relation, *behind*, with the Longus capitis, the superior cervical ganglion of the sympathetic trunk, and the superior laryngeal nerve; *laterally*, with the internal jugular vein and vagus nerve, the nerve lying on a plane posterior to the artery; *medially*, with the pharynx, superior laryngeal nerve, and ascending pharyngeal artery. At the base of the skull the glossopharyngeal, vagus, accessory, and hypoglossal nerves lie between the artery and the internal jugular vein.

Petrous Portion. When the internal carotid artery enters the canal in the petrous portion of the temporal bone, it first ascends a short distance, then curves forward and medialward, and again ascends as it leaves the canal to enter the cavity of the skull between the lingula and petrosal process of the sphenoid. The artery lies at first in front of the cochlea and tympanic cavity; from the latter cavity it is separated by a thin, bony lamella, which is cribriform in the young subject, and often partly absorbed in old age. Farther forward it is separated from the semilunar ganglion by a thin plate of bone, which forms the floor of the fossa for the ganglion and the roof of the horizontal portion of the canal. Frequently this bony plate is more or less deficient, and then the ganglion is separated from the artery by fibrous membrane. The artery is separated from the bony wall of the carotid canal by a prolongation of dura mater, and is surrounded by a number of small veins and by filaments of the carotid plexus, derived from the ascending branch of the superior cervical ganglion of the sympathetic trunk.

Cavernous Portion.—In this part of its course, the artery is situated between the layers of the dura mater forming the cavernous sinus, but covered by the lining membrane of the sinus. It at first ascends toward the posterior clinoid process, then passes forward by the side of the body of the sphenoid bone, and again curves upward on the medial side of the anterior clinoid process, and perforates the dura mater forming the roof of the sinus. This portion of the artery is surrounded by filaments of the sympathetic nerve, and on its lateral side is the abducent nerve.

Cerebral Portion.—Having perforated the dura mater on the medial side of the anterior clinoid process, the internal carotid passes between the optic and oculomotor nerves to the anterior perforated substance at the medial extremity of the lateral cerebral fissure, where it gives off its terminal or cerebral branches.

Peculiarities.—The length of the internal carotid varies according to the length of the neck, and also according to the point of bifurcation of the common carotid. It arises sometimes from the arch of the aorta; in such rare instances, this vessel has been found to be placed nearer the middle line of the neck than the external carotid, as far upward as the larynx, when the latter vessel crossed the internal carotid. The course of the artery, instead of being straight, may be very tortuous. A few instances are recorded in which this vessel was altogether absent; in one of these the common carotid passed up the neck, and gave off the usual branches of the external carotid; the cranial portion of the internal carotid was replaced by two branches of the maxillary, which entered the skull through the foramen rotundum and foramen ovale, and joined to form a single vessel.

Branches.—The cervical portion of the internal carotid gives off no branches. Those from the other portions are:

<i>Petrous Portion</i>	<i>Cavernous Portion</i>	<i>Cerebral Portion</i>
Caroticotympanic	Cavernous	Anterior Cerebral
Artery of the Pterygoid Canal	Hypophyseal	Middle Cerebral
	Semilunar	Posterior Communicating
	Anterior Meningeal	Anterior Choroidal
	Ophthalmic	

1. **The caroticotympanic branch** (*ramus caroticotympanicus*; *tympanic branch*) is small; it enters the tympanic cavity through a minute foramen in the carotid canal, and anastomoses with the anterior tympanic branch of the maxillary, and with the stylomastoid artery.

2. **The artery of the pterygoid canal** (*a. canalis pterygoidei* [Vidii]; *Vidian artery*) is a small, inconstant branch which passes into the pterygoid canal and anastomoses with a branch of the maxillary artery.

3. **The cavernous branches** are numerous small vessels which supply the hypophysis, the semilunar ganglion, and the walls of the cavernous and inferior petrosal sinuses. Some of them anastomose with branches of the middle meningeal.

4. **The hypophyseal branches** are one or two minute vessels supplying the hypophysis.

5. **The semilunar branches** are small vessels to the semilunar ganglion.

6. **The anterior meningeal branch** (*a. meningea anterior*) is a small branch which passes over the small wing of the sphenoid to supply the dura mater of the anterior cranial fossa; it anastomoses with the meningeal branch from the posterior ethmoidal artery.

7. **The ophthalmic artery** (*a. ophthalmica*) arises from the internal carotid, just as that vessel is emerging from the cavernous sinus, on the medial side of the anterior clinoid process, and enters the orbital cavity through the optic foramen, below and lateral to the optic nerve. It then passes over the nerve to reach the medial wall of the orbit, and thence horizontally forward, beneath the lower border of the Obliquus superior, and divides it into two terminal branches, the **frontal** and **dorsal nasal**. As the artery crosses the optic nerve it is accompanied by the nasociliary nerve, and is separated from the frontal nerve by the Rectus superior and Levator palpebrae superioris.

Branches.—The branches of the ophthalmic artery may be divided into an **orbital group**, distributed to the orbit and surrounding parts; and an **ocular group**, to the muscles and bulb of the eye.

The **Lacrimal Artery** (*a. lacrimalis*) arises close to the optic foramen, and is one of the largest branches derived from the ophthalmic: not infrequently it is given off before the artery enters the orbit. It accompanies the lacrimal nerve along the upper border of the Rectus lateralis, and supplies the lacrimal gland. Its terminal branches, escaping from the gland, are distributed to the eyelids and conjunctiva: of those supplying the eyelids, two are of considerable size and are named the **lateral palpebral arteries**; they run medialward in the upper and lower lids respectively and anastomose with the medial palpebral arteries, forming an arterial circle in this situation. The lacrimal artery give off one or two **zygomatic branches**, one of which passes through the zygomatico-temporal foramen, to reach the temporal fossa, and anastomoses with the deep temporal arteries; another appears on the cheek through the zygomatico-facial foramen, and anastomoses with the transverse facial. A **recurrent branch** passes backward through the lateral part of the superior orbital fissure to the dura mater, and anastomoses with a branch of the middle meningeal artery. The lacrimal artery is sometimes derived from one of the anterior branches of the middle meningeal artery.

• **The Supraorbital Artery** (*a. supraorbitalis*) springs from the ophthalmic as that vessel is crossing over the optic nerve. It passes upward on the medial borders of the Rectus superior and Levator palpebrae, and meeting the supraorbital nerve accompanies it between the periosteum and Levator palpebrae to the supraorbital foramen; passing through this it divides into a superficial and a deep branch, which supply the integument, the muscles, and the pericranium of the forehead, anastomosing with the frontal, the frontal branch of the superficial temporal, and the artery of the opposite side. This artery in the orbit supplies the Rectus superior and the Levator palpebrae, and sends a branch across the pulley of the Obliquus superior, to supply the parts at the medial palpebral commissure. At the supraorbital foramen it frequently transmits a branch to the diploë.

• **The Ethmoidal Arteries** are two in number: **posterior** and **anterior**. The **posterior ethmoidal artery**, the smaller, passes through the posterior ethmoidal canal, supplies the posterior ethmoidal cells, and, entering the cranium, gives off a meningeal branch to the dura mater, and nasal branches which descend into the nasal cavity through apertures in the cribriform plate, anastomosing with branches of the sphenopalatine. The **anterior ethmoidal artery** accompanies the nasociliary nerve through the anterior ethmoidal canal, supplies the anterior and middle ethmoidal cells and frontal sinus, and, entering the cranium, gives off a meningeal branch to the dura mater, and nasal branches; these latter descend into the nasal cavity through the slit by the side of the crista galli, and, running along the groove on the inner surface of the nasal bone, supply branches to the lateral wall and septum of the nose, and a terminal branch which appears on the dorsum of the nose between the nasal bone and the lateral cartilage.

• The **Medial Palpebral Arteries** (*aa. palpebrales mediales; internal palpebral arteries*), two in number, **superior** and **inferior**, arise from the ophthalmic, opposite the pulley of the Obliquus superior; they leave the orbit to encircle the eyelids near their free margins, forming a superior and an inferior arch, which lie between the Orbicularis oculi and the tarsi. The **superior palpebral** anastomoses, at the lateral angle of the orbit, with the zygomatico-orbital branch of the temporal artery and with the upper of the two lateral palpebral branches from the lacrimal artery; the **inferior palpebral** anastomoses, at the lateral angle of the orbit, with the lower of the two lateral palpebral branches from the lacrimal and with the transverse facial artery, and, at the medial part of the lid, with a branch from the angular artery. From this last anastomoses a branch passes to the nasolacrimal duct, ramifying in its mucous membrane, as far as the inferior meatus of the nasal cavity.

• The **Frontal Artery** (*a. frontalis*), one of the terminal branches of the ophthalmic, leaves the orbit at its medial angle with the supratrochlear nerve, and, ascending on the forehead, supplies the integument, muscles, and pericranium, anastomosing with the supraorbital artery, and with the artery of the opposite side.

• The **Dorsal Nasal Artery** (*a. dorsalis nasi; nasal artery*), the other terminal branch of the ophthalmic, emerges from the orbit above the medial palpebral ligament, and, after giving a twig to the upper part of the lacrimal sac, divides into two branches, one of which crosses the root of the nose, and anastomoses with the angular artery, the other runs along the dorsum of the nose, supplies its outer surface; and anastomoses with the artery of the opposite side, and with the lateral nasal branch of the Facial.

• The **Central Artery of the Retina** (*a. centralis retinae*) is the first and one of the smallest branches of the ophthalmic artery. It runs for a short distance within the dural sheath of the optic nerve, but about 1.25 cm. behind the eyeball it pierces the nerve obliquely, and runs forward in the center of its substance to the retina. Its mode of distribution will be described with the anatomy of the eye.

• The **Ciliary Arteries** (*aa. ciliares*) are divisible into three groups, the long and short, posterior, and the anterior. The **short posterior ciliary arteries** from six to twelve in number, arise from the ophthalmic, or its branches; they pass forward around the optic nerve to the posterior part of the eyeball, pierce the sclera around the entrance of the nerve, and supply the choroid and ciliary processes. The **long posterior ciliary arteries**, two in number, pierce the posterior part of the sclera at some little distance from the optic nerve, and run forward, along either side of the eyeball, between the sclera and choroid, to the ciliary muscle, where they divide into two branches; these form an arterial circle, the **circulus arteriosus major**, around the circumference of the iris, from which numerous converging branches run, in the substance of the iris, to its pupillary margin, where they form a second arterial circle, the **circulus arteriosus minor**. The **anterior ciliary arteries** are derived from the muscular branches; they run to the front of the eyeball in company with the tendons of the Recti, form a vascular zone beneath the conjunctiva, and then pierce the sclera a short distance from the cornea and end in the circulus arteriosus major.

• The **Muscular Branches**, (*rami musculares*), two in number, **superior** and **inferior**, frequently spring from a common trunk. The **superior**, often wanting, supplies the Levator palpebrae superioris, Rectus superior, and Obliquus superior. The **inferior**, more constantly present, passes forward between the optic nerve and Rectus inferior, and is distributed to the Recti lateralis, medialis, and inferior, and the Obliquus inferior. This vessel gives off most of the anterior ciliary arteries. Additional muscular branches are given off from the lacrimal and supraorbital arteries, or from the trunk of the ophthalmic.

8. The anterior cerebral artery (*a. cerebri anterior*) arises from the internal carotid, at the medial extremity of the lateral cerebral fissure. It passes forward and medialward across the anterior perforated substance, above the optic nerve, to the commencement of the longitudinal fissure. Here it comes into close relationship with the opposite artery, to which it is connected by a short trunk, the **anterior communicating artery**. From this point the two vessels run side by side in the longitudinal fissure, curve around the genu of the corpus callosum, and turning backward continue along the upper surface of the corpus callosum to its posterior part, where they end by anastomosing with the posterior cerebral arteries.

Branches.—In its course the anterior cerebral artery gives off the following branches:

• The **Antero-medial Ganglionic Branches** are a group of small arteries which arise at the commencement of the anterior cerebral artery; they pierce the anterior perforated substance and lamina terminalis, and supply the rostrum of the corpus callosum, the septum pellucidum, and the head of the caudate nucleus. The **inferior branches**, two or three in number, are distributed to the orbital surface of the frontal lobe, where they supply the olfactory lobe, gyrus rectus, and internal orbital gyrus. The **anterior bran-**

ches supply a part of the superior frontal gyrus, and send twigs over the edge of the hemisphere to the superior and middle frontal gyri and upper part of the anterior central gyrus. The **middle branches** supply the corpus callosum, the cingulate gyrus, the medial surface of the superior frontal gyrus, and the upper part of the anterior central gyrus. The **posterior branches** supply the precuneus and adjacent lateral surface of the hemisphere.

- The **Anterior Communicating Artery** (*a. communicans anterior*) connects the two anterior cerebral arteries across the commencement of the longitudinal fissure. Sometimes this vessel is wanting, the two arteries joining together to form a single trunk, which afterward divides; or it may be wholly, or partially, divided into two. Its length averages about 4 mm., but varies greatly. It gives off some of the antero-medial ganglionic vessels, but these are principally derived from the anterior cerebral.

9. The **middle cerebral artery** (*a. cerebri media*), the largest branch of the internal carotid, runs at first lateralward in the lateral cerebral or Sylvian fissure and then backward and upward on the surface of the insula, where it divides into a number of branches which are distributed to the lateral surface of the cerebral hemisphere.

Branches.—The branches of this vessel are the:

- The **Antero-lateral Ganglionic Branches**, a group of small arteries which *arise* at the commencement of the middle cerebral artery, are arranged in two sets: one, the **internal striate**, passes upward through the inner segments of the lentiform nucleus, and supplies it, the caudate nucleus, and the internal capsule; the other, the **external striate**, ascends through the outer segment of the lentiform nucleus, and supplies the caudate nucleus and the thalamus. One artery of this group is of larger size than the rest, and is of special importance, as being the artery in the brain most frequently ruptured; it has been termed by Charcot the **artery of cerebral hemorrhage**. It ascends between the lentiform nucleus and the external capsule, and ends in the caudate nucleus. The **inferior lateral frontal** supplies the inferior frontal gyrus (*Broca's convolution*) and the lateral part of the orbital surface of the frontal lobe. The **ascending frontal** supplies the anterior central gyrus. The **ascending parietal** is distributed to the posterior central gyrus and the lower part of the superior parietal lobule. The **parietotemporal** supplies the supramarginal and angular gyri, and the posterior parts of the superior and middle temporal gyri. The **temporal branches**, two or three in number, are distributed to the lateral surface of the temporal lobe.

10. The **posterior communicating artery** (*a. communicans posterior*) runs backward from the internal carotid, and anastomoses with the posterior cerebral, a branch of the basilar. It varies in size, being sometimes small, and occasionally so large that the posterior cerebral may be considered as arising from the internal carotid rather than from the basilar. It is frequently larger on one side than on the other. From its posterior half are given off a number of small branches, the **postero-medial ganglionic branches**, which, with similar vessels from the posterior cerebral, pierce the posterior perforated substance and supply the medial surface of the thalami and the walls of the third ventricle.

11. The **anterior choroidal** (*a. chorioidea; choroid artery*) is a small but constant branch, which *arises* from the internal carotid, near the posterior communicating artery. Passing backward and lateralward between the temporal lobe and the cerebral peduncle, it enters the inferior horn of the lateral ventricle through the choroidal fissure and ends in the choroid plexus. It is distributed to the hippocampus, fimbria, tela chorioidea of the third ventricle, and choroid plexus.

Since the mode of distribution of the vessels of the brain has an important bearing upon a considerable number of the pathological lesions which may occur in this part of the nervous system, it is important to consider a little more in detail the manner in which the vessels are distributed.

The cerebral arteries are derived from the internal carotid and vertebral, which at the base of the brain form a remarkable anastomosis known as the **arterial circle of Willis**. It is formed in front by the anterior cerebral arteries, branches of the internal carotid, which are connected together by the anterior communicating; behind by the two posterior cerebral arteries, branches of the basilar, which are connected on either side with the internal carotid by the posterior communicating. The parts of the brain included within this arterial circle are the lamina terminalis, the optic chiasma, the infundibulum, the tuber cinereum, the corpora mammillaria, and the posterior perforated substance.

The Cortical Arterial System.—The vessels forming this system are the terminal branches of the anterior, middle, and posterior cerebral arteries. They divide and ramify in the substance of the pia mater, and give off branches which penetrate the brain cortex, perpendicularly. These branches are divisible into two classes, long and short. The **long**, or **medullary arteries**, pass through the gray substance and penetrate the subjacent white substance to the depth of 3 or 4 cm., without intercommunicating otherwise than

by very fine capillaries, and thus constitute so many independent small systems. The **short vessels** are confined to the cortex, where they form with the long vessels a compact net-work in the middle zone of the gray substance, the outer and inner zones being sparingly supplied with blood. The vessels of the cortical arterial system are not so strictly "terminal" as those of the ganglionic system, but they approach this type very closely, so that injection of one area from the vessel of another area, though possible, is frequently very difficult, and is only effected through vessels of small caliber. As a result of this, obstruction of one of the main branches, or its divisions, may have the effect of producing softening in a limited area of the cortex.

THE SUBCLAVIAN ARTERY

The Subclavian Artery (A. Subclavia).—On the right side the **subclavian artery** *arises* from the innominate artery behind the right sternoclavicular articulation; on the left side it springs from the arch of the aorta. The two vessels, therefore, in the first part of their course, differ in length, direction, and relation with neighboring structures.

In order to facilitate the description, each subclavian artery is divided into three parts. The first portion extends from the origin of the vessel to the medial border of the Scalenus anterior; the second lies behind this muscle; and the third extends from the lateral margin of the muscle to the outer border of the first rib, where it becomes the axillary artery. The first portions of the two vessels require separate descriptions; the second and third parts of the two arteries are practically alike.

First Part of the Right Subclavian Artery. The first part of the right subclavian artery *arises* from the innominate artery, behind the upper part of the right sternoclavicular articulation, and passes upward and lateralward to the medial margin of the Scalenus anterior. It ascends a little above the clavicle, the extent to which it does so varying in different cases.

Relations.—It is covered, *in front*, by the integument, superficial fascia, Platysma, deep fascia, the clavicular origin of the Sternocleidomastoideus, the Sternohyoideus, and Sternothyroideus, and another layer of the deep fascia. It is crossed by the internal jugular and vertebral veins, by the vagus nerve and the cardiac branches of the vagus and sympathetic, and by the subclavian loop of the sympathetic trunk which forms a ring around the vessel. The anterior jugular vein is directed lateralward in front of the artery, but is separated from it by the Sternohyoideus and Sternothyroideus. *Below and behind* the artery is the pleura, which separates it from the apex of the lung; *behind* is the sympathetic trunk, the Longus colli and the first thoracic vertebra. The right recurrent nerve winds around the lower and back part of the vessel.

First Part of the Left Subclavian Artery.—The first part of the left subclavian artery *arises* from the arch of the aorta, behind the left common carotid, and at the level of the fourth thoracic vertebra; it ascends in the superior mediastinal cavity to the root of the neck and then arches lateralward to the medial border of the Scalenus anterior.

Relations.—It is in relation, *in front*, with the vagus, cardiac, and phrenic nerves, which lie parallel with it, the left common carotid artery, left internal jugular and vertebral veins, and the commencement of the left innominate vein, and is covered by the Sternothyroideus, Sternohyoideus, and Sternocleidomastoideus; *behind*, it is in relation with the esophagus, thoracic duct, left recurrent nerve, inferior cervical ganglion of the sympathetic trunk, and Longus colli; higher up, however, the esophagus and thoracic duct lie to its right side; the latter ultimately arching over the vessel to join the angle of union between the subclavian and internal jugular veins. *Medial* to it are the esophagus, trachea, thoracic duct, and left recurrent nerve; *lateral* to it, the left pleura and lung.

Second and Third Parts of the Subclavian Artery. The second **portion** of the subclavian artery lies behind the Scalenus anterior; it is very short, and forms the highest part of the arch described by the vessel.

Relations.—It is covered, *in front*, by the skin, superficial fascia, Platysma, deep cervical fascia, Sternocleidomastoideus, and Scalenus anterior. On the right side of the neck the phrenic nerve is separated from the second part of the artery by the Scalenus anterior, while on the left side it crosses the first part of the artery close to the medial edge of the muscle. *Behind* the vessel are the pleura and the Scalenus medius; *above*, the brachial plexus of nerves; *below*, the pleura. The subclavian vein lies below and in front of the artery, separated from it by the Scalenus anterior.

The **third portion** of the subclavian artery runs downward and lateralward from the lateral margin of the *Scalenus anterior* to the outer border of the first rib, where it becomes the axillary artery. This is the most superficial portion of the vessel, and is contained in the subclavian triangle.

Relations.—It is covered, *in front*, by the skin, the superficial fascia, the *Platysma*, the supraclavicular nerves, and the deep cervical fascia. The external jugular vein crosses its medial part and receives the transverse scapular, transverse cervical, and anterior jugular veins, which frequently form a plexus in front of the artery. Behind the veins, the nerve to the *Subclavius* descends in front of the artery. The terminal part of the artery lies behind the clavicle and the *Subclavius* and is crossed by the transverse scapular vessels. The subclavian vein is in front of and at a slightly lower level than the artery. *Behind*, it lies on the lowest trunk of the brachial plexus, which intervenes between it and the *Scalenus medius*. *Above* and to its *lateral* side are the upper trunks of the brachial plexus and the *Omo-hyoideus*. *Below*, it rests on the upper surface of the first rib.

Peculiarities.—The subclavian arteries vary in their origin, their course, and the height to which they rise in the neck.

The origin of the right subclavian from the innominate takes place, in some cases, above the sternoclavicular articulation, and occasionally, but less frequently, below that joint. The artery may arise as a separate trunk from the arch of the aorta, and in such cases it may be either the first, second, third, or even the last branch derived from that vessel; in the majority, however, it is the first or last, rarely the second or third. When it is the first branch, it occupies the ordinary position of the innominate artery; when the second or third, it gains its usual position by passing behind the right carotid; and when the last branch, it arises from the left extremity of the arch, and passes obliquely toward the right side, usually behind the trachea, esophagus, and right carotid, sometimes between the esophagus and trachea, to the upper border of the first rib, whence it follows its ordinary course. In very rare instances, this vessel arises from the thoracic aorta, as low down as the fourth thoracic vertebra. Occasionally, it perforates the *Scalenus anterior*; more rarely it passes in front of that muscle. Sometimes the subclavian vein passes with the artery behind the *Scalenus anterior*. The artery may ascend as high as 4 cm. above the clavicle, or any intermediate point between this and the upper border of the bone, the right subclavian usually ascending higher than the left.

The left subclavian is occasionally joined at its origin with the left carotid. The left subclavian artery is more deeply placed than the right in the first part of its course, and, as a rule, does not reach quite as high a level in the neck. The posterior border of the *Sternocleidomastoideus* corresponds pretty closely to the lateral border of the *Scalenus anterior*, so that the third portion of the artery, the part most accessible for operation, lies immediately lateral to the posterior border of the *Sternocleidomastoideus*.

Collateral Circulation.—After ligation of the third part of the subclavian artery, the collateral circulation is established mainly by three sets of vessels, thus described in a dissection:

1. A posterior set, consisting of the transverse scapular and the descending ramus of the transverse cervical branches of the subclavian, anastomosing with the subscapular from the axillary.
2. A medial set, produced by the connection of the internal thoracic on the one hand, with the highest intercostal and lateral thoracic arteries, and the branches from the subscapular on the other.
3. A middle or axillary set, consisting of a number of small vessels derived from branches of the subclavian, above, and, passing through the axilla, terminating either in the main trunk, or some of the branches of the axillary below. This last set presented most conspicuously the peculiar character of newly formed or, rather, dilated arteries, being excessively tortuous, and forming a complete plexus.

The chief agent in the restoration of the axillary artery below the tumor was the subscapular artery, which communicated most freely with the internal mammary, transverse scapular and descending ramus of the transverse cervical branches of the subclavian, from all of which it received so great an influx of blood as to dilate it to three times its natural size.

When a ligation is applied to the first part of the subclavian artery, the collateral circulation is carried on by: (1) the anastomosis between the superior and inferior thyroids; (2) the anastomosis of the two vertebrals; (3) the anastomosis of the internal thoracic with the inferior epigastric and the aortic intercostals; (4) the costocervical anastomosing with the aortic intercostals; (5) the profunda cervicis anastomosing with the descending branch of the occipital; (6) the scapular branches of the thyrocervical trunk anastomosing with the branches of the axillary, and (7) the thoracic branches of the axillary anastomosing with the aortic intercostals.

Branches. The branches of the subclavian artery are:

First Part	Second Part	Third Part
Vertebral	Costocervical trunk	Transversa colli
Thyrocervical trunk		
Internal thoracic		

On the left side all branches generally *arise* from the first portion of the vessel; but on the right side, the costocervical trunk usually springs from the second portion of the vessel. On both sides of the neck, the first three branches arise close together at the medial border of the Scalenus anterior; in the majority of cases, a free interval of from 1.25 to 2.5 cm. exists between the commencement of the artery and the origin of the nearest branch.

1. The vertebral artery (*a. vertebralis*), is the first branch of the subclavian, and *arises* from the upper and back part of the first portion of the vessel. It is surrounded by a plexus of nerve fibers derived from the inferior cervical ganglion of the sympathetic trunk, and ascends through the foramina in the transverse processes of the upper six cervical vertebrae, it then winds behind the superior articular process of the atlas and, entering the skull through the foramen magnum, unites, at the lower border of the pons, with the vessel of the opposite side to form the basilar artery.

Relations.—The vertebral artery may be divided into four parts: The **first part** runs upward and backward between the Longus colli and the Scalenus anterior. In front of it are the internal jugular and vertebral veins, and it is crossed by the inferior thyroid artery; the left vertebral is crossed by the thoracic duct also. Behind it are the transverse process of the seventh cervical vertebra, the sympathetic trunk and its inferior cervical ganglion. The **second part** runs upward through the foramina in the transverse processes of the upper six cervical vertebrae, and is surrounded by branches from the inferior cervical sympathetic ganglion and by a plexus of veins which unite to form the vertebral vein at the lower part of the neck. It is situated in front of the trunks of the cervical nerves, and pursues an almost vertical course as far as the transverse process of the atlas, above which it runs upward and lateralward to the foramen in the transverse process of the atlas. The **third part** issues from the latter foramen on the medial side of the Rectus capitis lateralis, and curves backward behind the superior articular process of the atlas, the anterior ramus of the first cervical nerve being on its medial side; it then lies in the groove on the upper surface of the posterior arch of the atlas, and enters the vertebral canal by passing beneath the posterior atlantoöccipital membrane. This part of the artery is covered by the Semispinalis capitis and is contained in the **suboccipital triangle**—a triangular space bounded by the Rectus capitis posterior major, the Obliquus superior, and the Obliquus inferior. The first cervical or suboccipital nerve lies between the artery and the posterior arch of the atlas. The **fourth part** pierces the dura mater and inclines medialward to the front of the medulla oblongata; it is placed between the hypoglossal nerve and the anterior root of the first cervical nerve and beneath the first digitation of the ligamentum denticulatum. At the lower border of the pons it unites with the vessel of the opposite side to form the basilar artery.

Branches.—The branches of the vertebral artery may be divided into two sets: those given off in the neck, and those within the cranium.

- **Spinal Branches** (*rami spiniales*) enter the vertebral canal through the intervertebral foramina, and each divides into two branches. Of these, one passes along the roots of the nerves to supply the medulla spinalis and its membranes, anastomosing with the other arteries of the medulla spinalis; the other divides into an ascending and a descending branch, which unite with similar branches from the arteries above and below, so that two lateral anastomotic chains are formed on the posterior surfaces of the bodies of the vertebrae, near the attachment of the pedicles. From these anastomotic chains branches are supplied to the periosteum and the bodies of the vertebrae, and others form communications with similar branches from the opposite side; from these communications small twigs arise which join similar branches above and below, to form a central anastomotic chain on the posterior surface of the bodies of the vertebrae.

- **Muscular Branches** are given off to the deep muscles of the neck, where the vertebral artery curves around the articular process of the atlas. They anastomose with the occipital, and with the ascending and deep cervical arteries.

- The **Meningeal Branch** (*ramus meningeus; posterior meningeal branch*) springs from the vertebral opposite the foramen magnum, ramifies between the bone and dura mater in the cerebellar fossa, and supplies the falx cerebelli. It is frequently represented by one or two small branches.

• The **Posterior Spinal Artery** (*a. spinalis posterior; dorsal spinal artery*) arises from the vertebral, at the side of the medulla oblongata; passing backward, it descends on this structure, lying in front of the posterior roots of the spinal nerves, and is reinforced by a succession of small branches, which enter the vertebral canal through the intervertebral foramina; by means of these it is continued to the lower part of the medulla spinalis, and to the cauda equina. Branches from the posterior spinal arteries form a free anastomosis around the posterior roots of the spinal nerves, and communicate, by means of very tortuous transverse branches, with the vessels of the opposite side. Close to its origin each gives off an ascending branch, which ends at the side of the fourth ventricle.

• The **Anterior Spinal Artery** (*a. spinalis anterior; ventral spinal artery*) is a small branch, which arises near the termination of the vertebral, and, descending in front of the medulla oblongata, unites with its fellow of the opposite side at the level of the foramen magnum. One of these vessels is usually larger than the other, but occasionally they are about equal in size. The single trunk, thus formed, descends on the front of the medulla spinalis, and is reinforced by a succession of small branches which enter the vertebral canal through the intervertebral foramina; these branches are derived from the vertebral and the ascending cervical of the inferior thyroid in the neck; from the intercostals in the thorax; and from the lumbar, iliolumbar, and lateral sacral arteries in the abdomen and pelvis. They unite, by means of ascending and descending branches, to form a single anterior median artery, which extends as far as the lower part of the medulla spinalis, and is continued as a slender twig on the filum terminale. This vessel is placed in the pia mater along the anterior median fissure; it supplies that membrane, and the substance of the medulla spinalis, and sends off branches at its lower part to be distributed to the cauda equina.

• The **Posterior Inferior Cerebellar Artery** (*a. cerebelli inferior posterior*), the largest branch of the vertebral, winds backward around the upper part of the medulla oblongata, passing between the origins of the vagus and accessory nerves, over the inferior peduncle to the under surface of the cerebellum, where it divides into two branches. The **medial branch** is continued backward to the notch between the two hemispheres of the cerebellum; while the **lateral** supplies the under surface of the cerebellum, as far as its lateral border, where it anastomoses with the anterior inferior cerebellar and the superior cerebellar branches of the basilar artery. Branches from this artery supply the choroid plexus of the fourth ventricle.

• The **Medullary Arteries** (*bulbar arteries*) are several minute vessels which spring from the vertebral and its branches and are distributed to the medulla oblongata.

The **Basilar Artery** (*a. basilaris*), so named from its position at the base of the skull, is a single trunk formed by the junction of the two vertebral arteries: it extends from the lower to the upper border of the pons, lying in its median groove, under cover of the arachnoid. It ends by dividing into the two posterior cerebral arteries.

Its **branches**, on either side, are the following:

❖ The **pontine branches** (*rami ad pontem; transverse branches*) are a number of small vessels which come off at right angles from either side of the basilar artery and supply the pons and adjacent parts of the brain.

❖ The **internal auditory artery** (*a. auditiva interna; auditory artery*), a long slender branch, arises from near the middle of the artery; it accompanies the acoustic nerve through the internal acoustic meatus, and is distributed to the internal ear.

❖ The **anterior inferior cerebellar artery** (*a. cerebelli inferior anterior*) passes backward to be distributed to the anterior part of the under surface of the cerebellum, anastomosing with the posterior inferior cerebellar branch of the vertebral.

❖ The **superior cerebellar artery** (*a. cerebelli superior*) arises near the termination of the basilar. It passes lateralward, immediately below the oculomotor nerve, which separates it from the posterior cerebral artery, winds around the cerebral peduncle, close to the trochlear nerve, and, arriving at the upper surface of the cerebellum, divides into branches which ramify in the pia mater and anastomose with those of the inferior cerebellar arteries. Several branches are given to the pineal body, the anterior medullary velum, and the tela chorioidea of the third ventricle.

❖ The **posterior cerebral artery** (*a. cerebri posterior*) is larger than the preceding, from which it is separated near its origin by the oculomotor nerve. Passing lateralward, parallel to the superior cerebellar artery, and receiving the posterior communicating from the internal carotid, it winds around the cerebral peduncle, and reaches the tentorial surface of the occipital lobe of the cerebrum, where it breaks up into branches for the supply of the temporal and occipital lobes.

The **branches** of the posterior cerebral artery are divided into two sets, **ganglionic** and **cortical**:

➤ **Ganglionic**.—The **postero-medial ganglionic branches** are a group of small arteries which *arise* at the commencement of the posterior cerebral artery: these, with similar branches from the posterior communicating, pierce the posterior perforated substance, and supply the medial surfaces of the thalami and the walls of the third ventricle. The **posterior choroidal branches** run forward beneath the splenium of the corpus callosum, and supply the tela chorioidea of the third ventricle and the choroid plexus. The **postero-lateral ganglionic branches** are small arteries which *arise* from the posterior cerebral artery after it has turned around the cerebral peduncle; they supply a considerable portion of the thalamus.

➤ **Cortical**.—The cortical branches are: the **anterior temporal**, distributed to the uncus and the anterior part of the fusiform gyrus; the **posterior temporal**, to the fusiform and the inferior temporal gyri; the **calcarine**, to the cuneus and gyrus lingualis and the back part of the convex surface of the occipital lobe; and the **parieto-occipital**, to the cuneus and the precuneus.

2. The **thyrocervical trunk** (*truncus thyrocervicalis*; *thyroid axis*) is a short thick trunk, which *arises* from the front of the first portion of the subclavian artery, close to the medial border of the Scalenus anterior, and divides almost immediately into three branches, the **inferior thyroid**, **suprascapular**, **ascending cervical** and **superficial cervical**.

• The **Inferior Thyroid Artery** (*a. thyreoidea inferior*) passes upward, in front of the vertebral artery and Longus colli; then turns medialward behind the carotid sheath and its contents, and also behind the sympathetic trunk, the middle cervical ganglion resting upon the vessel. Reaching the lower border of the thyroid gland it divides into two branches, which supply the postero-inferior parts of the gland, and anastomose with the superior thyroid, and with the corresponding artery of the opposite side. The recurrent nerve passes upward generally behind, but occasionally in front, of the artery.

The **branches** of the inferior thyroid are:

➤ The **inferior laryngeal artery** (*a. laryngea inferior*) ascends upon the trachea to the back part of the larynx under cover of the Constrictor pharyngis inferior, in company with the recurrent nerve, and supplies the muscles and mucous membrane of this part, anastomosing with the branch from the opposite side, and with the superior laryngeal branch of the superior thyroid artery.

➤ The **tracheal branches** (*rami tracheales*) are distributed upon the trachea, and anastomose below with the bronchial arteries.

➤ The **esophageal branches** (*rami oesophagei*) supply the esophagus, and anastomose with the esophageal branches of the aorta.

• The **ascending cervical artery** (*a. cervicalis ascendens*) is a small branch which *arises* from the inferior thyroid as that vessel is passing behind the carotid sheath; it runs up on the anterior tubercles of the transverse processes of the cervical vertebrae in the interval between the Scalenus anterior and Longus capitis. To the muscles of the neck it gives twigs which anastomose with branches of the vertebral, and it sends one or two spinal branches into the vertebral canal through the intervertebral foramina to be distributed to the medulla spinalis and its membranes, and to the bodies of the vertebrae, in the same manner as the spinal branches from the vertebral. It anastomoses with the ascending pharyngeal and occipital arteries.

➤ The **muscular branches** supply the depressors of the hyoid bone, and the Longus colli, Scalenus anterior, and Constrictor pharyngis inferior.

• The **Suprascapular Artery** (*a. suprascapular artery*) passes at first downward and lateralward across the Scalenus anterior and phrenic nerve, being covered by the Sternocleidomastoideus; it then crosses the subclavian artery and the brachial plexus, and runs behind and parallel with the clavicle and Subclavius, and beneath the inferior belly of the Omohyoideus, to the superior border of the scapula; it passes over the superior transverse ligament of the scapula which separates it from the suprascapular nerve, and enters the supraspinatous fossa. In this situation it lies close to the bone, and ramifies between it and the Supraspinatus, to which it supplies branches. It then descends behind the neck of the scapula, through the great scapular notch and under cover of the inferior transverse ligament, to reach the infraspinatous fossa, where it anastomoses with the scapular circumflex and the descending branch of the transverse cervical. Besides distributing branches to the Sternocleidomastoideus, Subclavius, and neighboring muscles, it gives off a **suprasternal branch**, which crosses over the sternal end of the clavicle to the skin of the upper part of the chest; and an **acromial branch**, which pierces the Trapezius and supplies the skin over the acromion, anastomosing with the thoracoacromial artery. As the artery passes over the superior transverse

ligament of the scapula, it sends a branch into the subscapular fossa, where it ramifies beneath the Subscapularis, and anastomoses with the subscapular artery and with the descending branch of the transverse cervical. It also sends articular branches to the acromioclavicular and shoulder-joints, and a nutrient artery to the clavicle.

3. The internal thoracic artery (*a. thoracica interna*) arises from the under surface of the first portion of the subclavian, opposite the thyrocervical trunk. It descends behind the cartilages of the upper six ribs at a distance of about 1.25 cm. from the margin of the sternum, and at the level of the sixth intercostal space divides into the **musculophrenic** and **superior epigastric arteries**.

Relations.—It is directed at first downward, forward, and medialward behind the sternal end of the clavicle, the subclavian and internal jugular veins, and the first costal cartilage, and passes forward close to the lateral side of the innominate vein. As it enters the thorax the phrenic nerve crosses from its lateral to its medial side. Below the first costal cartilage it descends almost vertically to its point of bifurcation. It is covered in front by the cartilages of the upper six ribs and the intervening Intercostales interni and anterior intercostal membranes, and is crossed by the terminal portions of the upper six intercostal nerves. It rests on the pleura, as far as the third costal cartilage; below this level, upon the Transversus thoracis. It is accompanied by a pair of veins; these unite above to form a single vessel, which runs medial to the artery and ends in the corresponding innominate vein.

Branches.—The branches of the internal thoracic are:

- The **Pericardiacophrenic Artery** (*a. pericardiacophrenica; a. comes nervi phrenici*) is a long slender branch, which accompanies the phrenic nerve, between the pleura and pericardium, to the diaphragm, to which it is distributed; it anastomoses with the musculophrenic and inferior phrenic arteries.

- The **Anterior Mediastinal Arteries** (*aa. mediastinales anteriores; mediastinal arteries*) are small vessels, distributed to the areolar tissue and lymph glands in the anterior mediastinal cavity, and to the remains of the thymus.

- The **Pericardial Branches** supply the upper part of the anterior surface of the pericardium; the lower part receives branches from the musculophrenic artery.

- The **Sternal Branches** (*rami sternales*) are distributed to the Transversus thoracis, and to the posterior surface of the sternum.

- The anterior mediastinal, pericardial, and sternal branches, together with some twigs from the pericardiacophrenic, anastomose with branches from the intercostal and bronchial arteries, and form a **subpleural mediastinal plexus**.

- The **Intercostal Branches** (*rami intercostales; anterior intercostal arteries*) supply the upper five or six intercostal spaces. Two in number in each space, these small vessels pass lateralward, one lying near the lower margin of the rib above, and the other near the upper margin of the rib below, and anastomose with the intercostal arteries from the aorta. They are at first situated between the pleura and the Intercostales interni, and then between the Intercostales interni and externi. They supply the Intercostales and, by branches which perforate the Intercostales externi, the Pectorales and the mamma.

- The **Perforating Branches** (*rami perforantes*) correspond to the five or six intercostal spaces. They pass forward through the intercostal spaces, and, curving lateralward, supply the Pectoralis major and the integument. Those which correspond to the second, third, and fourth spaces give branches to the mama, and during lactation are of large size.

- The **Musculophrenic Artery** (*a. musculophrenica*) is directed obliquely downward and lateralward, behind the cartilages of the false ribs; it perforates the diaphragm at the eighth or ninth costal cartilage, and ends, considerably reduced in size, opposite the last intercostal space. It gives off intercostal branches to the seventh, eighth, and ninth intercostal spaces; these diminish in size as the spaces decrease in length, and are distributed in a manner precisely similar to the intercostals from the internal thoracic. The musculophrenic also gives branches to the lower part of the pericardium, and others which run backward to the diaphragm, and downward to the abdominal muscles.

- The **Superior Epigastric Artery** (*a. epigastrica superior*) continues in the original direction of the internal mammary; it descends through the interval between the costal and sternal attachments of the diaphragm, and enters the sheath of the Rectus abdominis, at first lying behind the muscle, and then perforating and supplying it, and anastomosing with the inferior epigastric artery from the external iliac. Branches perforate the anterior wall of the sheath of the Rectus, and supply the muscles of the abdomen and the integument, and a small branch passes in front of the xiphoid process and anastomoses with the

artery of the opposite side. It also gives some twigs to the diaphragm, while from the artery of the right side small branches extend into the falciform ligament of the liver and anastomose with the hepatic artery.

4. **The costocervical trunk** (*truncus costocervicalis*; *superior intercostal artery*) arises from the upper and back part of the subclavian artery, behind the Scalenus anterior on the right side, and medial to that muscle on the left side. Passing backward, it gives off the **profunda cervicalis**, and, continuing as the **highest intercostal artery**, descends behind the pleura in front of the necks of the first and second ribs, and anastomoses with the first aortic intercostal. As it crosses the neck of the first rib it lies medial to the anterior division of the first thoracic nerve, and lateral to the first thoracic ganglion of the sympathetic trunk.

In the first intercostal space, it gives off a branch which is distributed in a manner similar to the distribution of the aortic intercostals. The branch for the second intercostal space usually joins with one from the highest aortic intercostal artery. This branch is not constant, but is more commonly found on the right side; when absent, its place is supplied by an intercostal branch from the aorta. Each intercostal gives off a posterior branch which goes to the posterior vertebral muscles, and sends a small spinal branch through the corresponding intervertebral foramen to the medulla spinalis and its membranes.

The **Profunda Cervicalis** (*a. cervicalis profunda*; *deep cervical branch*) arises, in most cases, from the costocervical trunk, and is analogous to the posterior branch of an aortic intercostal artery: occasionally it is a separate branch from the subclavian artery. Passing backward, above the eighth cervical nerve and between the transverse process of the seventh cervical vertebra and the neck of the first rib, it runs up the back of the neck, between the Semispinales capitis and colli, as high as the axis vertebra, supplying these and adjacent muscles, and anastomosing with the deep division of the descending branch of the occipital, and with branches of the vertebral. It gives off a spinal twig which enters the canal through the intervertebral foramen between the seventh cervical and first thoracic vertebrae.

5. **The Transverse Cervical Artery** (*a. transversa colli*; *transversalis colli artery*) lies at a higher level than the transverse scapular; it passes transversely above the inferior belly of the Omohyoideus to the anterior margin of the Trapezius, beneath which it divides into an **ascending** and a **descending branch**. It crosses in front of the phrenic nerve and the Scaleni, and in front of or between the divisions of the brachial plexus, and is covered by the Platysma and Sternocleidomastoideus, and crossed by the Omohyoideus and Trapezius.

- The **ascending branch** (*ramus ascendens*; *superficial cervical artery*) ascends beneath the anterior margin of the Trapezius, distributing branches to it, and to the neighboring muscles and lymph glands in the neck, and anastomosing with the superficial branch of the descending ramus of the occipital artery.

- The **descending branch** (*ramus descendens*; *posterior scapular artery*) passes beneath the Levator scapulae to the medial angle of the scapula, and then descends under the Rhomboidei along the vertebral border of that bone as far as the inferior angle. It supplies the Rhomboidei, Latissimus dorsi and Trapezius, and anastomoses with the transverse scapular and subscapular arteries, and with the posterior branches of some of the intercostal arteries.

Peculiarities.—The ascending branch of the transverse cervical frequently arises directly from the thyrocervical trunk; and the descending branch from the third, more rarely from the second, part of the subclavian.

THE VEINS OF SYSTEMIC CIRCULATION THE SYSTEM OF VENA CAVA SUPERIOR

The **superior vena cava** (*vena cava superior*) is a thick (about 2.5 cm) but short (5-6 cm) trunk located to the right and somewhat posteriorly of the ascending aorta. It is formed by the merger of the **right and left innominate veins** (vv. *brachiocephalicae dextra* and *sinistra*) behind the junction of the first right rib with the sternum. From there it passes downward along the right edge of the sternum, posteriorly of the first and second intercostal spaces; at the level of the top edge of the third rib, concealed behind the right auricle of the heart, it drains into the right atrium. Its posterior wall touches a. pulmonalis dextra, which separates it from the right bronchus. It also adheres to the right superior pulmonary vein for a very short distance at the place where it drains into the atrium; both these vessels cross it transversely. V. azygos, bending over the root of the right lung (the aorta bends over the root of the left lung) at the level of the upper edge of the right pulmonary vein, drains into the vena cava superior. The anterior wall of the vena cava superior is separated from the anterior wall of the thorax by a fairly thick stratum of the right; lung.

THE INNOMINATE VEINS

The right and left innominate veins (*vv. brachiocephalicae dextra and sinistra*), which form the vena cava superior, are, in their turn, each formed by the merger of the **subclavian** and **internal jugular veins** (*v. subclavia* and *v. jugularis interna*). The right innominate vein, just 2-3 cm in length, is shorter than the left. Originating behind the right sternoclavicular joint, it runs obliquely downward and medially to the place where it joins the contralateral vein on the left. In front the right innominate vein is covered by mm. sternocleidomastoideus, sternohyoideus, and sternothyreoidcus and lower by the cartilage of the first rib. The left innominate vein is about twice the length of the right. It originates behind the left sternoclavicular joint and passes behind the manubrium sterni, separated from it only by cellular tissue and the thymus. From there, it leads to the right and downward where it joins the right innominate vein, with its lower wall closely adhering meanwhile to the convexity of the aortic arch; in front it crosses the left subclavian artery, the upper sections of the left common carotid artery, and the innominate artery. **Vv. thyreoideae inferiores** and **v. thyreoidea ima**, originating from the dense venous plexus at the lower edge of the thyroid gland, and the veins of the thymus drain into the innominate veins.

THE INTERNAL JUGULAR VEIN

The internal jugular vein (*v. jugularis interna*) carries blood from the cavity and its contents of the skull and the organs of the neck. Beginning at the foramen jugulare, where it forms a **distention** (*the bulbus superior venae jugularis interne*), the vein passes downward, laterally of a. carotis interna and, further down, laterally of a. carotis communis. A **second distention** (*the bulbus inferior v. jugularis internae*) is formed at the lower end of v. jugularis internae before it joins v. subclavia; there are one or two valves in the vein in the region of the neck above this distention. In the back region the internal jugular vein is covered by mm. sternocleidomastoideus and omohyoideus. Mention should be made here of *vv. Ophthalmicae superior* and *inferior*, which collect blood from the orbital cavity and drain into the sinus cavernosus, and *v. ophthalmica inferior*, which also joins the plexus pterygoideus.

Besides its own veins, the dura mater contains several reservoirs collecting blood from the brain; these are the **sinuses of the dura mater** (*sinus durae matris*).

The sinuses are venous canals (triangular on transverse section) devoid of valves and located in the thickness of the dura mater at the attachment of its processes to the skull; they differ from veins in the structure of their walls which are composed of tightly stretched layers of the dura mater and consequently do not collapse when cut and gape on being injured. The inflexibility of the walls of the venous sinuses provides free drainage of venous blood in changes of intracranial pressure; this is important for uninterrupted activity of the brain, which explains why such venous sinuses are present only in the skull.

The sinuses are as follows:

- **The transverse sinus** (*sinus transversus*), the largest and widest sinus which runs along the posterior margin of the tentorium cerebelli in the sulcus sinus transversi of the occipital bone. From here it descends into the sulcus sinus sigmoidei under the name of the **sigmoid sinus** (*sinus sigmoideus*), and at the jugular foramen is continuous with the orifice of the internal jugular vein. As a result, the transverse and sigmoid sinuses form the main receptacle for all the venous blood of the cranial cavity. All the other sinuses drain into it either directly or indirectly.

- The following sinuses drain directly into it.

- **The superior sagittal sinus** (*sinus sagittalis superior*) runs on the upper margin of falx cerebri for the whole length of sulcus sinus sagittalis superioris from crista galli to the internal occipital protuberance (on either side of the superior sagittal sinus, within the dura mater, are located the so-called blood lacunae which are small cavities communicating with the sinus and the diploic veins on the one side and with the veins of the dura mater and brain on the other).

- **The occipital sinus** (*sinus occipitalis*) is a continuation, as it were, of the superior sagittal sinus along the attachment of falx cerebelli to the internal occipital crest and then (after bifurcating) along both margins of the foramen magnum of the occipital bone.

- **The straight sinus** (*sinus rectus*) runs on the line of attachment of falx cerebri to tentorium cerebelli. It receives anteriorly the **inferior sagittal sinus** (*sinus sagittalis inferior*) stretching on the free lower margin of falx cerebri and **vena cerebri magna** (Galenii) carrying blood from the deep parts of the brain.

- At the confluence of these sinuses (transverse, superior sagittal, straight, and occipital) a common expansion forms; it is called **the confluence of the sinuses** (*confluens sinuum*), or torcula herophili.

• **The cavernous sinus** (*sinus cavernosus*) is located on the base of the skull lateral to the sella turcica. It has the appearance of either a venous plexus or a wide lacuna surrounding the internal carotid artery. It is connected with a similar sinus on the other side by means of **two** transverse communications, **intercavernous sinuses** (*sinus intercavernosus*), passing in front of and behind the hypophyseal fossa as a consequence of which a **venous circle** forms in the region of the sella turcica.

According to certain data, the cavernous sinus is an intricate anatomical complex whose components, in addition to the sinus itself, are the internal carotid artery, the nerves and the connective tissue surrounding them. All these structures compose, as it were, a special instrument which plays an important role in regulation of the intracranial flow of venous blood. The cavernous sinus receives anteriorly **the superior ophthalmic vein** passing through the superior orbital fissure, as well as the inferior end of **the sphenoparietal sinus** (*sinus sphenoparietalis*) running on the margin of the ala parva. The cavernous sinus is drained of blood by two sinuses located behind it; namely **the inferior and superior petrosal sinuses** (*sinus petrosus superior* and *inferior*) located in the superior and inferior petrosal sulci. Both inferior petrosal sinuses communicate by means of several venous canals which lie within the dura mater on the basal part of the occipital bone and are united under the term **plexus basilaris**. This plexus is connected with the **venous plexuses of the vertebral canal**, into which blood from the cranial cavity flows.

Blood drains from the sinuses mainly into the internal jugular veins, but the sinuses are also connected with the veins of the outer surface of the skull through **emissary veins** (*venae emissariae*) transmitted through openings in the skull bones (foramen parietale, foramen mastoideum, canalis condylaris). Small veins leaving the skull together with nerves through foramen ovale, foramen rotundum and canalis hypoglossi play a similar role. **The diploic veins and the veins of the spongy substance** of the cranial bones also drain into the sinuses of the dura mater, while their other end may be connected with the veins on the external surface of the head. The diploic veins (*venae diploicae*) are canals anastomosing with one another and lined by a layer of endothelium; they pass in the spongy substance of the flat cranial bones.

The following veins flow into v. jugularis interna:

1. The facial vein (*v. facialis*) passes under m. stylohyoideus and m. sternocleidomastoideus. (it sometimes drains into v. jugularis ext.) The veins draining into the facial vein correspond to the branches arising from the facial artery.

2. The posterior facial vein (*v. retromandibularis*) collects blood from the temporal region. Further down, a trunk carrying blood out of the plexus pterygoideus (a dense plexus between mm. pterygoidei) drains into v. retromandibularis after which the vein, passing through the thickness of the parotid gland with the external carotid artery, merges with v. facialis below the angle of the lower maxilla.

The shortest route connecting v. facialis with the pterygoid venous plexus is the "anastomotic vein" (*v. anastomotica facialis*) situated at the level of the alveolar margin of the lower maxilla. Since it connects the superficial and deep veins of the face, the anastomotic vein may spread infection, which may be of importance in practice.

3. The pharyngeal veins (*vv. pharyngeae*) form a plexus on the pharynx and flow either directly into v. jugularis interne or empty into v. facialis.

4. The lingual vein (*v. lingualis*) accompanies the artery of the same name.

5. The superior thyroid veins (*vv. thyroideae superiores*) collect blood from the upper parts of the thyroid gland and the larynx.

6. The middle thyroid vein (*v. thyroidea media*) (more exactly, *lateralis*) arises from the lateral edge of the thyroid gland and drains into v. jugularis interne. At the lower margin of the thyroid gland, there is an unpaired venous plexus, plexus thyroideus impar, which drains through *vv. thyroideae superiores* into v. jugularis interne and also through *vv. thyroideae inferiores* and v. thyroidea ima into the veins of the middle mediastinum.

THE EXTERNAL JUGULAR VEIN

The external jugular vein (*v. jugularis externs*) originates behind the floor of the auricle and emerges at the level of the maxilla angle, from the region behind the mandibular fossa. From there it descends into the subcutaneous tissue covered by m. platysma and travels along the external surface of the sternocleidomastoid muscle, crossing it obliquely downward and posteriorly. On reaching the posterior edge of the sternocleidomastoid muscle, the vein enters the supraclavicular region where it immediately descends

and drains into the subclavian vein, usually in a common trunk with v. jugularis anterior. Behind the floor of the auricle, v. **auricularis posterior** and v. **occipitalis** drain into v. jugularis externa.

THE ANTERIOR JUGULAR VEIN

The **anterior jugular vein** (*v. jugularis anterior*) varies greatly in size and form. It is made up of small branches located over the hyoid bone, from which point it descends. Both the right and left anterior jugular veins perforate the deep fascia colli propriae, enter the spatium interaponeuroticum suprasternale, and drain into the subclavian vein. In the suprasternal space the anterior jugular veins anastomose, with either one or two trunks. Thus a **venous arch**, *arcus venosus juguli*, is formed over the top edge of the sternum and the clavicles. In some cases the right and left veins are replaced by a single unpaired vein, v. jugularis anterior, which descends along the median line and drains below into the venous arch formed, in such instances, by an anastomosis between vv. jugulares externae.

THE SUBCLAVIAN VEIN

The subclavian vein (*v. subclavia*) is a direct continuation of v. axillaris. It is located below and to the front of the subclavian artery, from which it is separated by m. scalenus anterior; behind the sternoclavicular joint the subclavian vein merges with v. jugularis interna. The union creates v. brachiocephalica.

VERTEBRAL VENOUS PLEXUSES

There are four venous vertebral plexuses: two internal and two external). The **internal vertebral plexuses** (*plexus venosi vertebrales interni*) **anterior** and **posterior** are located in the vertebral canal and consist of a venous rings, one for every vertebra. The veins of the spinal cord drain into the internal vertebral plexuses as: vv. basivertebrales, which arise from the posterior surfaces of the vertebral bodies and carry blood from the spongy substance of the vertebrae. The **external vertebral plexuses** (*plexus vertebrales externi*) are, in turn, subdivided into: *the anterior plexus* on the anterior surface of the vertebral bodies (developed mainly in the cervical and sacral regions) and *the posterior plexus* resting on the arches of the vertebrae, covered by deep dorsal and cervical muscles. Blood from the vertebral plexuses is drained in the torso through vv. intervertebrales into vv. intercostales post. and vv. lumbales. Blood in the neck drains mainly into v. **vertebralis**, which flows with the vertebral artery into v. **brachiocephalica** independently or after it has joined v. **cervicalis profunda**.

X-RAY EXAMINATION OF THE BLOOD VESSELS

It is now possible to examine practically all the blood vessels on a living human being röntgenologically using angiography or vasography. The entire length of the aorta or any of its separate parts—ascending, arch, thoracic and abdominal, with the large arteries of the abdominal cavities arising from it (splenic, renal, and others)—may be examined using various types of aortography.

The common carotid artery is studied in arterioencephalography angiography of the brain). The X-rays reveal the division of the artery into the internal and external carotid arteries and their ramification in the region of the head and brain.

The venous system can also be examined in living human beings with the injection of radiocontrast substances and subsequent röntgenography.

This method, called venography, produces the X-ray picture of most of the large (venae cavae, cardiac, and main veins) and small veins.

One of the methods of roentgenological examination of live subjects, electroroentgenography, can reveal the finest ramifications of the blood vessels in parenchymatous organs such as the lungs. As a result, the X-ray picture of the intraorganic vessels in a living human is in no way inferior to one obtained by injection, corrosion, or diminished intensity.

Examination of the vessels of a living human yields more exact anatomical information since it complements this information with physiological data.

THE LYMPHATIC SYSTEM

The **lymphatic system** (*systema lymphaticum*) constitutes part of the vascular system and may be considered a supplementary bed of the venous system. It develops in close relationship with the venous system and shares with it similar structural features (the existence of valves, the direction of the flow of lymph from the tissues to the heart). The main functions of the lymphatic system consist in conducting lymph from the tissues into the venous bed, in rendering harmless the foreign particles, bacteria and so

on, that find their way into the organism, and in forming lymphoid elements (lymphopoiesis), which participate in immunological reactions. In addition, the cells of malignant tumours spread along the lymphatic system; a thorough knowledge of the anatomy of the lymphatic system is essential in determining these paths.

The presence of lymph nodes distinguishes the lymphatic from the venous system. The two systems are further distinguished since the venous capillaries communicate with the arterial capillaries, whereas the lymphatic system is a system of tubes closed at one end (the peripheral end) and opening at the other end (central) into the venous bed.

The lymphatic system consists of the following parts:

(1) the closed end of the lymphatic bed begins with a meshwork of lymph capillaries piercing the tissue of the organs;

(2) the lymph capillaries develop into intraorganic plexuses of small lymphatic vessels possessing valves;

(3) these vessels emerge from the organs in the form of still larger, extraorganic, abducent lymphatic vessels interrupted by **lymph nodes**;

(4) the large lymphatic vessels drain into collectors and, further, into the main lymph trunks of the body right and left (thoracic) lymphatic ducts, which, in their turn, drain into the big veins of the neck.

The lymph capillaries absorb and resorb colloid solutions of protein substances that are not absorbed by the blood capillaries from the tissues. The lymph capillaries also help the veins to drain the tissues by absorbing aqueous fluid and the crystalloids dissolved in it. They also remove foreign particles, bacteria, and so on from the tissues under pathological conditions. The lymph capillaries perform these functions through a system of endothelial tubes that penetrate all organs of the body except the brain, splenic parenchyma, epithelial coat of the skin and mucous membranes, cartilages, cornea, lens of the eye, and placenta.

The structure of the initial lymphatic networks varies. It is determined by the structure and function of the organ and the properties of the connective tissue in which the lymph capillaries have been laid. The direction of the loops of these capillaries corresponds to the direction and position of the fasciculi of connective tissue, muscle fibres, glands, and other structural cements of the given organ.

Lymphatic vessels. The transition of **lymph capillaries** into lymphatic vessels is determined by changes in the structure of the wall and the appearance of a valve in the vessel, which serves as a border between it and the capillary. The intraorganic lymphatic vessels form widely looped plexuses and run parallel to the blood vessels in the connective-tissue layers of the organ. Abducent lymphatic vessels (extraorganic) leading to various lymph nodes arise from every organ or part of the body. *The collectors* are the main lymphatic vessels, which form when the secondary and attendant arteries or veins join. After passing through the last group of lymph nodes, the lymph collectors form lymph trunks, corresponding in number and position to the large parts of the body.

Thus, the main lymph trunk for the lower limb and pelvis is the **truncus lumbalis**, which forms from the efferent vessels of the lymph nodes located by the aorta and vena cava inferior. For the upper extremity the main lymph trunk is the **truncus subclavius** which passes along v. subclavia. The head and neck are supplied by the **truncus jugularis** passing along v. *jugularis interna*. In addition, the thoracic cavity is served by the paired **truncus bronchomediastinalis**. The **unpaired truncus intestinalis** is sometimes encountered in the abdominal cavity. All these trunks eventually join in two terminal ducts: the **ductus lymphaticus dexter** and **ductus thoracicus**, which drain into the large veins, mainly the internal jugular vein.

Lymph nodes. Before entering the thoracic duct or the right lymphatic duct, the lymph passes through several lymph nodes, *nodi lymphatici* s. *lymphonodi*, which are situated singly or, more frequently, in groups on the paths of the lymphatic vessels. The nodes are round or oval formations, ranging in size from a grain of wheat to a bean. The lymph node is covered by a connective tissue capsule from which the septa trabeculae protrude into the node. Lymphoid tissue, in the form of cortical, paracortical (paracortical zone), or cerebral matter, lies between the trabeculae. There are spaces lymphatic sinuses) between the trabeculae and the lymphoid tissue. The lymph comes to the lymph node through afferent lymphatic vessels, *vasa afferentia*, which enter its convex side and open into sinuses. There are special cells (macrophages) in the walls of the lymphatic sinuses which accomplish phagocytosis of foreign bodies brought by the flowing lymph. In the sinuses the lymph flow slows down and sweeps along with it the lymphocytes forming in the tissue of the node; the lymph then departs through efferent lymph vessels, *vasa efferentia*, which exit through the porta on the concave side of the node.

Thus, lymph nodes are distinguished from **lymphoid organs and tonsils**, which have only efferent lymphatic vessels and lack afferent lymphatic vessels. The lymphatic vessels of any organ pass through certain regional groups of nodes located near the given organ. The regional nodes for the internal organs are usually located at their hilum. In the "soma" large accumulations of lymph nodes are situated in protected and mobile places near the joints, the movements of which help the lymph to pass through the nodes. Thus, large groups of nodes are concentrated on the lower extremity in the popliteal fossa and the groin; on the upper extremity by the elbow joint and the axillary fossa; on the trunk in the lumbar region and the neck, i.e., near the most mobile parts of the spinal column.

The lymph nodes have arteries and veins which are branches (arteries) and affluents (veins) of neighbouring vessels. The nodes are also characterized by afferent and efferent innervation. Since lymph nodes can arrest foreign bodies (bacteria, tumorous cells, etc.) that enter them through the lymphatic vessels, substances of pathogenic origin may accumulate in the nodes. Knowledge of their topography can be of great diagnostic and therapeutic significance.

THE LYMPHATICS OF THE HEAD AND NECK

Lymph from the head and neck collects in the **right and left jugular lymph trunks**, *the truncus jugularis dexter et sinister*, which run on each side of the neck parallel to the internal jugular vein. The right trunk drains into the ductus lymphaticus dexter or directly into the right venous angle, the left into ductus thoracicus or directly into the left venous angle. Before flowing into the duct the lymph passes through the regional lymph nodes.

On the head lymph nodes group mainly along the border between the head and the neck. Among these groups of nodes we can note the following:

1 **Occipital lymph glands** (*nodi lymphatici occipitales*) drain the lymphatic vessels coming from the posteroexternal part of the temporal, parietal, and occipital regions of the head.

2. **Mastoid lymph glands** (*nodi lymphatici retro-auriculares*) collect lymph from the same areas as the occipital nodes as well as from the posterior surface of the floor of the auricle, the external acoustic meatus, and the tympanic membrane.

3. **Parotid lymph glands** (*nodi lymphatici parotidei*), **superficiales** and **profundi**, collect lymph flowing from the forehead, temple, lateral part of the eyelids, external surface of the floor of the auricle, temporomandibular joint, parotid and lacrimal glands, walls of the external acoustic meatus, tympanic membrane, and both auditory tubes.

4. **Submandibular lymph glands** (*nodi lymphatici submandibulares*) collect lymph from the lateral side of the chin, the upper and lower lips, cheeks, nose, gums and teeth, medial part of the eyelids, hard and soft palates, 1-Jody of the tongue, and submandibular and sublingual salivary glands.

5. **Mandibular lymph glands** (*nodi lymphatici mandibulares*) collect lymph from the eyeball, muscles of facial expression, mucous surface of the cheek, lips, and gums, muciparous glands of the oral cavity, periosteum of the region of the mouth and nose, and submandibular and sublingual glands.

6. **Submental lymph glands** (*nodi lymphatici submentales*) collect lymph from the same regions of the head as the mandibular nodes, as well as from the tip of the tongue.

7. **Buccal lymph glands** (*nodi lymphatici buccales*) collect lymph from the mucous membrane of the cheek and the cheek muscle.

8. **Retropharyngeal lymph glands** (*nodi lymphatici retropharyngei*) drain lymph from the mucous membrane of the nasal cavity and its accessory air-passage cavities, from the hard and soft palates, the root of the tongue, nasal and oral parts of the throat, as well as from the middle ear.

Lymph from the above nodes flows to the cervical nodes.

On the neck there are two groups of lymph nodes: **superficial** (*nodi lymphatici cervicales superficiales*) and **deep** (*nodi lymphatici cervicales profundi*).

The **superficial lymph nodes** are divided into **anterior nodes**, located below the hyoid bone between the two main neurovascular nodes of the neck, and the **lateral nodes**, situated along v. jugularis externa.

The **deep lymph nodes** form a chain along the length of v. jugularis interne as well as along the nerves of the spinal cord and a. transverse colli. They play a major role in the outflow of lymph from the organs and tissues of the head and neck. It is possible to distinguish nodes in front of the larynx, the thyroid gland, and the trachea, nodes running parallel to the sides of the trachea along the recurrent nerves, and supraclavicular nodes. All deep cervical lymph nodes can be divided generally into two large groups: **superior** and **inferior**.

Among the superior deep cervical lymph nodes, the *nodus lymphaticus jugulodigastricus* deserves special attention. Located on the internal jugular vein at the level of the greater horn of the hyoid bone, this node receives lymph from the vessels of the posterior third of the tongue and becomes greatly enlarged when this part of the tongue is affected by cancer.

The *nodus lymphaticus jugulo-omohyoideus* is one of the most important of the inferior deep cervical lymph nodes. This node lies on the internal jugular vein directly over *m. omohyoideus*. It receives the lymphatic vessels of the tongue either directly or through the mental or submaxillary lymph nodes, which may contain cancerous cells.

The lymphatic vessels of the skin and muscles of the neck pass to *nodi lymphatici cervicales superficiales*. Those of the larynx (the lymph plexus of the mucosa above the vocal chords) flow through the membrane *thyreochoidea* to *nodi lymph. cervicales profundi (superiores)*. The lymphatic vessels of the mucosa below the rima glottidis pass along two routes—forward through the membrane *thyreochoidea* to *nodi lymph. cervicales profundi (prelaryngeal)* and backward to the nodes located along *n. laryngeus recurrens (tracheal)*. The lymphatic vessels of the thyroid gland flow mainly to *nodi lymph. cervicales profundi (prethyroid)* and from the isthmus to the anterior superficial cervical nodes. From the pharynx and palatine tonsils, lymph flows to *nodi lymph. retropharyngei* and *cervicales profundi*.

THE COLLATERAL FLOW OF THE LYMPH

In case of occlusion or cutting of the lymphatic vessels, the surgical removal of the lymph nodes, their occlusion by cancer cells, or affection by chronic inflammatory processes, the natural patency of the lymph bed is disturbed and the lymph can no longer flow in the usual direction. The lymphatic system, however, has developed certain functional adaptations to restore the disturbed flow. If necessary, neighbouring auxiliary lymphatic vessels, which had not served previously as the main channels for the outflow of lymph from a given organ or part of the body, may become the principal or even the sole channels for draining lymph. The lymph thus begins to flow along direct lateral routes in what is called indirect or collateral lymph circulation, or to be more precise, collateral lymph flow. Changes in the direction of the lymph flow caused by obstruction are important in the development of collateral lymph flow.

Under normal conditions the lymph flow is directed by the valves of the lymphatic vessels to the right and left venous angles, where it drains into the vascular bed. Thus, collateral lymph flow to bypass obstacles along the main route is possible only when the direction in which the lymph flows is changed, i.e., only when the flow of lymph is reversed (retrograde). Distal to the obstruction, the lymph stagnates and the lymphatic vessels dilate; the valves weaken and the lymph reverses the direction of flow.

Thus, the system of collateral lymph flow involves normally existing auxiliary routes (collaterals) and newly developed lymphatic vessels which connect the segments of the disrupted route (anastomoses). The collateral lymph flow is important in understanding and predicting the spread of malignant tumours and infectious processes.

ANATOMY OF THE LYMPHATIC SYSTEM OF A LIVING PERSON

Roentgenolymphography makes it possible to see the lymphatic vessels and nodes on a live subject.

The method is currently used to study the lymphatic vessels of the limbs, pelvis, thoracic gland, tongue, and the abdominal cavity. The method reveals the thoracic duct in its entire length. There are currently two types of roentgenolymphography:

1) **indirect**, when the X-ray contrast medium is infused into the skin, under the skin, or into the thickness of the tissue. A "depot" of the medium is thus created; it is absorbed along the lymphatic vessels and produces shadows of the vessels and nodes on the radiograph;

2) **direct**, when the X-ray contrast medium is injected directly into the lymphatic vessel; the picture of the lymphatic channel in any part of the body is produced by this method. The radiograph shows the networks of lymphatic vessels, the larger collectors that form from these vessels with clearly outlined thickenings at the valves, the merger of lymph collectors into lymphatic trunks and ducts, and, finally, the drainage of the ducts into venous angles. The shadows of lymph nodes can also be seen very well, and one can judge the shape, size, position, and number of nodes by these shadows.

The entry and exit of the vessels into and from the nodes is clearly visible with the afferent lymphatic vessels flowing in the convex side of the node and the efferent vessels flowing out of the porta of the node on the concave side.

In general, most of lymphatic vessels and nodes of a given part of the body are investigated on cadavers, while roentgenography is used on living persons only to study those vessels and nodes where lymph from the part of the body, where a "depot" of X-ray contrast substance has been created, is flowing at the moment the X-ray is taken.

A special apparatus called the kymograph makes it possible to judge the efficacy of lymph circulation. Using the kymograph it is possible to observe the contraction of the large lymphatic ducts (pulsation) in a series of photographs and to check the velocity at which lymph flows.

Thus, the roentgenological method offers a number of advantages for studying the lymphatic system since it makes it possible to study the system directly on the living human body without disrupting natural anatomical relationships, which is inevitable in dissection. Roentgenolymphography also makes it possible to study the relationship of the lymphatic bed to the bones (skeletal) and to the blood vessels, if vasography (syntopy) is performed simultaneously with the projection of the large lymphatic ducts and nodes on the skin (holotopy).

DEVELOPMENT OF THE ARTERIES

In reflection of the change from branchial to pulmonary circulation in the process of phylogenesis, the branchial arteries are the first to differentiate during ontogenesis in man; later they evolve into arteries of pulmonary and systemic circulation. In the embryo at three weeks, the truncus arteriosus, as it leaves the heart, gives rise to two arterial trunks called the ventral aortas (right and left). They ascend, curve ventrally over the anterior gut in front of the right branchial pocket, and then return to the dorsal surface of the embryo; here they descend on both sides of the notochord and are called dorsal aortas. The dorsal aortas gradually converge in the middle segment of the embryo to form an unpaired descending aorta. With the gradual development of visceral arches in the cephalic end of the embryo, a branchial aortic arch or artery develops in each of them; these branchial arteries connect the ventral to the dorsal artery on each side. Thus, in the region of the visceral (branchial) arches, the ventral (ascending) and dorsal (descending) aortas are connected by six pairs of branchial arteries.

Part of the branchial arteries and part of the dorsal aortas (the right one, in particular) ultimately reduce, while the remaining primary vessels give rise to large precardiac and arterial trunks; as pointed out above, the truncus arteriosus is divided by the frontal septum into a ventral part, from which the pulmonary trunk is derived, and a dorsal part, which transforms into the ascending aorta. This explains the position of the aorta behind the pulmonary trunk. In following the flow of blood from the centre to the periphery, we observe that the last pair of branchial arteries, connected in lungfish and amphibians with the lung, is transformed in man into the right and left pulmonary arteries, which are branches of the pulmonary trunk (truncus pulmonalis). The sixth branchial artery on the right remains only as a small proximal segment; the artery on the left, in contrast, continues the entire distance and forms Botallo's duct (ductus arteriosus Botalli), which connects the pulmonary trunk with the end of the aortic arch, a fact of significance for circulation in the foetus. The fourth pair of branchial arteries continues the whole distance on both sides, but gives rise to different vessels. The fourth branchial artery on the left, together with the left ventral aorta and part of the left dorsal aorta, forms the arch of aorta (arcus aortae).

The proximal segment of the right ventral artery transforms into the brachiocephalic trunk (truncus brachiocephalicus). The fourth branchial artery on the right transforms into the initial part of the right subclavian artery (a. subclavia dextra) arising from this trunk. The left subclavian artery grows from the left dorsal aorta caudal to the last branchial artery. The dorsal aortas located between the third and fourth branchial arteries obliterate; the right dorsal aorta also obliterates from the site of origin of the right subclavian artery until it merges with the left dorsal aorta.

In the segment between the third and fourth aortic arches, both ventral aortas transform into the common carotid arteries (arteriae carotides communes); as a consequence of the transformations of the proximal segment of the ventral aorta described above, the right common carotid artery arises from the brachiocephalic trunk, while the left common carotid artery branches directly from the arcus aortae. Further, the ventral aortas transform into the external carotid arteries (arteriae carotides externae).

The third pair of branchial arteries and the dorsal aortas on the segment between the third and the first branchial arches develop into the internal carotid arteries (arteriae carotides internae). The internal carotid arteries in an adult, therefore, are located more laterally than the external arteries. The second pair of branchial arteries transforms into the lingual and pharyngeal arteries (arteriae linguales and pharyngeae), while the first pair transforms into the mandibular, facial, and temporal arteries. Various anomalies

occur when the usual course of development is disturbed. Absence of the pulmonary trunk has been described.

Some small paired vessels passing dorsally on both sides of the neural tube are derived from the dorsal aorta. They are called *dorsal segmental arteries* because they arise at regular intervals into the loose mesenchymal tissue found between the somites. In the region of the neck on both sides of the body, they are connected early by a series of anastomoses and form longitudinal vessels, the *vertebral arteries*.

DEVELOPMENT OF THE VEINS

In the beginning of placental circulation when the heart is in the cervical region and is still not separated by septa into the venous and arterial halves, the venous system is relatively simple in structure. Large veins stretch along the body of the embryo: the anterior cardinal veins (right and left) in the region of the head and neck and the right and left posterior cardinal veins in the remaining part of the body. On reaching the venous sinus of the heart, the anterior and posterior cardinal veins on each side merge to form the ducts of Cuvier (right and left), which at first pass strictly transversely and drain into the venous sinus of the heart. Besides the paired cardinal veins, there is one unpaired venous trunk, the primary vena cava inferior, which as a small vessel also drains into the venous sinus. Thus, three venous trunks drain into the heart in this developmental stage, namely, the paired ducts of Cuvier and the unpaired primary vena cava inferior.

Further changes in the position of the venous trunk are associated with the descent of the heart from the region of the neck and the separation of its venous section into the right and left atria. Since both ducts drain into the right atrium, after separation of the heart, the blood flow in the right Cuvier's duct occurs under more favourable conditions. As a result, an anastomosis forms between the right and left anterior cardinal veins along which the blood from the head flows into the right Cuvier's duct. As a consequence, the left Cuvier's duct ceases to function. Its walls collapse and it obliterates, except for a small segment, which becomes the coronary sinus of the heart (*sinus coronarius cordis*). The anastomosis between the anterior cardinal veins gradually increases and transforms into the left brachiocephalic vein, while the left anterior cardinal vein obliterates below the origin of the anastomosis.

The right anterior cardinal vein gives rise to two vessels: the segment above the site of drainage of the anastomosis develops into the right brachiocephalic vein, and the segment below the anastomosis transforms, together with the right duct of Cuvier, into the superior vena cava, which thereupon collects blood from the entire cranial half of the body. A developmental anomaly in the form of two superior venae cavae may occur in underdevelopment of these anastomoses.

The formation of the inferior vena cava is associated with the appearance of anastomoses between the posterior cardinal veins. An anastomosis found in the iliac region drains blood from the left lower limb into the right posterior cardinal vein; as a result, the segment of the left posterior cardinal vein above the anastomosis reduces, while the anastomosis itself transforms into the left common iliac vein. The right posterior cardinal vein in the segment proximal to the anastomosis (which has become the left common iliac vein) transforms into the right common iliac vein, while the segment beginning from the merger of both iliac veins and ending at the place of drainage of the renal veins develops into the secondary inferior vena cava. The remaining section of the secondary inferior vena cava forms from the unpaired primary inferior caval vein which drains into the heart and merges with the right inferior cardinal vein where the renal veins join it (here we have the second anastomosis between the cardinal veins draining the blood from the left kidney). The inferior vena cava is, therefore, ultimately formed of two parts: the right posterior cardinal vein (prior to the place where it receives the renal veins) and the primary inferior caval vein (distal to this). Since the inferior vena cava brings blood to the heart from the entire caudal part of the body, the posterior cardinal veins become less important; their development is retarded, and they transform into the azygos vein (right posterior cardinal vein) and the hemiazygos and accessory hemiazygos veins (left posterior cardinal vein). The hemiazygos vein drains into the azygos vein through the third anastomosis developing in the thoracic region between the former posterior cardinal veins.

Capitolul V. THE PERIPHERAL PART OF THE NERVOUS SYSTEM

ANIMAL, OR SOMATIC, NERVES

The nerve trunks are divided according to the place where they branch off from the central nervous system: the spinal nerves (*nn. spinales*) branch off from the spinal cord while the cranial nerves (*nn. craniales*) arise from the brain.

THE SPINAL NERVES

The spinal nerves (*nn. spinales*) are located in regular order (neuromeres) corresponding to the myotomes (myomeres) of the trunk and alternate with the segments of the spine; every nerve is attended by a corresponding area of skin (dermatome).

Man has 31 pairs of spinal nerves: 8 pairs of cervical, 12 pairs of thoracic, 5 pairs of lumbar, 5 pairs of sacral and 1 pair of coccygeal nerves. Every spinal nerve branches off from the spinal cord in two roots: the dorsal or posterior (sensory) root, and the ventral or anterior (motor) root. Both roots are joined in one trunk, or funiculus which passes from the spine through an intervertebral orifice. Near and somewhat externally of the place where the roots join, the posterior root forms the ganglion spinale or ganglion intervertebrale in which the anterior motor root does not participate. Since both roots are joined the spinal nerves are mixed nerves; they contain sensory (afferent) fibres from the cells of the spinal ganglia, motor (efferent) fibres from the cells of the anterior horn, and also vegetative fibres from the cells of the lateral horns emerging from the spinal cord as part of the anterior root.

On emerging from the intervertebral orifice every cerebrospinal nerve divides, according to two parts of the myotome (dorsal and ventral), into two branches:

(1) the posterior, dorsal branch (*ramus dorsalis*) for the autochthonous muscles of the back developing from the dorsal part of the myotome and the skin covering it;

(2) the anterior, ventral branch (*ramus ventralis*) for the ventral wall of the trunk and the limbs, developing from the ventral parts of the myotomes.

Besides this, another two kinds of branches arise from the cerebrospinal nerve:

(3) the communicating branches (*rami communicantes*) to the sympathetic trunk for innervating the internal organs;

(4) the meningeal branch (*ramus meningeus*) passing back through the intervertebral orifice for innervating the membranes of the spinal cord.

THE POSTERIOR BRANCHES OF THE SPINAL NERVES

The posterior branches (*rami dorsales*) of all the cerebrospinal nerves pass backward between the transverse processes of the vertebrae, curving around their articular processes. With the exception of the first cervical, fourth and fifth sacral and coccygeal branches, they all divide into the medial branch (*ramus medialis*) and lateral branch (*ramus lateralis*) which supply the skin of the back of the head, the posterior surface of the neck and back and the deep dorsal muscles.

The posterior branch of the first cervical nerve, *n. suboccipitalis*, emerges between the occipital bone and the atlas and then divides into branches supplying *mm. recti capitis major* and *minor*, *m. semispinalis capitis*, *m. obliqui capitis*. *N. suboccipitalis* does not give off branches to the skin. The posterior branch of the second cervical nerve, the greater occipital nerve (*n. occipitalis major*) coming out between the posterior arch of the atlas and the second vertebra, pierces the muscles and, having become subcutaneous, innervates the occipital part of the head.

THE ANTERIOR BRANCHES OF THE SPINAL NERVES

The anterior branches (*rami ventrales*) of the spinal nerves innervate the skin and muscles of the ventral wall of the body and both pairs of limbs. Since the skin of the lower abdomen participates in the development of the external sexual organs, the skin covering them is also innervated by the anterior branches. Except for the first two, the anterior branches are much larger than the posterior branches.

The anterior branches of the spinal nerves preserve their original metameric structure only in the thoracic segment (**nn. intercostales**). In the other segments connected with the limbs in whose development the segmentary character is lost, the nerves arising from the anterior spinal branches intertwine. This is how nervous plexuses are formed in which exchange of fibres of different neuromeres takes place. A complex redistribution of fibres occurs in the **plexuses**: the anterior branch of every spinal nerve sends its fibres into several peripheral nerves and, consequently, each of them contains fibres of several segments of the spinal cord. It is therefore understandable that lesion of a nerve arising from the plexus is not attended by disturbed function of all the muscles receiving innervation from the segments which gave origin to this nerve.

Most of the nerves emerging from plexuses are mixed; this is why the clinical picture of the lesion is made up of motor disorders, sensory disorders and vegetative disorders.

Three large plexuses are distinguished: **cervical, brachial and lumbosacral**.

THE CERVICAL PLEXUS

The **cervical plexus** (*plexus cervicalis*) is formed by the anterior branches of **four superior cervical nerves** (C1-C4) which are connected by three arching loops and are located laterally of the transverse processes between the prevertebral muscles from the medial side and vertebral (*m. scalenus medius, m. levator scapulae* and *m. splenius cervicis*) from the lateral side, anastomosing with *n. accessorius, n. hypoglossus* and *tr. sympathicus*. In front the plexus is covered by *m. sternocleidomastoideus*.

The branches arising from the plexus are divided into cutaneous, muscular and mixed.

The cutaneous branches:

1. **The lesser occipital nerve** (*n. occipitalis minor*) (from C1 and C2) runs to the skin of the lateral part of the occipital region.

2. **The great auricular nerve** (*n. auricularis magnus*) (from C3), the thickest nerve of the cutaneous branches of the cervical plexus, passes

3. **The anterior cutaneous nerve of the neck** (*n. transversus colli*) (from C2-3) arises, like the preceding two nerves, from the middle of the posterior edge of *m. sternocleidomastoideus* and divides into branches which curve around the posterior edge of the sternocleidomastoid muscle and pass over its external surface forward and down under the *m. platysma*, supplying the skin of the neck.

4. **The supraclavicular nerves** (*nn. supraclaviculares mediales, intermedii and laterales*) (from Cm and Civ) descend under the *platysma* nearly perpendicularly along the supraclavicular fossa into the skin above the *pectoralis major* and *deltoideus*.

The muscular branches:

1. **Branches** to the *mm. recti capitis anterior* and *lateralis, mm. longus capitis* and *colli, mm. scaleni, m. levator scapulae* and, finally, to *mm. intertransversarii anteriores*.

2. **Radix inferior**, arising from C2-C4, passes in front of the *v. jugularis interna* under the sternocleidomastoid muscle and at the intermediary tendon of the *m. omohyoideus* joins with *radix superior* forming a cervical loop (**ansa cervicalis**) with this branch. By means of the branches arising from the *ansa*, the fibres of the cervical plexus innervate the *m. sternohyoideus, m. sternothyreoideus* and *m. omohyoideus*.

3. **Branches to the m. sternocleidomastoideus and m. trapezius** (from C3 to C4) which participate in the innervation of these muscles together with the accessory nerve.

The mixed branches:

1. **The phrenic nerve** (*n. phrenicus*) (C3-C5) descends along *m. scalenus anterior* into the thoracic cavity where it passes between the subclavian artery and vein. Further the **right phrenic nerve** descends nearly vertically in front of the root of the right lung and passes along the lateral surface of the pericardium to the diaphragm. The **left phrenic nerve** crosses the anterior surface of the *aortic arch* and passes in front of the root of the left lung along the left lateral surface of the pericardium to the diaphragm. Both nerves pass in the anterior mediastinum between the pericardium and pleura. The phrenic nerve receives fibres from two inferior cervical ganglia of the sympathetic trunk. The phrenic nerve is a mixed nerve: **its motor branches** innervate the diaphragm thus functioning as a nerve that is responsible for respiration; it sends **sensory nerves** to the pleura and pericardium. Some of the terminal branches of the nerve pass through the diaphragm into the abdominal cavity (**nn. Phrenicoabdominales**) and anastomose with the sympathetic plexus of the diaphragm, sending small branches to the *peritoneum, the hepatic ligaments* and to the liver itself; as a result, when liver is affected, a *special phrenicus-symptom* may arise. There is

information pointing to more extensive innervation by the phrenic nerve; it is presumed that with its fibres in the thoracic cavity it supplies the heart, lungs, the thymus gland, and in the peritoneal cavity it is connected with the solar plexus through which it innervates certain internal organs.

THE CRANIAL NERVES

(NN. CRANIALES S. NN. CEREBRALES [BNA] seu NN. ENCEPHALICI)

There are twelve pairs of cranial nerves: I, n. olfactorius; II, n. opticus; III, n. oculomotorius; IV, n. trochlearis; V, n. trigeminus; VI, n. abducens; VII, n. facialis; VIII, n. vestibulocochlearis; IX, n. glossopharyngeus; X, n. vagus; XI, n. accessorius; XII, n. hypoglossus.

The cranial nerves have some features that distinguish them from the spinal nerves. These features mainly depend on the different conditions under which the brain and the head developed as compared with the spinal cord and trunk. Before all else, the first two cranial nerves connected with the prosencephalon in their character and origin occupy quite a different place among all the nerves. They are outgrowths of the brain. Although the other cranial nerves are not different in principle from the cerebrospinal nerves, they are nonetheless characterized by the fact that not a single one of them fully corresponds to the cerebrospinal nerve that is composed of an anterior and a posterior root. Each of the cranial nerves is either one of these two roots which in the region of the head are never joined together; this resembles similar relations existing among cerebrospinal nerves of primitive vertebrates. The third, fourth, sixth and twelfth cranial nerves correspond to the anterior roots of the cerebrospinal nerves, while the fifth, seventh, eighth, ninth and tenth nerves are homologous with the posterior roots.

The cranial nerves, like the spinal nerves, have nuclei of grey matter: the somatic-sensory (corresponding to the posterior horns of the grey matter of the spinal cord), the somatic-motor (corresponding to the anterior horns) and vegetative (corresponding to the lateral horns). These last may be divided into visceral-sensory and visceral-motor of which the visceral-motor nerves innervate not only the smooth muscles, but the striated muscles of visceral origin. Taking into account that the visceral striated muscles have acquired the features of somatic muscles, all the nuclei of the cranial nerves bearing relation to striated muscles, irrespective of their origin, should best be designated as somatic-motor nerves.

As a result, the composition of the cranial nerves includes the same components as there are in the cerebrospinal nerves.

Afferent components.

1. **Somatic-sensory** fibres emerging from the organs appreciating physical stimuli (pressure, temperature, sound and light), i.e. from the skin, the organs of hearing and vision; second, fifth, eighth.

2. **Visceral-sensory** fibres arising from the organs which appreciate chemical stimuli (by particles of various substances dissolved or suspended in a surrounding medium, or in internal cavities), i.e. from the nerve endings in the digestive organs and other internal organs, from special organs of the pharynx, the oral (organs of taste) and nasal (olfactory organs) cavities; the first, fifth, seventh, ninth, tenth.

Efferent components.

3. **Somatic-motor** fibres innervating the striated muscles, namely: the parietal muscles originating from the cephalic myotomes, the ocular muscles (third, fourth, sixth), and the sublingual muscles (twelfth), and also the muscles which became part of the first portion of the digestive tract later; these muscles of the skeletal (somatic) type belonged to the visceral (branchial) apparatus and in mammals and man became the muscles of mastication and facial expression, etc. (fifth, seventh, ninth, tenth, eleventh).

4. **Visceral-motor** fibres innervating the visceral muscles, i.e. the smooth muscles of the vessels and internal organs (organs of digestion and respiration), the heart muscle and various kind of gland (secretory fibres); seventh, ninth, tenth.

Sympathetic fibres from corresponding sympathetic ganglia are included as components of the motor nerves to the same organs.

Out of the twelve pairs of cranial nerves the somatic-sensory is the eighth nerve, the somatic-motor are the third, fourth, sixth, eleventh and twelfth nerves. The remainder (fifth, seventh, ninth, tenth) are mixed nerves.

The olfactory nerve, which may be called visceral-sensory, and the visual nerve, somatic-sensory, occupies a special place as it was mentioned above.

The small number of somatic-motor nerves as compared with the rest is connected with the reduction of cephalic myotomes which give rise only to ocular muscles. The development of mixed nerves containing visceral components is connected with the evolution of the anterior part of the alimentary tube

(grasping and respiratory) in the region of which the visceral apparatus develops with a complex sensory area and considerable musculature.

The cranial nerves are usually designated by numbers from first to twelfth. To be true to the historical principle, however, they should be taken in reverse order, corresponding to the development of different parts of the brain.

NERVES DEVELOPING BY UNION OF THE SPINAL NERVES

One nerve, n. hypoglossus, belongs to this group. **THE HYPOGLOSSAL (12th) NERVE**

NERVES OF THE VISCERAL ARCHES

The fifth, seventh, ninth and tenth cranial nerves belong to this group. As homologues of the posterior roots of the spinal nerves they possess nerve ganglia located outside the brain that contain pseudo-unipolar cells. These nerves develop in association with the hindbrain. Together with sensory fibres they also contain motor fibres that innervate the muscles of the visceral (branchial) apparatus and are nerves of the visceral arches.

A typical visceral nerve innervating the visceral (branchial) arch in fish usually consists of an epibranchial ganglion (ganglion epibranchiale) (Gk branchiae gills), a prebranchial branch (ramus pretrematicus) consisting of sensory fibres, and a postbranchial branch (ramus post-trematicus) containing both sensory and motor fibres. The sensory fibres of both branches are the processes of neurons lying in the suprabranchial ganglion, while the motor fibres by-pass the ganglion as in the cerebrospinal nerve. These characteristic structural features of a typical visceral nerve will be manifested more or less in the structure of the above mentioned nerves. In this group we shall also describe the eleventh pair, n. accessorius, which separated from the tenth nerve, and the eighth pair, n. vestibulocochlearis. The latter is an afferent nerve that separated in the developmental process from the facial nerve. For this reason it will be described after the seventh pair, although it does not belong to the nerves of the visceral arches.

NERVES DEVELOPED IN ASSOCIATION WITH CEPHALIC MYOTOMES

This group includes the third, fourth and sixth pairs of cranial nerves corresponding to the anterior roots of the nerves. They originated in association with the mesencephalon, in which their nuclei are lodged. The nucleus of the sixth pair was displaced a second time from the mesencephalon to the region of the rhomboid fossa. These nerves are the motor roots of the cephalic myotomes, and this is why they innervate the muscles of the eyeball, which developed from these myotomes.

NERVES ARISING FROM THE BRAIN

This group contains nn. olfactorii and n. opticus which grow from the brain and are therefore considered to be pseudonerves.

NN. OLFACTORII; FIRST NERVE

The **olfactory nerves** or **nerves of smell** are distributed to the mucous membrane of the olfactory region of the nasal cavity: this region comprises the superior nasal concha, and the corresponding part of the nasal septum. The nerves originate from the central or deep processes of the olfactory cells of the nasal mucous membrane. They form a plexiform net-work in the mucous membrane, and are then collected into about twenty branches, which pierce the cribriform plate of the ethmoid bone in two groups, a **lateral** and a **medial group**, and end in the glomeruli of the olfactory bulb.

Each branch receives tubular sheaths from the dura mater and pia mater, the former being lost in the periosteum of the nose, the latter in the neurolemma of the nerve. The olfactory nerves are non-medullated, and consist of axis-cylinders surrounded by nucleated sheaths, in which, however, there are fewer nuclei than are found in the sheaths of ordinary non-medullated nerve fibers.

The olfactory center in the cortex is generally associated with the rhinencephalon, located in parahippocampal gyrus and uncus.

The olfactory nerves are developed from the cells of the ectoderm which lines the olfactory pits; these cells undergo proliferation and give rise to what are termed the **olfactory cells** of the nose. The axons of the olfactory cells grow into the overlying olfactory bulb and form the olfactory nerves.

N. OPTICUS; SECOND NERVE

The **optic nerve**, or **nerve of sight**, consists mainly of fibers derived from the ganglionic cells of the retina. These axons terminate in arborizations around the cells in the lateral geniculate body, pulvinar, and

superior colliculus which constitute the lower or primary visual centers. From the cells of the lateral geniculate body and the pulvinar fibers pass to the cortical visual center, situated in the cuneus and in the neighborhood of the calcarine fissure. A few fibers of the optic nerve, of small caliber, pass from the primary centers to the retina and are supposed to govern chemical changes in the retina and also the movements of some of its elements (pigment cells and cones). There are also a few fine fibers, afferent fibers, extending from the retina to the brain, that are supposed to be concerned in pupillary reflexes.

The optic nerve is peculiar in that its fibers and ganglion cells are probably third in the series of neurons from the receptors to the brain. Consequently the optic nerve corresponds rather to a tract of fibers within the brain than to the other cranial nerves. Its fibers pass backward and medialward through the orbit and optic canal to the optic commissure where they partially decussate. The mixed fibers from the two nerves are continued in the optic tracts, the **primary visual centers of the brain**.

The orbital portion of the optic nerve is from 20 mm. to 30 mm. in length and has a slightly sinuous course to allow for movements of the eyeball. It is invested by an outer sheath of dura mater and an inner sheath from the arachnoid which are attached to the sclera around the area where the nerve fibers pierce the choroid and sclera of the bulb. A little behind the bulb of the eye the central artery of the retina with its accompanying vein perforates the optic nerve, and runs within it to the retina. As the nerve enters the optic canal (**the canalicular portion**) its dural sheath becomes continuous with that lining the orbit and the optic canal. In the optic canal the ophthalmic artery lies below and to its outer side. **The intercranial portion** of the optic nerve is about 10 mm. in length.

The **Optic Chiasma** (*chiasma opticum*), somewhat quadrilateral in form, rests upon the tuberculum sellae and on the anterior part of the diaphragma sellae. It is in relation, *above*, with the lamina terminalis; *behind*, with the tuber cinereum; on *either side*, with the anterior perforated substance. Within the chiasma, the optic nerves undergo a partial decussation. The fibers forming the medial part of each tract and posterior part of the chiasma have no connection with the optic nerves. They simply cross in the chiasma, and connect the medial geniculate bodies of the two sides; they form the **commissure of Gudden**. The remaining and principal part of the chiasma consists of two sets of fibers, crossed and uncrossed. The **crossed fibers** which are the more numerous, occupy the central part of the chiasma, and pass from the optic nerve of one side to the optic tract of the other, decussating in the chiasma with similar fibers of the opposite optic nerve. The **uncrossed fibers** occupy the lateral part of the chiasma, and pass from the nerve of one side into the tract of the same side.

The crossed fibers of the optic nerve tend to occupy the medial side of the nerve and the uncrossed fibers the lateral side. In the optic tract, however, the fibers are much more intermingled.

The **Optic Tract** passes backward and outward from the optic chiasma over the tuber cinereum and anterior perforated space to the cerebral peduncle and winds obliquely across its under surface. Its fibers terminate in the lateral geniculate body, the pulvinar and the superior colliculus. It is adherent to the tuber cinereum and the cerebral peduncle as it passes over them. In the region of the lateral geniculate body it splits into two bands. The medial and smaller one is a part of the commissure of Gudden and ends in the medial geniculate body.

From its mode of development, and from its structure, the optic nerve must be regarded as a prolongation of the brain substance, rather than as an ordinary cerebrospinal nerve. As it passes from the brain it receives sheaths from the three cerebral membranes, a perineural sheath from the pia mater, an intermediate sheath from the arachnoid, and an outer sheath from the dura mater, which is also connected with the periosteum as it passes through the optic foramen. These sheaths are separated from each other by cavities which communicate with the subdural and subarachnoid cavities respectively. The innermost or perineural sheath sends a process around the arteria centralis retinae into the interior of the nerve, and enters intimately into its structure.

N. OCULOMOTORIUS; THIRD NERVE

The **oculomotor nerve** supplies somatic motor fibers to all the ocular muscles, except the Obliquus superior and Rectus lateralis; it also supplies through its connections with the ciliary ganglion, sympathetic motor fibers to the Sphincter pupillae and the Ciliaris muscles.

The fibers of the oculomotor nerve arise from a nucleus which lies in the gray substance of the floor of the cerebral aqueduct and extends in front of the aqueduct for a short distance into the floor of the third ventricle. From this nucleus the fibers pass forward through the tegmentum, the red nucleus, and the

medial part of the substantia nigra, forming a series of curves with a lateral convexity, and emerge from the oculomotor sulcus on the medial side of the cerebral peduncle.

The nucleus of the oculomotor nerve does not consist of a continuous column of cells, but is broken up into a number of smaller nuclei, which are arranged in two groups, anterior and posterior. Those of the posterior group are six in number, five of which are symmetrical on the two sides of the middle line, while the sixth is centrally placed and is common to the nerves of both sides. The anterior group consists of two nuclei, an antero-medial and an antero-lateral.

The nucleus of the oculomotor nerve, considered from a physiological standpoint, can be subdivided into several smaller groups of cells, each group controlling a particular muscle.

On emerging from the brain, the nerve is invested with a sheath of pia mater, and enclosed in a prolongation from the arachnoid. It passes between the superior cerebellar and posterior cerebral arteries, and then pierces the dura mater in front of and lateral to the posterior clinoid process, passing between the free and attached borders of the tentorium cerebelli. It runs along the lateral wall of the cavernous sinus, above the other orbital nerves, receiving in its course one or two filaments from the cavernous plexus of the sympathetic, and a communicating branch from the ophthalmic division of the trigeminal. It then divides into two branches, which enter the orbit through the superior orbital fissure, between the two heads of the Rectus lateralis. Here the nerve is placed below the trochlear nerve and the frontal and lacrimal branches of the ophthalmic nerve, while the nasociliary nerve is placed between its two rami.

The **superior ramus**, the smaller, passes medialward over the optic nerve, and supplies the Rectus superior and Levator palpebrae superioris. The **inferior ramus**, the larger, divides into three branches. One passes beneath the optic nerve to the Rectus medialis; another, to the Rectus inferior; the third and longest runs forward between the Recti inferior and lateralis to the Obliquus inferior. From the last a short thick branch is given off to the lower part of the ciliary ganglion, and forms its **short root**. All these branches enter the muscles on their ocular surfaces, with the exception of the nerve to the Obliquus inferior, which enters the muscle at its posterior border.

N. TROCHLEARIS; FOURTH NERVE

The **trochlear nerve**, the smallest of the cranial nerves, supplies the Obliquus superior oculi.

It *arises* from a nucleus situated in the floor of the cerebral aqueduct, opposite the upper part of the inferior colliculus. From its origin it runs downward through the tegmentum, and then turns backward into the upper part of the anterior medullary velum. Here it decussates with its fellow of the opposite side and emerges from the surface of the velum at the side of the frenulum veli, immediately behind the inferior colliculus.

The nerve is directed across the superior cerebellar peduncle, and then winds forward around the cerebral peduncle, immediately above the pons, pierces the dura mater in the free border of the tentorium cerebelli, just behind, and lateral to, the posterior clinoid process, and passes forward in the lateral wall of the cavernous sinus, between the oculomotor nerve and the ophthalmic division of the trigeminal. It crosses the oculomotor nerve, and enters the orbit through the superior orbital fissure. It now becomes the highest of all the nerves, and lies medial to the frontal nerve. In the orbit it passes medialward, above the origin of the Levator palpebrae superioris, and finally enters the orbital surface of the Obliquus superior.

In the lateral wall of the cavernous sinus the trochlear nerve forms communications with the ophthalmic division of the trigeminal and with the cavernous plexus of the sympathetic. In the superior orbital fissure it occasionally gives off a branch to the lacrimal nerve. It gives off a recurrent branch which passes backward between the layers of the tentorium cerebelli and divides into two or three filaments which may be traced as far as the wall of the transverse sinus.

N. TRIGEMINUS; FIFTH OR TRIFACIAL NERVE

The **trigeminal nerve** is the largest cranial nerve and is the great sensory nerve of the head and face, and the motor nerve of the muscles of mastication.

It emerges from the side of the pons, near its upper border, by a small *motor* and a large *sensory root*—the former being situated in front of and medial to the latter.

Motor Root.—The fibers of the motor root *arise* from two nuclei, a superior and an inferior. The **superior nucleus** consists of a strand of cells occupying the whole length of the lateral portion of the gray substance of the cerebral aqueduct. The **inferior** or **chief nucleus** is situated in the upper part of the pons, close to its dorsal surface, and along the line of the lateral margin of the rhomboid fossa. The fibers from

the superior nucleus constitute the **mesencephalic root**: they descend through the mid-brain, and, entering the pons, join with the fibers from the lower nucleus, and the motor root, thus formed, passes forward through the pons to its point of emergence. It is uncertain whether the mesencephalic root is motor or sensory.

Sensory Root.—The fibers of the sensory root *arise* from the cells of the semilunar ganglion which lies in a cavity of the dura mater near the apex of the petrous part of the temporal bone. They pass backward below the superior petrosal sinus and tentorium cerebelli, and, entering the pons, divide into upper and lower roots. The upper root ends partly in a nucleus which is situated in the pons lateral to the lower motor nucleus, and partly in the locus caeruleus; the lower root descends through the pons and medulla oblongata, and ends in the upper part of the substantia gelatinosa of Rolando. This lower root is sometimes named the **spinal root** of the nerve. Medullation of the fibers of the sensory root begins about the fifth month of fetal life, but the whole of its fibers are not medullated until the third month after birth.

The **Semilunar Ganglion** (*ganglion semilunare* [Gasserii]; *Gasserian ganglion*) occupies a cavity (*cavum Meckelii*) in the dura mater covering the trigeminal impression near the apex of the petrous part of the temporal bone. It is somewhat crescentic in shape, with its convexity directed forward: medially, it is in relation with the internal carotid artery and the posterior part of the cavernous sinus. The motor root runs in front of and medial to the sensory root, and passes beneath the ganglion; it leaves the skull through the foramen ovale, and, immediately below this foramen, joins the mandibular nerve. The greater superficial petrosal nerve lies also underneath the ganglion.

The ganglion receives, on its medial side, filaments from the carotid plexus of the sympathetic. It give off minute branches to the tentorium cerebelli, and to the dura mater in the middle fossa of the cranium. From its convex border, which is directed forward and lateralward, three large nerves proceed, viz., the **ophthalmic**, **maxillary**, and **mandibular**. The ophthalmic and maxillary consist exclusively of sensory fibers; the mandibular is joined outside the cranium by the motor root.

Associated with the three divisions of the trigeminal nerve are four small ganglia. The **ciliary ganglion** is connected with the ophthalmic nerve; the **sphenopalatine ganglion** with the maxillary nerve; and the **otic** and **submaxillary ganglia** with the mandibular nerve. All four receive sensory filaments from the trigeminal, and motor and sympathetic filaments from various sources; these filaments are called the **roots of the ganglia**.

First division - The Ophthalmic Nerve

The **Ophthalmic Nerve** (*n. ophthalmicus*), or **first division** of the trigeminal, is a sensory nerve. It supplies branches to the cornea, ciliary body, and iris; to the lacrimal gland and conjunctiva; to the part of the mucous membrane of the nasal cavity; and to the skin of the eyelids, eyebrow, forehead, and nose. It is the smallest of the three divisions of the trigeminal, and *arises* from the upper part of the semilunar ganglion as a short, flattened band, about 2.5 cm. long, which passes forward along the lateral wall of the cavernous sinus, below the oculomotor and trochlear nerves; just before entering the orbit, through the superior orbital fissure, it divides into three branches, **lacrimal**, **frontal**, and **nasociliary**.

The ophthalmic nerve is joined by filaments from the cavernous plexus of the sympathetic, and communicates with the oculomotor, trochlear, and abducent nerves; it gives off a recurrent filament which passes between the layers of the tentorium.

The **Lacrimal Nerve** (*n. lacrimalis*) is the smallest of the three branches of the ophthalmic. It sometimes receives a filament from the trochlear nerve, but this is possibly derived from the branch which goes from the ophthalmic to the trochlear nerve. It passes forward in a separate tube of dura mater, and enters the orbit through the narrowest part of the superior orbital fissure. In the orbit it runs along the upper border of the Rectus lateralis, with the lacrimal artery, and communicates with the zygomatic branch of the maxillary nerve. It enters the lacrimal gland and gives off several filaments, which supply the gland and the conjunctiva. Finally it pierces the orbital septum, and ends in the skin of the upper eyelid, joining with filaments of the facial nerve. The lacrimal nerve is occasionally absent, and its place is then taken by the zygomaticotemporal branch of the maxillary. Sometimes the latter branch is absent, and a continuation of the lacrimal is substituted for it.

The **Frontal Nerve** (*n. frontalis*) is the largest branch of the ophthalmic, and may be regarded, both from its size and direction, as the continuation of the nerve. It enters the orbit through the superior orbital fissure, and runs forward between the Levator palpebrae superioris and the periosteum. Midway between the apex and base of the orbit it divides into two branches, **supratrochlear** and **supraorbital**.

The **supratrochlear nerve** (*n. supratrochlearis*), the smaller of the two, passes above the pulley of the Obliquus superior, and gives off a descending filament, to join the infratrochlear branch of the nasociliary nerve. It then escapes from the orbit between the pulley of the Obliquus superior and the supraorbital foramen, curves up on to the forehead close to the bone, ascends beneath the Corrugator and Frontalis, and dividing into branches which pierce these muscles, it supplies the skin of the lower part of the forehead close to the middle line and sends filaments to the conjunctiva and skin of the upper eyelid.

The **supraorbital nerve** (*n. supraorbitalis*) passes through the supraorbital foramen, and gives off, in this situation, palpebral filaments to the upper eyelid. It then ascends upon the forehead, and ends in two branches, a medial and a lateral, which supply the integument of the scalp, reaching nearly as far back as the lambdoidal suture; they are at first situated beneath the Frontalis, the medial branch perforating the muscle, the lateral branch the galca aponeurotica. Both branches supply small twigs to the pericranium.

The **Nasociliary Nerve** (*n. nasociliaris; nasal nerve*) is intermediate in size between the frontal and lacrimal, and is more deeply placed. It enters the orbit between the two heads of the Rectus lateralis, and between the superior and inferior rami of the oculomotor nerve. It passes across the optic nerve and runs obliquely beneath the Rectus superior and Obliquus superior, to the medial wall of the orbital cavity. Here it passes through the anterior ethmoidal foramen, and, entering the cavity of the cranium, traverses a shallow groove on the lateral margin of the front part of the cribriform plate of the ethmoid bone, and runs down, through a slit at the side of the crista galli, into the nasal cavity. It supplies **internal nasal branches** to the mucous membrane of the front part of the septum and lateral wall of the nasal cavity. Finally, it emerges, as the **external nasal branch**, between the lower border of the nasal bone and the lateral nasal cartilage, and, passing down beneath the Nasalis muscle, supplies the skin of the ala and apex of the nose.

The nasociliary nerve gives off the following branches: the **long root of the ciliary ganglion**, the **long ciliary**, and the **ethmoidal nerves**.

The **long root of the ciliary ganglion** (*radix longa ganglii ciliaris*) usually arises from the nasociliary between the two heads of the Rectus lateralis. It passes forward on the lateral side of the optic nerve, and enters the postero-superior angle of the ciliary ganglion; it is sometimes joined by a filament from the cavernous plexus of the sympathetic, or from the superior ramus of the trochlear nerve.

The **long ciliary nerves** (*nn. ciliares longi*), two or three in number, are given off from the nasociliary, as it crosses the optic nerve. They accompany the short ciliary nerves from the ciliary ganglion, pierce the posterior part of the sclera, and running forward between it and the choroid, are distributed to the iris and cornea. The long ciliary nerves are supposed to contain sympathetic fibers from the superior cervical ganglion to the Dilator pupillae muscle.

The **infratrochlear nerve** (*n. infratrochlearis*) is given off from the nasociliary just before it enters the anterior ethmoidal foramen. It runs forward along the upper border of the Rectus medialis, and is joined, near the pulley of the Obliquus superior, by a filament from the supratrochlear nerve. It then passes to the medial angle of the eye, and supplies the skin of the eyelids and side of the nose, the conjunctiva, lacrimal sac, and caruncula lacrimalis.

The **ethmoidal branches** (*nn. ethmoidales*) supply the ethmoidal cells; the posterior branch leaves the orbital cavity through the posterior ethmoidal foramen and gives some filaments to the sphenoidal sinus.

The Ciliary Ganglion (ophthalmic or lenticular ganglion).—The ciliary ganglion is a small, sympathetic ganglion, of a reddish-gray color, and about the size of a pin's head; it is situated at the back part of the orbit, in some loose fat between the optic nerve and the Rectus lateralis muscle, lying generally on the lateral side of the ophthalmic artery.

Its **roots** are three in number, and enter its posterior border. One, the long or sensory root, is derived from the nasociliary nerve, and joins its postero-superior angle. The second, the short or motor root, is a thick nerve (occasionally divided into two parts) derived from the branch of the oculomotor nerve to the Obliquus inferior, and connected with the postero-inferior angle of the ganglion. The motor root is supposed to contain sympathetic efferent fibers (preganglionic fibers) from the nucleus of the third nerve in the mid-brain to the ciliary ganglion where they form synapses with neurons whose fibers (postganglionic) pass to the Ciliary muscle and to Sphincter muscle of the pupil. The third, the sympathetic root, is a slender filament from the cavernous plexus of the sympathetic; it is frequently blended with the long root.

According to Tiedemann, the ciliary ganglion receives a twig of communication from the sphenopalatine ganglion.

Its **branches** are the **short ciliary nerves**. These are delicate filaments, from six to ten in number, which *arise* from the forepart of the ganglion in two bundles connected with its superior and inferior angles; the lower bundle is the larger. They run forward with the ciliary arteries in a wavy course, one set above and the other below the optic nerve, and are accompanied by the long ciliary nerves from the nasociliary. They pierce the sclera at the back part of the bulb of the eye, pass forward in delicate grooves on the inner surface of the sclera, and are distributed to the Ciliaris muscle, iris, and cornea. Tiedemann has described a small branch as penetrating the optic nerve with the arteria centralis retinae.

Second division - The Maxillary Nerve

The **Maxillary Nerve** (*n. maxillaris; superior maxillary nerve*), or **second division** of the trigeminal, is a sensory nerve. It is intermediate, both in position and size, between the ophthalmic and mandibular. It begins at the middle of the semilunar ganglion as a flattened plexiform band, and, passing horizontally forward, it leaves the skull through the foramen rotundum, where it becomes more cylindrical in form, and firmer in texture. It then crosses the pterygopalatine fossa, inclines lateralward on the back of the maxilla, and enters the orbit through the inferior orbital fissure; it traverses the infraorbital groove and canal in the floor of the orbit, and appears upon the face at the infraorbital foramen. At its termination, the nerve lies beneath the Quadratus labii superioris, and divides into a leash of branches which spread out upon the side of the nose, the lower eyelid, and the upper lip, joining with filaments of the facial nerve.

Branches.—Its branches may be divided into four groups, according as they are given off in the **cranium**, in the **pterygopalatine fossa**, in the **infraorbital canal**, or on the face.

The **Middle Meningeal Nerve** (*n. meningeus medius; meningeal or dural branch*) is given off from the maxillary nerve directly after its origin from the semilunar ganglion; it accompanies the middle meningeal artery and supplies the dura mater.

The **Zygomatic Nerve** (*n. zygomaticus; temporomalar nerve; orbital nerve*) *arises* in the pterygopalatine fossa, enters the orbit by the inferior orbital fissure, and divides at the back of that cavity into two branches, **zygomaticotemporal** and **zygomaticofacial**.

The **zygomaticotemporal branch** (*ramus zygomaticotemporalis; temporal branch*) runs along the lateral wall of the orbit in a groove in the zygomatic bone, receives a branch of communication from the lacrimal, and, passing through a foramen in the zygomatic bone, enters the temporal fossa. It ascends between the bone, and substance of the Temporalis muscle, pierces the temporal fascia about 2.5 cm. above the zygomatic arch, and is distributed to the skin of the side of the forehead, and communicates with the facial nerve and with the auriculotemporal branch of the mandibular nerve. As it pierces the temporal fascia, it gives off a slender twig, which runs between the two layers of the fascia to the lateral angle of the orbit.

The **zygomaticofacial branch** (*ramus zygomaticofacialis; malar branch*) passes along the inferolateral angle of the orbit, emerges upon the face through a foramen in the zygomatic bone, and, perforating the Orbicularis oculi, supplies the skin on the prominence of the cheek. It joins with the facial nerve and with the inferior palpebral branches of the maxillary.

The **Sphenopalatine Branches** (*nn. sphenopalatini*), two in number, descend to the sphenopalatine ganglion.

The **Posterior Superior Alveolar Branches** (*rami alveolares superiores posteriores; posterior superior dental branches*) *arise* from the trunk of the nerve just before it enters the infraorbital groove; they are generally two in number, but sometimes arise by a single trunk. They descend on the tuberosity of the maxilla and give off several twigs to the gums and neighboring parts of the mucous membrane of the cheek. They then enter the posterior alveolar canals on the infratemporal surface of the maxilla, and, passing from behind forward in the substance of the bone, communicate with the middle superior alveolar nerve, and give off branches to the lining membrane of the maxillary sinus and three twigs to each molar tooth; these twigs enter the foramina at the apices of the roots of the teeth.

The **Middle Superior Alveolar Branch** (*ramus alveolaris superior medius; middle superior dental branch*), is given off from the nerve in the posterior part of the infraorbital canal, and runs downward and forward in a canal in the lateral wall of the maxillary sinus to supply the two premolar teeth. It forms a superior dental plexus with the anterior and posterior superior alveolar branches.

The **Anterior Superior Alveolar Branch** (*ramus alveolaris superior anteriores; anterior superior dental branch*), of considerable size, is given off from the nerve just before its exit from the infraorbital

foramen; it descends in a canal in the anterior wall of the maxillary sinus, and divides into branches which supply the incisor and canine teeth. It communicates with the middle superior alveolar branch, and gives off a **nasal branch**, which passes through a minute canal in the lateral wall of the inferior meatus, and supplies the mucous membrane of the anterior part of the inferior meatus and the floor of the nasal cavity, communicating with the nasal branches from the sphenopalatine ganglion.

The **Inferior Palpebral Branches** (*rami palpebrales inferiores; palpebral branches*) ascend behind the Orbicularis oculi. They supply the skin and conjunctiva of the lower eyelid, joining at the lateral angle of the orbit with the facial and zygomaticofacial nerves.

The **External Nasal Branches** (*rami nasales externi*) supply the skin of the side of the nose and of the septum mobile nasi, and join with the terminal twigs of the nasociliary nerve.

The **Superior Labial Branches** (*rami labiales superiores; labial branches*), the largest and most numerous, descend behind the Quadratus labii superioris, and are distributed to the skin of the upper lip, the mucous membrane of the mouth, and labial glands. They are joined, immediately beneath the orbit, by filaments from the facial nerve, forming with them the **infraorbital plexus**.

Sphenopalatine Ganglion (*ganglion of Meckel*).—The sphenopalatine ganglion, the largest of the sympathetic ganglia associated with the branches of the trigeminal nerve, is deeply placed in the pterygopalatine fossa, close to the sphenopalatine foramen. It is triangular or heart-shaped, of a reddish-gray color, and is situated just below the maxillary nerve as it crosses the fossa. It receives a sensory, a motor, and a sympathetic root.

Its **sensory root** is derived from two sphenopalatine branches of the maxillary nerve; their fibers, for the most part, pass directly into the palatine nerves; a few, however, enter the ganglion, constituting its sensory root. Its **motor root** is probably derived from the nervus intermedius through the greater superficial petrosal nerve and is supposed to consist in part of sympathetic efferent (preganglionic) fibers from the medulla. In the sphenopalatine ganglion they form synapses with neurons whose postganglionic axons, vasodilator and secretory fibers, are distributed with the deep branches of the trigeminal to the mucous membrane of the nose, soft palate, tonsils, uvula, roof of the mouth, upper lip and gums, and to the upper part of the pharynx. Its **sympathetic root** is derived from the carotid plexus through the deep petrosal nerve. These two nerves join to form the nerve of the pterygoid canal before their entrance into the ganglion.

The **greater superficial petrosal nerve** (*n. petrosus superficialis major; large superficial petrosal nerve*) is given off from the genicular ganglion of the facial nerve; it passes through the hiatus of the facial canal, enters the cranial cavity, and runs forward beneath the dura mater in a groove on the anterior surface of the petrous portion of the temporal bone. It then enters the cartilaginous substance which fills the foramen lacerum, and joining with the deep petrosal branch forms the nerve of the pterygoid canal.

The **deep petrosal nerve** (*n. petrosus profundus; large deep petrosal nerve*) is given off from the carotid plexus, and runs through the carotid canal lateral to the internal carotid artery. It then enters the cartilaginous substance which fills the foramen lacerum, and joins with the greater superficial petrosal nerve to form the nerve of the pterygoid canal.

The **nerve of the pterygoid canal** (*n. canalis pterygoidei [Vidii]; Vidian nerve*), formed by the junction of the two preceding nerves in the cartilaginous substance which fills the foramen lacerum, passes forward, through the pterygoid canal, with the corresponding artery, and is joined by a small ascending **sphenoidal branch** from the otic ganglion. Finally, it enters the pterygopalatine fossa, and joins the posterior angle of the sphenopalatine ganglion.

Branches of Distribution.—These are divisible into four groups, **orbital, palatine, posterior superior nasal, and pharyngeal**.

The **orbital branches** (*rami orbitales; ascending branches*) are two or three delicate filaments, which enter the orbit by the inferior orbital fissure, and supply the periosteum. According to Luschka, some filaments pass through foramina in the frontoethmoidal suture to supply the mucous membrane of the posterior ethmoidal and sphenoidal sinuses.

The **palatine nerves** (*nn. palatini; descending branches*) are distributed to the roof of the mouth, soft palate, tonsil, and lining membrane of the nasal cavity. Most of their fibers are derived from the sphenopalatine branches of the maxillary nerve. They are three in number: **anterior, middle, and posterior**.

The **anterior palatine nerve** (*n. palatinus anterior*) descends through the pterygopalatine canal, emerges upon the hard palate through the greater palatine foramen, and passes forward in a groove in the hard palate, nearly as far as the incisor teeth. It supplies the gums, the mucous membrane and glands of

the hard palate, and communicates in front with the terminal filaments of the nasopalatine nerve. While in the pterygopalatine canal, it gives off **posterior inferior nasal branches**, which enter the nasal cavity through openings in the palatine bone, and ramify over the inferior nasal concha and middle and inferior meatuses; at its exit from the canal, a palatine branch is distributed to both surfaces of the soft palate.

The **middle palatine nerve** (*n. palatinus medius*) emerges through one of the minor palatine canals and distributes branches to the uvula, tonsil, and soft palate. It is occasionally wanting.

The **posterior palatine nerve** (*n. palatinus posterior*) descends through the pterygopalatine canal, and emerges by a separate opening behind the greater palatine foramen; it supplies the soft palate, tonsil, and uvula. The middle and posterior palatine join with the tonsillar branches of the glossopharyngeal to form a plexus (**circulus tonsillaris**) around the tonsil.

The **posterior superior nasal branches** (*rami nasales posteriores superiores*) are distributed to the septum and lateral wall of the nasal fossa. They enter the posterior part of the nasal cavity by the sphenopalatine foramen and supply the mucous membrane covering the superior and middle nasal conchae, the lining of the posterior ethmoidal cells, and the posterior part of the septum. One branch, longer and larger than the others, is named the **nasopalatine nerve**. It enters the nasal cavity through the sphenopalatine foramen, passes across the roof of the nasal cavity below the orifice of the sphenoidal sinus to reach the septum, and then runs obliquely downward and forward between the periosteum and mucous membrane of the lower part of the septum. It descends to the roof of the mouth through the incisive canal and communicates with the corresponding nerve of the opposite side and with the anterior palatine nerve. It furnishes a few filaments to the mucous membrane of the nasal septum.

The **pharyngeal nerve** (*pterygopalatine nerve*) is a small branch arising from the posterior part of the ganglion. It passes through the pharyngeal canal with the pharyngeal branch of the maxillary artery, and is distributed to the mucous membrane of the nasal part of the pharynx, behind the auditory tube.

Third division - The mandibular nerve

The **mandibular nerve** (*n. mandibularis; inferior maxillary nerve*) supplies the teeth and gums of the mandible, the skin of the temporal region, the auricula, the lower lip, the lower part of the face, and the muscles of mastication; it also supplies the mucous membrane of the anterior two-thirds of the tongue. It is the largest of the three divisions of the fifth, and is made up of two roots: a large, **sensory root** proceeding from the inferior angle of the semilunar ganglion, and a small **motor root** (the motor part of the trigeminal), which passes beneath the ganglion, and unites with the sensory root, just after its exit through the foramen ovale. Immediately beneath the base of the skull, the nerve gives off from its medial side a recurrent branch (*nervus spinosus*) and the nerve to the Pterygoideus medialis, and then divides into two trunks, an anterior and a posterior.

The **Nervus Spinosus** (*recurrent or meningeal branch*) enters the skull through the foramen spinosum with the middle meningeal artery. It divides into two branches, anterior and posterior, which accompany the main divisions of the artery and supply the dura mater; the posterior branch also supplies the mucous lining of the mastoid cells; the anterior communicates with the meningeal branch of the maxillary nerve.

The **Medial Pterygoid Nerve** (*n. Pterygoideus medialis*).—The nerve to the Pterygoideus medialis is a slender branch, which enters the deep surface of the muscle; it gives off one or two filaments to the otic ganglion.

The anterior and smaller division of the mandibular nerve receives nearly the whole of the fibers of the motor root of the nerve, and supplies the muscles of mastication and the skin and mucous membrane of the cheek. Its branches are the **masseteric, deep temporal, buccinator, and lateral pterygoid**.

The **Masseteric Nerve** (*n. massetericus*) passes lateralward, above the Pterygoideus lateralis, in front of the temporomandibular articulation, and behind the tendon of the Temporalis; it crosses the mandibular notch with the masseteric artery, to the deep surface of the Masseter, in which it ramifies nearly as far as its anterior border. It gives a filament to the temporomandibular joint.

The **Deep Temporal Nerves** (*nn. temporales profundi*) are two in number, anterior and posterior. They pass above the upper border of the Pterygoideus lateralis and enter the deep surface of the Temporalis. The **posterior branch**, of small size, is placed at the back of the temporal fossa, and sometimes arises in common with the masseteric nerve. The **anterior branch** is frequently given off from the buccinator nerve, and then turns upward over the upper head of the Pterygoideus lateralis. Frequently a third or intermediate branch is present.

The **Buccinator Nerve** (*n. buccinatorius; long buccal nerve*) passes forward between the two heads of the Pterygoideus lateralis, and downward beneath or through the lower part of the Temporalis; it emerges from under the anterior border of the Masseter, ramifies on the surface of the Buccinator, and unites with the buccal branches of the facial nerve. It supplies a branch to the Pterygoideus lateralis during its passage through that muscle, and may give off the anterior deep temporal nerve. The buccinator nerve supplies the skin over the Buccinator, and the mucous membrane lining its inner surface.

Lateral Pterygoid Nerve (*n. Pterygoideus lateralis*).—The nerve to the Pterygoideus lateralis frequently *arises* in conjunction with the buccinator nerve, but it may be given off separately from the anterior division of the mandibular nerve. It enters the deep surface of the muscle.

The posterior and larger division of the mandibular nerve is for the most part sensory, but receives a few filaments from the motor root. It divides into **auriculotemporal, lingual, and inferior alveolar nerves**.

The **Auriculotemporal Nerve** (*n. auriculotemporalis*) generally *arises* by two roots, between which the middle meningeal artery ascends. It runs backward beneath the Pterygoideus lateralis to the medial side of the neck of the mandible. It then turns upward with the superficial temporal artery, between the auricula and condyle of the mandible, under cover of the parotid gland; escaping from beneath the gland, it ascends over the zygomatic arch, and divides into superficial temporal branches.

The **branches of communication** of the auriculotemporal nerve are with the facial nerve and with the otic ganglion. The branches to the facial, usually two in number, pass forward from behind the neck of the mandible and join the facial nerve at the posterior border of the Masseter. The filaments to the otic ganglion are derived from the roots of the auriculotemporal nerve close to their origin. Its **branches of distribution** are:

- The **anterior auricular branches** (*nn. auriculares anteriores*) are usually two in number; they supply the front of the upper part of the auricula, being distributed principally to the skin covering the front of the helix and tragus.

- The **branches to the external acoustic meatus** (*n. meatus auditorii externi*), two in number, enter the meatus between its bony and cartilaginous portions and supply the skin lining it; the upper one sends a filament to the tympanic membrane.

- The **articular branches** consist of one or two twigs which enter the posterior part of the temporomandibular joint.

- The **parotid branches** (*rami parotidei*) supply the parotid gland.

- The **superficial temporal branches** (*rami temporales superficiales*) accompany the superficial temporal artery to the vertex of the skull; they supply the skin of the temporal region and communicate with the facial and zygomaticotemporal nerves.

The **Lingual Nerve** (*n. lingualis*) supplies the mucous membrane of the anterior two-thirds of the tongue. It lies at first beneath the Pterygoideus lateralis, medial to and in front of the inferior alveolar nerve, and is occasionally joined to this nerve by a branch which may cross the maxillary artery. The chorda tympani also joins it at an acute angle in this situation. The nerve then passes between the Pterygoideus medialis and the ramus of the mandible, and crosses obliquely to the side of the tongue over the Constrictor pharyngis superior and Styloglossus, and then between the Hyoglossus and deep part of the submandibular gland; it finally runs across the duct of the submandibular gland, and along the tongue to its tip, lying immediately beneath the mucous membrane.

Its **branches of communication** are with the facial (through the chorda tympani), the inferior alveolar and hypoglossal nerves, and the submaxillary ganglion. The branches to the submandibular ganglion are two or three in number; those connected with the hypoglossal nerve form a plexus at the anterior margin of the Hyoglossus.

Its **branches of distribution** supply the sublingual gland, the mucous membrane of the mouth, the gums, and the mucous membrane of the anterior two-thirds of the tongue; the terminal filaments communicate, at the tip of the tongue, with the hypoglossal nerve.

The **Inferior Alveolar Nerve** (*n. alveolaris inferior; inferior dental nerve*) is the largest branch of the mandibular nerve. It descends with the inferior alveolar artery, at first beneath the Pterygoideus lateralis, and then between the sphenomandibular ligament and the ramus of the mandible to the mandibular foramen. It then passes forward in the mandibular canal, beneath the teeth, as far as the mental foramen, where it divides into two terminal branches, incisive and mental.

The branches of the inferior alveolar nerve are the **mylohyoid, dental, incisive, and mental.**

The **mylohyoid nerve** (*n. mylohyoideus*) is derived from the inferior alveolar just before it enters the mandibular foramen. It descends in a groove on the deep surface of the ramus of the mandible, and reaching the under surface of the Mylohyoideus supplies this muscle and the anterior belly of the Digastricus.

The **dental branches** supply the molar and premolar teeth. They correspond in number to the roots of those teeth; each nerve entering the orifice at the point of the root, and supplying the pulp of the tooth; above the alveolar nerve they form an **inferior dental plexus.**

The **incisive branch** is continued onward within the bone, and supplies the canine and incisor teeth.

The **mental nerve** (*n. mentalis*) emerges at the mental foramen, and divides beneath the Triangularis muscle into three branches; one descends to the skin of the chin, and two ascend to the skin and mucous membrane of the lower lip; these branches communicate freely with the facial nerve.

Two small ganglia, the **otic** and the **submaxillary**, are connected with the mandibular nerve.

Otic Ganglion (*ganglion oticum*)—The otic ganglion is a small, ovalshaped, flattened ganglion of a reddish-gray color, situated immediately below the foramen ovale; it lies on the medial surface of the mandibular nerve, and surrounds the origin of the nerve to the Pterygoideus medialis. It is in relation, *laterally*, with the trunk of the mandibular nerve at the point where the motor and sensory roots join; *medially*, with the cartilaginous part of the auditory tube, and the origin of the Tensor veli palatini; *posteriorly*, with the middle meningeal artery.

Branches of Communication.—It is connected by two or three short filaments with the nerve to the Pterygoideus medialis, from which it may obtain a motor, and possibly a sensory root. It communicates with the glossopharyngeal and facial nerves, through the lesser superficial petrosal nerve continued from the tympanic plexus, and through this nerve it probably receives a root from the glossopharyngeal and a motor root from the facial; its sympathetic root consists of a filament from the plexus surrounding the middle meningeal artery. The fibers from the glossopharyngeal which pass to the otic ganglion in the small superficial petrosal are supposed to be sympathetic efferent (preganglionic) fibers from the dorsal nucleus or inferior salivatory nucleus of the medulla. Fibers (postganglionic) from the otic ganglion with which these form synapses are supposed to pass with the auriculotemporal nerve to the parotid gland. A slender filament (sphenoidal) ascends from it to the nerve of the Pterygoid canal, and a small branch connects it with the chorda tympani.

Its **branches of distribution** are: a filament to the Tensor tympani, and one to the Tensor veli palatini. The former passes backward, lateral to the auditory tube; the latter arises from the ganglion, near the origin of the nerve to the Pterygoideus medialis, and is directed forward. The fibers of these nerves are, however, mainly derived from the nerve to the Pterygoideus medialis.

Submandibular Ganglion (*ganglion submandibular*) - The submandibular ganglion is of small size and is fusiform in shape. It is situated above the deep portion of the submandibular gland, on the hyoglossus, near the posterior border of the Mylohyoideus, and is connected by filaments with the lower border of the lingual nerve. It is suspended from the lingual nerve by two filaments which join the anterior and posterior parts of the ganglion. Through the posterior of these it receives a branch from the chorda tympani nerve which runs in the sheath of the lingual; these are sympathetic efferent (preganglionic) fibers from the facial nucleus or the superior salivatory nucleus of the medulla oblongata that terminate in the submaxillary ganglion. The postganglionic fibers pass to the submandibular gland, it communicates with the sympathetic by filaments from the sympathetic plexus around the Facial artery.

Its **branches of distribution** are five or six in number; they *arise* from the lower part of the ganglion, and supply the mucous membrane of the mouth and the duct of the submandibular gland, some being lost in the submandibular gland. The branch of communication from the lingual to the forepart of the ganglion is by some regarded as a branch of distribution, through which filaments pass from the ganglion to the lingual nerve, and by it are conveyed to the sublingual gland and the tongue.

Trigeminal Nerve Reflexes.—Pains referred to various branches of the trigeminal nerve are of very frequent occurrence, and should always lead to a careful examination in order to discover a local cause. As a general rule the diffusion of pain over the various branches of the nerve is at first confined to one only of the main divisions, and the search for the causative lesion should always commence with a thorough examination of all those parts which are supplied by that division; although in severe cases pain may radiate over the branches of the other main divisions. The commonest example of this condition is the neuralgia which is so often associated with dental caries - here, although the tooth itself may not ap-

pear to be painful, the most distressing referred pains may be experienced, and these are at once relieved by treatment directed to the affected tooth.

Many other examples of trigeminal reflexes could be quoted, but it will be sufficient to mention the more common ones. Dealing with the ophthalmic nerve, severe supraorbital pain is commonly associated with acute glaucoma or with disease of the frontal or ethmoidal air cells. Malignant growths or empyema of the maxillary antrum, or unhealthy conditions about the inferior conchae or the septum of the nose, are often found giving rise to "second division" neuralgia, and should be always looked for in the absence of dental disease in the maxilla.

It is on the mandibular nerve, however, that some of the most striking reflexes are seen. It is quite common to meet with patients who complain of pain in the ear, in whom there is no sign of aural disease, and the cause is usually to be found in a carious tooth in the mandible. Moreover, with an ulcer or cancer of the tongue, often the first pain to be experienced is one which radiates to the ear and temporal fossa, over the distribution of the auriculotemporal nerve.

N. ABDUCENS; SIXTH NERVE

The **abducent nerve** supplies the Rectus lateralis oculi.

Its fibers arise from a small nucleus situated in the upper part of the rhomboid fossa, close to the middle line and beneath the colliculus facialis. They pass downward and forward through the pons, and emerge in the furrow between the lower border of the pons and the upper end of the pyramid of the medulla oblongata.

From the nucleus of the sixth nerve, fibers are said to pass through the medial longitudinal fasciculus to the oculomotor nerve of the opposite side, along which they are carried to the Rectus medialis. The Rectus lateralis of one eye and the Rectus medialis of the other may therefore be said to receive their nerves from the same nucleus.

The nerve pierces the dura mater on the dorsum sellae of the sphenoid, runs through a notch in the bone below the posterior clinoid process, and passes forward through the cavernous sinus, on the lateral side of the internal carotid artery. It enters the orbit through the superior orbital fissure, above the ophthalmic vein, from which it is separated by a lamina of dura mater. It then passes between the two heads of the Rectus lateralis, and enters the ocular surface of that muscle. The abducent nerve is joined by several filaments from the carotid and cavernous plexuses, and by one from the ophthalmic nerve. The oculomotor, trochlear, ophthalmic, and abducent nerves bear certain relations to each other in the cavernous sinus, at the superior orbital fissure, and in the cavity of the orbit, as follows:

In the **cavernous sinus**, the oculomotor, trochlear, and ophthalmic nerves are placed in the lateral wall of the sinus, in the order given, from above downward. The abducent nerve lies at the lateral side of the internal carotid artery. As these nerves pass forward to the superior orbital fissure, the oculomotor and ophthalmic divide into branches and the abducent nerve approaches the others; so that their relative positions are considerably changed.

In the **superior orbital fissure**, the trochlear nerve and the frontal and lacrimal divisions of the ophthalmic lie in this order from the medial to the lateral side upon the same plane; they enter the cavity of the orbit above the muscles. The remaining nerves enter the orbit between the two heads of the Rectus lateralis. The superior division of the oculomotor is the highest of these; beneath this lies the nasociliary branch of the ophthalmic; then the inferior division of the oculomotor; and the abducent lowest of all.

In the **orbit**, the trochlear, frontal, and lacrimal nerves lie immediately beneath the periosteum, the trochlear nerve resting on the Obliquus superior, the frontal on the Levator palpebrae superioris, and the lacrimal on the Rectus lateralis. The superior division of the oculomotor nerve lies immediately beneath the Rectus superior, while the nasociliary nerve crosses the optic nerve to reach the medial wall of the orbit. Beneath these is the optic nerve, surrounded in front by the ciliary nerves, and having the ciliary ganglion on its lateral side, between it and the Rectus lateralis. Below the optic nerve are the inferior division of the oculomotor, and the abducent, the latter lying on the medial surface of the Rectus lateralis.

N. FACIALIS; SEVENTH NERVE

The **facial nerve** consists of a motor and a sensory part, the latter being frequently described under the name of the **nervus intermedius** (*pars intermedia of Wrisberg*). The two parts emerge at the lower border of the pons in the recess between the olive and the inferior peduncle, the motor part being the more medial, immediately to the lateral side of the sensory part is the acoustic nerve.

The motor part supplies somatic motor fibers to the muscles of the face, scalp, and auricle, the Buccinator and Platysma, the Stapedius, the Stylohyoideus, and posterior belly of the Digastricus; it also contains some sympathetic motor fibers which constitute the vasodilator nerves of the submaxillary and sublingual glands, and are conveyed through the chorda tympani nerve. These are preganglionic fibers of the sympathetic system and terminate in the submandibular ganglion and small ganglia in the hilus of the submandibular gland. From these ganglia postganglionic fibers are conveyed to these glands. The sensory part contains the fibers of taste for the anterior two-thirds of the tongue and a few somatic sensory fibers from the middle ear region. A few splanchnic sensory fibers are also present.

The **motor root** arises from a nucleus which lies deeply in the reticular formation of the lower part of the pons. This nucleus is situated above the nucleus ambiguus, behind the superior olivary nucleus, and medial to the spinal tract of the trigeminal nerve. From this origin the fibers pursue a curved course in the substance of the pons. They first pass backward and medialward toward the rhomboid fossa, and, reaching the posterior end of the nucleus of the abducent nerve, run upward close to the middle line beneath the colliculus fasciculus. At the anterior end of the nucleus of the abducent nerve they make a second bend, and run downward and forward through the pons to their point of emergence between the olive and the inferior peduncle.

The **sensory root** arises from the genicular ganglion, which is situated on the geniculum of the facial nerve in the facial canal, behind the hiatus of the canal. The cells of this ganglion are unipolar, and the single process divides in a T-shaped manner into central and peripheral branches. The central branches leave the trunk of the facial nerve in the internal acoustic meatus, and form the sensory root; the peripheral branches are continued into the chorda tympani and greater superficial petrosal nerves. Entering the brain at the lower border of the pons between the motor root and the acoustic nerve, the fibers of the sensory root pass into the substance of the medulla oblongata and end in the upper part of the terminal nucleus of the glossopharyngeal nerve and in the fasciculus solitarius.

From their superficial attachments to the brain, the two roots of the facial nerve pass lateralward and forward with the acoustic nerve to the internal acoustic meatus. In the meatus the motor root lies in a groove on the upper and anterior surface of the acoustic nerve, the sensory root being placed between them.

At the bottom of the meatus, the facial nerve enters the facial canal, which it traverses to its termination at the stylomastoid foramen. It is at first directed lateralward between the cochlea and vestibule toward the medial wall of the tympanic cavity; it then bends suddenly backward and arches downward behind the tympanic cavity to the stylomastoid foramen. The point where it changes its direction is named the **geniculum**; it presents a reddish gangliform swelling, the **genicular ganglion** (*ganglion geniculi*; *geniculate ganglion*; *nucleus of the sensory root of the nerve*). On emerging from the stylomastoid foramen, the facial nerve runs forward in the substance of the parotid gland, crosses the external carotid artery, and divides behind the ramus of the mandible into branches, from which numerous offsets are distributed over the side of the head, face, and upper part of the neck, supplying the superficial muscles in these regions. The branches and their offsets unite to form the **parotid plexus**.

Branches of Communication.—The branches of communication of the facial nerve may be arranged as follows:

In the internal acoustic meatus	With the acoustic nerve
At the genicular ganglion	With the sphenopalatine ganglion by the greater superficial petrosal nerve. With the otic ganglion by a branch which joins the lesser superficial petrosal nerve. With the sympathetic on the middle meningeal artery.
In the facial canal	With the auricular branch of the vagus.
At its exit from the stylomastoid foramen	With the glossopharyngeal. With the vagus. With the great auricular. With the auriculotemporal.
Behind the ear	With the lesser occipital.
On the face	With the trigeminal.
In the neck	With the cutaneous cervical.

In the internal acoustic meatus some minute filaments pass from the facial to the acoustic nerve.

The **greater superficial petrosal nerve** (*large superficial petrosal nerve*) arises from the genicular ganglion, and consists chiefly of sensory branches which are distributed to the mucous membrane of the soft palate; but it probably contains a few motor fibers which form the motor root of the sphenopalatine ganglion. It passes forward through the hiatus of the facial canal, and runs in a sulcus on the anterior surface of the petrous portion of the temporal bone beneath the semilunar ganglion, to the foramen lacerum. It receives a twig from the tympanic plexus, and in the foramen is joined by the deep petrosal, from the sympathetic plexus on the internal carotid artery, to form the nerve of the pterygoid canal which passes forward through the pterygoid canal and ends in the sphenopalatine ganglion. The genicular ganglion is connected with the otic ganglion by a branch which joins the lesser superficial petrosal nerve, and also with the sympathetic filaments accompanying the middle meningeal artery. According to Arnold, a twig passes back from the ganglion to the acoustic nerve. Just before the facial nerve emerges from the stylomastoid foramen, it generally receives a twig from the auricular branch of the vagus.

After its exit from the stylomastoid foramen, the facial nerve sends a twig to the glossopharyngeal, and communicates with the auricular branch of the vagus, with the great auricular nerve of the cervical plexus, with the auriculotemporal nerve in the parotid gland, and with the lesser occipital behind the ear; on the face with the terminal branches of the trigeminal, and in the neck with the cutaneous cervical nerve.

Branches of Distribution.—The branches of distribution of the facial nerve may be thus arranged:

The **Nerve to the Stapedius** (*n. stapedius; tympanic branch*) arises opposite the pyramidal eminence (page 1042); it passes through a small canal in this eminence to reach the muscle.

The **Chorda Tympani Nerve** is given off from the facial as it passes downward behind the tympanic cavity, about 6 mm. from the stylomastoid foramen. It runs upward and forward in a canal, and enters the tympanic cavity, through an aperture (**iter chordae posterius**) on its posterior wall, close to the medial surface of the posterior border of the tympanic membrane and on a level with the upper end of the manubrium of the malleus. It traverses the tympanic cavity, between the fibrous and mucous layers of the tympanic membrane, crosses the manubrium of the malleus, and emerges from the cavity through a foramen situated at the inner end of the petrotympanic fissure, and named the **iter chordae anterior** (*canal of Huguier*). It then descends between the Pterygoideus lateralis and internus on the medial surface of the spina angularis of the sphenoid, which it sometimes grooves, and joins, at an acute angle, the posterior border of the lingual nerve. It receives a few efferent fibers from the motor root; these enter the submaxillary ganglion, and through it are distributed to the submaxillary and sublingual glands; the majority of its fibers are afferent, and are continued onward through the muscular substance of the tongue to the mucous membrane covering its anterior two-thirds; they constitute the nerve of taste for this portion of the tongue. Before uniting with the lingual nerve, the chorda tympani is joined by a small branch from the otic ganglion.

The **Posterior Auricular Nerve** (*n. auricularis posterior*) arises close to the stylo-mastoid foramen, and runs upward in front of the mastoid process; here it is joined by a filament from the auricular branch of the vagus, and communicates with the posterior branch of the great auricular, and with the lesser occipital. As it ascends between the external acoustic meatus and mastoid process it divides into auricular and occipital branches. The **auricular branch** supplies the Auricularis posterior and the intrinsic muscles on the cranial surface of the auricula. The **occipital branch**, the larger, passes backward along the superior nuchal line of the occipital bone, and supplies the Occipitalis.

The **Digastric Branch** (*ramus digastricus*) arises close to the stylomastoid foramen, and divides into several filaments, which supply the posterior belly of the Digastricus; one of these filaments joins the glossopharyngeal nerve.

The **Stylohyoid Branch** (*ramus stylohyoideus*) frequently arises in conjunction with the digastric branch; it is long and slender, and enters the Stylohyoideus about its middle.

The **Temporal Branches** (*rami temporales*) cross the zygomatic arch to the temporal region, supplying the Auriculares anterior and superior, and joining with the zygomaticotemporal branch of the maxillary, and with the auriculotemporal branch of the mandibular. The more anterior branches supply the Frontalis, the Orbicularis oculi, and the Corrugator, and join the supraorbital and lacrimal branches of the ophthalmic.

The **Zygomatic Branches** (*rami zygomatici; malar branches*) run across the zygomatic bone to the lateral angle of the orbit, where they supply the Orbicularis oculi, and join with filaments from the lacrimal nerve and the zygomaticofacial branch of the maxillary nerve.

The **Buccal Branches** (*rami buccales; infraorbital branches*), of larger size than the rest, pass horizontally forward to be distributed below the orbit and around the mouth. The **superficial branches** run beneath the skin and above the superficial muscles of the face, which they supply: some are distributed to the Procerus, joining at the medial angle of the orbit with the infratrochlear and nasociliary branches of the ophthalmic. The **deep branches** pass beneath the Zygomaticus and the Quadratus labii superioris, supplying them and forming an **infraorbital plexus** with the infraorbital branch of the maxillary nerve. These branches also supply the small muscles of the nose. The lower deep branches supply the Buccinator and Orbicularis oris, and join with filaments of the buccinator branch of the mandibular nerve.

The **Mandibular Branch** (*ramus marginalis mandibulae*) passes forward beneath the Platysma and Triangularis, supplying the muscles of the lower lip and chin, and communicating with the mental branch of the inferior alveolar nerve.

The **Cervical Branch** (*ramus colli*) runs forward beneath the Platysma, and forms a series of arches across the side of the neck over the suprahyoid region. One branch descends to join the cervical cutaneous nerve from the cervical plexus (*superficial cervical plexus*); others supply the Platysma.

N. VESTIBULO-COCHLEARIS, ACOUSTIC NERVE, EIGHTH NERVE

The **acoustic nerve** consists of two distinct sets of fibers which differ in their peripheral endings, central connections, functions, and time of medullation. It is soft in texture and devoid of neurilemma.

Cochlear Nerve.—The cochlear nerve or root, the **nerve of hearing**, arises from bipolar cells in the spiral ganglion of the cochlea, situated near the inner edge of the osseous spiral lamina. The peripheral fibers pass to the organ of Corti. The central ones pass down the modiolus and then through the foramina of the tractus spiralis foraminosus or through the foramen centrale into the lateral or outer end of the internal auditory meatus. The nerve passes along the internal auditory meatus with the vestibular nerve and across the subarachnoid space, just above the flocculus, almost directly medialward toward the inferior peduncle to terminate in the cochlear nucleus.

The cochlear nerve is placed lateral to the vestibular root. Its fibers end in two nuclei: one, the **accessory nucleus**, lies immediately in front of the inferior peduncle; the other, the **tuberculum acusticum**, somewhat lateral to it.

The **striae medullares** (*striae acusticae*) are the axons of the cells of the tuberculum acusticum. They pass over the inferior peduncle, and across the rhomboid fossa to the median sulcus. Here they dip into the substance of the pons, to end around the cells of the superior olivary nuclei of both sides. There are, however, other fibers, and these are both direct and crossed, which pass into the lateral lemniscus. The cells of the accessory nucleus give origin to fibers which run transversely in the pons and constitute the trapezium. Of the trapezoid fibers some end around the cells of the superior olivary nucleus or of the trapezoid nucleus of the same or opposite side, while others, crossed or uncrossed, pass directly into the lateral lemniscus.

If the further connections of the cochlear nerve of one side, say the left, be considered, it is found that they lie lateral to the main sensory tract, the lemniscus, and are therefore termed the **lateral lemniscus**. The fibers comprising the left lateral lemniscus arise in the superior olivary and trapezoid nuclei of the same or opposite side, while others are the uninterrupted fibers already alluded to, and these are either crossed or uncrossed, the former being the axons of the cells of the right accessory nucleus or of the cells of the right tuberculum acusticum, while the latter are derived from the cells of the left nuclei. In the upper part of the lateral lemniscus there is a collection of nerve cells, the **nucleus of the lateral lemniscus**, around the cells of which some of the fibers arborize and from the cells of which axons originate to continue upward the tract of the lateral lemniscus. The ultimate ending of the left lateral lemniscus is partly in the opposite medial geniculate body, and partly in the inferior colliculi. From the cells of these bodies new fibers arise and ascend in the occipital part of the internal capsule to reach the posterior three-fifths of the left superior temporal gyrus and the transverse temporal gyri.

Vestibular Nerve.—The vestibular nerve or root, the **nerve of equilibration**, arises from bipolar cells in the **vestibular ganglion**, *ganglion of Scarpa*, which is situated in the upper part of the outer end of the internal auditory meatus. The peripheral fibers divide into three branches: the superior branch passes through the foramina in the area vestibularis superior and ends in the utricle and in the ampullae of

the superior and lateral semicircular ducts; the fibers of the inferior branch traverse the foramina in the area vestibularis inferior and end in the sacculæ; the posterior branch runs through the foramen singulare and supplies the ampulla of the posterior semicircular duct.

N. GLOSSOPHARYNGEUS; NINTH NERVE

The **glossopharyngeal nerve** contains both motor and sensory fibers, and is distributed, as its name implies, to the tongue and pharynx. It is the nerve of ordinary sensation to the mucous membrane of the pharynx, fauces, and palatine tonsil, and the nerve of taste to the posterior part of the tongue. It is attached by three or four filaments to the upper part of the medulla oblongata, in the groove between the olive and the inferior peduncle.

The **sensory fibers** arise from the cells of the superior and petrous ganglia, which are situated on the trunk of the nerve, and will be presently described. When traced into the medulla, some of the sensory fibers, probably sympathetic afferent, end by arborizing around the cells of the upper part of a nucleus which lies beneath the ala cinerea in the lower part of the rhomboid fossa. Many of the fibers, probably the **taste fibers**, contribute to form a strand, named the **fasciculus solitarius**, which descends in the medulla oblongata. Associated with this strand are numerous nerve cells, and around these the fibers of the fasciculus end. The **somatic sensory fibers**, few in number, are said to join the spinal tract of the trigeminal nerve.

The **somatic motor fibers** spring from the cells of the **nucleus ambiguus**, which lies some distance from the surface of the rhomboid fossa in the lateral part of the medulla and is continuous below with the anterior gray column of the medulla spinalis. From this nucleus the fibers are first directed backward, and then they bend forward and lateralward to join the fibers of the sensory root. The nucleus ambiguus gives origin to the motor branches of the glossopharyngeal and vagus nerves, and to the cranial part of the accessory nerve.

The **sympathetic efferent fibers** from the nucleus beneath the ala cinerea, the dorsal nucleus, are probably both preganglionic motor fibers and preganglionic secretory fibers of the sympathetic system. The secretory fibers pass to the otic ganglion and from it secondary neurons are distributed to the parotid gland. Some authors describe these fibers as arising from a distinct nucleus the inferior salivatory nucleus, which lies near the dorsal nucleus.

From the medulla oblongata, the glossopharyngeal nerve passes lateralward across the flocculus, and leaves the skull through the central part of the jugular foramen, in a separate sheath of the dura mater, lateral to and in front of the vagus and accessory nerves. In its passage through the jugular foramen, it grooves the lower border of the petrous part of the temporal bone; and, at its exit from the skull, passes forward between the internal jugular vein and internal carotid artery; it descends in front of the latter vessel, and beneath the styloid process and the muscles connected with it, to the lower border of the Stylopharyngeus. It then curves forward, forming an arch on the side of the neck and lying upon the Stylopharyngeus and Constrictor pharyngis medius. Thence it passes under cover of the Hyoglossus, and is finally distributed to the palatine tonsil, the mucous membrane of the fauces and base of the tongue, and the mucous glands of the mouth.

In passing through the jugular foramen, the nerve presents two ganglia, the **superior, jugular** and the **inferior, petrous**.

The **Superior Jugular Ganglion** (*ganglion superius; jugular ganglion*) is situated in the upper part of the groove in which the nerve is lodged during its passage through the jugular foramen. It is very small, and is usually regarded as a detached portion of the petrous ganglion.

The **Inferior Petrous Ganglion** (*ganglion inferius; petrosum ganglion*) is larger than the superior and is situated in a depression in the lower border of the petrous portion of the temporal bone.

Branches of Communication.—The glossopharyngeal nerve communicates with the **vagus, sympathetic, and facial**.

The branches to the vagus are two filaments which *arise* from the petrous ganglion, one passing to the auricular branch, and the other to the jugular ganglion, of the vagus. The petrous ganglion is connected by a filament with the superior cervical ganglion of the sympathetic. The branch of communication with the facial perforates the posterior belly of the Digastricus. It *arises* from the trunk of the glossopharyngeal below the petrous ganglion, and joins the facial just after the exit of that nerve from the stylomastoid foramen.

Branches of Distribution.—The branches of distribution of the glossopharyngeal are: the **tympanic, carotid, pharyngeal, muscular, tonsillar, and lingual.**

The **Tympanic Nerve** (*n. tympanicus; nerve of Jacobson*) arises from the inferior, petrous ganglion, and ascends to the tympanic cavity through a small canal on the under surface of the inferior, petrous portion of the temporal bone on the ridge which separates the carotid canal from the jugular fossa. In the tympanic cavity it divides into branches which form the **tympanic plexus** and are contained in grooves upon the surface of the promontory. This plexus gives off: (1) the lesser superficial petrosal nerve; (2) a branch to join the greater superficial petrosal nerve; and (3) branches to the tympanic cavity, all of which will be described in connection with the anatomy of the middle ear.

The **Carotid Branches** (*n. caroticotympanicus superior* and *n. caroticotympanicus inferior*) descend along the trunk of the internal carotid artery as far as its origin, communicating with the pharyngeal branch of the vagus, and with branches of the sympathetic.

The **Pharyngeal Branches** (*rami pharyngei*) are three or four filaments which unite, opposite the Constrictor pharyngis medius, with the pharyngeal branches of the vagus and sympathetic, to form the **pharyngeal plexus**; branches from this plexus perforate the muscular coat of the pharynx and supply its muscles and mucous membrane.

The **Muscular Branch** (*ramus stylopharyngeus*) is distributed to the Stylopharyngeus.

The **Tonsillar Branches** (*rami tonsillares*) supply the palatine tonsil, forming around it a plexus from which filaments are distributed to the soft palate and fauces, where they communicate with the palatine nerves.

The **Lingual Branches** (*rami linguales*) are two in number; one supplies the papillae vallatae and the mucous membrane covering the base of the tongue; the other supplies the mucous membrane and follicular glands of the posterior part of the tongue, and communicates with the lingual nerve.

N. VAGUS; TENTH NERVE

The **vagus nerve** is composed of both motor and sensory fibers, and has a more extensive course and distribution than any of the other cranial nerves, since it passes through the neck and thorax to the abdomen.

The vagus is attached by eight or ten filaments to the medulla oblongata in the groove between the olive and the inferior peduncle, below the glossopharyngeal. The **sensory fibers** arise from the cells of the jugular ganglion and ganglion nodosum of the nerve, and, when traced into the medulla oblongata mostly end by arborizing around the cells of the inferior part of a nucleus which lies beneath the ala cinerea in the lower part of the rhomboid fossa. These are the sympathetic afferent fibers. Some of the sensory fibers of the glossopharyngeal nerve have been seen to end in the upper part of this nucleus. A few of the sensory fibers of the vagus, probably **taste fibers**, descend in the fasciculus solitarius and end around its cells. The **somatic sensory fibers**, few in number, from the posterior part of the external auditory meatus and the back of the ear, probably join the spinal tract of the trigeminal as it descends in the medulla. The **somatic motor fibers** arise from the cells of the nucleus ambiguus, already referred to in connection with the motor root of the glossopharyngeal nerve.

The **sympathetic efferent fibers**, distributed probably as preganglionic fibers to the thoracic and abdominal viscera, *i. e.*, as motor fibers to the bronchial tree, inhibitory fibers to the heart, motor fibers to the esophagus, stomach, small intestine and gall passages, and as secretory fibers to the stomach and pancreas, arise from the dorsal nucleus of the vagus.

The filaments of the nerve unite, and form a flat cord, which passes beneath the flocculus to the jugular foramen, through which it leaves the cranium. In emerging through this opening, the vagus is accompanied by and contained in the same sheath of dura mater with the accessory nerve, a septum separating them from the glossopharyngeal which lies in front. In this situation the vagus presents a well-marked ganglionic enlargement, which is called the **superior, jugular ganglion** (*ganglion of the root*); to it the accessory nerve is connected by one or two filaments. After its exit from the jugular foramen the vagus is joined by the cranial portion of the accessory nerve, and enlarges into a second gangliform swelling, called the **ganglion inferior nodosum** (*ganglion of the trunk*); through this the fibers of the cranial portion of the accessory pass without interruption, being principally distributed to the pharyngeal and superior laryngeal branches of the vagus, but some of its fibers descend in the trunk of the vagus, to be distributed with the recurrent nerve and probably also with the cardiac nerves.

The vagus nerve passes vertically down the neck within the carotid sheath, lying between the internal jugular vein and internal carotid artery as far as the upper border of the thyroid cartilage, and then between the same vein and the common carotid artery to the root of the neck. The further course of the nerve differs on the two sides of the body.

On the *right side*, the nerve passes across the subclavian artery between it and the right innominate vein, and descends by the side of the trachea to the back of the root of the lung, where it spreads out in the **posterior pulmonary plexus**. From the lower part of this plexus two cords descend on the esophagus, and divide to form, with branches from the opposite nerve, the **esophageal plexus**. Below, these branches are collected into a single cord, which runs along the back of the esophagus enters the abdomen, and is distributed to the postero-inferior surface of the stomach, joining the left side of the celiac plexus, and sending filaments to the lienal plexus.

On the *left side*, the vagus enters the thorax between the left carotid and subclavian arteries, behind the left innominate vein. It crosses the left side of the arch of the aorta, and descends behind the root of the left lung, forming there the **posterior pulmonary plexus**. From this it runs along the anterior surface of the esophagus, where it unites with the nerve of the right side in the **esophageal plexus**, and is continued to the stomach, distributing branches over its anterosuperior surface; some of these extend over the fundus, and others along the lesser curvature. Filaments from these branches enter the lesser omentum, and join the hepatic plexus.

The Superior Jugular Ganglion (*ganglion jugulare; ganglion of the root*) is of a grayish color, spherical in form, about 4 mm. in diameter.

Branches of Communication.—This ganglion is connected by several delicate filaments to the cranial portion of the accessory nerve; it also communicates by a twig with the petrous ganglion of the glossopharyngeal, with the facial nerve by means of its auricular branch, and with the sympathetic by means of an ascending filament from the superior cervical ganglion.

The Inferior Ganglion Nodosum (*ganglion of the trunk; inferior ganglion*) is cylindrical in form, of a reddish color, and 2.5 cm. in length. Passing through it is the cranial portion of the accessory nerve, which blends with the vagus below the ganglion.

Branches of Communication.—This ganglion is connected with the hypoglossal, the superior cervical ganglion of the sympathetic, and the loop between the first and second cervical nerves.

Branches of Distribution.—The branches of distribution of the vagus are:

In the Jugular Fossa	In the Neck	In the Thorax	In the Abdomen
Meningeal.	Pharyngeal.	Inferior cardiac.	Gastric.
Auricular.	Superior laryngeal.	Anterior bronchial.	Celiac.
	Recurrent laryngeal.	Posterior bronchial.	Hepatic.
	Superior cardiac.	Esophageal.	

The Meningeal Branch (*ramus meningeus; dural branch*) is a recurrent filament given off from the jugular ganglion; it is distributed to the dura mater in the posterior fossa of the base of the skull.

The Auricular Branch (*ramus auricularis; nerve of Arnold*) arises from the jugular ganglion, and is joined soon after its origin by a filament from the petrous ganglion of the glossopharyngeal; it passes behind the internal jugular vein, and enters the mastoid canaliculus on the lateral wall of the jugular fossa. Traversing the substance of the temporal bone, it crosses the facial canal about 4 mm. above the stylomastoid foramen, and here it gives off an ascending branch which joins the facial nerve. The nerve reaches the surface by passing through the tympanomastoid fissure between the mastoid process and the tympanic part of the temporal bone, and divides into two branches: one joins the posterior auricular nerve, the other is distributed to the skin of the back of the auricula and to the posterior part of the external acoustic meatus.

The Pharyngeal Branch (*ramus pharyngeus*), the principal motor nerve of the pharynx, arises from the upper part of the ganglion nodosum, and consists principally of filaments from the cranial portion of the accessory nerve. It passes across the internal carotid artery to the upper border of the Constrictor pharyngis medius, where it divides into numerous filaments, which join with branches from the glossopharyngeal, sympathetic, and external laryngeal to form the **pharyngeal plexus**. From the plexus, branches are distributed to the muscles and mucous membrane of the pharynx and the muscles of the soft palate,

except the Tensor veli palatini. A minute filament descends and joins the hypoglossal nerve as it winds around the occipital artery.

The **Superior Laryngeal Nerve** (*n. laryngeus superior*) larger than the preceding *arises* from the middle of the ganglion nodosum and in its course receives a branch from the superior cervical ganglion of the sympathetic. It descends, by the side of the pharynx, behind the internal carotid artery, and divides into two branches, **external** and **internal**.

- The **external branch** (*ramus externus*), the smaller, descends on the larynx, beneath the Sternothyreoides, to supply the Cricothyreoides. It gives branches to the pharyngeal plexus and the Constrictor pharyngis inferior, and communicates with the superior cardiac nerve, behind the common carotid artery.

- The **internal branch** (*ramus internus*) descends to the hyothyroid membrane, pierces it in company with the superior laryngeal artery, and is distributed to the mucous membrane of the larynx. Of these branches some are distributed to the epiglottis, the base of the tongue, and the epiglottic glands; others pass backward, in the aryepiglottic fold, to supply the mucous membrane surrounding the entrance of the larynx, and that lining the cavity of the larynx as low down as the vocal folds. A filament descends beneath the mucous membrane on the inner surface of the thyroid cartilage and joins the recurrent nerve.

The **Recurrent Laryngeal Nerve** (*n. recurrens; inferior or recurrent laryngeal nerve*) *arises*, on the *right side*, in front of the subclavian artery; winds from before backward around that vessel, and ascends obliquely to the side of the trachea behind the common carotid artery, and either in front of or behind the inferior thyroid artery. On the *left side*, it *arises* on the left of the arch of the aorta, and winds below the aorta at the point where the ligamentum arteriosum is attached, and then ascends to the side of the trachea. The nerve on either side ascends in the groove between the trachea and esophagus, passes under the lower border of the Constrictor pharyngis inferior, and enters the larynx behind the articulation of the inferior cornu of the thyroid cartilage with the cricoid; it is distributed to all the muscles of the larynx, excepting the Cricothyreoides. It communicates with the internal branch of the superior laryngeal nerve, and gives off a few filaments to the mucous membrane of the lower part of the larynx.

As the recurrent nerve hooks around the subclavian artery or aorta, it gives off several cardiac filaments to the deep part of the cardiac plexus. As it ascends in the neck it gives off branches, more numerous on the left than on the right side, to the mucous membrane and muscular coat of the esophagus; branches to the mucous membrane and muscular fibers of the trachea; and some pharyngeal filaments to the Constrictor pharyngis inferior.

The **Superior Cardiac Branches** (*rami cardiaci superiores; cervical cardiac branches*), two or three in number, *arise* from the vagus, at the upper and lower parts of the neck.

- The **upper branches** are small, and communicate with the cardiac branches of the sympathetic. They can be traced to the deep part of the cardiac plexus.

- The **lower branch** *arises* at the root of the neck, just above the first rib. That from the right vagus passes in front or by the side of the innominate artery, and proceeds to the deep part of the cardiac plexus; that from the left runs down across the left side of the arch of the aorta, and joins the superficial part of the cardiac plexus.

The **Inferior Cardiac Branches** (*rami cardiaci inferiores; thoracic cardiac branches*), on the right side, *arise* from the trunk of the vagus as it lies by the side of the trachea, and from its recurrent nerve; on the left side from the recurrent nerve only; passing inward, they end in the deep part of the cardiac plexus.

The **Anterior Bronchial Branches** (*rami bronchiales anteriores; anterior or ventral pulmonary branches*), two or three in number, and of small size, are distributed on the anterior surface of the root of the lung. They join with filaments from the sympathetic, and form the **anterior pulmonary plexus**.

The **Posterior Bronchial Branches** (*rami bronchiales posteriores; posterior or dorsal pulmonary branches*), more numerous and larger than the anterior, are distributed on the posterior surface of the root of the lung; they are joined by filaments from the third and fourth (sometimes also from the first and second) thoracic ganglia of the sympathetic trunk, and form the **posterior pulmonary plexus**. Branches from this plexus accompany the ramifications of the bronchi through the substance of the lung.

The **Esophageal Branches** (*rami aesophagei*) are given off both above and below the bronchial branches; the lower are numerous and larger than the upper. They form, together with the branches from the opposite nerve, the **esophageal plexus**. From this plexus filaments are distributed to the back of the pericardium.

The **Gastric Branches** (*rami gastrici*) are distributed to the stomach. The right vagus forms the **posterior gastric plexus** on the postero-inferior surface of the stomach and the left the **anterior gastric plexus** on the antero-superior surface.

The **Celiac Branches** (*rami celiaci*) are mainly derived from the right vagus: they join the celiac plexus and through it supply branches to the pancreas, spleen, kidneys, suprarenal bodies, and intestine.

The **Hepatic Branches** (*rami hepatici*) arise from the left vagus: they join the hepatic plexus and through it are conveyed to the liver.

N. ACCESSORIUS; ELEVENTH NERVE; SPINAL ACCESSORY NERVE

The **accessory nerve** consists of two parts: a **cranial** and a **spinal**.

The **Cranial Part** (*ramus internus; accessory portion*) is the smaller of the two. Its fibers arise from the cells of the **nucleus ambiguus** and emerge as four or five delicate rootlets from the side of the medulla oblongata, below the roots of the vagus. It runs lateralward to the jugular foramen, where it interchanges fibers with the spinal portion or becomes united to it for a short distance; here it is also connected by one or two filaments with the jugular ganglion of the vagus. It then passes through the jugular foramen, separates from the spinal portion and is continued over the surface of the ganglion nodosum of the vagus, to the surface of which it is adherent, and is distributed principally to the pharyngeal and superior laryngeal branches of the vagus. Through the pharyngeal branch it probably supplies the *Musculus uvulae* and *Levator veli palatini*. Some few filaments from it are continued into the trunk of the vagus below the ganglion, to be distributed with the recurrent nerve and probably also with the cardiac nerves.

The **Spinal Part** (*ramus externus; spinal portion*) is firm in texture, and its fibers arise from the motor cells in the lateral part of the anterior column of the gray substance of the medulla spinalis as low as the fifth cervical nerve. Passing through the lateral funiculus of the medulla spinalis, they emerge on its surface and unite to form a single trunk, which ascends between the ligamentum denticulatum and the posterior roots of the spinal nerves; enters the skull through the foramen magnum, and is then directed to the jugular foramen, through which it passes, lying in the same sheath of dura mater as the vagus, but separated from it by a fold of the arachnoid. In the jugular foramen, it receives one or two filaments from the cranial part of the nerve, or else joins it for a short distance and then separates from it again. As its exit from the jugular foramen, it runs backward in front of the internal jugular vein in 66.6 % of cases, and behind in it 33.3 %. The nerve then descends obliquely behind the *Digastricus* and *Stylohyoideus* to the upper part of the *Sternocleidomastoideus*; it pierces this muscle, and courses obliquely across the posterior triangle of the neck, to end in the deep surface of the *Trapezius*. As it traverses the *Sternocleidomastoideus* it gives several filaments to the muscle, and joins with branches from the second cervical nerve. In the posterior triangle it unites with the second and third cervical nerves, while beneath the *Trapezius* it forms a plexus with the third and fourth cervical nerves, and from this plexus fibers are distributed to the muscle.

N. HYPOGLOSSUS; TWELFTH NERVE

The **hypoglossal nerve** is the motor nerve of the tongue.

Its fibers arise from the cells of the **hypoglossal nucleus**, which is an upward prolongation of the base of the anterior column of gray substance of the medulla spinalis. This nucleus is about 2 cm. in length, and its upper part corresponds with the **trigonum hypoglossi**, or lower portion of the medial eminence of the rhomboid fossa. The lower part of the nucleus extends downward into the closed part of the medulla oblongata, and there lies in relation to the ventro-lateral aspect of the central canal. The fibers run forward through the medulla oblongata, and emerge in the antero-lateral sulcus between the pyramid and the olive.

The rootlets of this nerve are collected into two bundles, which perforate the dura mater separately, opposite the hypoglossal canal in the occipital bone, and unite together after their passage through it; in some cases the canal is divided into two by a small bony spicule. The nerve descends almost vertically to a point corresponding with the angle of the mandible. It is at first deeply seated beneath the internal carotid artery and internal jugular vein, and intimately connected with the vagus nerve; it then passes forward between the vein and artery, and lower down in the neck becomes superficial below the *Digastricus*. The nerve then loops around the occipital artery, and crosses the external carotid and lingual arteries below the tendon of the *Digastricus*. It passes beneath the tendon of the *Digastricus*, the *Stylohyoideus*, and the *Mylohyoideus*, lying between the last-named muscle and the *Hyoglossus*, and communicates at the anterior

border of the Hyoglossus with the lingual nerve; it is then continued forward in the fibers of the Genioglossus as far as the tip of the tongue, distributing branches to its muscular substance.

Branches of Communication.—Its branches of communication are, with the Vagus, Sympathetic, First and second cervical nerves, Lingual nerves.

The communications with the vagus take place close to the skull, numerous filaments passing between the hypoglossal and the ganglion nodosum of the vagus through the mass of connective tissue which unites the two nerves. As the nerve winds around the occipital artery it gives off a filament to the pharyngeal plexus.

The communication with the sympathetic takes place opposite the atlas by branches derived from the superior cervical ganglion, and in the same situation the nerve is joined by a filament derived from the loop connecting the first and second cervical nerves.

The communications with the lingual take place near the anterior border of the Hyoglossus by numerous filaments which ascend upon the muscle.

Branches of Distribution.—The branches of distribution of the hypoglossal nerve are: Meningeal, Descending, Thyrohyoid, Muscular.

Of these branches, the meningeal, descending, thyrohyoid, and the muscular twig to the Geniohyoideus, are probably derived mainly from the branch which passes from the loop between the first and second cervical to join the hypoglossal.

Meningeal Branches (dural branches).—As the hypoglossal nerve passes through the hypoglossal canal it gives off, according to Luschka, several filaments to the dura mater in the posterior fossa of the skull.

The **Descending Ramus** (*ramus descendens; descendens hypoglossi*), long and slender, quits the hypoglossal where it turns around the occipital artery and descends in front of or in the sheath of the carotid vessels; it gives a branch to the superior belly of the Omohyoideus, and then joins the communicantes cervicales from the second and third cervical nerves; just below the middle of the neck, to form a loop, the **ansa hypoglossi**.

From the convexity of this loop branches pass to supply the Sternohyoideus, the Sternothyreoideus, and the inferior belly of the Omohyoideus. According to Arnold, another filament descends in front of the vessels into the thorax, and joins the cardiac and phrenic nerves.

The **Thyrohyoid Branch** (*ramus thyreochoideus*) arises from the hypoglossal near the posterior border of the hyoglossus; it runs obliquely across the greater cornu of the hyoid bone, and supplies the Thyrohyoideus muscle.

The **Muscular Branches** are distributed to the Styloglossus, Hyoglossus, Geniohyoideus, and Genioglossus. At the under surface of the tongue numerous slender branches pass upward into the substance of the organ to supply its intrinsic muscles.

THE VEGETATIVE (AUTONOMIC) PART OF THE NERVOUS SYSTEM¹

The fundamental qualitative difference in the structure, development and action of the smooth and striated musculature has been pointed out above. The skeletal muscles take part in the organism's reaction to environmental factors and respond by rapid and purposeful movements to changes in the environment. The smooth musculature is located in the viscera and vessels and works slowly but rhythmically, thus ensuring the course of vital processes in the body. These functional differences are linked with the difference in innervation: the skeletal musculature receives motor impulses from the animal or somatic part of the nervous system, whereas the smooth musculature receives them from the vegetative or autonomic part.

The vegetative nervous system controls the activity of all organs concerned with the vegetative functions of the body (nutrition, respiration, excretion, reproduction, and fluid circulation) and accomplishes trophic innervation.

The trophic function of the vegetative nervous system is responsible for the nutrition of the tissues and organs in conformity to their functioning under certain environmental conditions (adaptational-trophic function).

It is general knowledge that changes in the state of the higher nervous activity affect the function of the viscera and vice versa, changes in the organism's internal environment cause an effect on the functional state of the central nervous system. The vegetative nervous system intensifies or weakens the function of the specifically working organs. This regulation is of a tonic character and the vegetative system alters therefore the tonus of the organ. Since one and the same nerve fibre acts only in one direction and is inca-

pable of simultaneously increasing and reducing the tonus, the vegetative nervous system is accordingly separated into two parts, or systems: the sympathetic and parasympathetic systems.

The sympathetic part is mainly concerned with trophic functions. It is responsible for intensification of oxidation processes, nutrient consumption, and respiration and increases the rate of cardiac activity and the supply of oxygen to the muscles.

The parasympathetic system carries a protective role: constriction of the pupil in bright light, inhibition of cardiac activity, evacuation of the cavitory organs.

Comparison of the areas of distribution of the sympathetic and parasympathetic innervation discloses, firstly, the predominant role of one vegetative part over the other. The urinary bladder, for instance, receives mostly parasympathetic innervation, and division of the sympathetic nerves causes no essential changes in its activity; the sweat glands, the pilary muscles of the skin, the spleen, and the suprarenals are supplied only with sympathetic innervation. Secondly, in organs with double vegetative innervation, interaction of the sympathetic and parasympathetic nerves in the form of a definite antagonism is encountered. Stimulation of the sympathetic nerves causes dilatation of the pupil, constriction of the vessels, an increase in the rate of cardiac contractions, and inhibition of intestinal peristalsis; stimulation of the parasympathetic nerves, in contrast, leads to constriction of the pupil, dilatation of the vessels, diminution of the heart beat rate, and intensification of peristalsis.

The "antagonism" of the sympathetic and parasympathetic systems, however, should not be considered static, as an opposition of their functions. There are reciprocally acting systems and the relations between them alter dynamically in the different phases of the functioning of this or that organ; they can act both as antagonists and as synergists.

Antagonism and synergism are two aspects of a single process. The normal functions of our organism are ensured by the coordinated action of these two parts of the vegetative nervous system. This coordination and regulation of functions is brought about by the cerebral cortex. The sympathetic and parasympathetic parts are distinguished in the vegetative system mainly according to the physiological and pharmacological data, but morphological distinctions due to their structure and development also exist.

We shall therefore first characterize the morphological features of the vegetative nervous system as compared to those of the somatic nervous system. We describe firstly the centres of the vegetative nervous system. The somatic nerves emerge from the brain stem and spinal cord segmentally for the whole length of these structures. The segmental character is also maintained partly on the periphery. The vegetative nerves emerge only from some of the parts (foci) of the central nervous system.

Four such foci exist.

1. The mesencephalic part located in the midbrain (the accessory, or Yakubovitch's nucleus, nucleus accessorius, and the unpaired median nucleus of the third pair of cranial nerves).

2. The bulbar part located in the medulla oblongata and pons (the nuclei of the seventh, ninth, and tenth pairs of cranial nerves). Both parts are united under the term cranial part.

3. The thoracolumbar part situated in the lateral horns of the spinal cord for the distance of the C₈, Th₁-L₃ segments.

4. The sacral part located in the lateral horns of the spinal cord for the distance of the S₂-S₄ segments.

The thoracolumbar part belongs to the sympathetic system; the cranial and sacral parts to the parasympathetic system.

Certain authors assume that vegetative centres may also exist in the cervical segment of the spinal cord and relate them to the spinal nucleus of the accessory nerve.

Higher vegetative centres (suprasegmentar centres) dominate over the foci; these centres are not simply sympathetic or parasympathetic but are concerned with the regulation of both parts of the vegetative nervous system. They are supra-segmental and are situated in the brain stem and pallium as follows.

1. In the metencephalon: the vasomotor centre on the floor of the fourth ventricle; the cerebellum to which regulation of some of the vegetative functions (vasomotor reflexes, skin trophics, the rate of wound healing, etc.) is attributed.

2. In the midbrain: the grey matter of the aqueduct of Sylvius.

3. In the diencephalon: the hypothalamus (tuber cinereum).

4. In the endbrain: the striated body.

The hypothalamic region is the most essential in vegetative regulation; it is one of the oldest parts of the brain though older and phylogenetically younger structures are distinguished in it.

The nuclei of the hypothalamic area are connected through the hypothalamo-hypophyseal fasciculus with the hypophysis to form the hypothalamo-hypophyseal system. This system, acting by means of the hypophyseal secretions, is a regulator of all the endocrine glands.

The hypothalamic region regulates the activity of all organs of vegetative life by uniting and coordinating their functions.

The vegetative and somatic functions of the whole body are united in the cerebral cortex in the premotor zone in particular.

According to scientists, the cortex is a complex of the cortical ends of the analysers and it receives stimuli from all organs, the organs of vegetative life among others, producing an effect on them through its efferent systems, those of the vegetative nervous system included. Consequently, a two-way connection exists between the cortex and the viscera, i.e. a cortico-visceral connection. As a result, all vegetative functions are subordinate to the cerebral cortex which directs all body processes.

The vegetative nervous system is thus not an independently functioning autonomic structure, as was contended before Pavlov, it is a special part of the integrate nervous system to whose highest parts, the cerebral cortex among others, it is subordinate. Therefore, like in the somatic part of the nervous system, a central and peripheral part can be distinguished in it. The central part are the above described foci and centres in the spinal cord and brain. The peripheral part is composed of the nerve ganglia, nerves, plexuses, and peripheral nerve endings.

Reports have appeared recently claiming that the vegetative ganglia possess their own afferent innervation through which they are controlled by the central nervous system.

The reflex arc differs markedly.

The cell body of the sensory neuron, both of the somatic and of the vegetative nervous systems, is located in the spinal ganglion (ganglion spinale) in which afferent pathways, both from organs of somatic life and those of vegetative life, gather and which is therefore a mixed somatic vegetative ganglion.

The cell body of the internuncial neuron of the vegetative nervous system, as distinct from that of the somatic system, is located in the lateral horns of the spinal cord. The axon of a somatic internuncial neuron arises from the cells of the posterior horn and terminates within the boundaries of the spinal cord among the cells of its anterior horns. The internuncial neuron of the vegetative system, in contrast, does not terminate in the spinal cord but passes from it to nerve ganglia lying on the periphery. On emerging from the spinal cord the axon of the internuncial neuron runs into the ganglia of the sympathetic trunk (ganglia trunci sympathici) related to the sympathetic part of the vegetative nervous system (these are ganglia of the first order, they form the sympathetic trunk), or the fibres do not terminate in these ganglia but stretch to the intermediate ganglia (ganglia intermedia) lying closer to the periphery between the sympathetic trunk and an organ (e.g. the mesenteric ganglia). These are ganglia of the second order and are also related to the sympathetic nervous system. Finally, the fibres may reach, without interruption, ganglia lying either near to an organ (paraorganic ganglia, e.g. the ciliary, optic ganglia, and others) or within the organ (intraorganic, intramural ganglia); both are ganglia of the third order and are called the terminal ganglia (ganglia terminalia). They are related to the parasympathetic part of the vegetative nervous system. All fibres which stretch to the ganglia

1 Besides the gross defined ganglia, tiny groups of effector neurons, microganglia, are encountered along the distance of the vegetative nerves; these had migrated here during embryonic development of the first, second, or third order and are axons of an internuncial neuron are called preganglionic fibres (rami preganglionares). They are covered with myelin.

The third, effector, neuron of the somatic reflex arc is located in the anterior horns of the spinal cord, whereas the effector neuron of the vegetative reflex arc was brought out of the central into the peripheral nervous system in the process of development, closer to the working organ, and is located in the vegetative nerve ganglia. This positioning of the effector neurons on the periphery is responsible for the main sign of the vegetative nervous system, namely the double-neurone structure of the efferent peripheral pathway: the first is the internuncial neuron whose body lies in the vegetative nuclei of the cranial nerves or in the lateral horns of the spinal cord while its axon runs to a ganglion; the second is the efferent neuron with the body located in the ganglion and the axon reaching the working organ. The effector neurons of the sympathetic nerves arise in the ganglia of the sympathetic trunk (ganglia of the first order) or in the intermediate ganglia (ganglia of the second order); the effector neurons of the parasympathetic nerves originate in the para- or intraorganic ganglia, the terminal ganglia (ganglia of the third order). Since there is synapsis of the internuncial and efferent neurones in these ganglia, the indicated difference between the

sympathetic and parasympathetic parts of the vegetative nervous system is linked exactly with these neurons.

The axons of the efferent vegetative neurons are almost devoid of myelin, they are nonmedullated (grey). They constitute the postganglionic fibres (rami postganglionares). The postganglionic fibres of the sympathetic nervous system which arise from the ganglia of the sympathetic trunk diverge in two directions. Some pass to the viscera and form the visceral part of the sympathetic system. Other fibres form the communicating branches (rami communicantes grisei) connecting the sympathetic trunk with the somatic nerves. As components of these nerves, the fibres reach the somatic organs (the motor apparatus and the skin) in which they innervate the smooth muscles of the vessels and nerves, and the glands.

The sum total of the described efferent vegetative fibres stretching from the ganglia of the sympathetic trunk to the organs of the soma form the somatic part of the sympathetic system. Such structure provides for the functioning of the vegetative nervous system which regulates the metabolism of all parts of the organism in conformity with the continuously changing environmental conditions and with the activity (work) of the organs and tissues.

In accordance with this most universal function associated with all parts, all organs and tissues of the body and not simply with separate organs and tissues, the vegetative nervous system is characterized morphologically also by universal, generalized distribution in the body, and penetrates all organs and tissues.

Therefore, the sympathetic nervous system innervates not only the viscera but also the soma in which it is responsible for the metabolic and trophic processes.

As a result each organ is under a triple nervous control, in view of which he distinguished three types of nerves: (1) functional, concerned with the function of the given organ; (2) vasomotor, responsible for the rough flow of blood to the organ, and (3) trophic, regulating the assimilation of nutrients from the blood brought to the organ.

The visceral part of the sympathetic system contains all these three types of nerves for the viscera, whereas the somatic part of this system contains only vasomotor and trophic nerves. As to the functional nerves for the organs of the soma (the skeletal musculature, etc.) these pass as components of the somatic nervous system.

The main distinction of the efferent part of the vegetative nervous system from the efferent part of the somatic nervous system consists therefore in the fact that the somatic nerve fibres on emerging from the central nervous system, pass to the working organ without interruption, whereas the vegetative fibres are interrupted on their way from the brain to the working organ in one of the ganglia of the first, second or third order. As a consequence, the efferent tract of the vegetative system breaks up into two parts of which it is actually composed: the preganglionic myelinated (medullated) fibres, rami preganglionares, and postganglionic devoid of myelin (nonmedullated) fibres, rami postganglionares.

The presence of ganglia in the efferent part of the reflex arc is a characteristic sign of the vegetative nervous system, distinguishing it from the somatic system.

The nerves also possess certain characteristic features. The afferent pathways of the vegetative nervous system do not possess the character of macroscopically visible nerves and their fibres pass as components of other nerves (the greater and lesser splanchnic nerves, the posterior roots, etc.). The sympathetic system in this case is marked by the fact that the sensory innervation associated with it can spread extensively and, consequently, the sympathetic system can be regarded as a system of collateral innervation.

For instance, the afferent spinal nerve fibres contributing to the formation of the solar plexus that innervates the abdominal organs arise from numerous spinal ganglia (C_5-L_3). This circumstance determines the multiplicity and the multisegmental nature of the pathways and sources of afferent innervation of the abdominal organs. This also explains the conduction of the sense of pain from the viscera both along the vegetative and the somatic nerves.

Moreover, it has recently been established that, in addition to the diffuse distribution of the sensory neurons and the paths of the fibres, there is a predominant participation of certain spinal ganglia in innervation of the viscera. Among the sources and pathways of afferent innervation of the viscera, principal and additional ones can therefore be distinguished. This division is intimately related to the concept of collateral pathways of afferent spinal innervation of the viscera. In morbid conditions (interruption of the spinal cord, etc.), the collateral pathways may act as compensatory pathways substituting for the activity of the impaired main pathways, as compensatory adaptations in the form of an "overlap" in the afferent innervation of the organs.

As to the efferent pathways of the vegetative system, these form clearly defined nerves and ganglia. One can therefore speak about two centrifugal pathways of the integral nervous system: one is the somatic, motor nerves, and the other is the vegetative nerves. The vegetative nerves form plexuses around the blood vessels with which they approach and enter the organs. The presence of plexuses around the vessels is a characteristic sign of the vegetative nervous system distinguishing it from the somatic system.

As it is indicated above, the vegetative nervous system is characterized by universal distribution in the body. It has an extensive area of efferent innervation embracing all the body organs and tissues, including the skeletal musculature (whose tonus it increases). This constitutes the morphological feature of the vegetative nervous system in contrast to the somatic system whose centrifugal fibres innervate only the skeletal muscles, i.e. it has a relatively limited area of efferent innervation.

To understand the structure of the vegetative nervous system **its development** must be taken into account.

The smooth musculature of the invertebrates is regulated by the ganglionic-reticular nervous system which, in addition to this function, is also concerned with metabolism regulation. Since it adapts the level of metabolism to the altering activity of the organs, this function of the nervous system is called adaptive while the corresponding function of the nervous system is called adaptative-trophic. It is the most common and extremely old function of the nervous system, which had existed in the primitive ancestors of the vertebrates. In the later process of evolution, the motor apparatus (the hard skeleton and striated muscles) and the sensory organs, i.e. the organs of animal life, developed most prominently. Consequently, the part of the nervous system concerned with these organs, i.e. the somatic part, underwent the most striking changes and acquired new signs, namely, the fibres were isolated by means of myelin sheaths (medullated fibres) and the rate of stimulation conduction increased (12-100 m/sec). In contrast, the organs of vegetative life went through a slower and less progressive evolution so that the part of the nervous system linked with them reserved for itself the most common function, the adaptation-trophic. This is the vegetative part of the nervous system.

Along with certain specialization, it retained a number of the old primitive features: the absence of myelin sheaths in most nerve fibres (non-medullated fibres), a lower rate of stimulation conduction (0.3-10 m/sec), and a lesser concentration and centralization of the effector neurons remaining scattered on the periphery as components of ganglia, nerves, and plexuses. The effector neuron proved to be located close to or even inside the working organ.

Such peripheral location of the effector neuron on the periphery was responsible for the main morphological feature of the vegetative nervous system, namely, the double-neuron structure of the efferent peripheral pathway consisting of an internuncial and an effector neurons.

With the appearance of the spinal (truncal) medulla (in Acrania vertebrates), the adaptation impulses arising in it pass along the internuncial neurons which are marked by a high rate of stimulation, but adaptation itself is accomplished by the smooth muscles and glands which are reached by effector neurons marked by slow conduction (which is pointed out above). This contradiction has been corrected during evolution by the development of special nerve ganglia in which contact is established between the internuncial and effector neurons; one internuncial neuron communicates with many effector neurons (approximately 1 : 32). As a result the medullated fibres possessing a high rate of stimulation conduction are switched over to the non-medullated fibres of a small conduction rate. The whole efferent peripheral pathway of the vegetative nervous system is thus divided into two parts: preganglionic and postganglionic, while the ganglia themselves become the transformers of rapid to slow stimulation rates.

The brain forming in lower fishes has centres which unite the activity of organs producing the organism's internal environment.

Since the skeletal striated musculature takes part in this activity, in addition to the smooth musculature, the need arises for coordinating their work. For instance, the gill opercles are brought into action by the skeletal muscles; in man likewise both the smooth muscles of the bronchi and the striated muscles of the chest participate in the act of respiration. This coordination is accomplished by a special reflex apparatus developing in the metencephalon as a system of the vagus nerve (the bulbar part of the parasympathetic nervous system).

Other structures also develop in the central nervous system, which, like the vagus nerve, are responsible for the coordinated mutual activity of the skeletal muscles (which possess high rates of stimulation) and the smooth muscles (possessing low stimulation rates). Among such structures is the part of the oculomotor nerve which by means of the smooth and striated muscles of the eye sets the standard width of

the pupil, accommodation, and convergence according to the intensity of the illumination and the distance to the object examined, in the same manner as it is done by a photographer (the mesencephalic part of the parasympathetic nervous system). Another such structure is the part of the sacral nerves (second, third, and fourth) which is responsible for the common function of the pelvic organs (the rectum and bladder), i.e. evacuation, accomplished by the joint action of the smooth muscles of these organs and the striated muscles of the pelvis and the prelum abdominale (the sacral part of the parasympathetic system). A central adaptation apparatus developed in the midbrain and diencephalon in the form of grey substance arranged around the aqueduct and tuber cinereum (the hypothalamus).

Finally, centres uniting the higher somatic and vegetative functions formed in the cerebral cortex.

The development of the vegetative nervous system in ontogenesis (embryogenesis) differs from that in phylogenesis.

The vegetative part of the nervous system arises from a source in common with the somatic part, namely from the neuroectoderm, which proves the unity of the whole nervous system.

Sympathetoblasts evicted from the common germ of the nervous system migrate to the periphery, and accumulate in definite places to form at first the ganglia of the sympathetic trunk and then the intermediate ganglia as well as the nerve plexuses. The processes of the cells of the sympathetic trunk unite into bundles to form the grey communicating branches (*rami communicantes grisei*).

The cephalic part of the vegetative nervous system develops in a like manner. The germs of the parasympathetic ganglia are evicted from the medulla oblongata or the ganglionic lamina, migrate for a far distance along the branches of the trigeminal, vagus, and other nerves and settle on them or form intramural ganglia.

THE SYMPATHETIC NERVOUS SYSTEM

The sympathetic nervous system occurs historically as a segmental part and therefore in man it also has a segmental structure.

THE CENTRAL PART OF THE SYMPATHETIC NERVOUS SYSTEM

The central part of the sympathetic system is located in the lateral horns of the spinal cord between the level of C₈ and Th₁-L₃ in the intermediolateral nucleus (*nucleus intermediolateralis*). It gives rise to fibres innervating the smooth muscles of the viscera and the sensory organs (eyes), and the glands. Vasomotor, pilomotor, and perspiration centres are also located here. It is considered (and has been verified by clinical experience) that different parts of the spinal cord cause a trophic effect and have influence on thermoregulation and metabolism.

THE PERIPHERAL PART OF THE SYMPATHETIC NERVOUS SYSTEM

The peripheral part of the sympathetic system is firstly formed of two symmetrical right and left sympathetic trunks (*truncus sympathicus dexter and sinister*) stretching on either side of the spine from the base of the skull to the coccyx where the caudal ends of both trunks meet to form a single common ganglion. Each sympathetic trunk is composed of a series of nerve ganglia of the first order connected by longitudinal interganglionic branches (*rami interganglionares*) that consist of nerve fibres. In addition to the ganglia of the sympathetic trunk (*ganglia trunci sympathici*), the intermediate ganglia mentioned above are also constituents of the sympathetic system. It has also been found that beginning from the level of the superior cervical ganglion the sympathetic trunk contains elements of the parasympathetic and even those of the somatic nervous system.

The processes of cells located in the lateral horns of the thoracolumbar part of the spinal cord emerge from it through the anterior roots and, on separating from them, pass in the white communicating branches (*rami communicantes albi*) to the sympathetic trunk. Here they join by means of synapsis with the cells of the sympathetic trunk ganglia or pass through the ganglia without interruption and reach one of intermediate ganglia. This is the preganglionic pathway. From the ganglia of the sympathetic trunk or (if there was no interruption) from the intermediate ganglia arise non-medullated fibres of the postganglionic pathways and pass to the blood vessels and viscera.

Since the sympathetic system has a somatic part, it is connected with the spinal nerves providing innervation of the soma. This connection is brought about by the grey communicating branches (*rami communicantes grisei*) which are a segment of postganglionic fibres stretching from the sympathetic trunk ganglia to a spinal nerve. As components of the grey communicating branches and the spinal nerves

the postganglionic fibres spread in the vessels, glands, and smooth muscles of the skin of the trunk and limbs, as well as in the striated muscles for whose nutrition and tonus they are responsible.

Thus, the sympathetic nervous system is connected with the somatic system by two types of communicating branches, grey and white. The white communicating branches (medullated) are the preganglionic fibres. They stretch from the centres of the sympathetic nervous system through the anterior roots to the ganglia of the sympathetic trunk. Since the centres are situated at the level of the thoracic and upper lumbar segments, the white communicating branches are also present only in the area between the level of the first thoracic and that of the third lumbar spinal nerves. The grey communicating branches, the postganglionic fibres, provide for the vasomotor and trophic processes in the soma; they connect the sympathetic trunk with the spinal nerves for its entire length. The cervical part of the sympathetic trunk is also connected with the cranial nerves. All the plexuses of the somatic nervous system contain therefore fibres of the sympathetic system in their bundles and nerve trunks, which emphasizes the unity of these systems.

THE SYMPATHETIC TRUNK

Each of the two sympathetic trunks is subdivided into four parts: cervical, thoracic, lumbar (or abdominal), and sacral (or pelvic).

The cervical part stretches from the base of the skull to the neck of the first rib; the sympathetic trunk lies behind the carotid arteries on the deep muscles of the neck. It has three cervical sympathetic ganglia: superior, middle, and inferior.

The superior cervical ganglion (*ganglion cervicale superius*) is the largest ganglion of the sympathetic trunk and is about 20 mm in length and 4-6 mm in breadth. It lies on the level of the second and partly the third cervical vertebrae behind the internal carotid artery and medial to the vagus nerve.

The middle cervical ganglion (*ganglion cervicale medium*) is small and is usually located at the intersection of the inferior thyroid artery with the carotid artery. Often it is absent or separated into two small ganglia.

The inferior cervical ganglion (*ganglion cervicale inferius*) is quite large and is situated behind the initial part of the vertebral artery; it is often fused with the first and sometimes also with the second thoracic ganglion to form a common inferior cervical ganglion (*ganglion cervicothoracicum* s. *ganglion stellatum*). Certain authors describe four cervical ganglia of the sympathetic trunk which are linked with the development of the segmental arteries, namely, superior, middle, inferior, and stellate ganglia.

The cervical ganglia send nerves to the head, neck, and chest. These can be divided into an ascending group passing to the head, a descending group stretching to the heart, and a group running to the organs of the neck almost immediately from the site of origin.

The nerves for the head arise from the superior and inferior cervical ganglia and separate into a group of nerves that penetrate the cranial cavity and another group of nerves that reach the head from outer surface.

The first group is represented by **the internal carotid nerve** (*n. caroticus internus*) arising from the superior cervical ganglion, and the vertebral branch of the inferior cervical ganglion (*n. vertebralis*) branching off from the inferior cervical ganglion. Both nerves pass in attendance to arteries of the same names and form plexuses around them, namely the internal carotid plexus (*plexus caroticus internus*) and the **vertebral plexus** (*plexus vertebralis*). Together with the arteries the nerves enter the cranial cavity where they anastomose with one another and send branches to the cerebral vessels, the meninges, the hypophysis, the trunks of the third, fourth, fifth, and sixth pairs of cranial nerves and to the tympanic nerve.

The **internal carotid plexus** (*plexus caroticus internus*) is continuous with the **cavernous plexus** (*plexus cavernosus*) which surrounds the internal carotid artery in the part passing through the cavernous sinus.

The branches of the plexus extend on the internal carotid artery itself and on its ramifications. Among the branches of the artery is the deep **petrosal nerve** (*nervus petrosus profundus*), which joins the greater superficial petrosal nerve (*n. petrosus major*) to form the **nerve of the pterygoid canal** (*n. canalis pterygoidei*) stretching through the pterygoid canal to the **sphenopalatine ganglion** (*ganglion pterygopalatinum*).

The second, external, group of the sympathetic nerves of the head consists of two branches of the superior cervical ganglion, the **external carotid nerves** (*nervi carotici externi*), which form plexuses around the external carotid artery and then pass in attendance to its ramifications on the head. The plexus

sends a small ramus to the **otic ganglion** (*ganglion oticum*); the **facial plexus** (*plexus facialis*) gives off a branch accompanying the facial artery and passing to the submandibular ganglion.

Through rami included in the plexuses around the carotid artery and its branches, the superior cervical plexus sends fibres to the vessels (vasoconstrictors) and the glands of the head (sweat, lacrimal, mucous, and salivary), as well as to the smooth muscles of the hair and to the muscle which dilates the pupil **m. dilatator pupillae**. The pupilodilator centre, called the ciliospinal centre (*centrum ciliospinale*), is in the spinal cord at the level between the seventh cervical and second thoracic segments.

The organs of the neck receive nerves from all three cervical ganglia; besides, some nerves arise from the interganglionic areas of the cervical part of the sympathetic trunk and still others from the plexuses of the carotid arteries.

The rami of the plexuses follow the course of the branches of the external carotid artery and are known by the same name; they approach the organs together with the arterial branches as a consequence of which the number of sympathetic plexuses is equal to the number of the arterial branches. Among the nerves arising from the cervical part of the sympathetic trunk mention should be made of the **pharyngeal branches** (*rami laryngopharyngei*) of the superior cervical ganglion, part of which pass with the **superior laryngeal nerve** (a branch of the vagus nerve) to the larynx and part descend to the lateral pharyngeal wall where together with the branches of the glossopharyngeal, vagus, and superior laryngeal nerves form the **pharyngeal plexus** (*plexus pharyngeus*).

The descending group of branches of the cervical sympathetic trunk segment is formed by the cardiac branches of the superior, middle, and inferior cervical ganglia (*nervi cardiaci cervicales superior, medius and inferior*). They descend into the thoracic cavity and together with the cardiac branches of the sympathetic thoracic ganglia and branches of the vagus nerve contribute to the formation of the cardiac plexuses.

THE PARASYMPATHETIC SYSTEM

The peripheral part of the cranial parasympathetic system consists of the following structures: (1) preganglionic fibres passing in the third, seventh, ninth, and tenth pairs of cranial nerves (according to Mitchell, also in the first and eleventh pairs); (2) terminal ganglia lying close to the organs, namely, the ciliary, sphenopalatine, submandibular, and optic ganglia, and (3) postganglionic fibres which either stretch independently, e.g. the short ciliary nerves arising from the ciliary ganglion, or pass in some other nerves, e.g. postganglionic fibres originating from the otic ganglion and running in the auriculotemporal nerve. Certain authors claim that the parasympathetic fibres also emerge from different segments of the spinal cord through the dorsal roots and pass to the walls of the trunk and the limbs.

The intramural nervous system also belongs to the parasympathetic nervous system.

The walls of some hollow organs contain nerve plexuses of small ganglia (terminal) with ganglionic cells and non-medulated fibres; this is the ganglionic-reticular, or intramural system.

The intramural system is particularly developed in the digestive tract where it is represented by several plexuses.

1. The myenteric (Auerbach's) plexus (*plexus myentericus Auerbachii*) lies between the longitudinal and circular muscles of the digestive tube.

2. The submucous (Meissner's) plexus (*plexus submucosus Meissneri*) is located in the submucous tissue. It is continuous with the plexus of the glands and villi.

The plexuses receive nerve fibres from the sympathetic and parasympathetic systems. In the intramural plexuses the preganglionic fibres of the parasympathetic systems are switched over to the postganglionic fibres.

INNERVATION OF ORGANS

INNERVATION OF THE EYE

Convergence and accommodation of the visual apparatus occur in response to definite visual stimuli arriving from the retina.

Convergence of the eyes, the bringing of their visual axes together to be fixed on the object examined, occurs by reflex due to associated contraction of the eyeball muscles. This reflex, necessary for binocular vision, is linked with accommodation of the eye. Accommodation, the property of the eye to see objects clearly at different distances from it, depends on contraction of the smooth muscles (the ciliary muscle and the sphincter of the pupil). In view of the fact that the activity of the smooth muscles of the eye

occurs simultaneously with the contraction of its striated muscles, we shall discuss the vegetative innervation of the eye together with the somatic innervation of its motor apparatus.

The afferent pathway from the eyeball muscles (proprioceptive sensitivity) are, according to some authors, the somatic nerves innervating these muscles (the third, fourth, and sixth cranial nerves) and according to others, the ophthalmic nerve (the first division of the trigeminal nerve).

The centres of innervation of the eyeball muscles are the nuclei of the third, fourth, and sixth pairs. The efferent pathway are the third, fourth, and sixth cranial nerves. Convergence of the eye, as it is pointed out above, is accomplished by simultaneous contraction of the muscles of both eyes.

It should be borne in mind that isolated movement of one eyeball does not occur altogether. Both eyes always take part in any voluntary and reflex movements. Associated movement of the eyeballs (the gaze) is produced by a special system of fibres connecting the nuclei of the third, fourth, and sixth nerves to one another; it is called the medial longitudinal bundle.

The medial longitudinal bundle arises in the cerebral peduncle from Darkshevich's nucleus. It is connected to the nuclei of the third, fourth, and sixth nerves by means of collaterals and descends on the brain stem into the spinal cord where it evidently terminates in the cells of the anterior horns of the superior cervical segments. Due to this, the movements of the eyes are combined with movements of the head and neck.

The smooth muscles of the eyes, i.e. the ciliary muscle and the sphincter of the pupil, responsible for accommodation, are supplied with parasympathetic innervation; the dilator of the pupil receives nerves from the sympathetic system. The oculomotor and ophthalmic nerves are the afferent pathways of the vegetative system.

Efferent parasympathetic innervation. The preganglionic fibres pass from Yakubovich's nucleus (mesencephalic part of the parasympathetic nervous system) in the oculomotor nerve and in the root of this nerve reach the ciliary ganglion in which they terminate. The ciliary ganglion gives rise to the postganglionic fibres which through the short ciliary nerves (*nn. ciliares breves*) reach the ciliary muscle and the circular muscle of the iris (sphincter of the pupil). Function: contraction of the pupil and accommodation of the eye to vision at a long and short distance.

Efferent sympathetic innervation. The preganglionic fibres arise from the cells of the intermediolateral nucleus, the lateral horns of the last cervical and two upper thoracic segments (C8—Th2, centrum ciliospinale), emerge through two superior thoracic white communicating branches, pass in the cervical segment of the sympathetic trunk, and terminate in the superior cervical ganglion. The postganglionic fibres pass in the internal carotid nerve into the cranial cavity and enter the internal carotid and ophthalmic plexuses; after that some of the fibres penetrate into the communicating branch which is connected with the nasociliary and the long ciliary nerves, while others pass to the ciliary ganglion through which they extend without interruption into the short ciliary nerves. The sympathetic fibres passing in the long ciliary nerves, as well as those passing in the short ciliary nerves, reach the radial muscle of the iris (the dilator of the pupil). Function: dilation of the pupil and constriction of the eye vessels.

INNERVATION OF THE LACRIMAL AND SALIVARY GLANDS

The afferent pathway for the lacrimal gland are the lacrimal nerve (a branch of the ophthalmic nerve which is the first division of the trigeminal nerve), for the submandibular and sublingual glands the lingual nerve (a branch of the mandibular nerve which is the third division of the trigeminal nerve), and the chorda tympani (a branch of nervus intermedius, formerly called the sensory root of the facial nerve). The auriculotemporal and glossopharyngeal nerves are the afferent pathways for the parotid gland.

Efferent parasympathetic innervation of the lacrimal gland. The centre is in the upper part of the medulla oblongata and is connected with the nucleus of the nervus intermedius (the superior Salivary nucleus). The preganglionic fibres extend as components of nervus intermedius and then of greater superficial petrosal nerve to the sphenopalatine ganglion. This ganglion gives rise to the postganglionic fibres which as components of the maxillary nerve and then of its branch, the zygomatic nerve, reach the lacrimal gland through connections with the lacrimal nerve.

Efferent parasympathetic innervation of the submandibular and sublingual glands. The preganglionic fibres extend from the superior salivary nucleus as components of nervus intermedius, then of the chorda tympani and the lingual nerve to the submandibular ganglion from which the postganglionic fibres arise and reach the glands in the lingual nerve.

Efferent parasympathetic innervation of the parotid gland. The preganglionic fibres pass from the inferior salivary nucleus as components of the glossopharyngeal nerve, then of the tympanic and the lesser superficial petrosal nerve to the otic ganglion.

Here arise the postganglionic fibres and extend in the auriculotemporal nerve to reach the gland. **Function:** stimulation of the secretion of the lacrimal and the salivary glands mentioned above; dilation of the vessels of the glands.

Efferent sympathetic innervation of all the glands named above. The preganglionic fibres originate in the lateral horns of the superior thoracic segments of the spinal cord and terminate in the superior cervical ganglion. The postganglionic fibres arise in this ganglion and reach the lacrimal glands as components of the internal carotid plexus, the parotid gland in the external carotid plexus, and the submandibular and sublingual glands through the external carotid plexus and then through the facial plexus. **Function:** inhibition of saliva secretion (dryness in the mouth); mild stimulation of lacrimation.

Capitolul VI. AESTHESIOLOGY (SENSRY ORGANS)

GENERAL DATA

The sensory organs (*organs sensuum*) or analysers, are instruments by means of which the nervous system receives stimuli from the environment as well as from the organs of the body itself and perceives these stimuli in the form of sensations. The indication of our sensory organs serve as the source of our realization of the world surrounding us. If it were not for our sensation we would be incapable of learning about any forms of matter or any forms of movement. This is why V. I. Lenin regarded the physiology of the sensory organs as one of the sciences forming the basis for building the dialectical materialistic theory of knowledge.

The process of sensory cognition in man is accomplished by five senses, namely by touching, hearing, seeing, tasting and smelling. The five senses provide man with a wide variety of information about the objective world surrounding us, which is reflected in our consciousness in the form of subjective images by feeling, perceiving and remembering.

Live protoplasm can be stimulated and is capable of responding to stimulation. In the process of phylogenesis this ability is particularly developed in specialized cells of the skin epithelium under the effect of external stimuli and in cells of intestinal epithelium under the effect of stimulation by food. The specialized cells of the epithelium have been associated with the nervous system as early as the coelenteratae stage. In some parts of the body, in the feelers, for instance, in the region of the mouth the specialized cells possessing heightened excitability form accumulations from which the simplest sensory organs originate. Later, depending on the position of these cells, their specialization is accomplished in relation to stimuli. Thus, the cells in the region of the mouth become specialized in the appreciation of chemical stimuli (smell, taste) and the cells in the protruding parts of the body specializes in the appreciation of mechanical stimuli (perceptible by touch), and so on.

The development of the sensory organs depends on the importance of their adaptation to conditions of existence. For example, the dog has a fine sense of smell and can distinguish negligible concentrations of organic acids secreted by the body of animals (hence the ability to trace footsteps) but cannot make out the odours of plants which are of no biological significance for the dog.

The increased fineness achieved in the analysis of the outer world is the result not only of more complicated structure and function of the sensory organs, but mainly of a more complex nervous system. The development of the brain (particularly of its cortex) acquires a very special significance for analysing the environment; because of this Engels called the sensory organs "tools of the brain". We perceive the nerve excitation arising from this or that stimulus in the form of different sensations. Lenin's theory of reflection maintains that sensation is the reflection in our consciousness of objects and phenomena of the environment as a result of their effect on our sensory organs. When light affects the retina of the eye, for example, it arouses nerve impulses which produce visual sensations in our consciousness as they are conveyed along the nervous system.

Sensations will arise if there are devices appreciating the stimuli, nerves along which the stimulus is conveyed, and the brain where it is transformed into a factor of consciousness. All this apparatus necessary for the sensation to occur was called the "analyser". The analyser is an instrument which decomposes the complexity of the environment into its separate elements.

Every analyser consists of three parts: (1) the receptor which transforms the energy of the stimulus into a nerve process; **(2) the conductor** which conveys the nerve excitation; **(3) the cortical end** of the analyser where the excitation is perceived as a sensation.

There are two groups of sensations.

1. Sensations reflecting the properties of objects and phenomena of the material, world around us: the sensation of touch and pressure, the sensation of temperature (heat and cold), the sensation of pain; and also the sensations of hearing, sight, taste and smell.

2. Sensations reflecting the movement of different parts of the body and the condition of the internal organs (motor sensations, the sense of body balance, the sensations of organs and tissues).

In accordance, all organs are divided into two groups.

1. Organs of external sensibility which receive nerve impulses from the exteroceptive field, the exteroceptors. There are five such sensory organs: those of cutaneous sense, hearing, sight, taste and smell.

2. Organs of inner sensibility: (a) those which receive impulses from the proprioceptive field (the muscle-joint sensation), as well as from the organ of balance (the internal ear); they are termed the proprioceptors: (b) organs receiving nerve impulses from the interoceptive field (internal organs and vessels), these are the interoceptors.

The sensations coming from the internal organs are usually indefinite in the normal state of these organs, do not reach the consciousness, and are only reflected in a person's impression of his "general condition". Actually all the internal processes regulated by the vegetative nervous system take place irrespective of our will and become manifested only during morbid disorders by more or less severe pain. As to excitations coming from the proprioceptive field, mention must be made only of the muscle-joint sensation, which makes a person aware of the position of the parts of his body and which is important for the coordination of movements. On the one hand, this sensation is combined with cutaneous sensitivity (the property of stereognosis), and on the other, it is connected with the statokinetic apparatus, which is responsible for the equilibrium of the body. The nerve endings (in the muscles, bones, tendons and joints) and the conductors of the muscle-joint sensation were described when we discussed the motor analyser. This is why the organ of equilibrium is the only proprioceptor described here. In this section we shall therefore describe only organs appreciating sensations from the environment, i.e. the exteroceptors.

The general plan of receptive devices in all classes of animals is more or less the same despite subsequent considerable complication of details. The basic element, with the exception of the organs of cutaneous sense, in terrestrial animals are special sensory cells. These cells in the process of development always originate from the epithelium of the external layer (ectoderm), which due to its position is always in contact with the environment. Every one of these cells has a small projection or receptive pili at the end facing the external surface, while at the other end in some sensory organs (organs of smell and sight) the cell gives off a process which reaches out to join processes of the nerve cells of conducting neurons.

In other organs (organs of taste and hearing) the sensory cell does not give off a central process, but is entwined by the end branches of the afferent nerve approaching it. The first type of sensory cells should be considered primary in relation to the second type. In aquatic animals this form of receptive elements is found in their skin where these elements are moistened by the surrounding fluid. There are no sensory cells in the skin of terrestrial animals and the receptive nerve fibres either terminate freely between the cells of the epithelium or have a particular kind of corpuscles at their ends. The mesoderm also participates in the formation of sensory organs but in a secondary way, it forms protective, supporting and auxiliary adaptations. These adaptations covering and supplementing the sensory cells, i.e. the receptors, form together with them the peripheral parts of the sensory organs: the skin, ear, eye, tongue, and nose. The visual receptor, for instance, consists of the sensory cells of the retina (cones and rods) while the peripheral part is the whole eye.

THE ORGAN OF GRAVITATION AND BALANCE AND THE ORGAN OF HEARING

The organ consists of two analysers: **the analyser of gravitation** (i.e. the sense of gravitational attraction) and balance, and the **analyser of hearing** (*auditory analyser*). Until recently both analysers were regarded as one organ of hearing and balance (**organum vestibulocochleare**). This is how it is still described in all textbooks of anatomy, but with the appearance of space medicine and, particularly, space anatomy, which studies the influences of gravitational overloads on the structure of the organism, certain patterns were revealed in the adaptation of the body to the effect of gravitational overloads occurring in high-altitude and spaceflights, when the pilot or fliers takes off from the ground and overcomes the gravitational attraction. This is why in our textbook both these analysers are studied independently, because each of them has its own receptor, conductor and cortical end.

The joint description of them as of a single organ, however, has its justification, because of the character of their development. At first both analysers formed as a single organ in one bone, the temporal bone, where they are located in man to this day. Eventually they differentiated into two different analysers both of which are closely interconnected as though they form a single organ. In man and vertebrate animals a substantial part of this organ is the labyrinth which contains dual-type receptors: one of them (the organ of Corti) is a delicate arrangement serving for the appreciation of sound stimuli; the others (maculae and cristae ampullares) are the receptor devices of the stato-kinetic apparatus necessary for the

appreciation of the forces of gravitational attraction, and for maintaining the balance and orientation of the body in space. At the lower stages of development these two functions had not been differentiated from each other yet, but the static function is primary. The prototype of the labyrinth in this sense is the static vesicle (the oto- or statocyst) which is commonly found in invertebrate aquatic animals, e.g. mollusks.

In vertebrates this originally simple form of the vesicle becomes much more complicated in accord with the complication of the functions of the labyrinth. Genetically the vesicle arises from the ectoderm first by protruding and then breaking off. This is followed by the separation of the semicircular canals which are special tube-like appendages of the static apparatus. Hagfishes have just one semicircular canal connected with a single vesicle and that is why they can move only in one direction. Two semicircular canals appear in cyclostomata, so they can easily move their body in two directions. Finally, beginning with fish, all the rest of the vertebrates have three semicircular canals developing corresponding to the three dimensions existing in nature, which permit them to move in any direction. As a result, a vestibule is thus formed for the labyrinth and the semicircular canals which have their own special nerve, the vestibular nerve (n. vestibularis) which is the vestibular part of the auditory nerve. With the emergence onto land, when terrestrial animals began moving by means of limbs and man acquired an upright posture the importance of balance increased. The static receptor does not change in structure in the terrestrial vertebrates because it is already fully formed in fish. This, however, made the structure of the brain centres that automatically regulate the posture of the body even more complicated.

In man the centres controlling the body posture reach the highest development. The organ of balance in aquatic animals, forms in connection with their free movement in space, but the auditory apparatus, which is at an embryonic stage in fish, develops only with the emergence of animals onto land when the direct appreciation of air vibrations becomes possible. The auditory apparatus gradually separates from the remainder of the labyrinth, twisting spirally into a coil like a snail shell. With the change from water to an air medium, the internal ear is joined by a sound-conducting apparatus. Thus, the middle ear appears beginning with amphibians; this is the tympanic cavity with the tympanic membrane and the auditory ossicles. The auditory apparatus reaches the highest development in mammals with a spiral cochlea coupled with a complex sound-sensory device. They possess a separate nerve, the cochlear nerve (n. cochlearis), and several auditory centres in the brain, subcortical (in the mesencephalon and metencephalon) and cortical. Mammals also develop the external ear with a deep auditory meatus and concha of the auricle. The auricle is the latest acquisition in time which plays the part of a megaphone to amplify sound and also to protect the external auditory meatus. In terrestrial mammals the auricle is supplied with special muscles and moves easily in the direction of the sound (to prick up one's ears). Mammals living in water or underground have no auricle. In man and higher primates it is reduced in size and is immobile. The origin of oral speech among human beings was paralleled by the maximum development of auditory centres, particularly in the cerebral cortex; they constitute part of the second signalling system, the superior supplement to the thinking of animals. Thus, despite the reduction of certain parts of the ear, the auditory analyzer proves to be most developed in man.

The embryogenesis of the organ of hearing and balance in man is generally similar to phylogenesis. In about the third week of embryonic life an auditory vesicle, the germ of the labyrinth, appears from the ectoderm on both sides of the posterior cerebral vesicle. By the end of the fourth week the endolymphatic duct (ductus endolymphaticus) and three semicircular canals grow out of it.

The upper part of the auditory vesicle into which the semicircular canals drain is the germ of the utricle; it separates at the place where the endolymphatic duct departs from the lower part of the vesicle, the rudiment of the future sacculus. The narrowed place between these two parts transforms into the utriculosaccular duct (ductus utriculosaccularis). In the fifth week of embryonic life at first a small protrusion (lagaena) forms on the anterior segment of the auditory vesicle corresponding to the sacculus, which soon develops to form the spiral duct of the cochlea (ductus cochlearis). At first the walls of the cavity of the vesicle of the labyrinth are covered with similar epithelial cells, some of which due to the ingrowth of peripheral processes of the nerve cells from the auditory ganglion lying on the anterior surface of the labyrinth, transform into sensory cells (**organ of Corti**).

The mesenchyme adjoining the membranous labyrinth transforms into connective tissue, creating perilymphatic spaces around the utricle, sacculus and semicircular canals that had formed.

In the sixth month of embryonic life an osseous labyrinth arises from the perichondrium of the cartilaginous auditory capsule of the cranium by perichondral ossification. The osseous labyrinth grows

around the membranous labyrinths with perilymphatic spaces duplicating the general form of the latter. The middle ear, i.e. the tympanic cavity with the auditory tube, develops from the first pharyngeal pouch and the lateral part of the superior wall of the pharynx. Consequently, the epithelium of the mucous coat of the middle ear cavities derives from the entoderm. The auditory ossicles in the tympanic cavity are derived from the cartilage of the first (malleus and the anvil) and the second (stirrup)-visceral arches. The external ear originates from the first branchial pouch.

The peripheral part of the organ of hearing and gravitation is located in the temporal bone and is divided into three parts: the external, middle and internal ear. The first two serve exclusively for conducting sound vibrations, and the third, in addition to this, contains sound-sensory and static apparatuses which are the peripheral parts of the auditory and statokinetic analysers.

THE ORGAN OF HEARING

THE EXTERNAL EAR

The external ear consists of the **auricle** and the **external auditory meatus**.

The **auricle** (*auricula*) commonly called the ear, is formed of elastic cartilage covered with skin. This cartilage determines the external shape of the auricle and its projections: the free curved margin called the **helix**, the **anthelix**, located parallel to it, the anterior prominence, the **tragus**, and the **antitragus** situated behind it. Downward the ear terminates as the lobule which has no cartilage; this is a characteristic progressive developmental sign for man. In the depression on the lateral surface of the auricle (**the concha auriculæ**), behind the tragus, is the external auditory meatus around which the remainder of the rudimentary muscles has been preserved. They are of no functional significance. Since the auricle of man is immobile, some authors consider it to be a rudimentary formation, but others disagree with this point of view because the cartilaginous skeleton of the human ear is well defined.

The **external auditory meatus** (*meatus acusticus externus*) consists of two parts: **cartilaginous** and **bony**. The cartilaginous auditory meatus is a continuation of the auricular cartilage in the form of a groove open upward and to the back. Its internal end is joined by means of connective tissue with the edge of the tympanic part of the temporal bone. The cartilaginous auditory meatus constitutes two thirds of the whole external auditory meatus. The bony auditory meatus which constitutes two thirds of the entire length of the auditory meatus opens to the exterior by means of the porus acusticus externus on the periphery of which runs a circular bony **tympanic groove** (*sulcus tympanicus*).

The direction of the whole auditory meatus is frontal in general but it does not advance in a straight line; it winds in the form of letter "S" both horizontally and vertically. Because of the curves of the auditory meatus, the deeply situated tympanic membrane can only be seen by pulling the auricle backward, outward and upward. The skin that covers the auricle continues into the external auditory meatus. In the cartilaginous part of the meatus the skin is very rich both in sebaceous glands and in a particular kind of glands, the ceruminous glands (*glandulae ceruminosae*), which produce a yellowish secretion, cerumen (ear wax). In this part there are also short hairs growing in the skin which prevent tiny particles from getting into the organ. In the bony part of the duct the skin thins out considerably and extends without interruption onto the external surface of the tympanic membrane which closes the medial end of the meatus.

THE TYMPANIC MEMBRANE

The **tympanic membrane** or **ear drum** (*membrana tympani*) is located at the junctions of the external and middle ears. Its edge fits into the sulcus tympanicus at the end of the external auditory meatus as into a frame. The tympanic membrane is secured in the sulcus tympanicus by a fibrocartilaginous ring (*anulus fibrocartilagineus*). The membrane is inclined because of the oblique position of the medial end of the auditory meatus, but in newborns it is almost horizontal. The tympanic membrane in an adult is oval in shape and measures 11 mm in length and 9 mm in breadth. It is a thin semitransparent sheet in which the centre, called the **umbo** (*umbo membranae tympani*) is drawn in like a shallow funnel. Its external surface is covered by a thinned-out continuation of the **skin covering** the auditory meatus (*stratum cutaneum*), the internal surface by the **mucous lining** of the tympanic cavity (*stratum mucosum*).

The substance of the membrane itself between the two layers consists of fibrous connective tissue, the fibres of which in the peripheral part of the membrane run in a radial direction and in the central part in a circular direction. In the upper part the tympanic membrane contains no fibrous fibres and consists only of the skin and mucous layers and a thin stratum of loose tissue between them; this part of the tym-

panic membrane is softer and less tightly stretched; it has therefore been named the flaccid part (*pars flaccida*) in contrast to the remaining tightly stretched tense part (*pars tensa*).

THE MIDDLE EAR

The middle ear consists of the tympanic cavity and the auditory tube through which it communicates with the nasopharynx.

The tympanic cavity (*cavitas tympani*) is situated in the base of the pyramid of the temporal bone between the external auditory meatus and the labyrinth (internal ear). It contains a chain of three small ossicles transmitting sound vibrations from the tympanic membrane to the labyrinth. The tympanic cavity is very small (volume of about 1 cm³) and resembles a tambourine propped up on its side and greatly inclined toward the external auditory meatus. Six walls are distinguished in the tympanic cavity.

1. **The lateral, or membranous, wall (*paries membranaceus*)** of the tympanic cavity is formed by the tympanic membrane and the bony plate of the external auditory meatus. The upper dome-like, expanded part of the tympanic cavity, the epitympanic recess (*recessus epitympanicus*), contains two auditory ossicles: the head of the malleus and the anvil. In disease the pathological changes in the middle ear are most evident in the epitympanic recess.

2. **The medial wall** of the tympanic cavity belongs to the labyrinth and is therefore called the labyrinthine wall (*paries labyrinthicus*). It has two openings: a round one, the fenestra cochleae opening into the cochlea and closed with the secondary tympanic membrane (*membrana tympani secundaria*), and an oval fenestra vestibuli opening into the vestibulum labyrinthi. The base of the third auditory ossicle, the stapes, is inserted in this opening. The fenestra cochlea is the most vulnerable spot in the bony wall of the internal ear.

3. **The posterior, or mastoid, wall** of the tympanic cavity (*paries mastoideus*) has an eminence, the pyramid of the tympanum (*eminentia pyramidalis*), containing the stapedius muscle. The epitympanic recess is continuous posteriorly with the **tympanic antrum** (*antrum mastoideum*) into which the mastoid air cells (*cellulae mastoideae*) open. The tympanic antrum is a small cavity protruding toward the mastoid process from whose external surface it is separated by a layer of bone bordering with the posterior wall of the auditory meatus immediately behind the suprameatal spine where the antrum is usually cut open in suppuration of the mastoid process.

4. **The anterior, or carotid, wall** of the tympanic cavity (*paries caroticus*) is called so because it is closely adjoined by the internal carotid artery separated from the cavity of the middle ear only by a thin bony plate. In the upper part of this wall is the tympanic opening of the pharyngotympanic tube (*ostium tympanicum tubae auditivae*) which in newborns and infants gapes; this explains the frequent penetration of infection from the nasopharynx into the cavity of the middle ear and further into the skull.

5. **The roof, or tegmental wall** of the tympanic cavity (*paries tegmentalis*) corresponds on the anterior surface of the pyramid to the tegmen tympani and separates the tympanic cavity from the cranial cavity.

6. **The floor, or jugular wall** of the tympanic cavity (*paries jugularis*) faces the base of the skull in close proximity to the jugular fossa.

The three tiny auditory ossicles in the tympanic cavity are called the **malleus, incus, and stapes**, the Latin for hammer, anvil and stirrup, respectively, which they resemble in shape.

1. The malleus has a rounded **head** (*caput mallei*) which by means of a **neck** (*collum mallei*) is joined to the **handle** (*manubrium mallei*).

2. The incus has a **body** (*corpus inoudis*) and two diverging processes, a short (**crus breve**), and a long process (**crus longum**). The short process projects backward and abuts upon the fossa. The long process runs parallel to the handle of the malleus, medially and posteriorly of it and has a small oval thickening on its end, the **lenticular process** (*processus lenticularis*), which articulates with the stapes.

3. The stapes justifies its name in shape and consists of a small **head** (*caput stapedis*), carrying an articulating surface for the lenticular process of the incus and two limbs: an anterior, less curved limb (*crus anterius*), and a posterior more curved limb (*crus posterius*). The limbs are attached to an **oval base** (*basis stapedis*) fitted into the fenestra vestibuli.

In places where the auditory ossicles articulate with one another, two true joints of limited mobility are formed: the incudomalleolar joint (articulation incudomallearis) and the incudostapedial joint (articulatio incudostapedia).

The base of the stapes is joined with the edges of fenestra vestibuli by means of connective tissue to form the **tymanostapedial synclesmosis** (*syndesmosis tympanostapedia*). The auditory ossicles are attached, moreover, by several separate ligaments. On the whole, all three ossicles form a more or less mobile chain running across the tympanic cavity from the tympanic membrane to the labyrinth. The mobility of the ossicles becomes gradually reduced from malleus to stapes, as the result of which the organ of Corti located in the internal ear is protected from excessive concussions and harsh sounds.

The chain of ossicles performs two functions: (1) the conduction of sound through the bones and (2) the mechanical transmission of sound vibrations to the fenestra cochlea. The latter function is accomplished by two small muscles connected with the auditory ossicles and located in the tympanic cavity; they regulate the movement of the chain of ossicles. One of them, the tensor tympani muscle, lies in the canal for the tensor tympany (*semicanalis m. tensoris*) constituting the upper part of the musculotubal canal of the temporal bone; its tendon is fastened to the handle of the malleus near the neck. This muscle pulls the handle of the malleus medially, thus tensing the tympanic membrane. At the same time all the system of ossicles moves medially and the stapes presses into the fenestra cochlea. The muscle is innervated from the third division of the trigeminal nerve by a small branch of the nerve supplied to the tensor tympani muscle. The other muscle, the stapedius muscle, is lodged in the pyramid of the tympanum and fastened to the posterior limb of the stapes at the head. In function this muscle is an antagonist of the preceding one and accomplishes a reverse movement of the ossicle in the middle ear in the direction of the fenestra cochlea. The stapedius muscle is innervated from the facial nerve, which, passing nearby, sends small branch to the muscle.

In general, the muscles of the middle ear perform a variety of functions: (1) maintain the normal tonus of the tympanic membrane and the chain of auditory ossicles; (2) protect the internal ear from excessive sound stimuli and (3) accommodate the sound-conducting apparatus to sounds of different intensity and pitch. The basic principle of the work of the middle ear on the whole consists in conducting sound from the tympanic cavity to the fenestra cochlea.

The auditory, or Eustachian, or pharyngotympanic tube (*tuba auditiva, Eustachii*) which lends the name "eustachitis" to inflammation of the tube, lets the air pass from the pharynx into the tympanic cavity, thus equalizing the pressure in this cavity with the atmospheric pressure, which is essential for the proper conduction to the labyrinth of the vibrations of the tympanic membrane. The auditory tube consists of osseous and cartilaginous parts which are joined with each other. At the site of their junction, called the isthmus of the tube (*isthmus tubae*), the canal of the tube is narrowest. The bony part of the tube, beginning with its tympanic opening (*ostium tympanicum tubae auditivae*), occupies the large inferior portion of the muscular-tube canal (*semicanalis tubae auditivae*) of the temporal bone. The cartilaginous part, which is a continuation of the bony part, is formed of elastic cartilage.

The tube widens downward and terminates on the lateral wall of the nasopharynx as the pharyngeal opening (*ostium pharyngeum tubae auditivae*); the edge of the cartilage pressing into the pharynx forms the **tubae elevation** (*torus tubarius*). The mucosa lining the auditory tube is covered by ciliated epithelium and contains **mucous glands** (*glandulae tubariae mucosae*) and lymphatic follicles which accumulate in large amounts at the pharyngeal ostium to form **the tube tonsil** (*tonsilla tubaria*). Fibres of the tensor palati muscle arise from the cartilaginous part of the tube and, consequently, when this muscle contracts in swallowing, the lumen of the tube can expand, which is conducive to the passage of air into the tympanic cavity.

THE INTERNAL EAR

The internal ear, or the *labyrinth*, is located in the depth of the pyramid of the temporal bone between the tympanic cavity and the internal auditory meatus, through which the auditory nerve emerges from the labyrinth. A bony and membranous labyrinth is distinguished with the latter enclosed in the former.

The **bony labyrinth** (*labyrinthus osseus*) comprises a number of very small intercommunicating cavities, whose walls are of compact bone. Three parts are distinguished in the labyrinth: the vestibule, semicircular canals, and the cochlea. The cochlea lies in front of, medially to, and somewhat below the vestibule; the semicircular canals are situated behind, laterally to and above the vestibule.

1. The vestibule (*vestibulum*) which forms the middle part of the labyrinth is a small, approximately oval-shaped cavity, communicating in back through five openings with the semicircular canals. In front it communicates through a wider opening with the canal of the cochlea. On the lateral vestibular wall facing

the tympanic cavity is the opening mentioned above, the fenestra vestibuli, which is occupied by the base of the stapes. Another opening, **fenestra cochleae**, closed by the secondary tympanic membrane is located at the beginning of the cochlea. The **vestibular crest** (*crista vestibuli*) passing on the inner surface of the medial vestibular wall divides this cavity in two, of which the posterior connected with the semicircular canals is called the **elliptical recess** (*recessus ellipticus*) and the anterior, nearest the cochlea, is called the **spherical recess** (*recessus sphericus*). The aqueduct of the vestibule begins in the elliptical recess as a small opening (*apertura interna aqueductus vestibuli*), passes through the bony substance of the pyramid, and terminates on its posterior surface. Under the posterior end of the crest on the floor of the vestibule is a small depression called the **cochlear recess** (*recessus cochlearis*).

2. The **semicircular canals** (*canales semicirculares ossei*) are three arch-like bony passages situated in three mutually perpendicular planes. The anterior semicircular canal (canal is *semicircularis anterior*) is directed vertically at right angles to the axis of the pyramid of the temporal bone; the posterior semicircular canal (*canalis semicircularis posterior*), which is also vertical, is situated nearly parallel to the posterior surface of the pyramid, while the lateral canal (*canalis semicircularis lateralis*) lies horizontally, protruding toward the tympanic cavity. Each canal has two limbs.

The bony labyrinth may easily be separated as a whole from the spongy substance of the pyramid surrounding it in the skulls of children. The external shape of the labyrinth may also be studied conveniently on its metal moulds obtained by means of corrosion, which open into the vestibule by five apertures only; however, because the neighbouring ends of the anterior and posterior canals join to form a common limb termed the *crus commune*. One of the limbs of each canal before joining the vestibule forms a dilatation called an *ampulla*. An ampullated limb is called *crus ampullare*, and a non-ampullated limb is termed *crus simplex*.

3. The **cochlea** is as a spiral bony canal (*canalis spiralis cochleae*) which, beginning from the vestibule, winds up like the shell of a snail into two and a half coils. The bony pillar around which the coils wind lies horizontally and is called the *modiolus*. An osseous spiral lamina (*lamina spiralis ossea*) projects from the *modiolus* into the cavity of the canal along the entire length of its coils. This lamina together with the cochlear duct divides the cavity of the cochlea into two sections: the *scala vestibuli* which communicates with the vestibule and the *scala tympani* which opens on the skeletonized bone into the tympanic cavity through the *fenestra cochleae*. Near this *fenestra* in the *scala tympani* is a very small inner orifice of the aqueduct of the cochlea (*aqueductus cochleae*), whose external opening (*apertura externus canaliculi cochleae*) lies on the inferior surface of the pyramid of the temporal bone.

The **membranous labyrinth** (*labirynthus membranaceus*) lies inside the bony labyrinth and repeats its configurations more or less exactly. It contains the peripheral parts of the statokinetic and auditory analysers. Its walls are formed of a thin semitransparent connective tissue membrane. The membranous labyrinth is filled with a transparent fluid called the **endolymph**. Since the membranous labyrinth is somewhat smaller than the bony labyrinth, a space is left between the walls of the two; this is the *perilymphatic space* (*spatium perilymphaticum*) filled with **perilymph**. Two parts of the membranous labyrinth are located in the vestibule of the bony labyrinth: the **utricle** (*utriculus*) and the **sacculle** (*sacculus*). The utricle has the shape of a closed tube and occupies the elliptical recess of the vestibule and communicates posteriorly with **three membranous semicircular ducts** (*ductus semicirculares*) which lie in the same kind of bony canals exactly repeating their shape. This is why it is necessary to distinguish the **anterior, posterior and lateral membranous ducts** (*ductus semicircularis anterior, posterior and lateralis*) with their corresponding ampullae: *ampulla membranacea anterior, posterior and lateralis*. The *sacculle*, a pear-shaped sac, lies in the spherical recess of the vestibule and is joined with the utricle and with the long narrow endolymphatic duct which passes through the aqueduct of the vestibule and ends as a small blind dilatation termed the **endolymphatic sac** (*saccus endolymphaticus*) under the *dura mater* on the posterior surface of the pyramid of the temporal bone. The small canal joining the endolymphatic duct with the utricle and *sacculle* is called the **utriculosaccular duct** (*ductus utriculosaccularis*). With its narrowed lower end which is continuous with the narrow **ductus reuniens**, the *sacculle* joins with the vestibular end of the **duct of the cochlea**. Both vestibular *sacculles* are surrounded by the *perilymphatic space*.

In the region of the semicircular canals the membranous labyrinth is suspended on the compact wall of the bony labyrinth by a complex system of threads and membranes. This prevents its displacement during forceful movements.

Neither the *perilymphatic* nor the *endolymphatic* spaces are sealed off completely from the environment. The *perilymphatic space* communicates with the middle ear via the *fenestra vestibuli* and the *fenestra*

tra cochleae which are both elastic and yielding. The endolymphatic space is connected by means of the endolymphatic duct with the endolymphatic sac lying in the cranial cavity; it is a more elastic reservoir which communicates with the inner space of the semicircular canals and the rest of the labyrinth. This creates physical prerequisites for the response of the semicircular canals to progressive movement.

STRUCTURE OF THE AUDITORY ANALYSER

The anterior part of the membranous labyrinth, the duct of the **cochlea**, (*ductus cochlearis*), enclosed in the bony cochlea, is the most vital component of the organ of hearing. The duct of the cochlea begins with a blind end in the cochlear recess of the vestibule somewhat posteriorly of the ductus reuniens that connects the duct with the saccule. Then it passes along the entire spiral canal of the bony cochlea and ends blindly at its apex. On cross section the duct of the cochlea is triangular in shape. One of its three walls is fused with the external wall of the bony canal of the cochlea; another wall, termed the **spiral membrane** (*membrana spiralis*), is a continuation of the osseous spiral lamina which stretches between the free edge of the latter and the outer wall. The third, a very thin wall of the **duct of the cochlea** (*paries vestibularis ductus cochlearis*) stretches obliquely from the spiral lamina to the outer wall. The **basilar membrane** (*membrana spiralis*) encloses the basilar lamina which carries the apparatus appreciating sounds: the organ of Corti, or the spiral organ. The duct of the cochlea separates the scala vestibuli from the scala tympani except for a place in the dome of the cochlea where they communicate through an opening called helicotrema. Scala vestibuli communicates with the perilymphatic space of the vestibule and scala tympani ends blindly at the fenestra cochlea.

The spiral organ

The **organ of Corti**, or the **spiral organ** (*organum spirale*) is located along the length of the duct of the cochlea on the basilar lamina occupying the part nearest to the osseous spiral lamina. The **basilar lamina** (*lamina basilaris*) consists of a large number (24 000) of fibrous fibres of different length tightened like strings (**acoustic strings**). According to the well-known theory of Helmholtz, they are resonators, the vibrations of which make it possible to appreciate tones of different pitch. According to the findings of electron microscopy, however, these fibres form an elastic network which as a whole resonates with strictly graded vibrations. The organ of Corti itself is composed of several rows of epithelial cells among which the neurosensory acoustic hair cells can be distinguished. Certain authors claim that this organ performs the role of a "reverse microphone" converting mechanical (acoustic) vibrations into electric oscillations.

The pathways of sound conduction

From the functional viewpoint, the organ of hearing (the peripheral part of the auditory analyser) is divided into two: (1) the sound-conducting apparatus, i.e. the external and middle ear, as well as certain components of the internal ear (peri- and endolymph); and (2) the sound-appreciating apparatus, i.e. the internal ear (schematical representation of the auditory analyser). The air waves collected by the ear pass into the external auditory meatus, hit the tympanic membrane and cause it to vibrate. The vibrations of the tympanic membrane, the degree of tension of which is regulated by the contraction of the tensor tympani muscle (innervation from the trigeminal nerve) move the handle of the malleus fused with the membrane. The malleus moves the incus, and the incus moves the stapes fitted in the fenestra vestibuli leading into the internal ear. The displacement of the stapes in the fenestra vestibuli is regulated by the contraction of the stapedius muscle (innervation by the nerve supplied to it from the facial nerve). Thus, the chain of ossicles which are linked in mobility, conducts the vibrating movements of the tympanic membrane in a definite direction, namely, to the fenestra vestibuli.

The movement of the stapes in the fenestra vestibuli stirs the labyrinth fluid which protrudes the membrane of the vestibuli cochlea to the exterior. These fluid movements are necessary for the functioning of the highly sensitive elements of the organ of Corti. The first to move is the perilymph in the vestibule. Its vibrations in the perilymph of scala vestibuli reach the apex of the cochlea and are conducted via the helicotrema to the perilymph in the scala tympani; then they descend along it to the secondary tympanic membrane and close the fenestra cochleae (which is a vulnerable place in the osseous wall of the internal ear) and return, as it were, to the tympanic cavity. From the perilymph the sound vibrations are conducted to the endolymph and through it to the organ of Corti. Thus, due to the system of the auditory ossicles of the tympanic cavity, the vibrations of air in the external and internal ear are converted into vibrations of the fluid in the membranous labyrinth which stimulate the special acoustic hair cells of the organ of Corti comprising the receptor of the auditory analyser.

In the receptor, which plays the role of a "reverse microphone" the mechanical vibrations causing fluctuations in the fluid (endolymph) are converted into electric oscillations characterizing the nerve process spreading along the conductor to the cerebral cortex. The conductor of the auditory analyser is made up of auditory conductors consisting of a number of links. The cellular body of the first neuron lies in the spiral ganglion. The peripheral process of the bipolar cells enters the organ of Corti and ends at the receptor cells, while the central process passes as the cochlear division of the auditory nerve to its nuclei, nucleus dorsalis and nucleus ventralis, located in the rhomboid fossa. According to the electrophysiological data, different parts of the auditory nerve conduct sounds of various frequency of vibration.

The nuclei mentioned above contain the bodies of the secondary neurons, the axons of which form the central acoustic fasciculus, which, in the region of the posterior nucleus of the trapezoid body, crosses with the fasciculae of the same name on the opposite side, forming the lateral lemniscus. The fibres of the central acoustic fasciculus coming from the ventral nucleus form a trapezoid body and, on passing the pons, become part of the lateral lemniscus of the opposite side. The fibres of the central fasciculus coming out of the dorsal nucleus, run along the floor of the fourth ventricle in the form of auditory striae (striae medullares ventriculi quarti), penetrate the reticular formation of the pons and, together with the fibres of the trapezoid body, become part of the lateral lemniscus on the opposite side. The lateral lemniscus ends partly in the inferior quadrigeminal bodies of the tectal lamina and partly in medial geniculate body, where the third neurons are located.

The superior quadrigeminal bodies serve as the reflex centre for auditory impulses. They are connected with the spinal cord by the tectospinal tract through which motor responses to auditory stimuli entering the mesencephalon are made. Reflex responses to auditory impulses may also be received from other intermediate auditory nuclei, namely nuclei of the trapezoid body and lateral lemniscus, connected by short pathways with the motor nuclei of the mesencephalon, the pons and medulla oblongata.

Ending in structures related to hearing (the inferior quadrigeminal bodies and the medial geniculate body) the auditory fibres and their collaterals also join the medial longitudinal fasciculus by means of which they establish connections with the nuclei of the oculomotor muscles and the motor nuclei of other cranial and spinal nerves. These connections provide an explanation for the reflex responses to auditory stimuli.

The inferior quadrigeminal bodies have no centripetal connections with the cortex. The medial geniculate body contains the cellular bodies of the last neurons whose axons as part of the internal capsule reach the cortex of the temporal lobe of the brain. **The cortical end** of the auditory analyser is located in the **superior temporal gyrus** (Heschl's gyrus, area 41). Here the vibrations of air in the external ear causing movement of the auditory ossicles in the middle ear and fluctuation of fluid in the internal ear are converted into nerve impulses further in the receptor, transmitted along the conductor to the brain cortex, and perceived in the form of auditory sensations. Consequently, thanks to the auditory analyser, the air vibrations, i.e. the objective phenomenon existing independently of our conscious awareness of the surrounding reality, is reflected in our consciousness in the form of subjectively perceived images, i.e. auditory perceptions.

Due to the auditory analyser, various sound stimuli received in our brain as sound perceptions and complexes of perceptions, sensations, become signals (primary signals) of vitally important environmental phenomena. According to Pavlov, this constitutes the first signalling system of reality, i.e. concretely visible thinking also inherent in animals.

THE ORGAN OF GRAVITATION AND BALANCE

The analyser of gravitation, or the statokinetic analyser begins in the membranous labyrinth, where its peripheral part is located. The parts of the membranous labyrinth (discussed in describing the auditory analyser) are related to the statokinetic analyser, or the analyser of gravitation.

The structure of the statokinetic analyser (the analyser of gravitation). The sensory hair cells which the fibres of the vestibular part of the auditory nerve approach from the exterior are located in a layer of squamous epithelium lining the inner surface of the **sacculae, utricle and the ampullae** of the semicircular canals. In the utricle and sacculae these sites appear as whitish spots (**maculae** of the utricle and sacculae) (*s. maculae staticae*), because the sensitive epithelium in them is covered by a jelly-like substance. In the ampullae of the semicircular canals they appear in the form of **crisetae** (*crisetae ampullares, s. crisetae staticae*). The epithelium covering the projections of the crisetae has sensory cells with pili, which are joined by nerve fibres. The semicircular canals as well as the sacculae and utricle may also be

stimulated by either acceleration or deceleration of rotary or right-angle movements, by shaking, swinging or any kind of change in the position of the head, as well as by the force of gravity. The stimulus in such instances is tension of sensory hairs or the pressure exerted on them by the jelly-like substance, which stimulates the nerve endings.

Thus, the vestibular apparatus and the entire system of conductors connected with it and reaching the cerebral cortex, is the analyser of the position and movements of the head in space. As a consequence of this, it was named the statokinetic analyser. The receptor of this analyser in the form of special hair cells which are stimulated by the flow of endolymph is located in the utricle and saccule (maculae), which regulate static equilibrium, i.e. the balance of the head and, thereby, the body when it is at rest, and in the ampullae of the semicircular canals (cristae), regulating dynamic equilibrium, i.e. the balance of the body moving in space. Although changes in the position and movements of the head are also regulated by other analysers (particularly by the visual, motor and skin analysers), the vestibular analyser plays a very special role.

The first neuron of the reflex arc of the statokinetic analyser lies in the vestibular ganglion. The peripheral processes of the cells of this ganglion advance as part of the vestibular division of the auditory nerve to the labyrinth and communicate with the receptor. Meanwhile, the central processes pass together with the cochlear division of the auditory nerve through the porus acusticus internus into the cranial cavity and further into the brain matter through the cerebellopontile angle. Here the fibres of the first neuron divide into ascending and descending fibres and approach the vestibular nuclei (second neuron), which are situated in the medulla oblongata and pons on the floor of the rhomboid fossa. On each side there are four vestibular nuclei: superior, lateral, medial and inferior. The ascending fibres end in the superior nucleus, the descending fibres in the remaining three nuclei. The descending fibres and their accompanying nucleus descend very low, through the whole medulla oblongata to the level of the gracile and cuneate nuclei.

The vestibular nuclei give rise to fibres running in three directions: (1) to the cerebellum; (2) to the spinal cord, and (3) the fibres which are part of the medial longitudinal fasciculus.

The fibres to the cerebellum pass through its inferior peduncle; this path is called the vestibulo-cerebellar tract. (Some of the fibres of the vestibular nerve without interruption in the vestibular nuclei pass directly into the cerebellum; the vestibular nerve is connected with the flocculonodular lobe, the oldest part of the cerebellum.)

There are also fibres running in the opposite direction, from the cerebellum to the vestibular nuclei; as a result, a close connection is established between them, while the nucleus fastigii of the cerebellum becomes an important vestibular centre.

The nuclei of the vestibular nerve are connected with the spinal cord through the vestibulospinal tract. It passes in the anterior funiculi of the spinal cord and approaches the cells of the anterior horns along the entire length of the spinal cord. It is the connections with the spinal cord that are responsible for the conduction of the vestibular reflexes to the muscles of the neck, trunk and limbs, and for the regulation of the muscle tonus.

The fibres from the vestibular nuclei, comprising part of the medial longitudinal fasciculus, establish contact with the nuclei of the nerves of the eye muscles. As a result vestibular reflexes are accomplished by the eye muscles (compensating for accommodation of the eyes, i.e. keeping them directed at a certain object when the head is moved). This also explains the peculiar movements of the eyeballs (nystagmus) in loss of balance.

The vestibular nuclei are connected through the reticular formation with the nuclei of the vagus and glossopharyngeal nerves. This is why dizziness in stimulation of the vestibular apparatus is often attended by a vegetative reaction in the form of a slower pulse beat, a drop in arterial pressure, nausea, vomiting, cold hands and feet, a pale face, cold sweat, etc.

Vestibular tracts play a major role in regulating balance and help keep the head in its natural position even when the eyes are closed.

A decussated tract is directed from the vestibular nuclei to the thalamus (third neuron) and further to the cerebral cortex for conscious awareness of the head's position. It is presumed that the cortical end of the statokinetic analyser is distributed in the cortex of the occipital and temporal lobes. (With the gradual phylogenetic development of animals the function of balance becomes less dependent on the vestibular apparatus.)

Adequate training of the vestibular apparatus allows airmen and space-fliers to become adapted to sudden movements and changes in the position of the body during flights.

THE ORGAN OF VISION

Light became the stimulus which gave rise, in the animal world, to a special organ of vision. The main component of this organ in all animals are specific sensory cells which originate from the ectoderm and are capable of receiving stimuli from rays of light. For the most part these cells are surrounded by pigment which serves to channel the rays of light in a definite direction and absorb superfluous rays.

Such cells in lower animals are scattered over the body (primitive "eyes"), but eventually a depression forms, lined by sensitive cells (retina) which is reached by the nerve. In invertebrates light-refracting media appear in front of the depression (lens) for the concentration of light rays falling on the retina. Vertebrates whose eyes attain the highest development, also develop muscles which move the eye and protective adaptations (eyelids, lacrimal apparatus).

A characteristic feature of vertebrates is seen in the fact that the light-sensitive membrane of the eye (retina), which contains specific cells, does not develop directly from the ectoderm, but forms by projecting from the anterior brain vesicle.

At the first stage of development of the visual analyser (in fish) the light-sensitive cells in its peripheral end (retina) look like rods and only the visual centres are located in the brain, in the mesencephalon. Such an organ of vision is only capable of light perception and of distinguishing objects. In terrestrial animals the retina is supplemented by new light-sensitive cells, retinal cones, and new visual centres appear in the diencephalon; in mammals new visual centres appear in the cortex. Due to this the eye becomes capable of colour vision. All this is connected with the first signalling system. Finally, very special development in man is attained by the highest centres of vision in the cerebral cortex which are responsible for the origin of abstract thinking closely associated with visual images, and the written speech, which are a component of the second signalling system inherent only in man.

Embryogenesis of the eye. The lateral projections of the wall of the anterior brain vesicle (the parts that give rise to the diencephalon) are stretching laterally form two optic vesicles communicating by a hollow narrowed stalk with the brain. The optic nerve develops from the stalk and the retina forms from the peripheral segment of the optic vesicle. With the development of the lens, the anterior segment of the optic vesicle projects toward the stalk and, as a result, the vesicle becomes a double-layer "optic cup".

Both layers are continuous with each other at the margin of the cup to form the rudiment of the pupil. The outer (bulging) layer of the cup develops into the pigmented layer of the retina, while the inner layer becomes the sensory layer (the retina proper). The lens forms in the anterior part of the cup in its cavity, and the vitreous body forms behind the lens.

The external coats of the eye, the vascular coat, sclera and cornea, develop from the mesoderm surrounding the optic cup together with the lens. The sclera and cornea are derived from the outer denser layer of the mesoderm, while the choroid with the ciliary body and iris develop from the inner layer of the mesoderm which is rich in vessels. In the anterior part of the embryonic eye both layers separate one from the other, as a result of which the anterior chamber forms. In this place, the outer layer of the mesoderm becomes transparent and forms the cornea. The ectoderm covering the cornea in front provides the conjunctival epithelium which extends to the posterior surface of the eyelid.

THE EYEBALL

The eye (*oculus*) consists of the **eyeball** (*bulbus oculi*) and the **auxiliary apparatus** surrounding it.

The eyeball is spherical in shape and is situated in the eye socket. The **anterior pole**, corresponding to the most convex point on the cornea, and the **posterior pole**, located lateral to the exit of the optic nerve are distinguished in the eyeball. The straight line connecting both poles is called the **optic axis**, or the **external axis** of the eye (*axis opticus*). The part lying between the posterior surface of the cornea and the retina is called the **internal axis** of the eye. This axis intersects at a sharp angle with the so-called **visual line** (*linea visus*) which passes from the object of vision, through the nodal point, to the place of the best vision in the central pit of the retina. The lines connecting both poles along the circumference of the eyeball form meridians, whereas the plane perpendicular to the optic axis is the equator of the eyeball dividing it into the anterior and posterior halves. The horizontal diameter of the equator is slightly shorter than the external optic axis (the latter is 24 mm and the former 23.6 mm); its vertical diameter is even shorter (23.3 mm). The internal optic axis of a normal eye is 21.3 mm; in myopic eyes it is longer, and in

long-sighted people (hypermetropic eyes) it is shorter. Consequently, the focus of converging rays in myopic people is in front of the retina, and in hypermetropic people it is behind the retina. To achieve clear vision, the hypermetropic people must always resort to accommodation. To relieve such anomalies of sight, adequate correction by means of eyeglasses is essential.

The eyeball has three coats surrounding its inner nucleus; a fibrous outer coat, a vascular middle coat, and an inner reticular coat (the retina).

THE COATS OF THE EYEBALL

1. **The fibrous coat** (*tunica fibrosa bulbi*) forms an external sheath around the eyeball and plays a protective role. In the posterior, largest of its parts, it forms an opaque tunic called the **sclera**, and in the anterior segment, a transparent **cornea**. Both areas of the fibrous coat are separated one from the other by a shallow **circular sulcus** (*sulcus sclerae*).

- **The sclera** consists of dense connective tissue, white in colour. Its anterior part is visible between the eyelids and is commonly referred to as the "white of the eye". At the junction with the cornea in the thickness of the sclera there is a circular venous canal, the **sinus venosus sclerae** (Schlemmi) called Schlemm's canal. Since light must penetrate to the light-sensitive elements of the retina lying in the eyeball, the anterior segment of the fibrous tunic becomes transparent and develops into the cornea.

- **The cornea** is a continuation of the sclera and is a transparent, rounded plate, convex toward the front and concave in the back, which, like the glass of a watch, is fitted by its edge (*limbus corneae*) into the anterior segment of the sclera.

2. **The vascular coat** of the eyeball (*tunica vasculosa bulbi*) is rich in vessels, soft, dark-coloured by the pigment contained in it. It lies immediately under the sclera and consists of three parts: the choroid, the ciliary body, and the iris.

- **The choroid** (*chorioidea*) is the posterior largest segment of the vascular coat. Due to the constant movement of the choroid in accommodation a slit-like lymphatic perichoroidal space (*spatium perichorioideale*) is formed here between the layers.

- **The ciliary body** (*corpus ciliare*), the anterior thickened part of the vascular tunic, is arranged in the shape of a circular swelling in the region where the sclera is continuous with the cornea. Its posterior edge, which forms the ciliary ring (*orbiculus ciliaris*), is continuous with the choroid. This place corresponds to the retinal ora serrata (see below). In front the ciliary body is connected with the external edge of the iris. Anteriorly of the ciliary ring the ciliary body carries about 70 fine radially arranged whitish ciliary processes (*processus ciliares*).

Due to the abundance and the particular structure of the vessels in the ciliary processes, they secrete a fluid, the aqueous humour of the chambers. This part of the ciliary body is comparable with the choroid plexus of the brain and is known as the **secernent part** (*L. secerne to separate*). The other part, the **accommodating part**, is formed by the smooth **ciliary muscle** (*musculus ciliaris*) which lies in the thickness of the ciliary body externally of the **ciliary processes**. Formerly this muscle was divided into three portions: **external meridional** (Bruecke); **middle radial** (Ivanov) and **internal circulatory** (Miller). Now only two types of fibres are distinguished, namely, **meridional** (*fibrae meridionales*) arranged longitudinally, and **circular** (*fibrae circulares*) arranged in rings. The meridional fibres forming the principal part of the ciliary muscle, begin from the sclera and terminate posteriorly in the choroid. On contracting, they tighten the choroid and relax the sac of the lens in adjusting the eyes for short distances (**accommodation**). Circulatory fibres help accommodation, advancing the frontal part of the ciliary processes and this is why they are particularly well developed in hypermetropics who must tense their accommodation apparatus very greatly. Thanks to the elastic tendons, the muscle after contraction resumes its initial position and there is no need for an antagonist.

Fibres of both kinds intertwine and form a single muscular-elastic system which in childhood consists mostly of meridional fibres, and in old age of circulatory fibres. During the lifespan the muscle fibres become gradually atrophied and replaced by connective tissue, which explains the weakening of accommodation in old age. In females degeneration of the ciliary muscle begins 5 to 10 years earlier than in males, that is, with the onset of the menopause.

- **The iris** is the most anterior portion of the vascular coat of the eye and is a circular vertically standing plate with a round aperture called the **pupil** (*pupilla*). The pupil is not exactly in the middle, but is slightly displaced toward the nose. The iris plays the role of a diaphragm regulating the amount of light entering the eye. Due to this, when there is strong light the pupil contracts and when the light is weak, it

dilates. With its outer edge (**margo ciliaris**) the iris is connected with the ciliary body and the sclera. Its inner edge surrounding the pupil (**margo pupillaris**) is free. The iris has an **anterior surface** (*facies anterior*) facing the cornea and a **posterior surface** (*facies posterior*) adhering to the lens. The anterior surface which is visible through the transparent cornea is of different colour in different people and determines the colour of their eyes. This depends on the amount of pigment contained in the superficial layers of the iris. If there is much pigment, the eyes are brown to the point of being very dark, and, on the contrary, if the pigmentary layer is weakly developed or practically absent, then the colour tones are mixed greenish-grey and light blue. The last two colours are mainly due to the transparency of the black retinal pigment on the posterior surface of the iris. In performing the function of a diaphragm, the iris displays remarkable mobility; this is ensured by fine adaptation and the correlation of its components.

Thus, the **basis of the iris** (*stroma iridis*) consists of connective tissue with the architecture of a lattice in which vessels have been fitted radially from the periphery to the pupil. These vessels are the sole carriers of elastic elements (since the connective tissue of the stroma contains no elastic fibres) and together with the connective tissue form an elastic skeleton of the iris, permitting it to change easily in size.

The actual movements of the iris itself are accomplished by the muscle system lodged within the stroma. This system consists of smooth muscle fibres which are partly arranged in a ring around the pupil to form the **sphincter of the pupil** (*m. sphincter pupillae*) and partly fan out radially from the pupillary aperture to form the **dilator of the pupil** (*m. dilatator pupillae*). Both muscles are interrelated and affect each other: the sphincter stretches the dilator, while the dilator straightens out the sphincter. Because of this, each muscle returns to its initial position, which explains the rapidity of the movements of the iris. This integral muscle system has a punctum fixum on the ciliary body.

The sphincter of the pupil is innervated by parasympathetic fibres coming from the nucleus of Yakubovich's as part of n. oculomotorius, while the dilator of the pupil is innervated by sympathetic fibres from the sympathetic trunk.

The impermeability of the diaphragm to light is due to the presence on its posterior surface of a double layer of pigmentary epithelium. On the anterior surface washed by fluid it is covered by the endothelium of the anterior chamber.

Due to the position of the vascular membrane between the fibrous and retinal coats its pigmentary layer prevents superfluous rays from falling on the retina and the vessels are distributed to all layers of the eyeball.

The vessels and nerves of the vascular coat. The arteries arise from branches of the ophthalmic artery some of which enter the eyeball from the back (the short and long posterior ciliary arteries), while others pass anteriorly along the margin of the cornea (the anterior ciliary arteries). Anastomosing among themselves around the ciliary margin of the iris, they form the greater arterial circle of the iris (circulus arteriosus iridis major) from which small branches reach out to the ciliary body and the iris, and around the pupillary orifice and the lesser arterial circle of the iris (circulus arteriosus iridis minor). The veins form a dense network in the vascular membrane. The blood from them is carried mainly by four (or five-six) venae vorticosae, resembling whirlpools (I, vortex whirl), which along the equator of the eyeball at equal distances obliquely perforate the sclera and drain into the orbital veins. Anteriorly the veins from the ciliary muscle drain into the sinus venosus sclerae (Schlemm's canal) which, in turn, drains into the anterior ciliary veins. Schlemm's canal also communicates with the lymphatic channel through a system of fissures in Fontana's space.

The nerves of the vascular coat contain sensory (from the trigeminal nerve), parasympathetic (from the oculomotorius nerve) and sympathetic fibres.

3. The retina is the innermost of the three coats of the eyeball adhering to the vascular coat along its entire length until it reaches the pupil. Unlike the other coats it develops from the ectoderm (from the walls of the optic cup) and according to its origin consists of two layers; the external pigmented layer (stratum pigmenti retinae) and the internal layer which is the **retina proper**. The retina proper is divided in structure and function into two parts: the posterior, which contains light-sensitive elements, constitutes the **optic part** of the retina (*pars optica retinae*) and the anterior part which does not have these elements. The junction between the two is an **indented line** (*ora serrata*) passing at the level where the choroid is continuous with the ciliary ring of the ciliary body. The optic part is almost fully transparent and opacifies only in a cadaver.

On examination with an ophthalmoscope the fundus of the eye in a living person is dark red because the blood in the vascular coat is seen through the transparent retina. On this crimson background a white

round spot is visible on the fundus which is the site of the exit of the optic nerve from the retina. As it emerges the optic nerve forms an **optic disk** (*discus n. optici*) with a crater-like depression in the centre, the excavation of the optic disc (excavatio disci). In examination with a mirror the vessels of the retina arising from this excavation are also well visible. The fibres of the optic nerve deprived of their myelin sheath spread from the disk in all directions over the optic part of the retina. The optic disk which is about 1.7 mm in diameter lies slightly medially (toward the nose) of the posterior pole of the eye. Laterally from it and, at the same time, slightly in the temporal direction from the posterior pole, is an oval 1 mm area, **the macula**; it is reddish brown in a living person with a **pinpoint depression** (*fovea centralis*) in the centre. This is the site of sharpest acuity of vision.

There are light-sensitive visual cells in the retina, whose peripheral ends are shaped as rods and cones. Since they are situated in the external layer of the retina and adhere to the **pigmentary layer**, to reach them, the rays of light must penetrate the entire thickness of the retina. **The rods** contain visual purple (**rhodopsin**) which is responsible for the pink hue of a fresh retinal membrane in the dark; in the light it is rendered colourless. The formation of visual purple is attributed to the cells of the pigmentary layer. **The cones** do not contain visual purple. It should be noted that there are only cones in the macula and no rods. In the region of the optic disk there are no light-sensitive elements at all, as a result of which this place produces no visual sensation and is therefore called the blind spot.

The retinal vessels. The retina possesses its own system of blood vessels. It is supplied with arterial blood from a special small branch arising from the ophthalmic artery, the central artery of the retina (a. centralis retinae) which penetrates the optic nerve even before the nerve emerges from the eye, and then passes along the axis of the nerve to the centre of its disk where it divides into superior and inferior branches. The branches of the artery reach the ora serrata. The veins fully correspond to the arteries and are known as venulae of the same names. All the venules of the retina join to form the central vein of the retina (v. centralis retinae) which passes together with the artery of the same name along the axis of the optic nerve and drains into the superior ophthalmic vein or directly into the sinus cavernosus.

THE REFRACTING MEDIA OF THE EYE

The transparent light-refracting media of the eye are the **cornea**, **the vitreous body** and **the lens** which serve to form the image on the retina, and the aqueous humour which fills the chambers of the eye and provides nutrition for the avascular structures of the eye.

A. The vitreous body (*corpus vitreum*) fills the space between the lens and the retina and is an absolutely transparent mass resembling jelly. The lens presses into the anterior surface of the vitreous body as a result of which a depression, the **hyaloid fossa** (*fossa hyaloidea*) forms; its edges are joined with the capsule of the lens by a special ligament.

B. The lens is a very important light-refracting medium of the eyeball. It is completely transparent and shaped like a lentil or a biconvex glass. The central points of the posterior and anterior convexities are called the poles of the lens (polus anterior and posterior), while the peripheral circumference of lens, where both surfaces join, is called the equator. The axis of the lens joining both poles is 3.7 mm long when looking at a distance and 4.4 mm in accommodation, when the lens becomes more convex. The equatorial diameter is 9 mm. The equator plane is at a right angle to the optical axis.

THE ACCESSORY ORGANS OF THE EYE

The accessory organs of the eye include the **ocular muscles**, the **fasciae**, the **eyebrows**, the **eyelids**, the **conjunctiva**, and the **lacrimal apparatus**.

The Ocular Muscles (*musculi oculi*).—The ocular muscles are the: Levator palpebrae superioris, Rectus superior, Rectus medialis, Rectus lateralis, Rectus inferior, Obliquus inferior and Obliquus superior.

The **Levator palpebrae superioris** is thin, flat, and triangular in shape. It *arises* from the under surface of the small wing of the sphenoid, above and in front of the optic foramen, from which it is separated by the origin of the Rectus superior. At its origin, it is narrow and tendinous, but soon becomes broad and fleshy, and ends anteriorly in a wide aponeurosis which splits into three lamellae. The superficial lamella blends with the upper part of the orbital septum, and is prolonged forward above the superior tarsus to the palpebral part of the Orbicularis oculi, and to the deep surface of the skin of the upper eyelid. The middle lamella, largely made up of non-striped muscular fibers, is inserted into the upper margin of the superior tarsus, while the deepest lamella blends with an expansion from the sheath of the Rectus superior and with it is attached to the superior fornix of the conjunctiva.

The upper part of the sheath of the Levator palpebrae becomes thickened in front and forms, above the anterior part of the muscle, a transverse ligamentous band which is attached to the sides of the orbital cavity. On the medial side it is mainly fixed to the pulley of the Obliquus superior, but some fibers are attached to the bone behind the pulley and a slip passes forward and bridges over the supraorbital notch; on the lateral side it is fixed to the capsule of the lacrimal gland and to the frontal bone. In front of the transverse ligamentous band the sheath is continued over the aponeurosis of the Levator palpebrae, as a thin connective-tissue layer which is fixed to the upper orbital margin immediately behind the attachment of the orbital septum. When the Levator palpebrae contracts, the lateral and medial parts of the ligamentous band are stretched and check the action of the muscle; the retraction of the upper eyelid is checked also by the orbital septum coming into contact with the transverse part of the ligamentous band.

The four Recti arise from a fibrous ring (*annulus tendineus communis*) which surrounds the upper, medial, and lower margins of the optic foramen and encircles the optic nerve. The ring is completed by a tendinous bridge prolonged over the lower and medial part of the superior orbital fissure and attached to a tubercle on the margin of the great wing of the sphenoid, bounding the fissure. Two specialized parts of this fibrous ring may be made out: a lower, the **ligament or tendon of Zinn**, which gives origin to the Rectus inferior, part of the Rectus internus, and the lower head of origin of the Rectus lateralis; and an upper, which gives origin to the Rectus superior, the rest of the Rectus medialis, and the upper head of the Rectus lateralis. This upper band is sometimes termed the **superior tendon of Lockwood**. Each muscle passes forward in the position implied by its name, to be inserted by a tendinous expansion into the sclera, about 6 mm. from the margin of the cornea. Between the two heads of the Rectus lateralis is a narrow interval, through which pass the two divisions of the oculomotor nerve, the nasociliary nerve, the abducent nerve, and the ophthalmic vein. Although these muscles present a common origin and are inserted in a similar manner into the sclera, there are certain differences to be observed in them as regards their length and breadth. The Rectus medialis is the broadest, the Rectus lateralis the longest, and the Rectus superior the thinnest and narrowest.

The **Obliquus oculi superior** (*superior oblique*) is a fusiform muscle, placed at the upper and medial side of the orbit. It arises immediately above the margin of the optic foramen, above and medial to the origin of the Rectus superior, and, passing forward, ends in a rounded tendon, which plays in a fibrocartilaginous ring or pulley attached to the trochlear fovea of the frontal bone. The contiguous surfaces of the tendon and ring are lined by a delicate mucous sheath, and enclosed in a thin fibrous investment. The tendon is reflected backward, lateralward, and downward beneath the Rectus superior to the lateral part of the bulb of the eye, and is inserted into the sclera, behind the equator of the eyeball, the insertion of the muscle lying between the Rectus superior and Rectus lateralis.

The **Obliquus oculi inferior** (*inferior oblique*) is a thin, narrow muscle, placed near the anterior margin of the floor of the orbit. It arises from the orbital surface of the maxilla, lateral to the lacrimal groove. Passing lateralward, backward, and upward, at first between the Rectus inferior and the floor of the orbit, and then between the bulb of the eye and the Rectus lateralis, it is inserted into the lateral part of the sclera between the Rectus superior and Rectus lateralis, near to, but somewhat behind the insertion of the Obliquus superior.

Actions.—The Levator palpebrae raises the upper eyelid, and is the direct antagonist of the Orbicularis oculi. The four Recti are attached to the bulb of the eye in such a manner that, acting singly, they will turn its corneal surface either upward, downward, medialward, or lateralward, as expressed by their names. The movement produced by the Rectus superior or Rectus inferior is not quite a simple one, for inasmuch as each passes obliquely lateralward and forward to the bulb of the eye, the elevation or depression of the cornea is accompanied by a certain deviation medialward, with a slight amount of rotation. These latter movements are corrected by the Obliqui, the Obliquus inferior correcting the medial deviation caused by the Rectus superior and the Obliquus superior that caused by the Rectus inferior. The contraction of the Rectus lateralis or Rectus medialis, on the other hand, produces a purely horizontal movement. If any two neighboring Recti of one eye act together they carry the globe of the eye in the diagonal of these directions, viz., upward and medialward, upward and lateralward, downward and medialward, or downward and lateralward. Sometimes the corresponding Recti of the two eyes act in unison, and at other times the opposite Recti act together. Thus, in turning the eyes to the right, the Rectus lateralis of the right eye will act in unison with the Rectus medialis of the left eye; but if both eyes are directed to an object in the middle line at a short distance, the two Recti mediales will act in unison. The movement of circumduction, as in looking around a room, is performed by the successive actions of the four Recti. The Obli-

qui rotate the eyeball on its antero-posterior axis, the superior directing the cornea downward and lateralward, and the inferior directing it upward and lateralward; these movements are required for the correct viewing of an object when the head is moved laterally, as from shoulder to shoulder, in order that the picture may fall in all respects on the same part of the retina of either eye.

Nerves.—The Levator palpebrae superioris, Obliquus inferior, and the Recti superior, inferior, and medialis are supplied by the oculomotor nerve; the Obliquus superior, by the trochlear nerve; the Rectus lateralis, by the abducent nerve.

The **Fascia Bulb** (*capsule of Ténon*) is a thin membrane which envelops the bulb of the eye from the optic nerve to the ciliary region, separating it from the orbital fat and forming a socket in which it plays. Its inner surface is smooth, and is separated from the outer surface of the sclera by the **periscleral lymph space**. This lymph space is continuous with the subdural and subarachnoid cavities, and is traversed by delicate bands of connective tissue which extend between the fascia and the sclera. The fascia is perforated behind by the ciliary vessels and nerves, and fuses with the sheath of the optic nerve and with the sclera around the entrance of the optic nerve. In front it blends with the ocular conjunctiva, and with it is attached to the ciliary region of the eyeball. It is perforated by the tendons of the ocular muscles, and is reflected backward on each as a tubular sheath. The sheath of the Obliquus superior is carried as far as the fibrous pulley of that muscle; that on the Obliquus inferior reaches as far as the floor of the orbit, to which it gives off a slip. The sheaths on the Recti are gradually lost in the perimysium, but they give off important expansions. The expansion from the Rectus superior blends with the tendon of the Levator palpebrae; that of the Rectus inferior is attached to the inferior tarsus. The expansions from the sheaths of the Recti lateralis and medialis are strong, especially that from the latter muscle, and are attached to the lacrimal and zygomatic bones respectively. As they probably check the actions of these two Recti they have been named the **medial and lateral check ligaments**. Lockwood has described a thickening of the lower part of the facia bulbi, which he has named the **suspensory ligament of the eye**. It is slung like a hammock below the eyeball, being expanded in the center, and narrow at its extremities which are attached to the zygomatic and lacrimal bones respectively.

The **Orbital Fascia** forms the periosteum of the orbit. It is loosely connected to the bones and can be readily separated from them. Behind, it is united with the dura mater by processes which pass through the optic foramen and superior orbital fissure, and with the sheath of the optic nerve. In front, it is connected with the periosteum at the margin of the orbit, and sends off a process which assists in forming the orbital septum. From it two processes are given off; one to enclose the lacrimal gland, the other to hold the pulley of the Obliquus superior in position.

The **Eyebrows** (*supercilia*) are two arched eminences of integument, which surmount the upper circumference of the orbits, and support numerous short, thick hairs, directed obliquely on the surface. The eyebrows consist of thickened integument, connected beneath with the Orbicularis oculi, Corrugator, and Frontalis muscles.

The **Eyelids** (*palpebrae*) are two thin, movable folds, placed in front of the eye, protecting it from injury by their closure. The upper eyelid is the larger, and the more movable of the two, and is furnished with an elevator muscle, the Levator palpebrae superioris. When the eyelids are open, an elliptical space, the palpebral fissure (*rima palpebrarum*), is left between their margins, the angles of which correspond to the junctions of the upper and lower eyelids, and are called the **palpebral commissures** or **canthi**.

The **lateral palpebral commissure** (*commissura palpebrarum lateralis; external canthus*) is more acute than the medial, and the eyelids here lie in close contact with the bulb of the eye: but the **medial palpebral commissure** (*commissura palpebrarum medialis; internal canthus*) is prolonged for a short distance toward the nose, and the two eyelids are separated by a triangular space, the **lacus lacrimalis**. At the basal angles of the lacus lacrimalis, on the margin of each eyelid, is a small conical elevation, the **lacrimal papilla**, the apex of which is pierced by a small orifice, the **punctum lacrimale**, the commencement of the lacrimal duct.

The **eyelashes** (*cilia*) are attached to the free edges of the eyelids; they are short, thick, curved hairs, arranged in a double or triple row: those of the upper eyelid, more numerous and longer than those of the lower, curve upward; those of the lower eyelid curve downward, so that they do not interlace in closing the lids. Near the attachment of the eyelashes are the openings of a number of glands, the **ciliary glands**, arranged in several rows close to the free margin of the lid; they are regarded as enlarged and modified sudoriferous glands.

Structure of the Eyelids.—The eyelids are composed of the following structures taken in their order from without inward: integument, areolar tissue, fibers of the *Orbicularis oculi*, tarsus, orbital septum, tarsal glands and conjunctiva. The upper eyelid has, in addition, the aponeurosis of the *Levator palpebrae superioris*/

The **integument** is extremely thin, and continuous at the margins of the eyelids with the conjunctiva. The **subcutaneous areolar tissue** is very lax and delicate, and seldom contains any fat. The **palpebral fibers of the *Orbicularis oculi*** are thin, pale in color, and possess an involuntary action.

The **tarsi** (*tarsal plates*) are two thin, elongated plates of dense connective tissue, about 2.5 cm. in length; one is placed in each eyelid, and contributes to its form and support. The **superior tarsus** (*tarsus superior; superior tarsal plate*), the larger, is of a semilunar form, about 10 mm. in breadth at the center, and gradually narrowing toward its extremities. To the anterior surface of this plate the aponeurosis of the *Levator palpebrae superioris* is attached. The **inferior tarsus** (*tarsus inferior; inferior tarsal plate*), the smaller, is thin, elliptical in form, and has a vertical diameter of about 5 mm. The free or ciliary margins of these plates are thick and straight. The attached or orbital margins are connected to the circumference of the orbit by the orbital septum. The lateral angles are attached to the zygomatic bone by the lateral palpebral raphé. The medial angles of the two plates end at the lacus lacrimalis, and are attached to the frontal process of the maxilla by the medial palpebral ligament

The **orbital septum** (*septum orbitale; palpebral ligament*) is a membranous sheet, attached to the edge of the orbit, where it is continuous with the periosteum. In the upper eyelid it blends by its peripheral circumference with the tendon of the *Levator palpebrae superioris* and the superior tarsus, in the lower eyelid with the inferior tarsus. Medially it is thin, and, becoming separated from the medial palpebral ligament, is fixed to the lacrimal bone immediately behind the lacrimal sac. The septum is perforated by the vessels and nerves which pass from the orbital cavity to the face and scalp. The eyelids are richly supplied with blood.

The **Tarsal Glands** (*glandulae tarsales [Meibomi]; Meibomian glands*). The tarsal glands are situated upon the inner surfaces of the eyelids, between the tarsi and conjunctiva, and may be distinctly seen through the latter on everting the eyelids, presenting an appearance like parallel strings of pearls. There are about thirty in the upper eyelid, and somewhat fewer in the lower. They are imbedded in grooves in the inner surfaces of the tarsi, and correspond in length with the breadth of these plates; they are, consequently, longer in the upper than in the lower eyelid. Their ducts open on the free margins of the lids by minute foramina.

Structure.—The tarsal glands are modified sebaceous glands, each consisting of a single straight tube or follicle, with numerous small lateral diverticula. The tubes are supported by a basement membrane, and are lined at their mouths by stratified epithelium; the deeper parts of the tubes and the lateral offshoots are lined by a layer of polyhedral cells.

The **conjunctiva** is the mucous membrane of the eye. It lines the inner surfaces of the eyelids or palpebrae, and is reflected over the forepart of the sclera and cornea.

The **Palpebral Portion** (*tunica conjunctiva palpebrarum*) is thick, opaque, highly vascular, and covered with numerous papillae, its deeper part presenting a considerable amount of lymphoid tissue. At the margins of the lids it becomes continuous with the lining membrane of the ducts of the tarsal glands, and, through the lacrimal ducts, with the lining membrane of the lacrimal sac and nasolacrimal duct. At the lateral angle of the upper eyelid the ducts of the lacrimal gland open on its free surface; and at the medial angle it forms a semilunar fold, the **plica semilunaris**. The line of reflection of the conjunctiva from the upper eyelid on to the bulb of the eye is named the **superior fornix**, and that from the lower lid the **inferior fornix**.

The **Bulbar Portion** (*tunica conjunctiva bulbi*).—Upon the *sclera* the conjunctiva is loosely connected to the bulb of the eye; it is thin, transparent, destitute of papillae, and only slightly vascular. Upon the *cornea*, the conjunctiva consists only of epithelium, constituting the epithelium of the cornea, already described. *Lymphatics* arise in the conjunctiva in a delicate zone around the cornea, and run to the ocular conjunctiva.

In and near the fornices, but more plentiful in the upper than in the lower eyelid, a number of convoluted tubular glands open on the surface of the conjunctiva. Other glands, analogous to lymphoid follicles, and called by Henle **trachoma glands**, are found in the conjunctiva, and, according to Strohmeier, are chiefly situated near the medial palpebral commissure. They were first described by Brush, in his description of Peyer's patches of the small intestine, as "identical structures existing in the under eyelid of the ox."

The **caruncula lacrimalis** is a small, reddish, conical-shaped body, situated at the medial palpebral commissure, and filling up the **lacus lacrimalis**. It consists of a small island of skin containing sebaceous and sudoriferous glands, and is the source of the whitish secretion which constantly collects in this region. A few slender hairs are attached to its surface. Lateral to the caruncula is a slight semilunar fold of conjunctiva, the concavity of which is directed toward the cornea; it is called the **plica semilunaris**. Müller found smooth muscular fibers in this fold; in some of the domesticated animals it contains a thin plate of cartilage.

The nerves in the conjunctiva are numerous and form rich plexuses. According to Krause they terminate in a peculiar form of tactile corpuscle, which he terms "terminal bulb."

THE LACRIMAL APPARATUS

The **Lacrimal Apparatus** (*apparatus lacrimalis*) consists of (a) the **lacrimal gland**, which secretes the tears, and its excretory ducts, which convey the fluid to the surface of the eye; (b) the **lacrimal ducts**, the **lacrimal sac**, and the **nasolacrimal duct**, by which the fluid is conveyed into the cavity of the nose.

The Lacrimal Gland (*glandula lacrimalis*).—The lacrimal gland is lodged in the lacrimal fossa, on the medial side of the zygomatic process of the frontal bone. It is of an oval form, about the size and shape of an almond, and consists of two portions, described as the superior and inferior lacrimal glands. The **superior lacrimal gland** is connected to the periosteum of the orbit by a few fibrous bands, and rests upon the tendons of the Recti superioris and lateralis, which separate it from the bulb of the eye. The **inferior lacrimal gland** is separated from the superior by a fibrous septum, and projects into the back part of the upper eyelid, where its deep surface is related to the conjunctiva. The ducts of the glands, from six to twelve in number, run obliquely beneath the conjunctiva for a short distance, and open along the upper and lateral half of the superior conjunctival fornix.

Structures of the Lacrimal Gland—In structure and general appearance the lacrimal resembles the serous salivary glands. In the recent state the cells are so crowded with granules that their limits can hardly be defined. They contain oval nuclei, and the cell protoplasm is finely fibrillated.

The Lacrimal Ducts (*ductus lacrimalis; lacrimal canals*).—The lacrimal ducts, one in each eyelid, commence at minute orifices, termed **puncta lacrimalia**, on the summits of the **papillae lacrimales**, seen on the margins of the lids at the lateral extremity of the lacus lacrimalis. The **superior duct**, the smaller and shorter of the two, at first ascends, and then bends at an acute angle, and passes medialward and downward to the lacrimal sac. The **inferior duct** at first descends, and then runs almost horizontally to the lacrimal sac. At the angles they are dilated into **ampullae**; their walls are dense in structure and their mucous lining is covered by stratified squamous epithelium, placed on a basement membrane. Outside the latter is a layer of striped muscle, continuous with the lacrimal part of the Orbicularis oculi; at the base of each lacrimal papilla the muscular fibers are circularly arranged and form a kind of sphincter.

The Lacrimal Sac (*saccus lacrimalis*).—The lacrimal sac is the upper dilated end of the nasolacrimal duct, and is lodged in a deep groove formed by the lacrimal bone and frontal process of the maxilla. It is oval in form and measures from 12 to 15 mm. in length; its upper end is closed and rounded; its lower is continued into the nasolacrimal duct. Its superficial surface is covered by a fibrous expansion derived from the medial palpebral ligament, and its deep surface is crossed by the lacrimal part of the Orbicularis oculi, which is attached to the crest on the lacrimal bone.

Structure.—The lacrimal sac consists of a fibrous elastic coat, lined internally by mucous membrane: the latter is continuous, through the lacrimal ducts, with the conjunctiva, and through the nasolacrimal duct with the mucous membrane of the nasal cavity.

The Nasolacrimal Duct (*ductus nasolacrimalis; nasal duct*).—The nasolacrimal duct is a membranous canal, about 18 mm. in length, which extends from the lower part of the lacrimal sac to the inferior meatus of the nose, where it ends by a somewhat expanded orifice, provided with an imperfect valve, the **plica lacrimalis** (*Hasneri*), formed by a fold of the mucous membrane. It is contained in an osseous canal, formed by the maxilla, the lacrimal bone, and the inferior nasal concha; it is narrower in the middle than at either end, and is directed downward, backward, and a little lateralward. The mucous lining of the lacrimal sac and nasolacrimal duct is covered with columnar epithelium, which in places is ciliated.

In conclusion of description of eye we shall explain the pathway of visual information. Light stimulates the light sensitive cells located in the retina. Before falling on the retina the light pass through different transparent media of eye ball: cornea, the aqueous humor of anterior chamber, pupil, lens and vitreous body. The nerve elements of retina form a chain of **three neurons**. First cells are light sensitive

components **rods and cones**, which constitute the receptor for visual analyser. After **bipolar** cells make connection to **ganglionic** (third element) multipolar neurons. The processes of the last ones make up the **optic nerve**. After leaving the orbits, the optic nerves decussate forming the optic chiasma. Only the medial parts of nerves running from medial halves of retina decussate. The opposite (lateral) sides remain uncrossed. Next structures that direct visual fibres are **optic tracts**. Analysing of optic information starts in subcortical centers of brain stem: **superior colliculi (midbrain)**, **lateral geniculate body (metathalamus)** and **pulvinar thalamy**. The terminal, cortical level of control and analyzing of vision is cortex around of calcarinus groove, area 17 **occipital lobe**. Commutation between subcortical and cortical centers is performed by **radiatio optica** (Gratiole bundle), that pass through end of posterior crus of internal capsule.

THE ORGAN OF TASTE

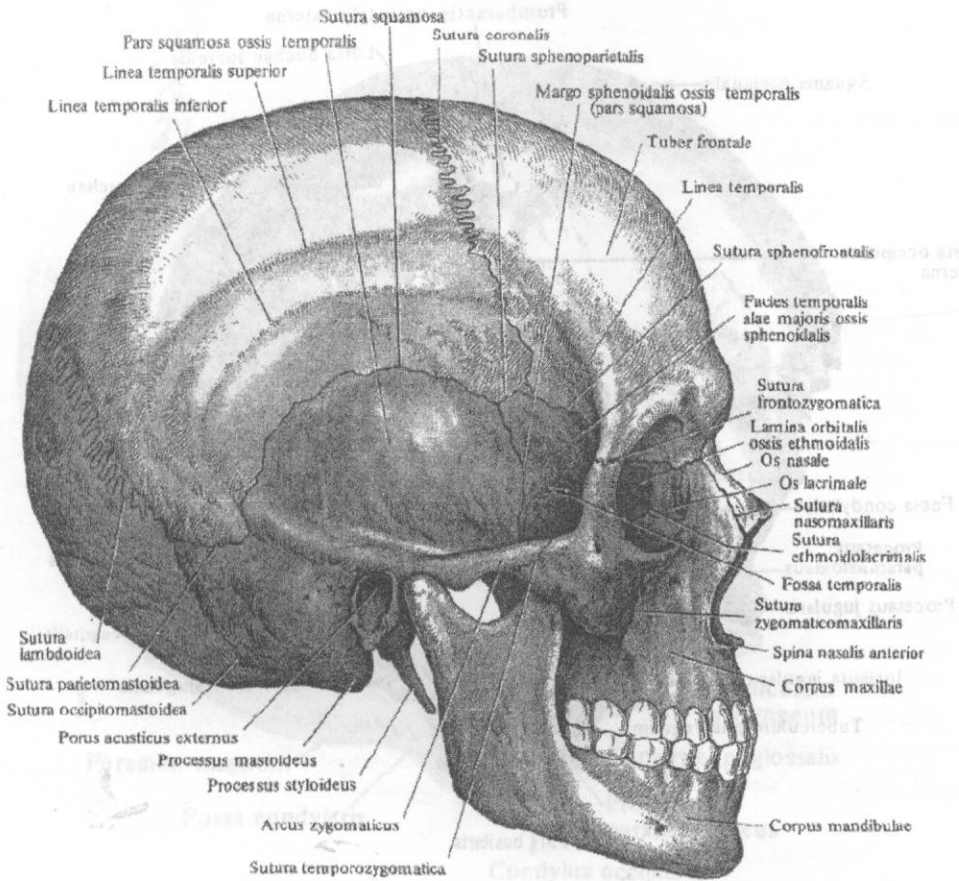
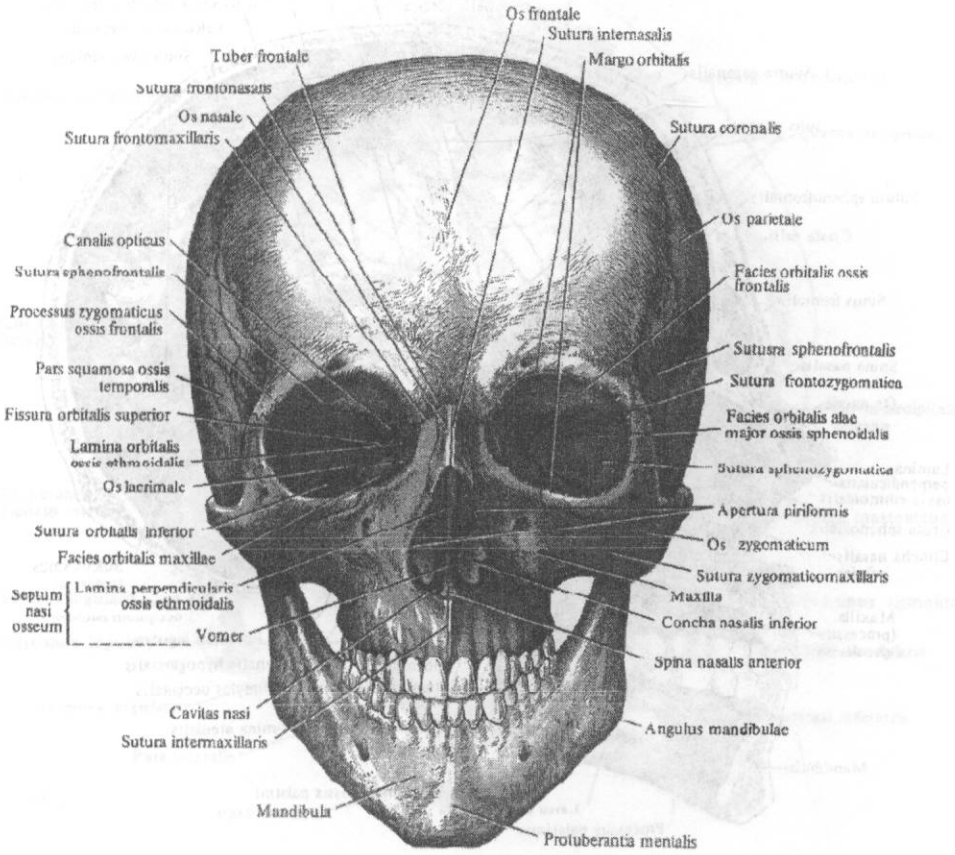
The importance of the sense of taste consist in recognizing the qualities of food. Formations like **taste buds** described below already existed in fish, although at this period they were as yet not fully differentiated from the organ of skin sense. Beginning with amphibians such buds were already concentrated in the oral cavity and nasal cavity, thus performing the function of taste buds. In reptiles and mammals the localization of taste buds is even more limited. They are mainly located on the tongue, although are also encountered on the palate, its arches and epiglottis. In man most of the taste buds are located in the **vallate and foliate papillae** (*papillae vallatae et foliatae*), a much less number in the **fungiform papillae** (*papillae fungiformis*), and finally some of them occurs on the **soft palate**, on the **posterior surface of the epiglottis** and on the **medial surface of the arytenoids cartilages**. The buds hold the taste cells which constitute the receptor of the taste analyzer. Its conductor is comprised of the conducting tracts from the receptors of taste consisting of **three paths**.

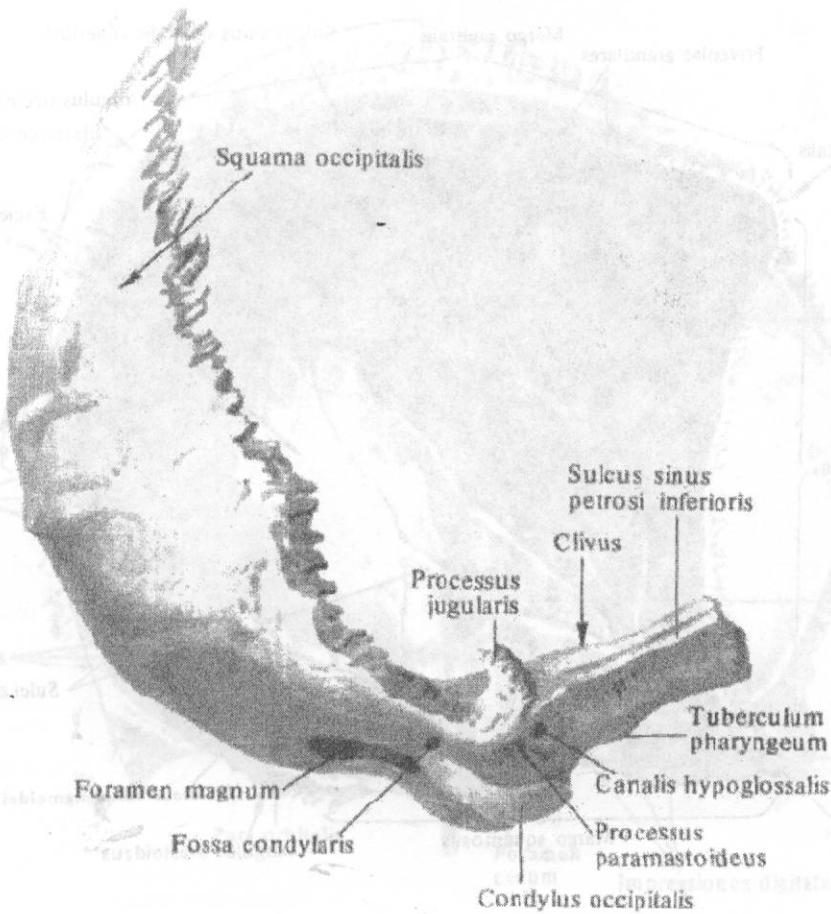
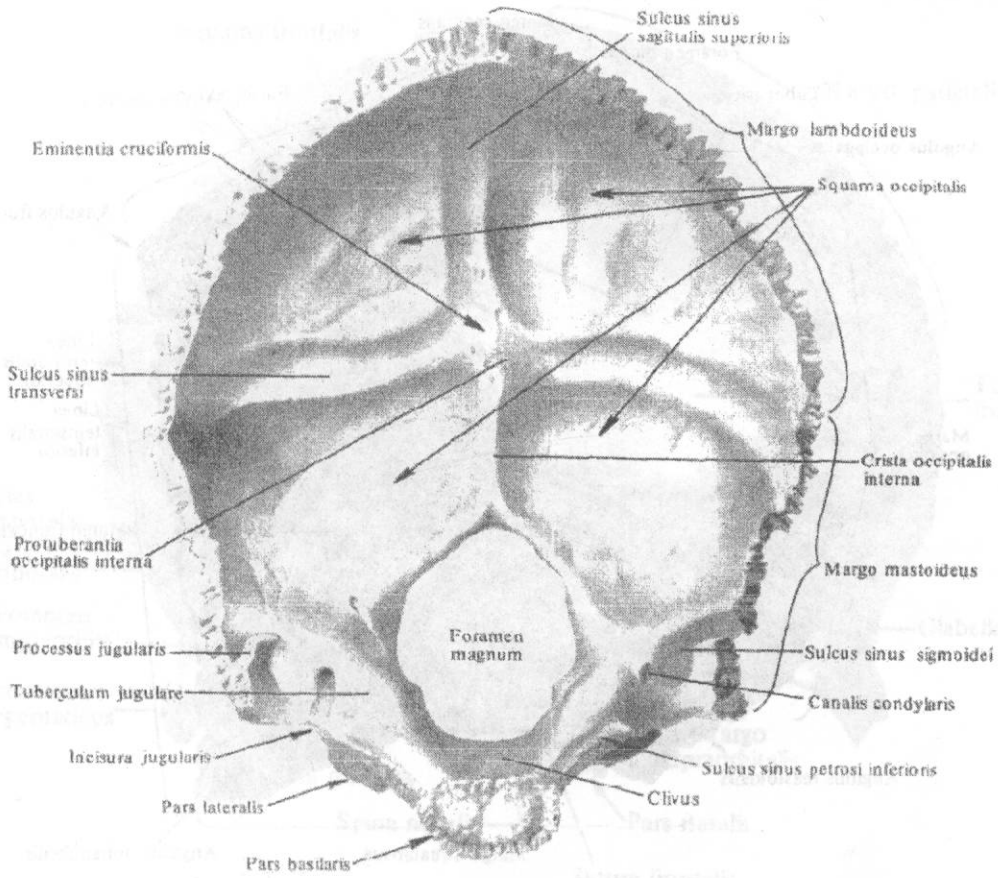
The first neuron is contained in ganglia of the afferent nerves of the tongue. The nerves conducting the sense of taste in man are: **1) the chorda tympani of the facial nerve** (the *first two thirds* of the tongue), **2) the glossopharyngeal nerve** (the *posterior third* of the tongue, the soft palate and its arches), and **3) the vagus nerve** (epiglottis).

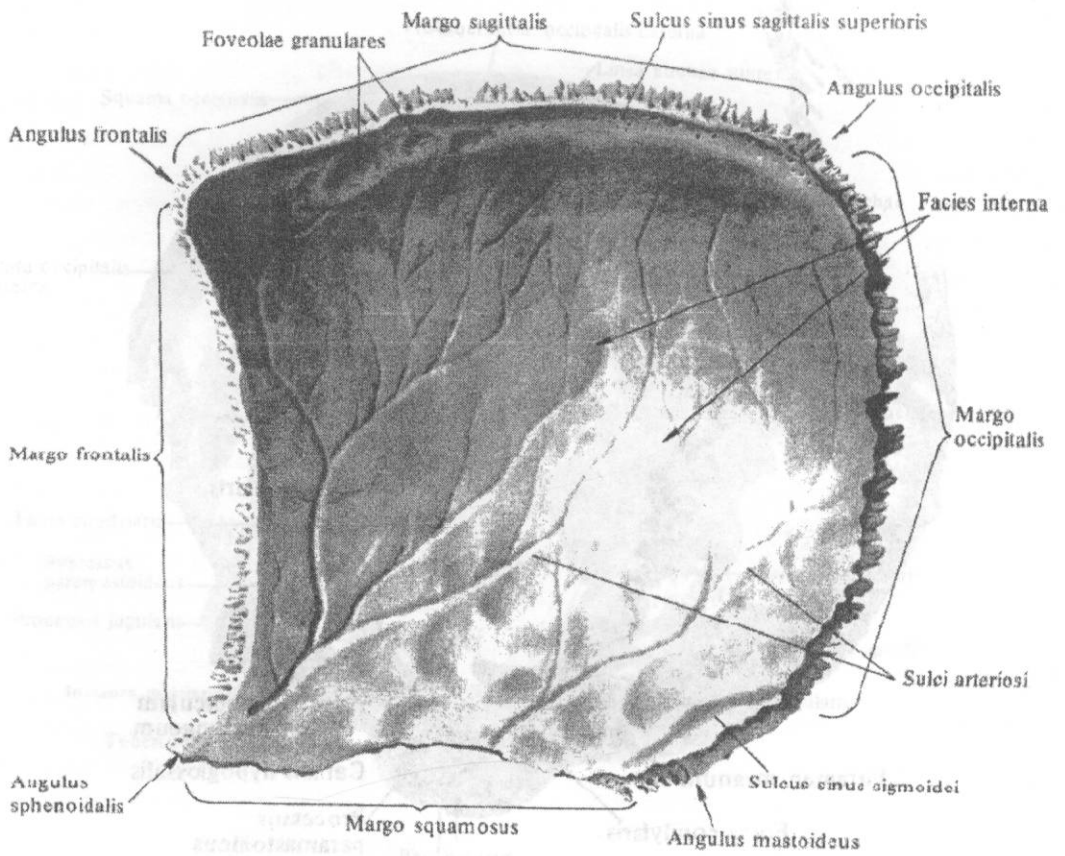
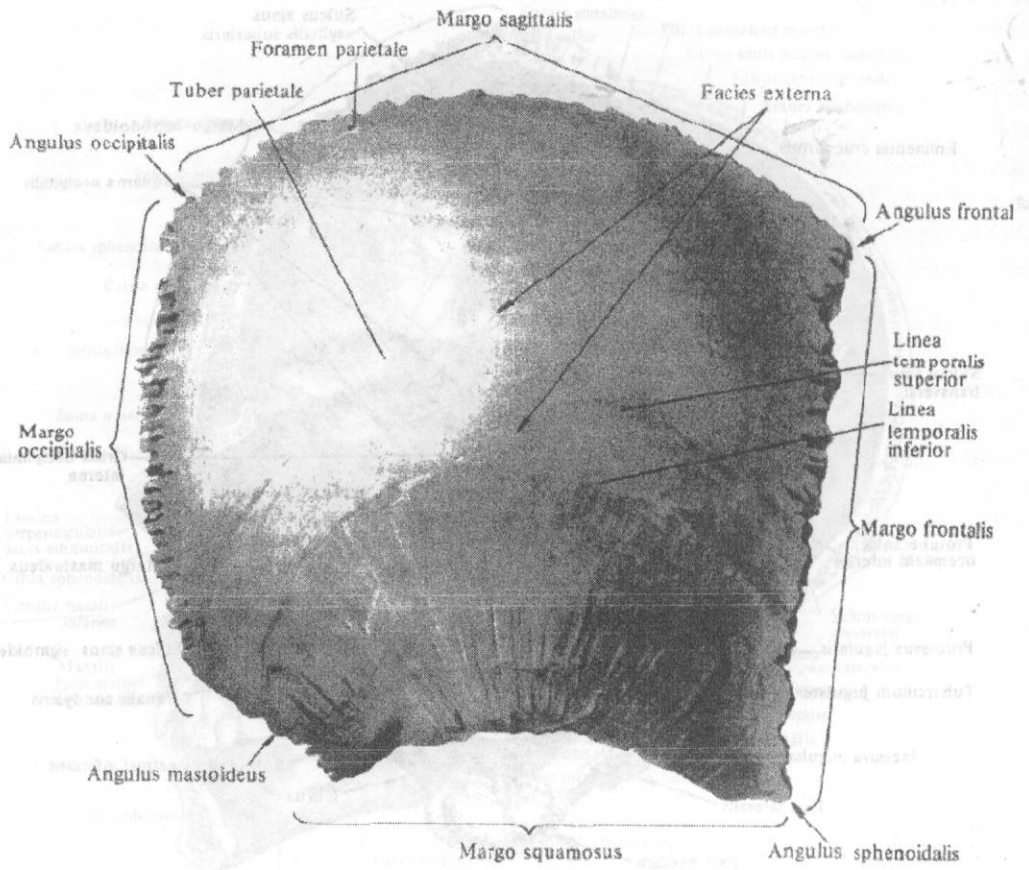
The location of the first neuron: **1) the ganglion of the facial nerve (ganglion geniculi)**. The peripheral processes of the cells of this ganglion run as a part of the chorda tympany to the anterior two thirds of the tongue mucosa where they come into contact with the taste receptor. The central processes pass as part of the sensory root of the facial nerve (n. intermedius) into the medulla oblongata. **2) the inferior ganglion of the the glossopharyngeal nerve**. The peripheral fibers of the cells of this ganglion run as part of ninth cranial nerve to the mucosal coat of the last third of the tongue, where they come into contact with the receptors. The central processes pass as part of this nerve into the Pons. **3) the inferior ganglion of the the vagus nerve**. As a part of the superior laryngeal nerve the peripheral processes of the cells of this ganglion approach the receptors located in the epiglottis. The central processes, as part of the vagus nerve, pass to the medulla oblongata. All the mentioned taste fibres end in medulla oblongata and pons, in the nucleus of tractus solitarius (second neuron). The processes of these last neurons ascend to the thalamus, that commute with cortical terminal point of analyzing of taste placed in parahippocampal gyrus, Ammon corn (hippocampus) and uncus, of temporal lobe.

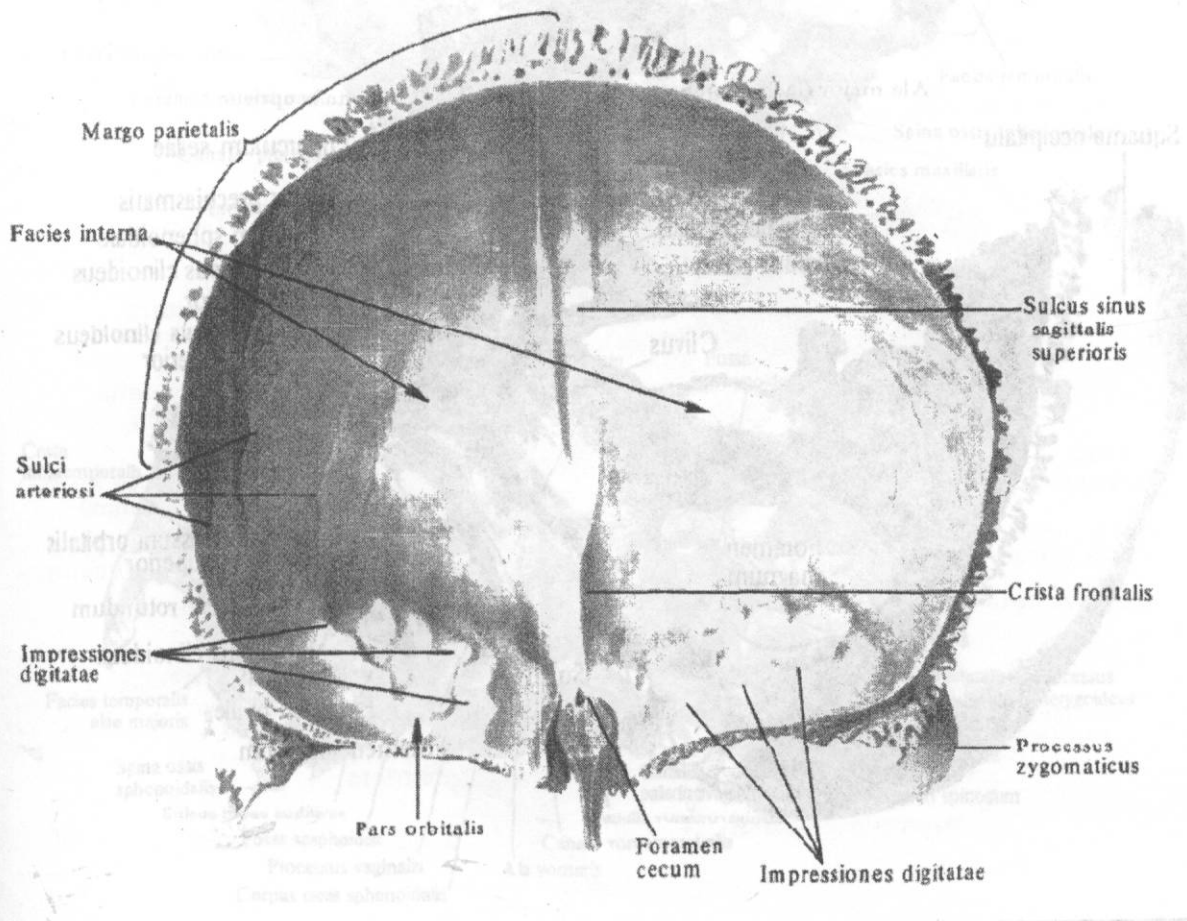
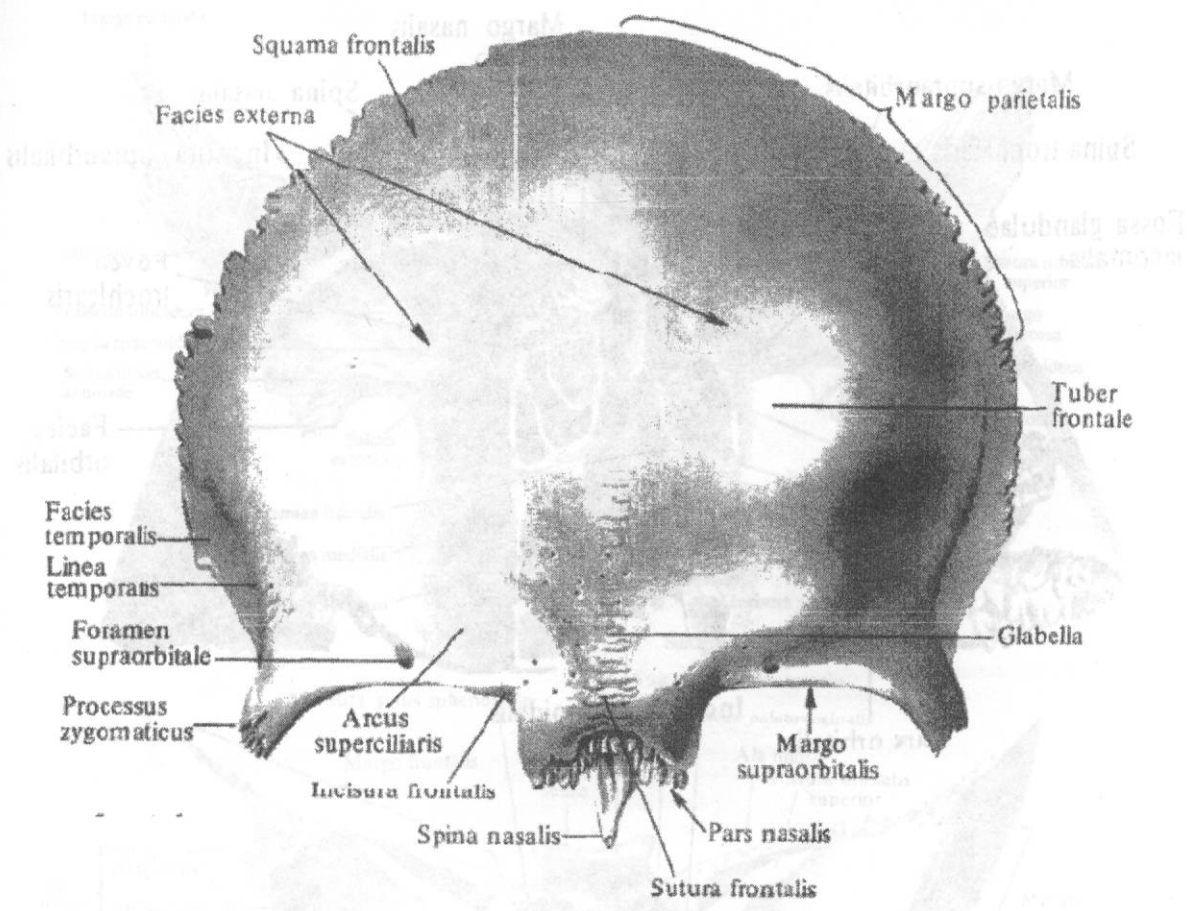
THE ORGAN OF SMELL

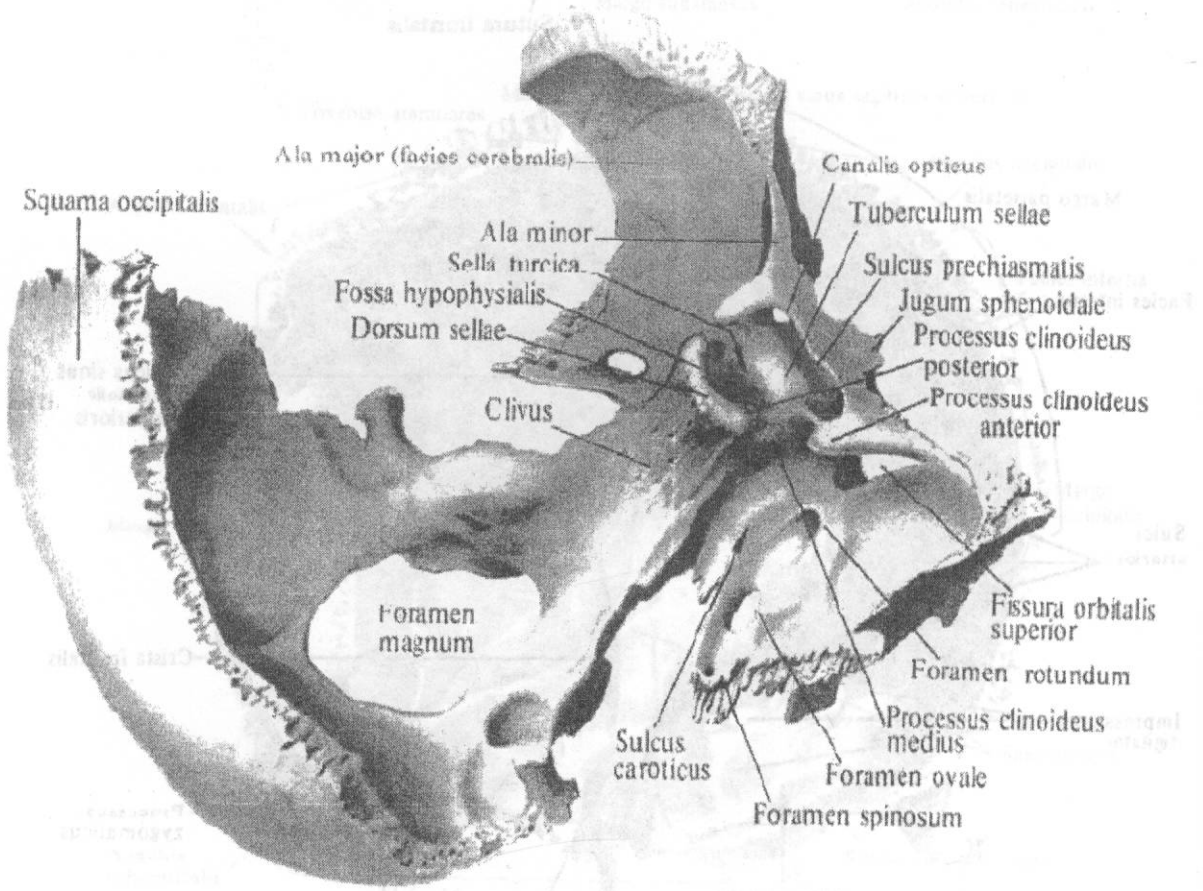
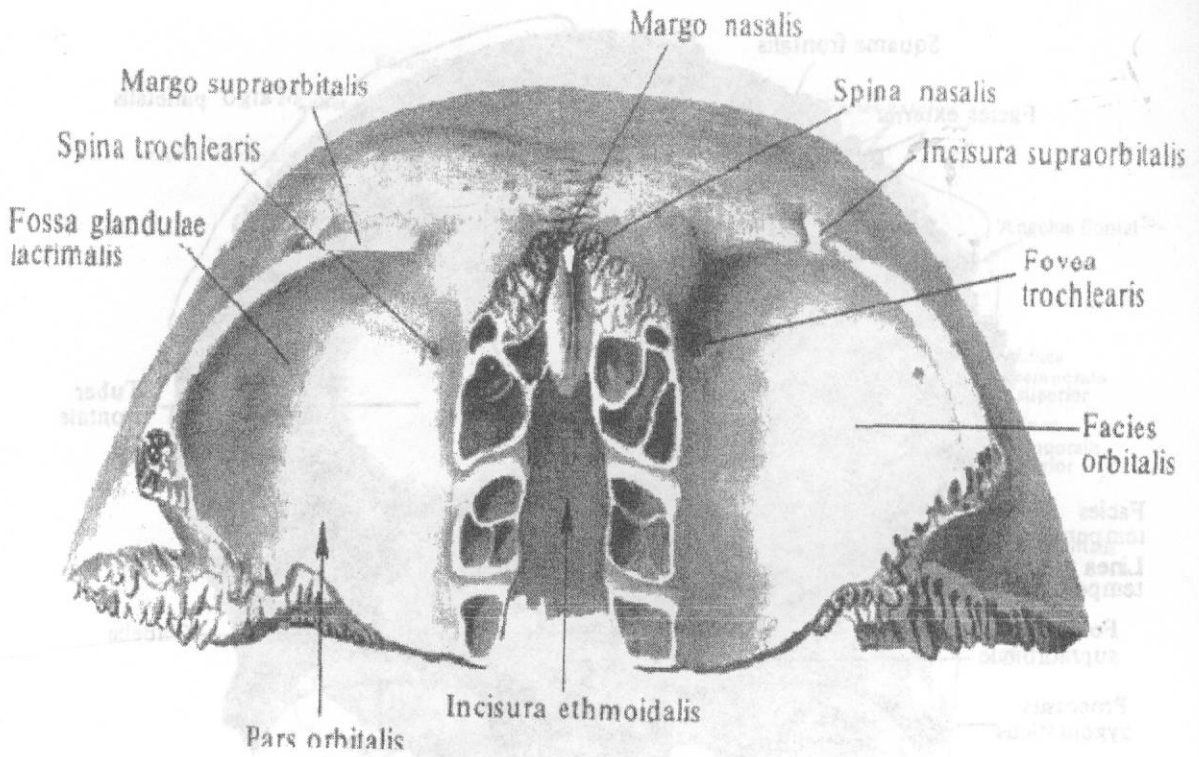
The receptor of smell analyser is represented by the olfactory cells that are spread in olfactory area of the nasal mucosa. The axons of olfactory cells as component of fila olfactoria pass through the sieve of cribriform plate of ethmoid bone. Olfactory bulb takes over these axons connecting them with mitral cells (second neuron) making the olfactory glomeruli. In continuation the axons of mitral neurons will run to the base of olfactory tract, the olfactory triangle, where its terminate in the grey matter of the anterior perforate substance and pelucide septum. The cortical analyser will be the same as in organ of taste in parahippocampal gyrus, Ammon corn (hippocampus) and uncus, of temporal lobe. There is direct way from olfactory triangle to the cortical end and using cingulate gyrus (cingulum, isthmus gyri cinguli, parahippocampal gyrus), mammillary bodies and fornix. Thalamus (anterior nuclei) also is connected with mammillary body (mamilothalamic tract – Vicq d'Azyr), taking part in subcortical analyzing of smell. At the level of hypothalamus (tuber cinereum) olfactory information is related with visceral sensation, including gustatory.

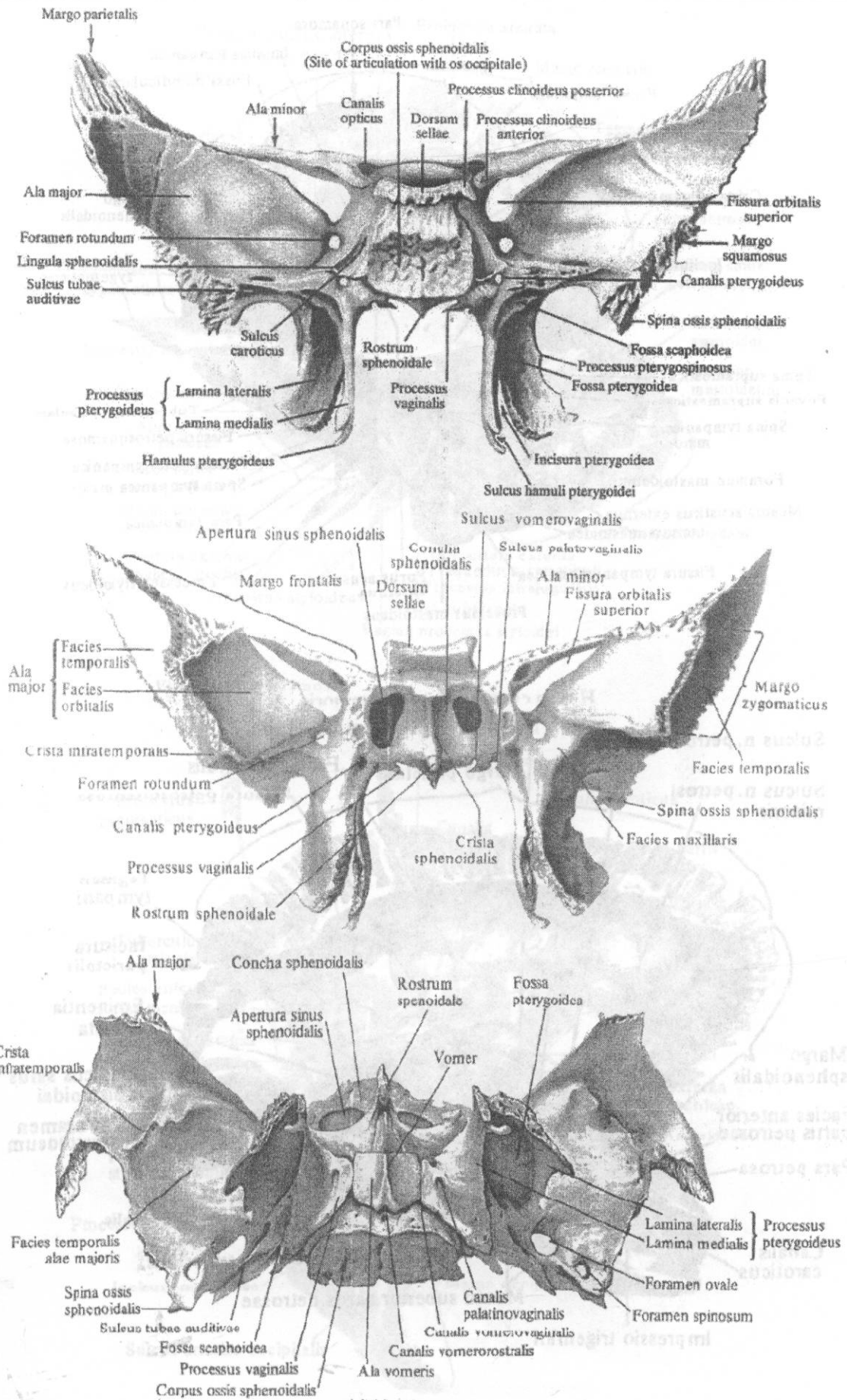


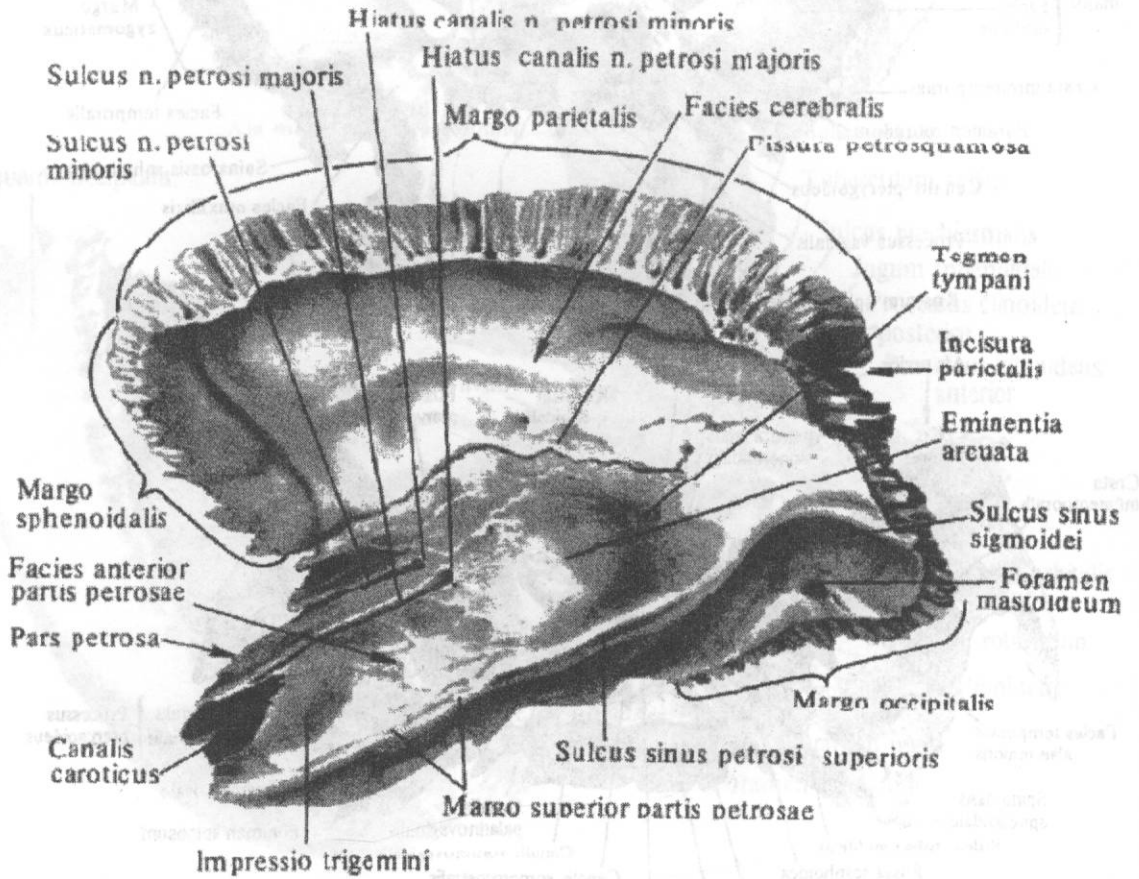
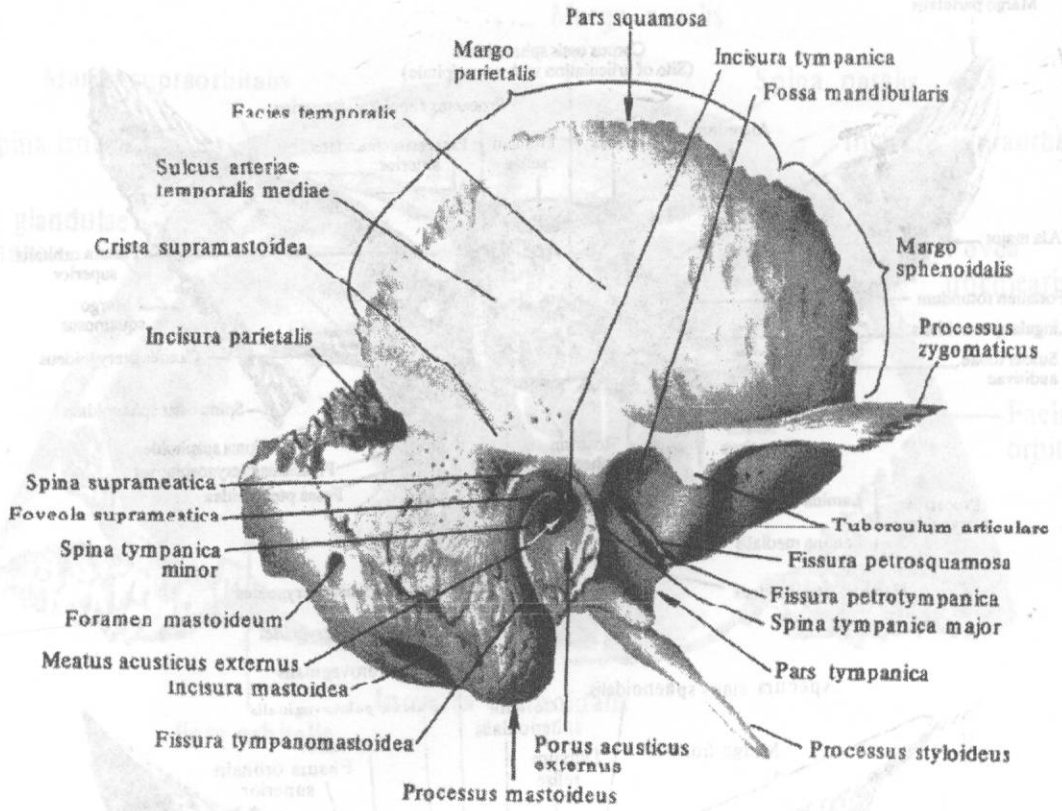


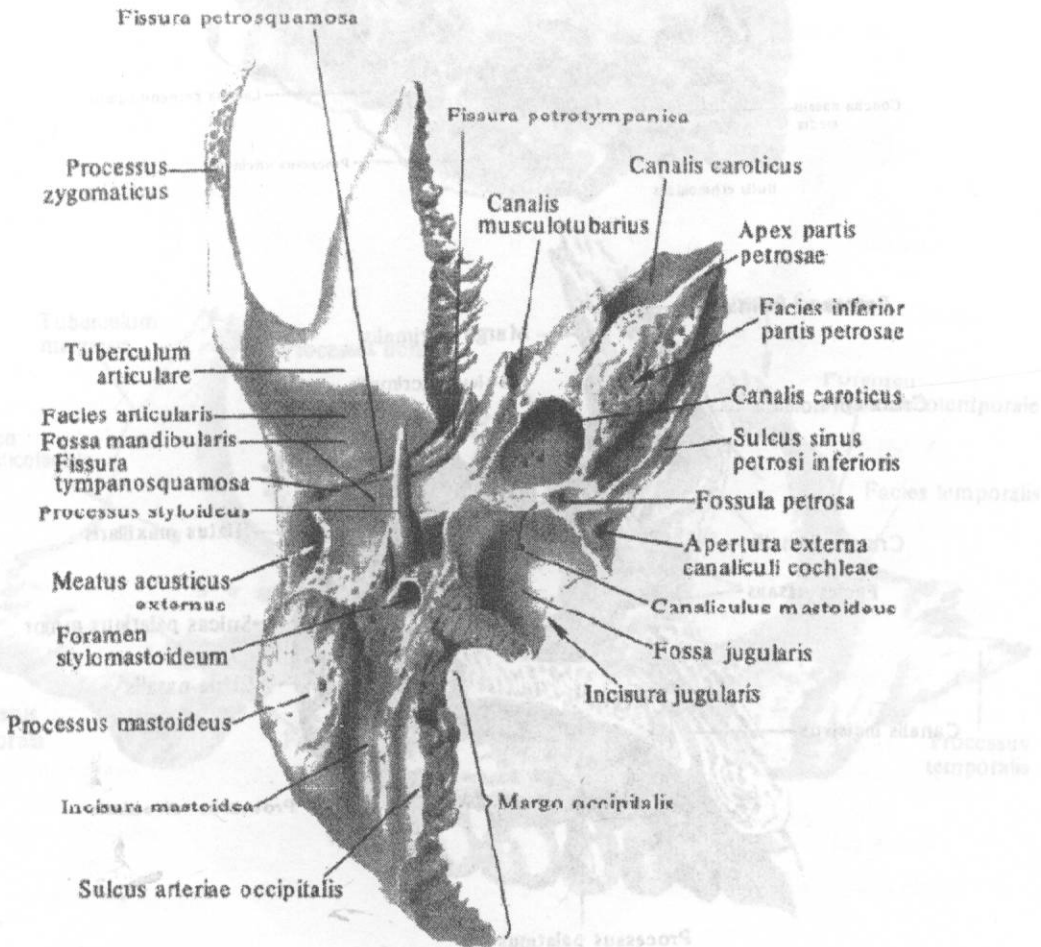
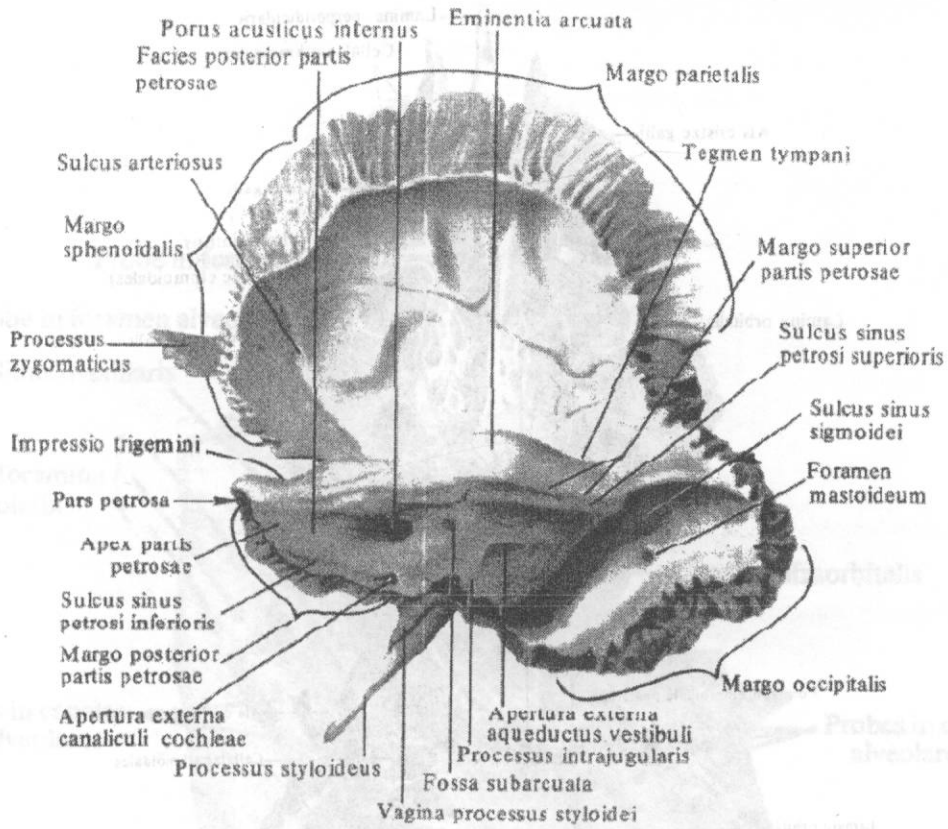


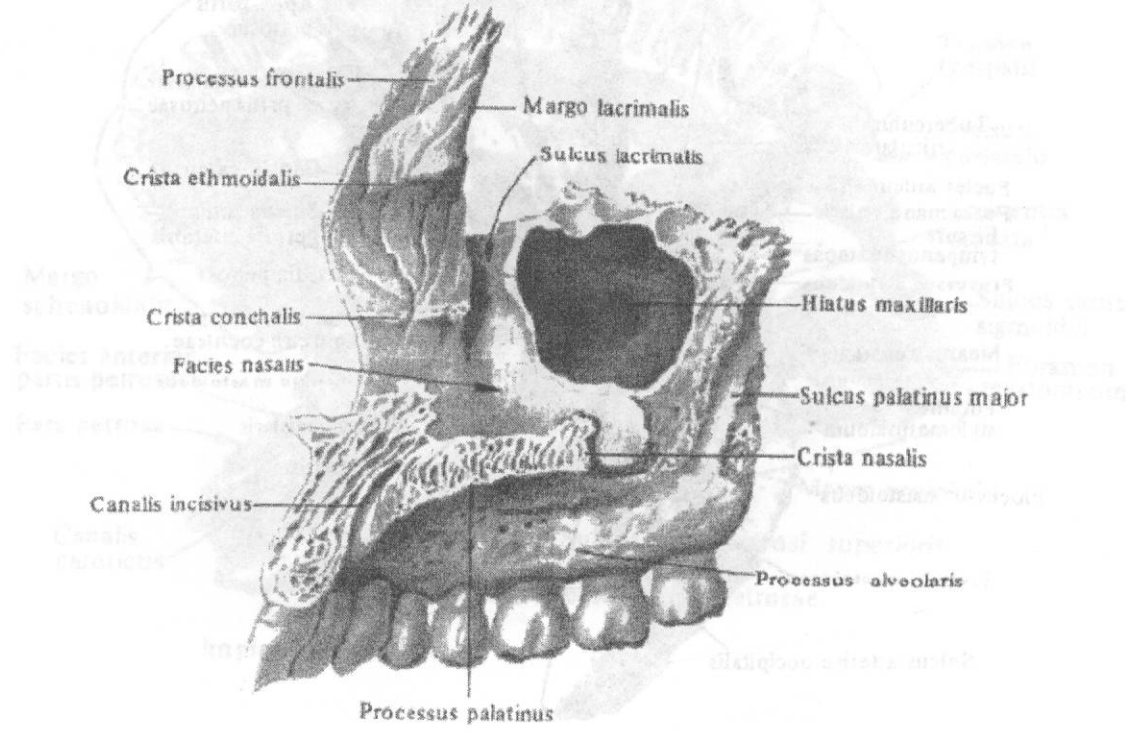
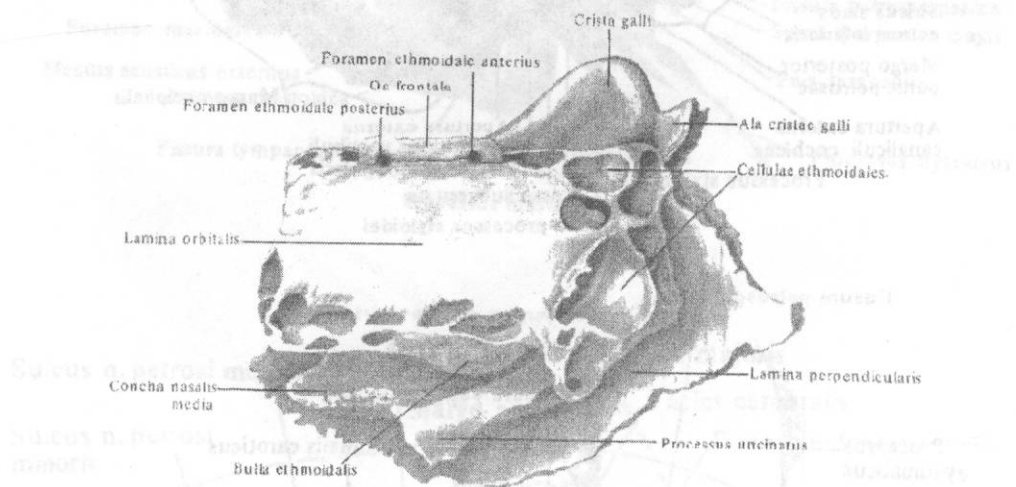
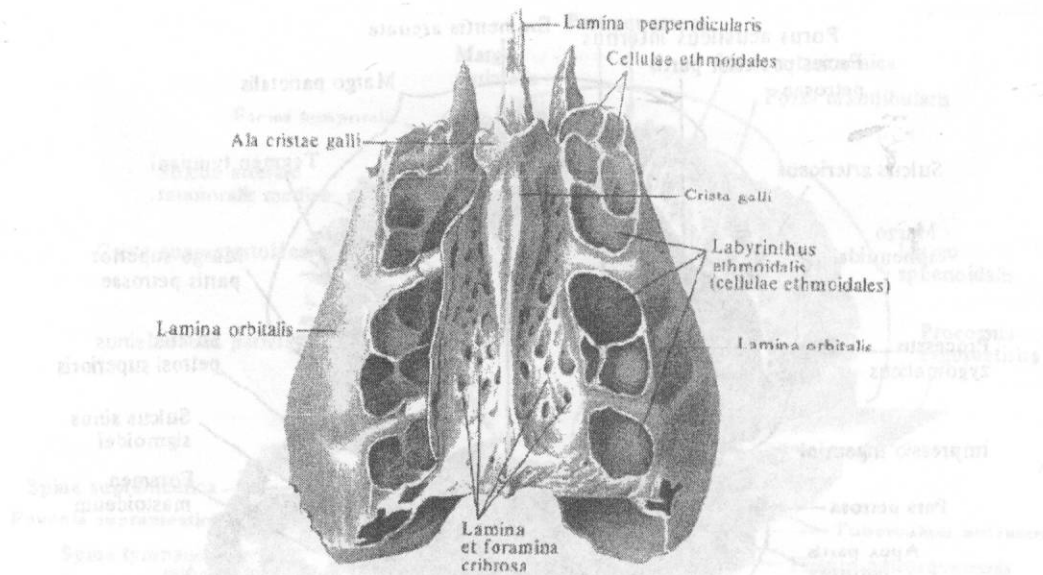


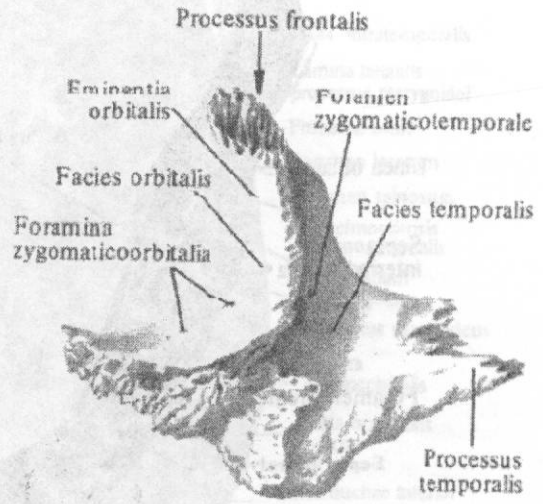
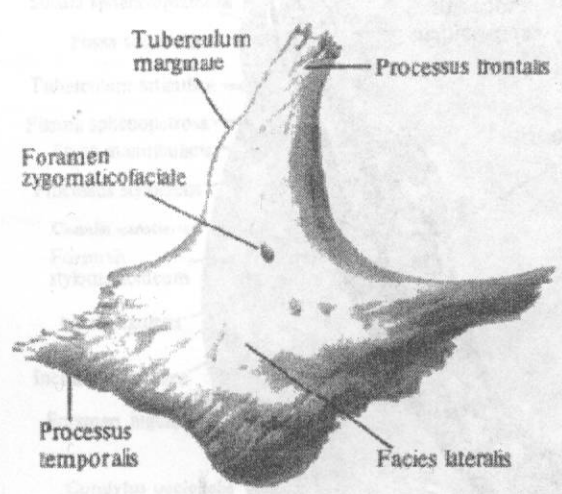
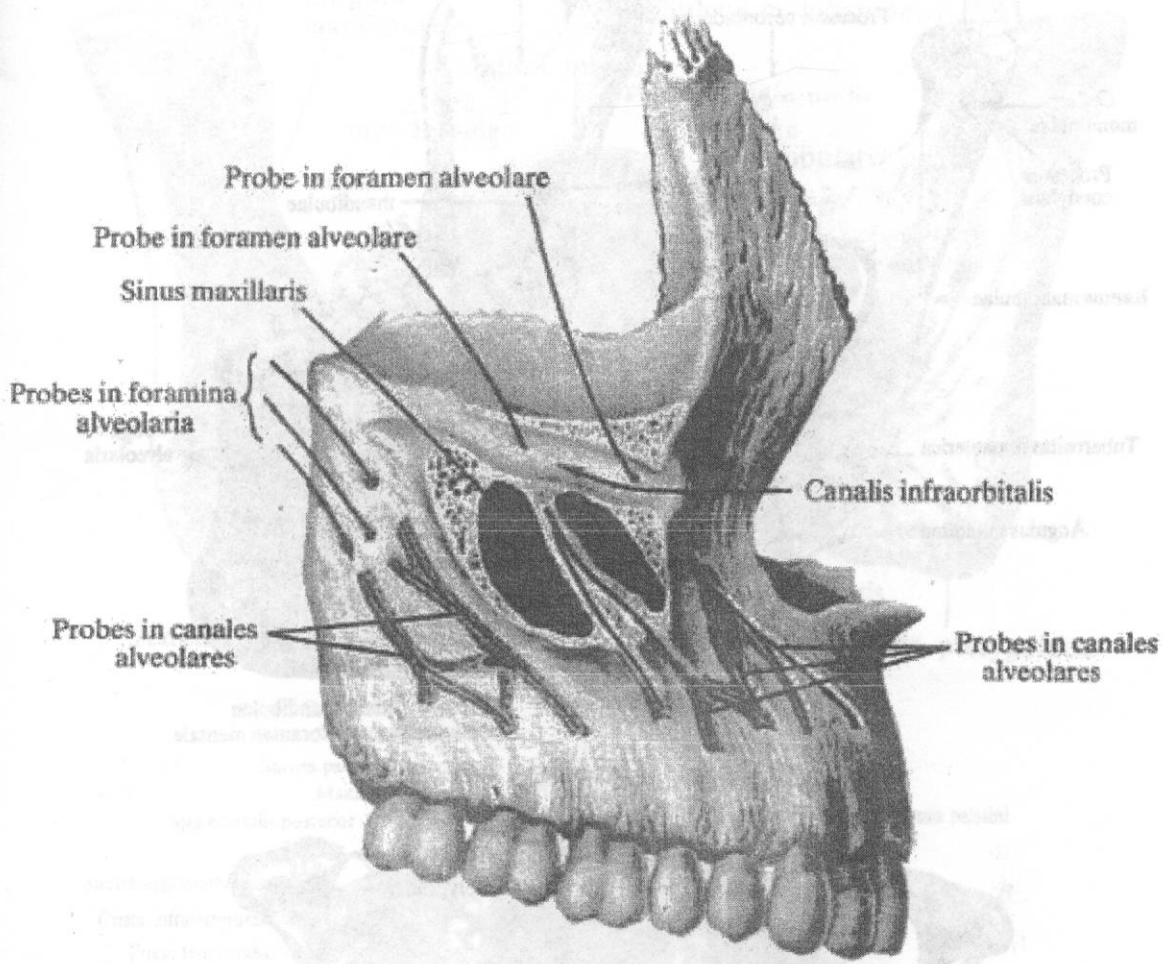


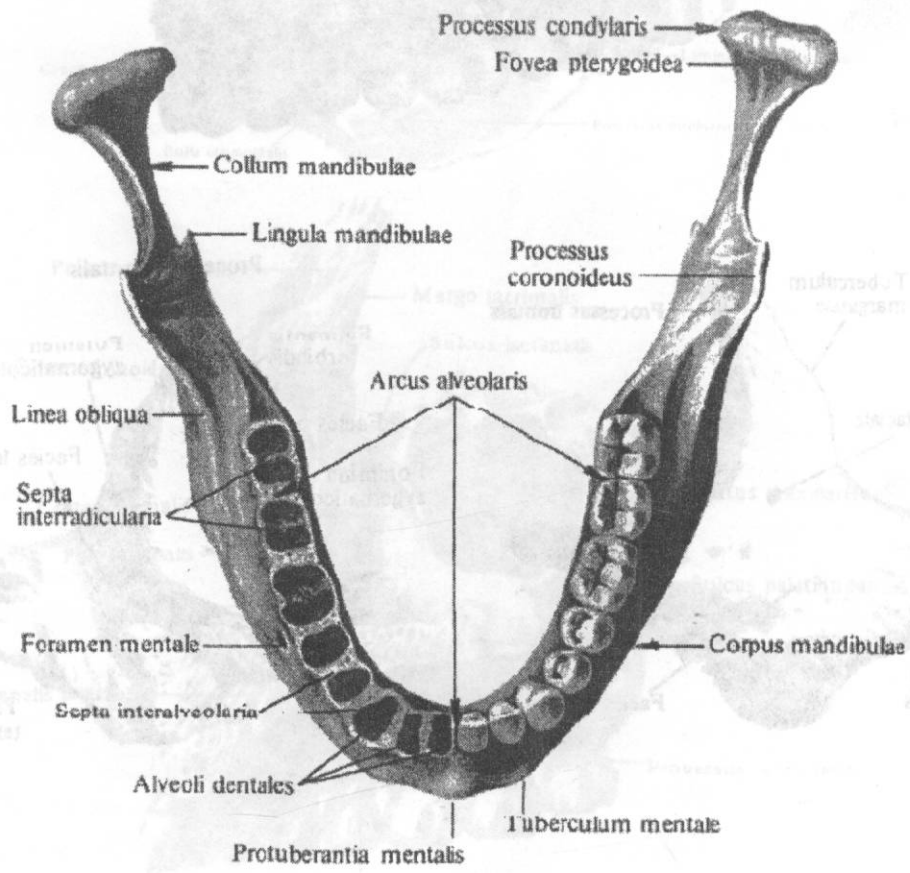
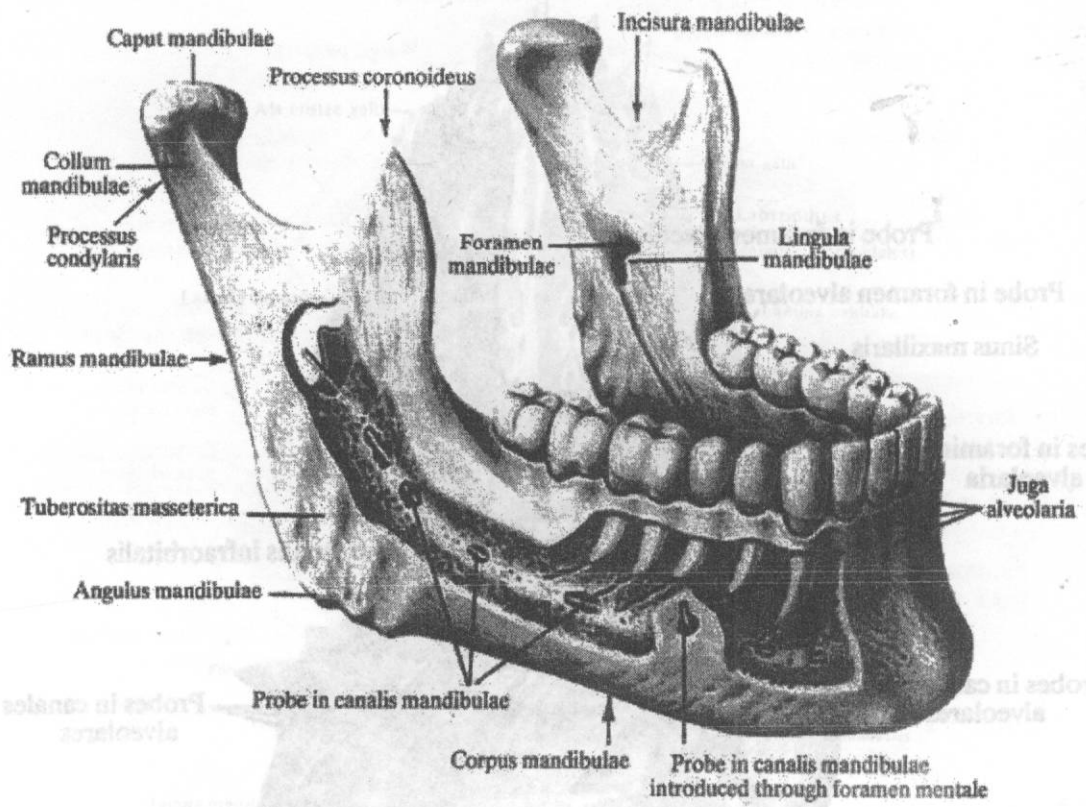


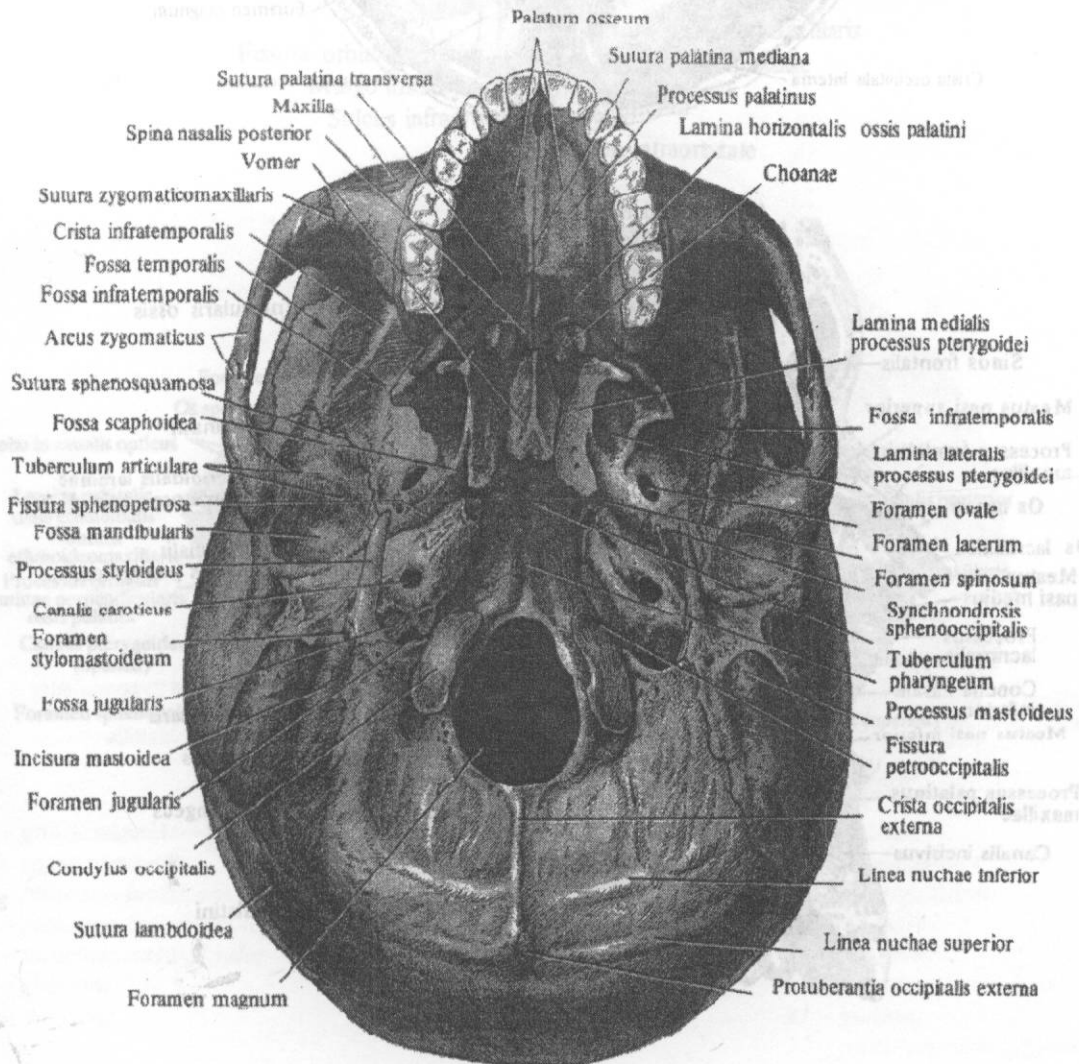
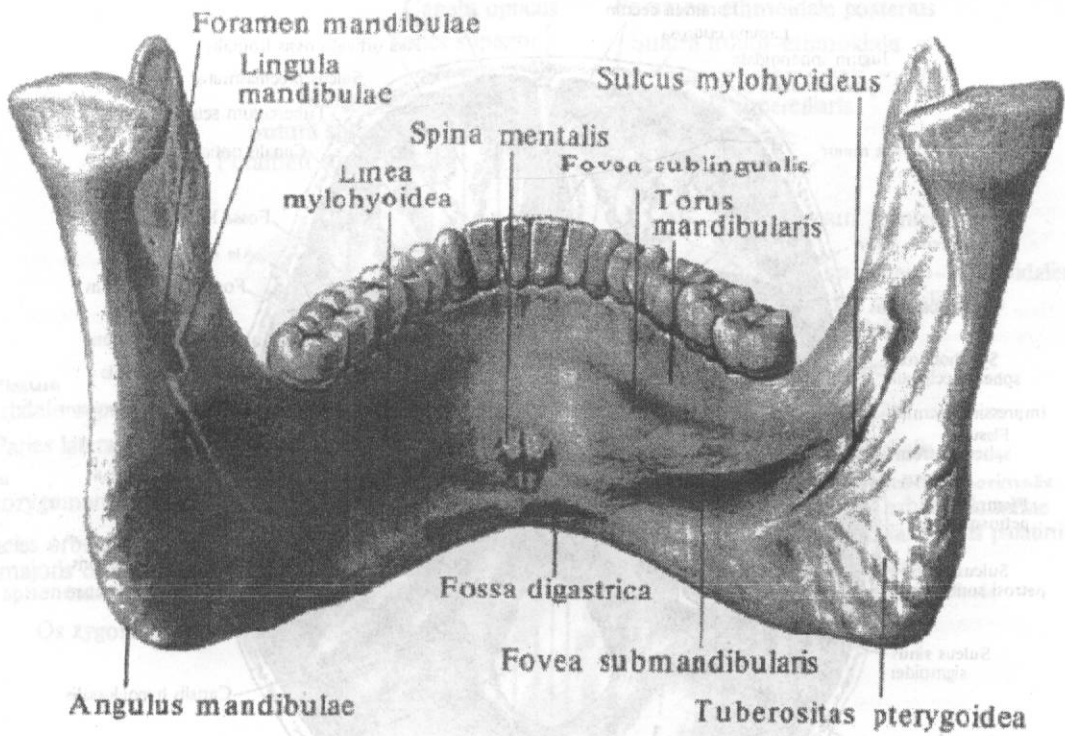


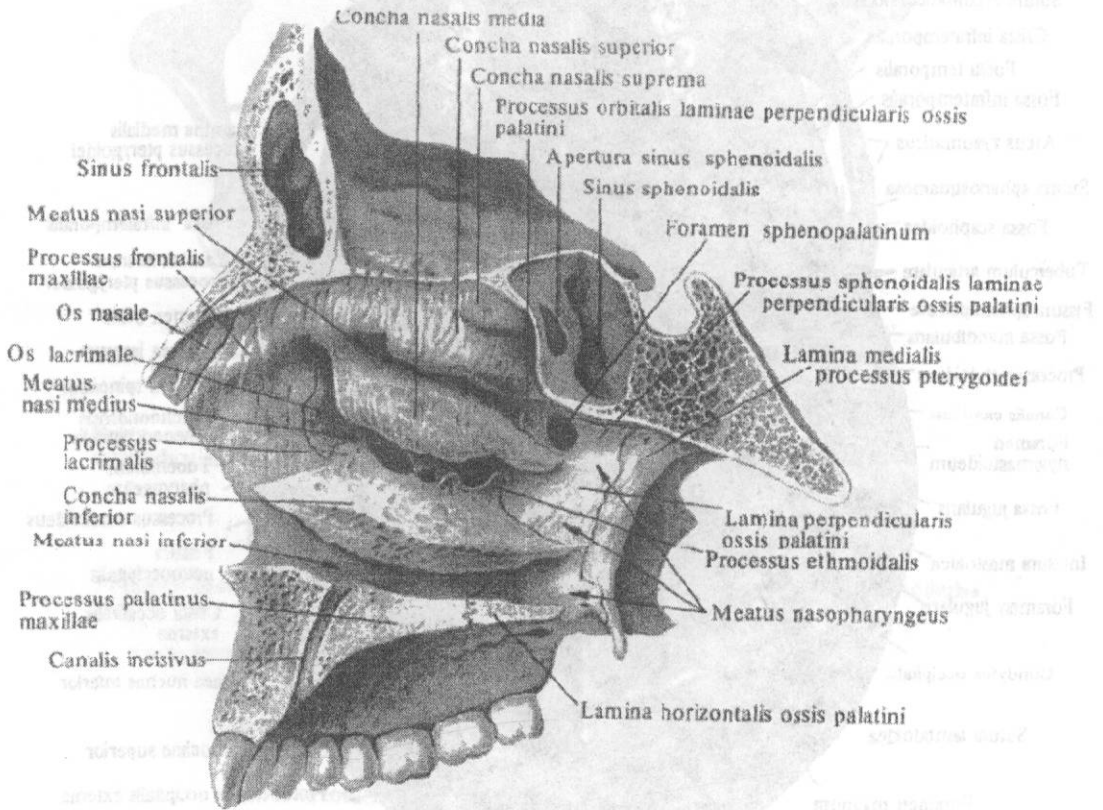
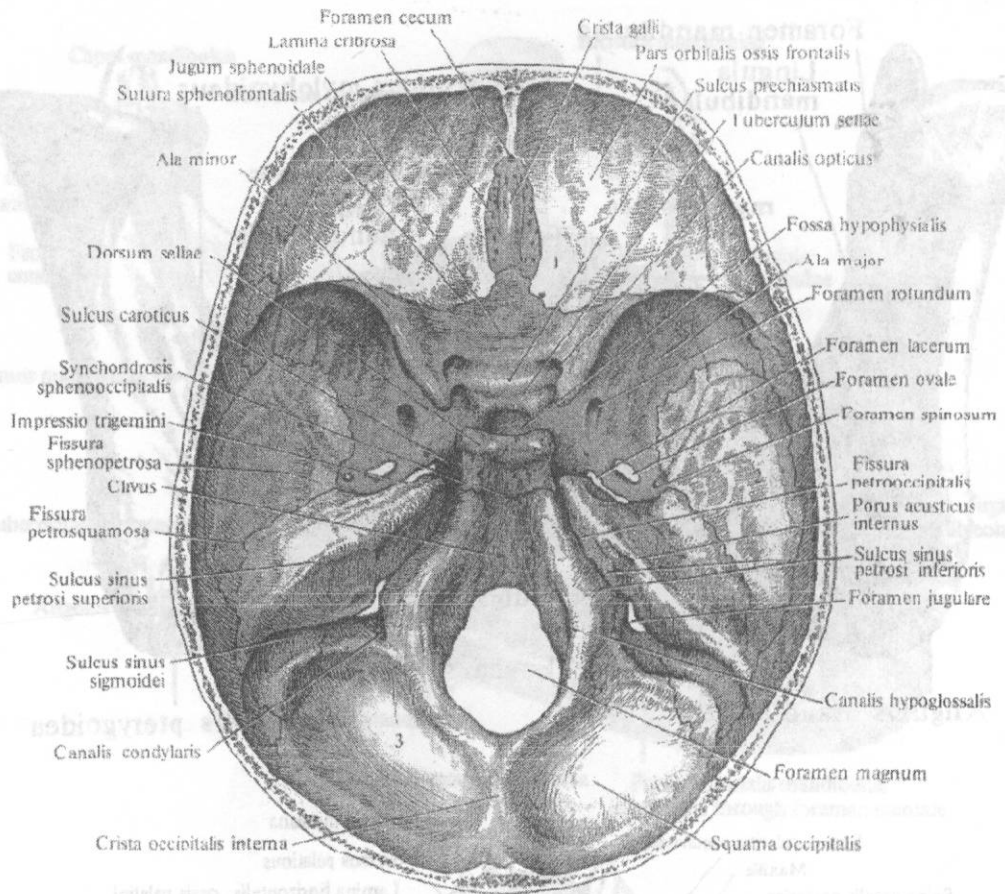


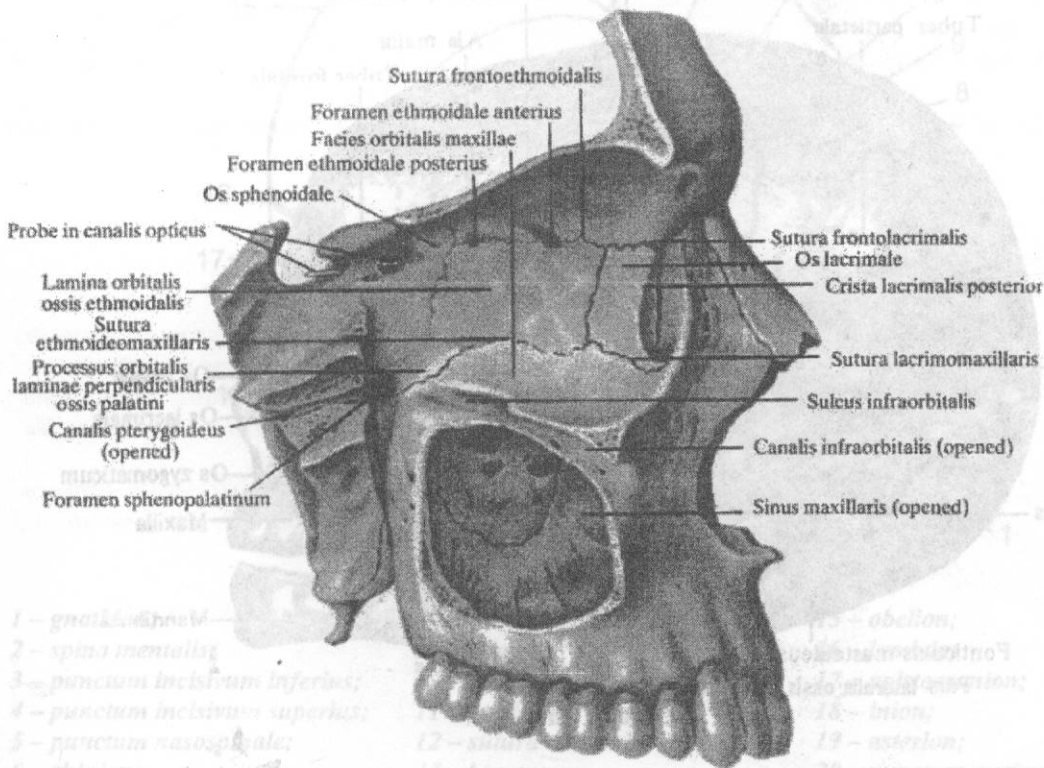
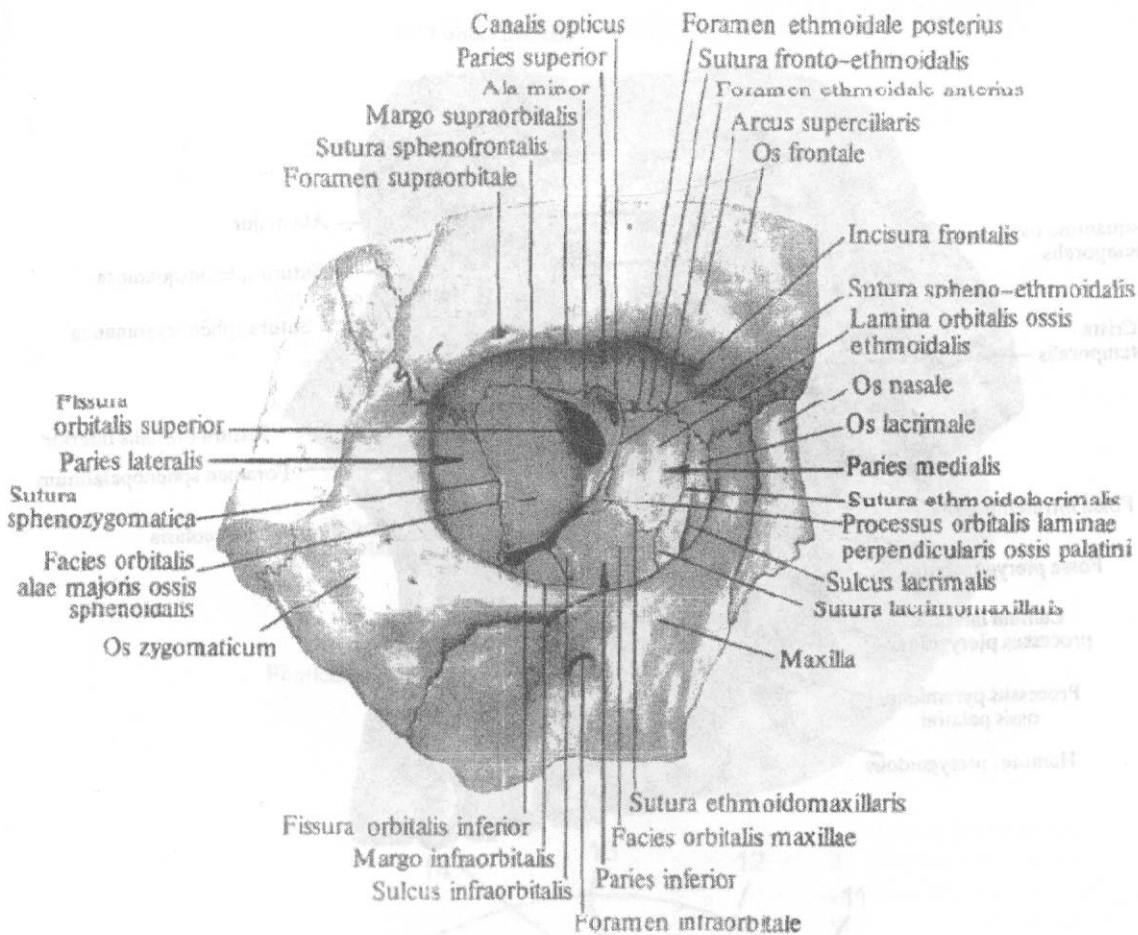












1 - gnathion;

2 - spina mentalis;

3 - punctum incisivum inferius;

4 - punctum incisivum superius;

5 - punctum nasospinale;

6 - rhinion;

7 - dakryon;

11 - supra-orbitale;

12 - supra-orbitale;

13 - bregma;

14 - sphenion;

15 - obellon;

16 - trion;

17 - asterion;

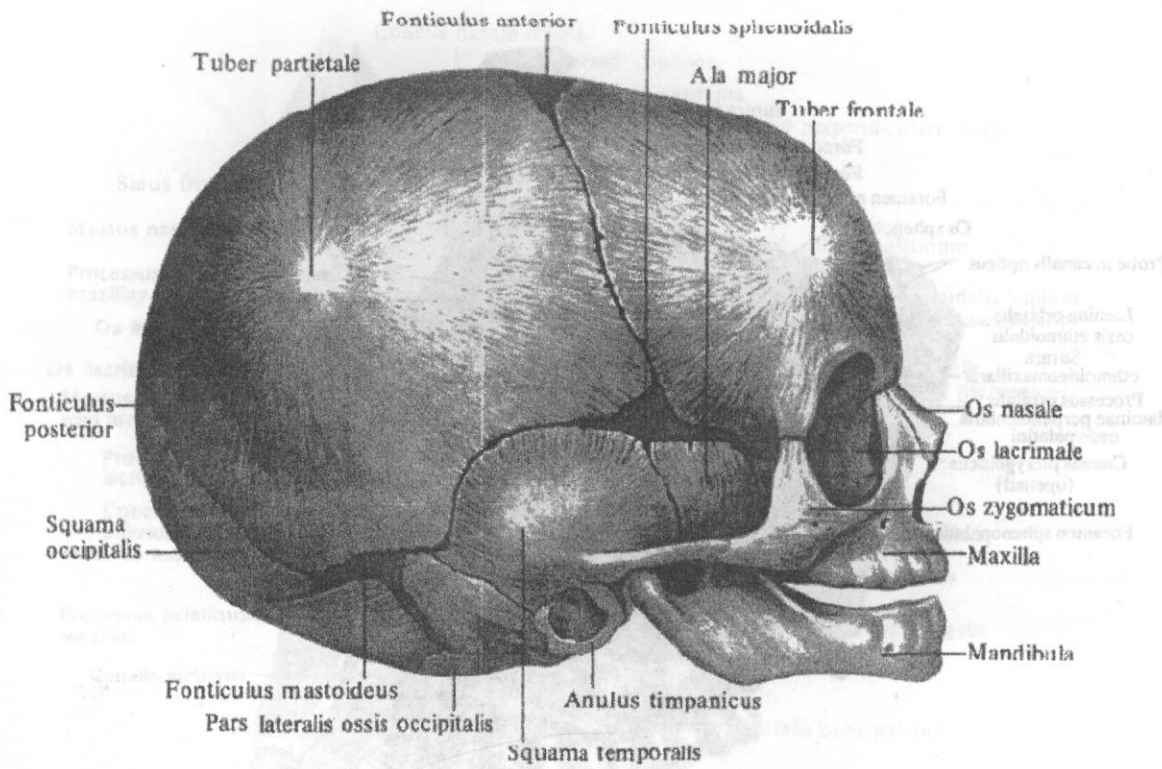
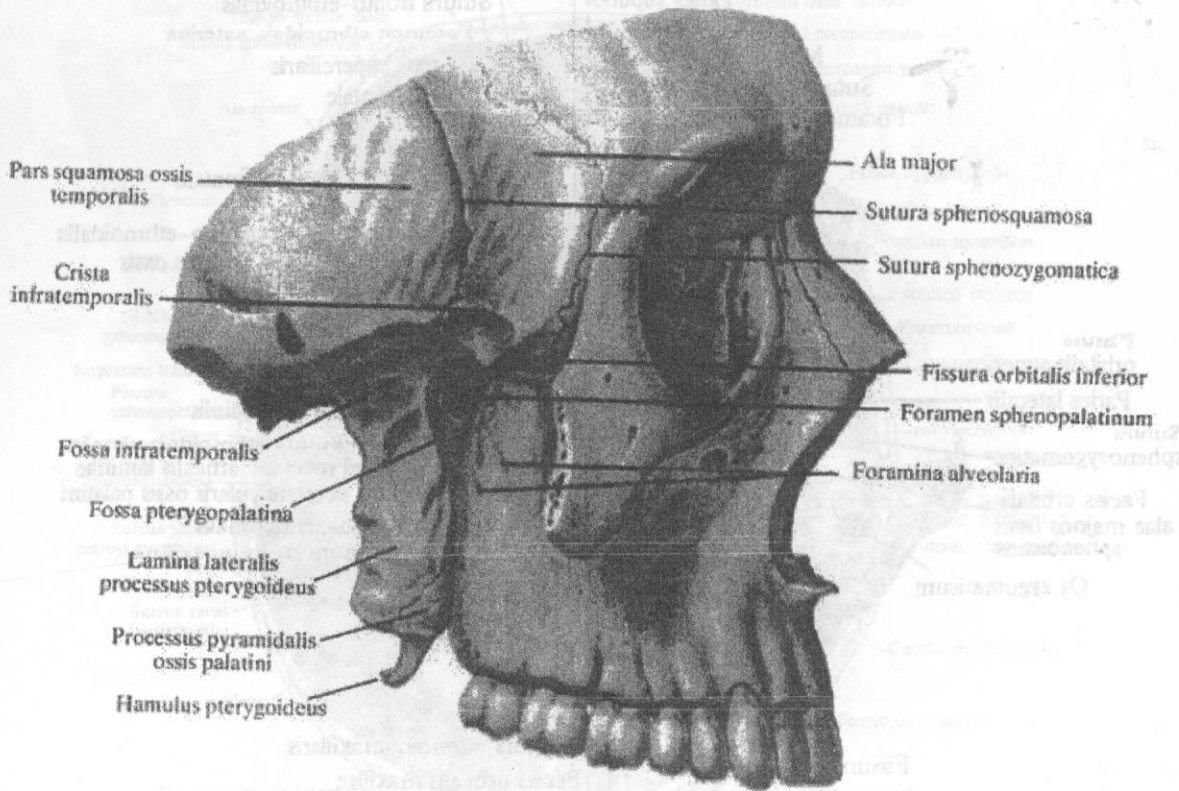
18 - punctum auriculare;

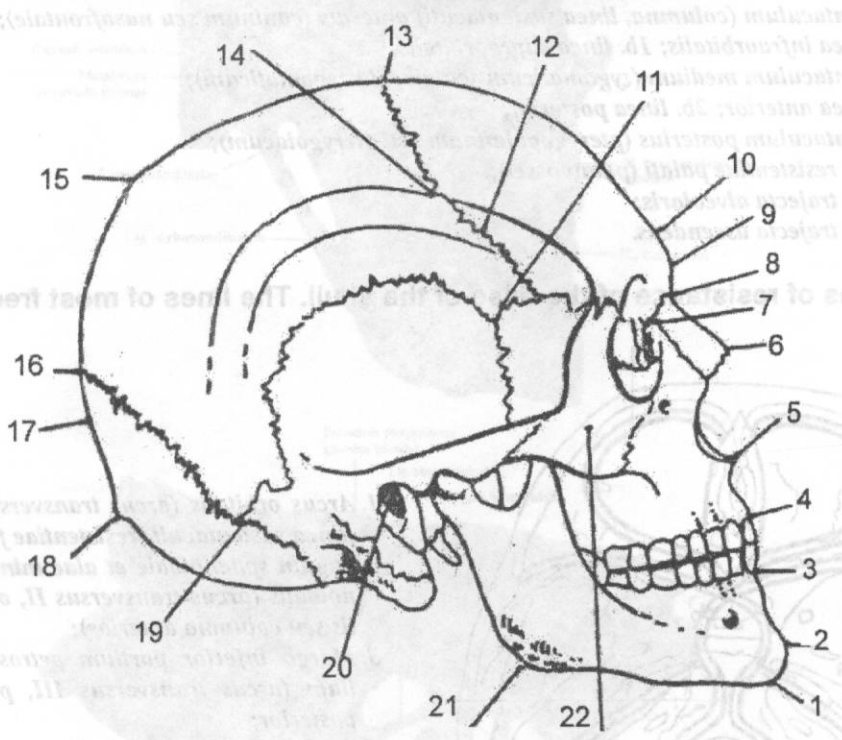
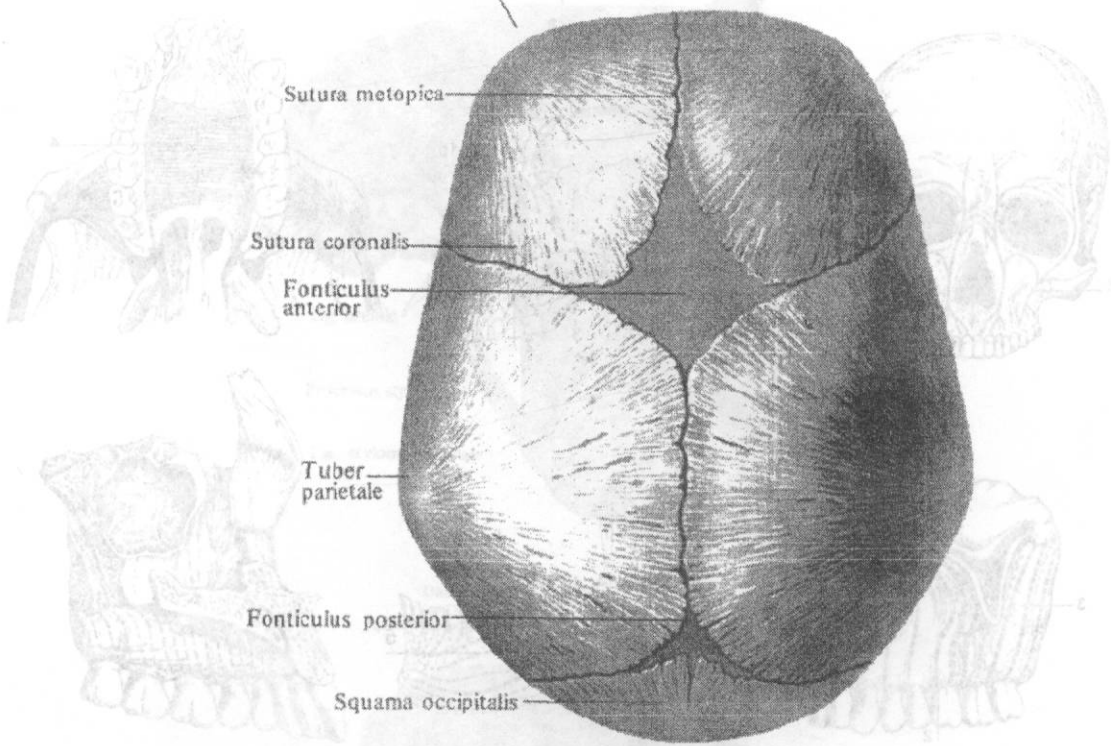
19 - gonion;

20 - punctum zygomaticum;

21 - gonion;

22 - punctum osis zygomatici.



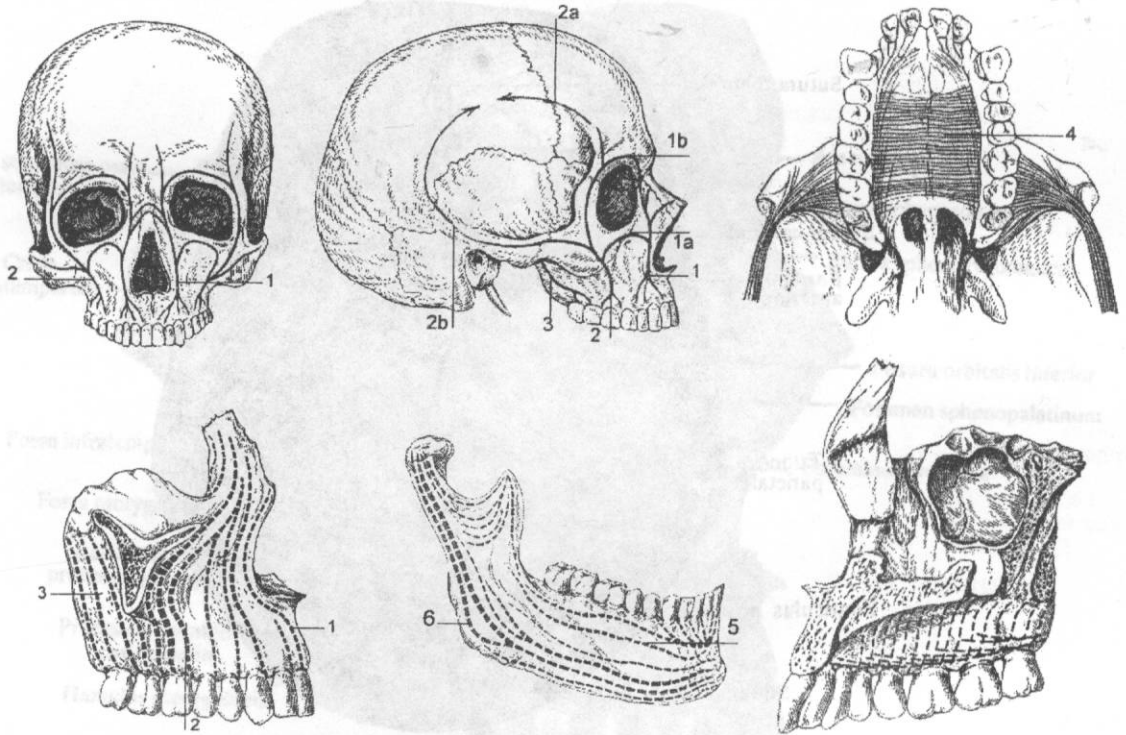


- 1 – gnathion;
- 2 – spina mentalis;
- 3 – punctum incisivum inferius;
- 4 – punctum incisivum superius;
- 5 – punctum nasospinale;
- 6 – rhinion;
- 7 – dakrion;

- 8 – nasion;
- 9 – glabella;
- 10 – ophrion;
- 11 – pterion;
- 12 – sutura coronalis;
- 13 – bregma;
- 14 – stephanion;

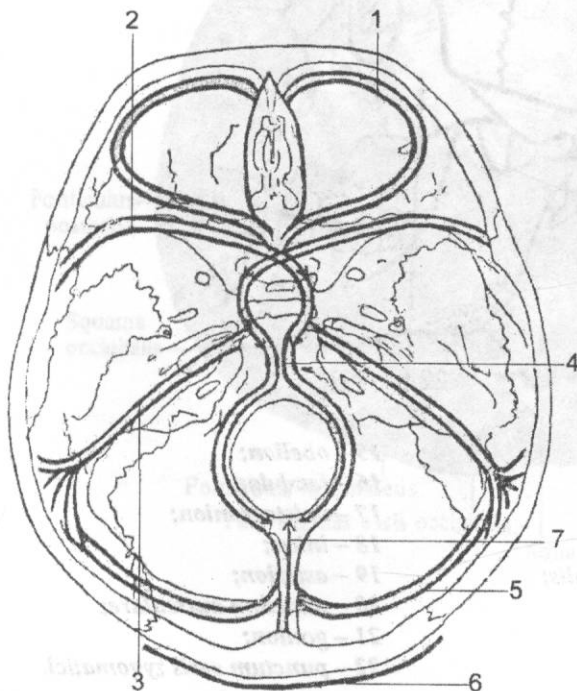
- 15 – obelion;
- 16 – lambda;
- 17 – opistocranium;
- 18 – inion;
- 19 – asterion;
- 20 – punctum auriculare;
- 21 – gonion;
- 22 – punctum ossis zygomatici.

Presistance of pillars of the visceral cranium

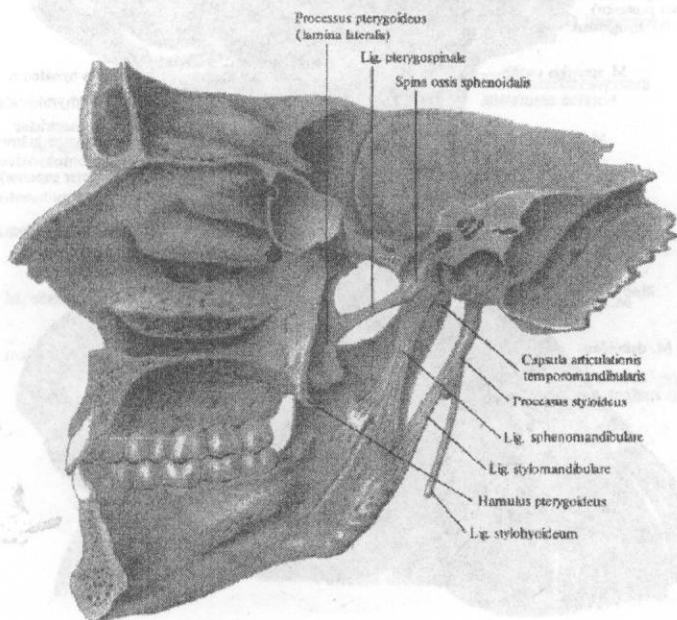
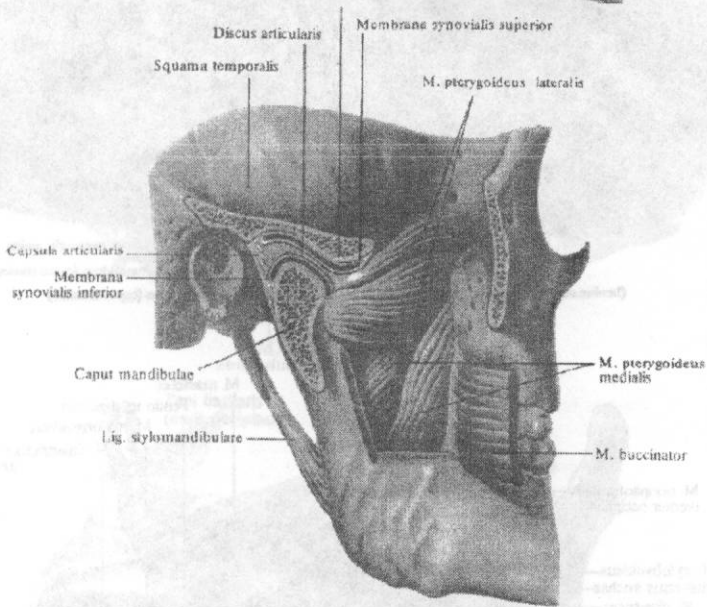
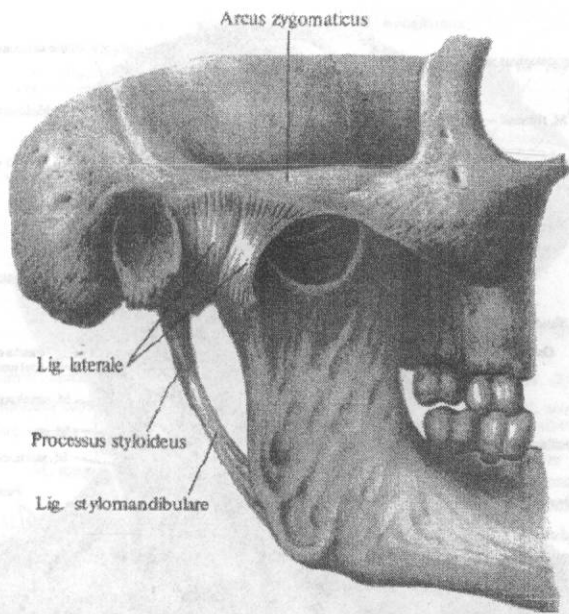


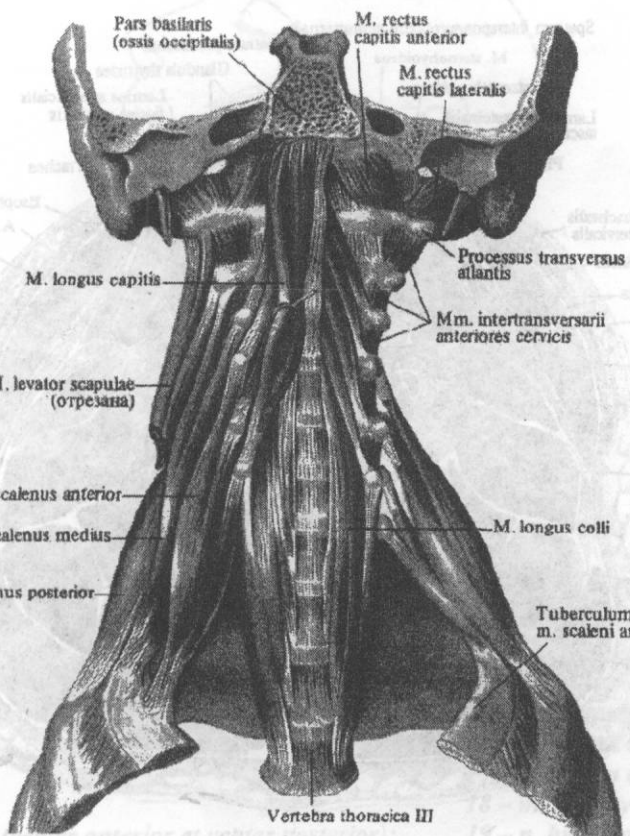
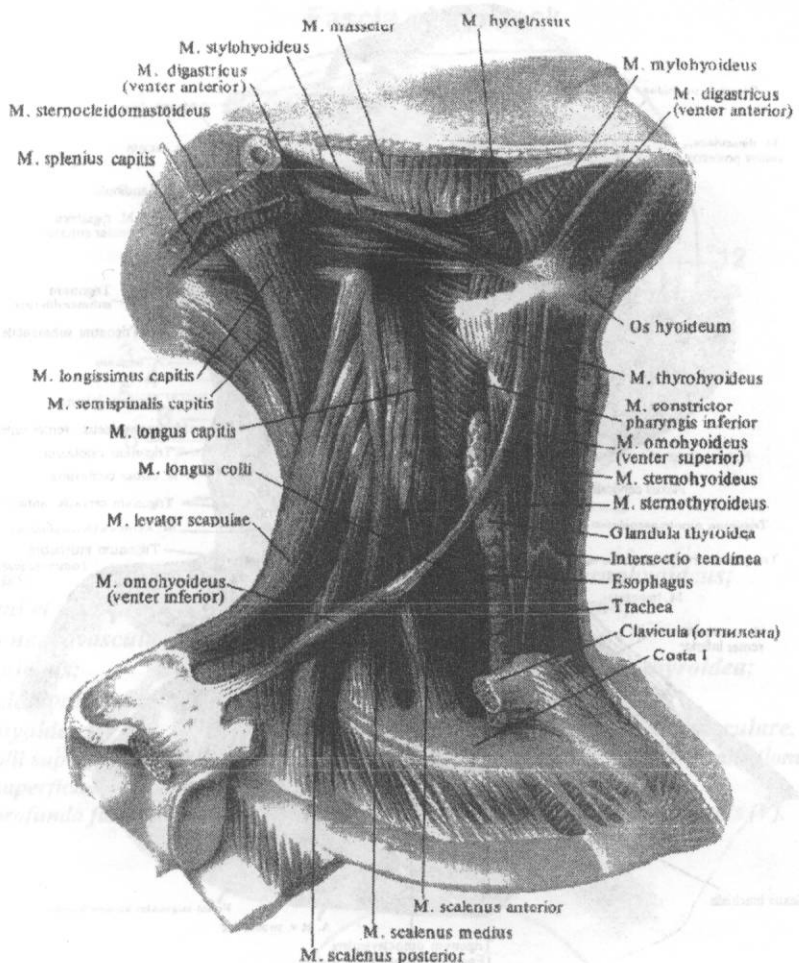
1. *Sustentaculum (columna, linea sustentaculi) anterius (caninum seu nasofrontale);*
1a. *linea infraorbitalis; 1b. linea supraorbitalis;*
2. *Sustentaculum medium (zygomaticum seu alveolo-zygomaticum);*
2a. *linea anterior; 2b. linea posterior;*
3. *Sustentaculum posterius (pterygopalatinum seu pterygoideum);*
4. *Linea resistentiae palati (palati ossei);*
5. *Linea trajecta alveolaris;*
6. *Linea trajecta ascendens.*

Structures of resistance of the base of the skull. The lines of most frequent fractures



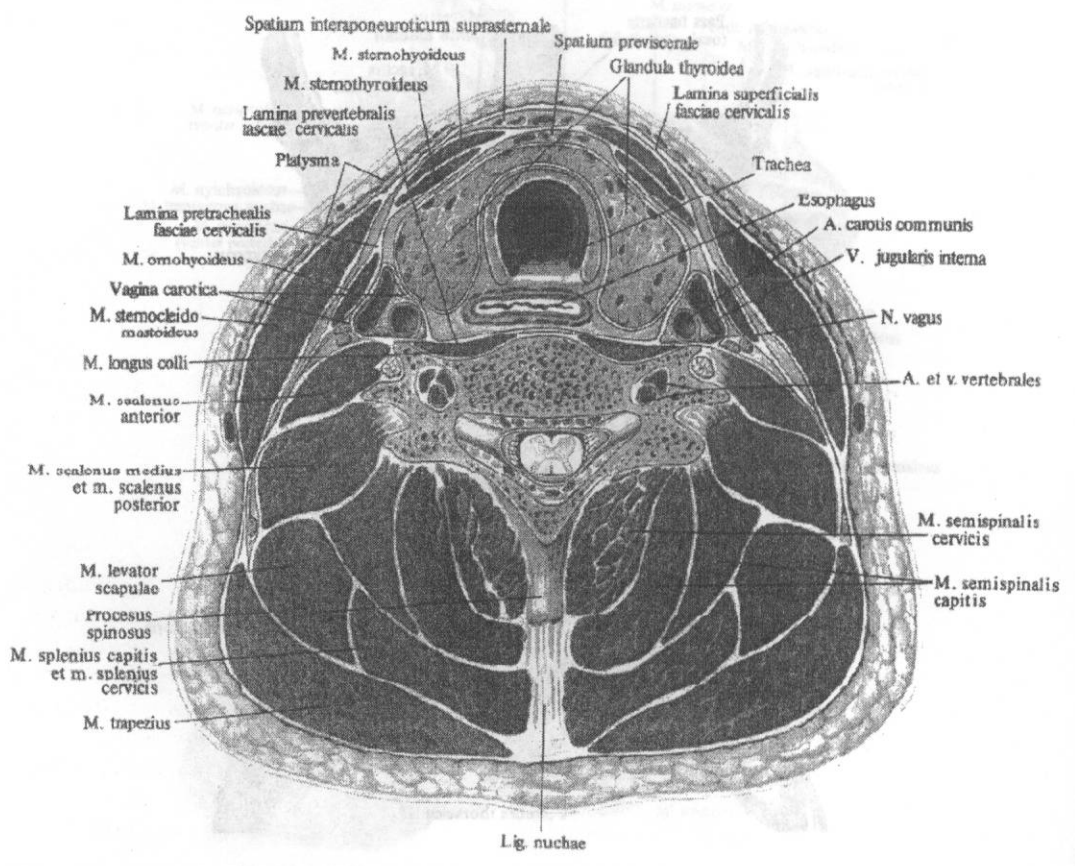
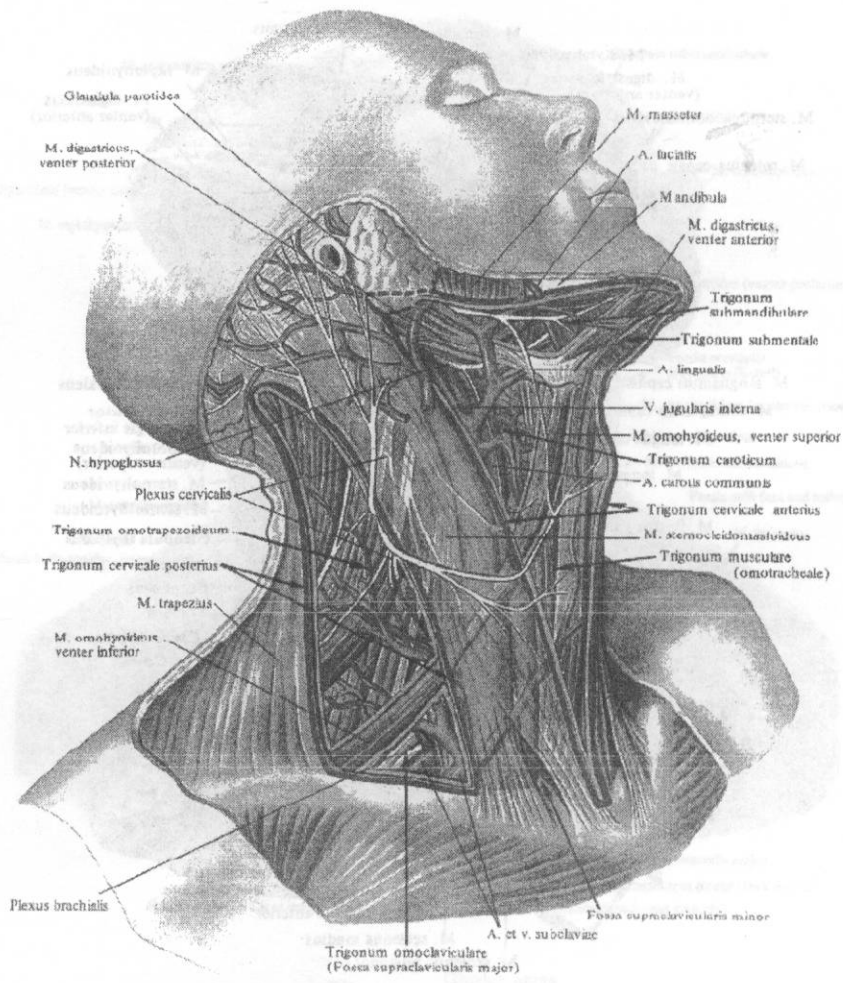
1. *Arcus orbitalis (arcus transversus I) (frontalis) [linea sustentaculi (resistentiae frontalis)];*
2. *Jugum sphenoidale et alae minores ossis sphenoidalis (arcus transversus II, orbitosphenoidalis seu columna anterior);*
3. *Margo inferior partium petrosarum temporarium (arcus transversus III, petromastoideus) posterior;*
4. *Basis ossea mediosagittalis;*
5. *Sinus transversus (arcus transversus IV);*
6. *Linea resistentiae occipitalis.*



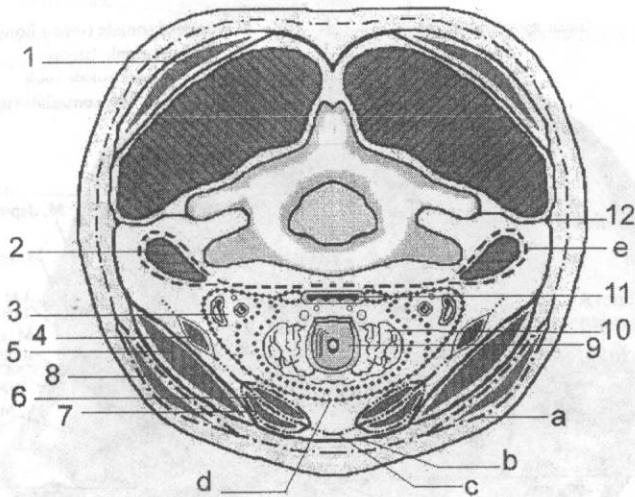


- 1 - m. trapezius
- 2 - m. sternocleidomastoideus
- 3 - m. omohyoideus
- 4 - fossa jugularis
- 5 - fossa suprascapularis
- 6 - fossa jugularis
- 7 - m. omohyoideus
- 8 - os hyoideum
- 9, 10 - m. digastricus (venter anterior et venter posterior)

19 - n. hypoglossus (XII).



Fascia of the neck



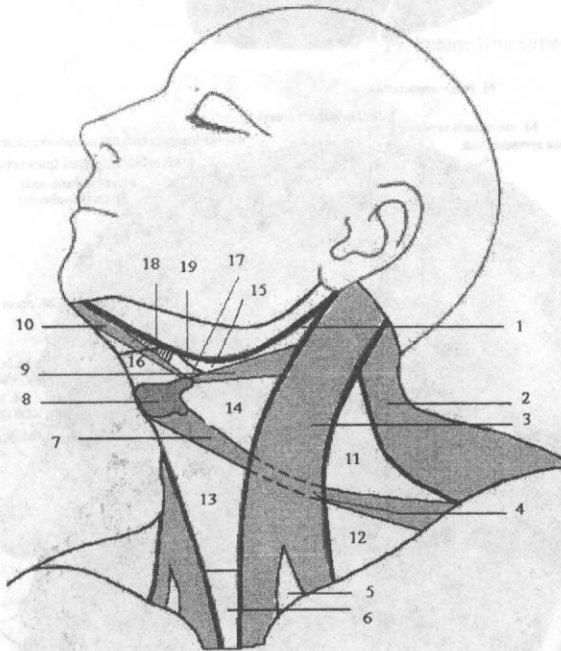
- 1 – *m. trapezius*;
 2 – *mm. scaleni et mm. prevertebrales*;
 3 – *fasciculus neurovascularis*;
 4 – *m. omohyoideus*;
 5 – *m. sternocleidomastoideus*;
 6 – *m. thyreochoideus*;

a – *fascia colli superficialis (I)*;
 b – *lamina superficialis fasciae colli propriae (III)*;
 c – *lamina profunda fasciae colli propriae (III)*;

- 7 – *m. sternohyoideus*;
 8 – *platysma*;
 9 – *larynx*;
 10 – *glandula thyroidea*;
 11 – *oesophagus*;
 12 – *septum intermusculare*.

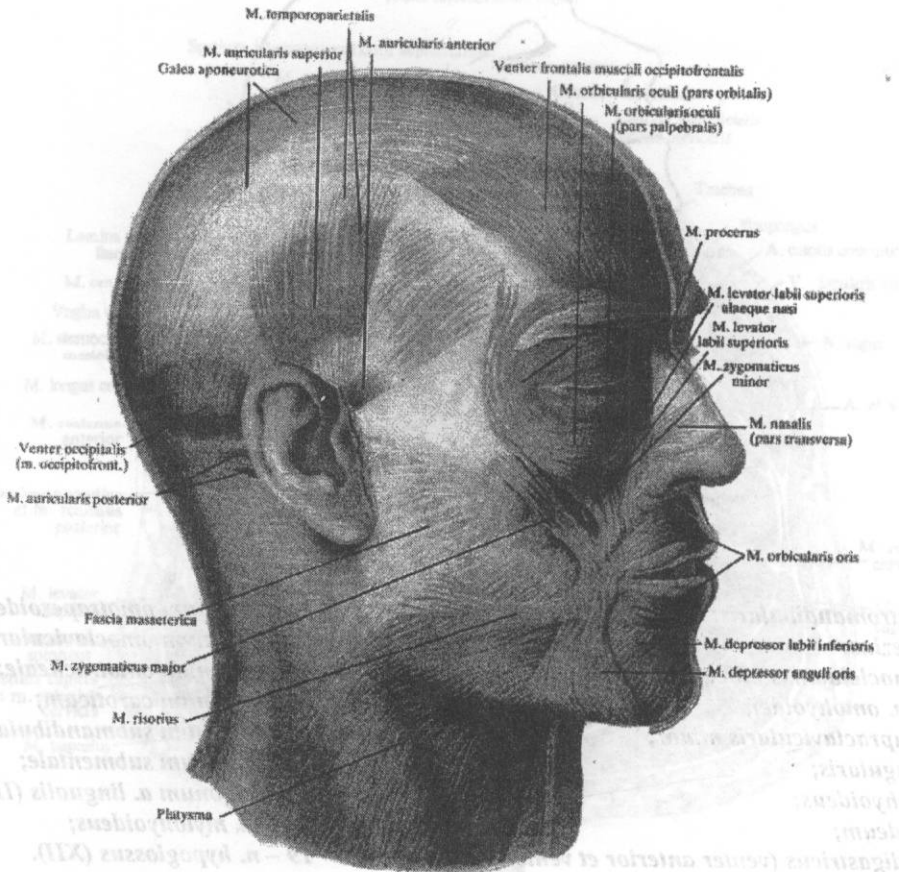
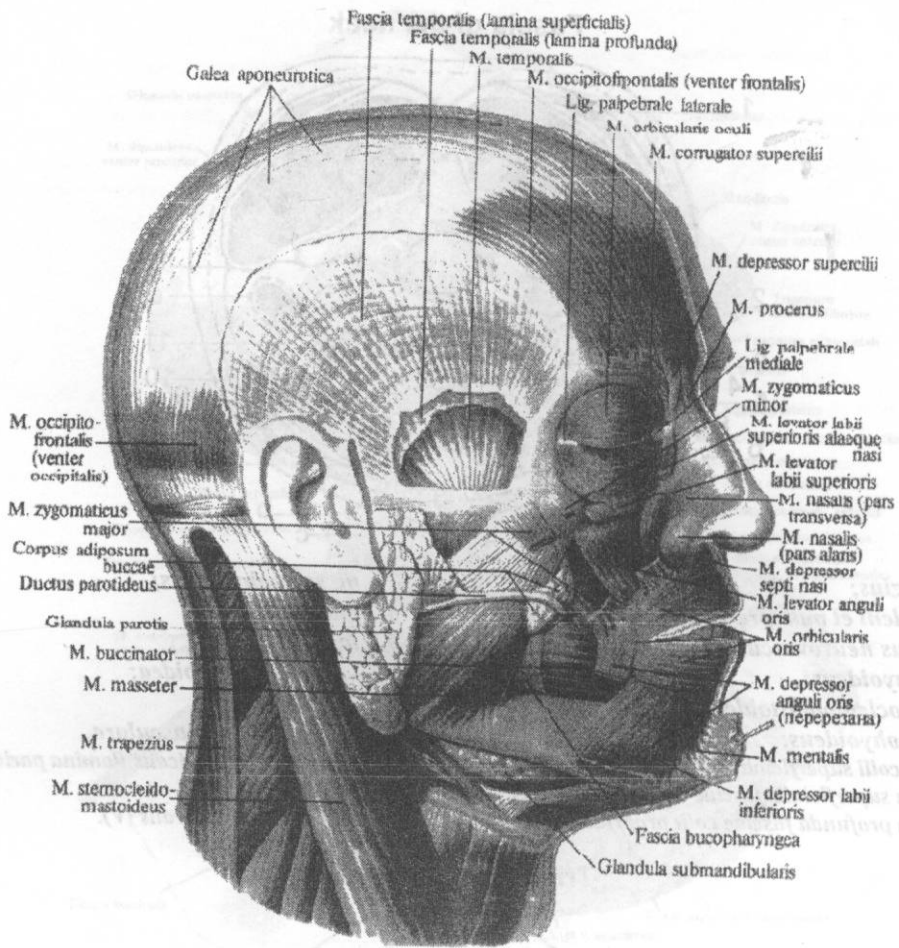
d – *fascia endocervicalis (lamina parietalis et visceralis) (IV)*;
 e – *fascia prevertebralis (V)*.

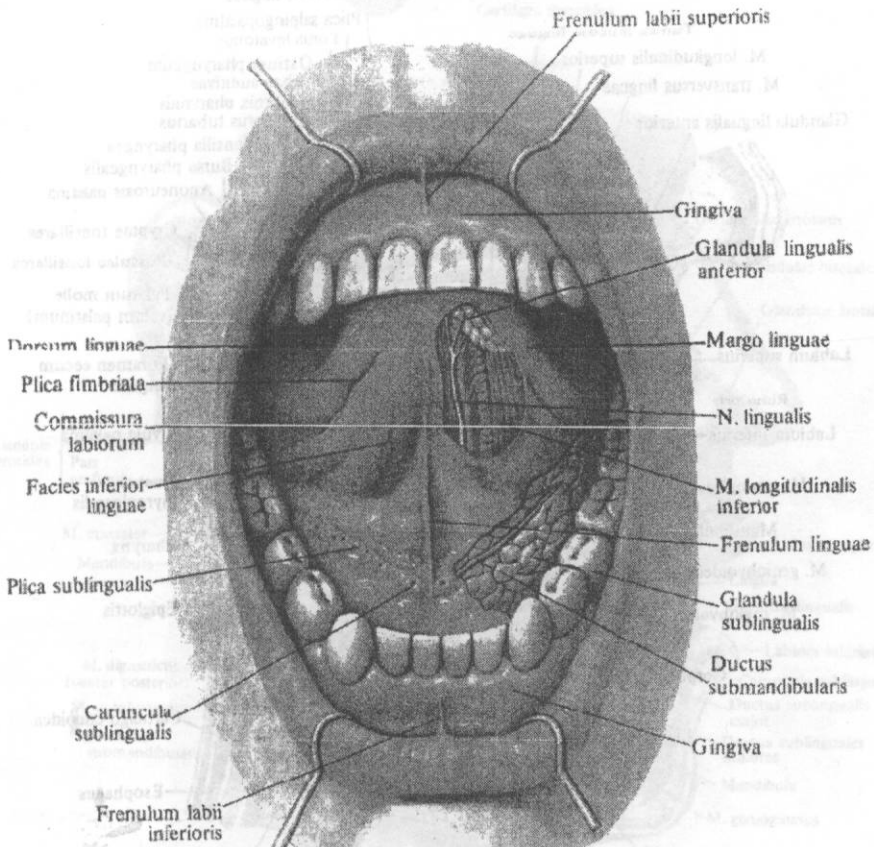
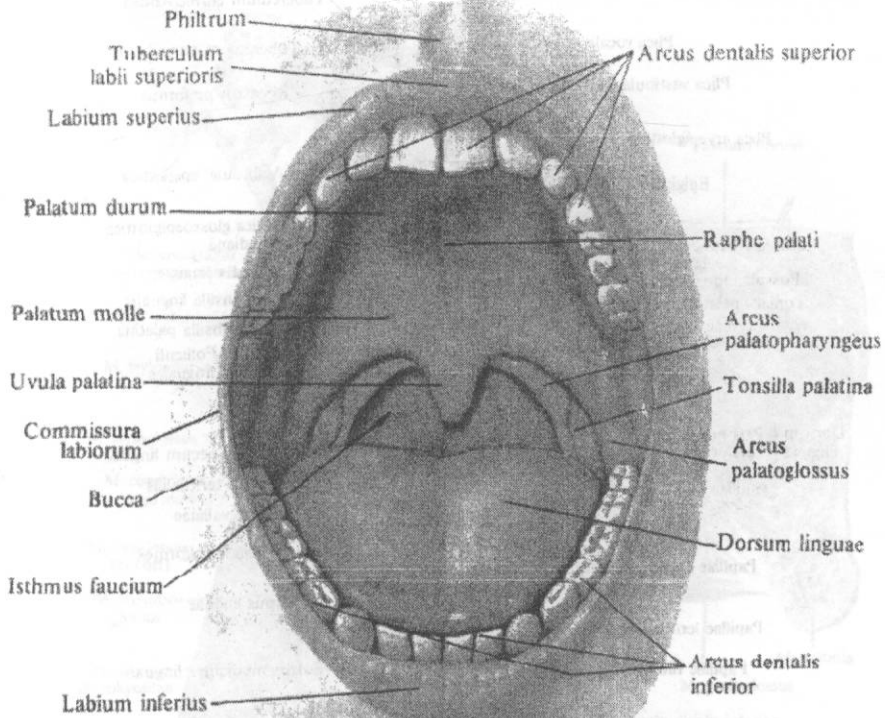
Triangles of the neck

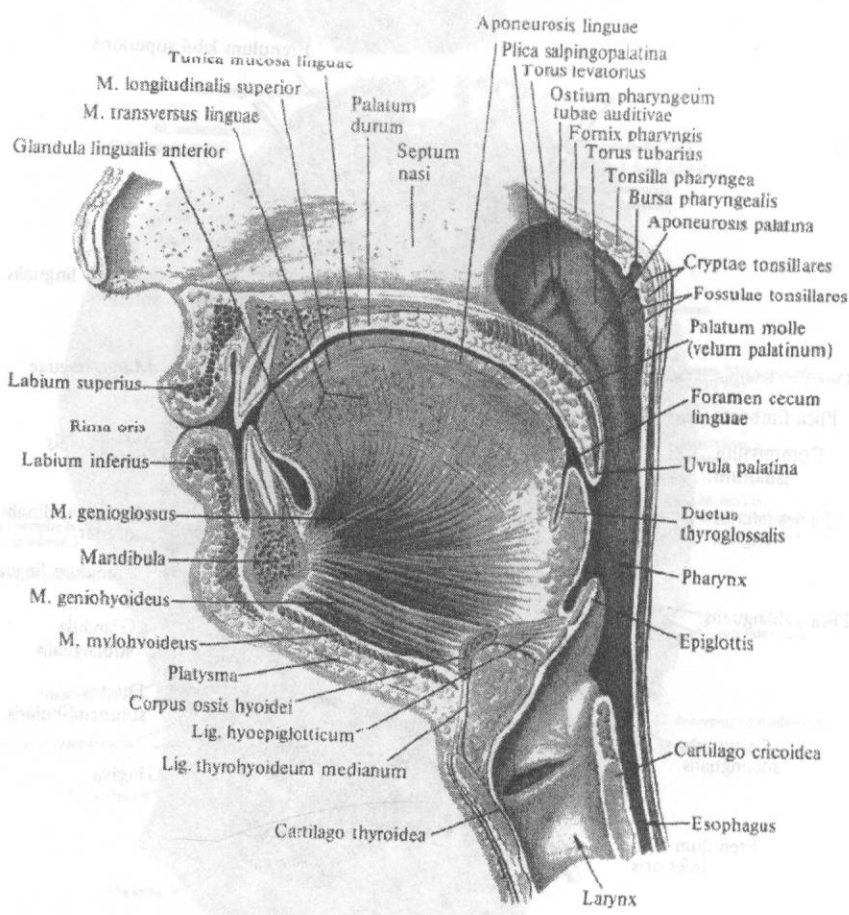
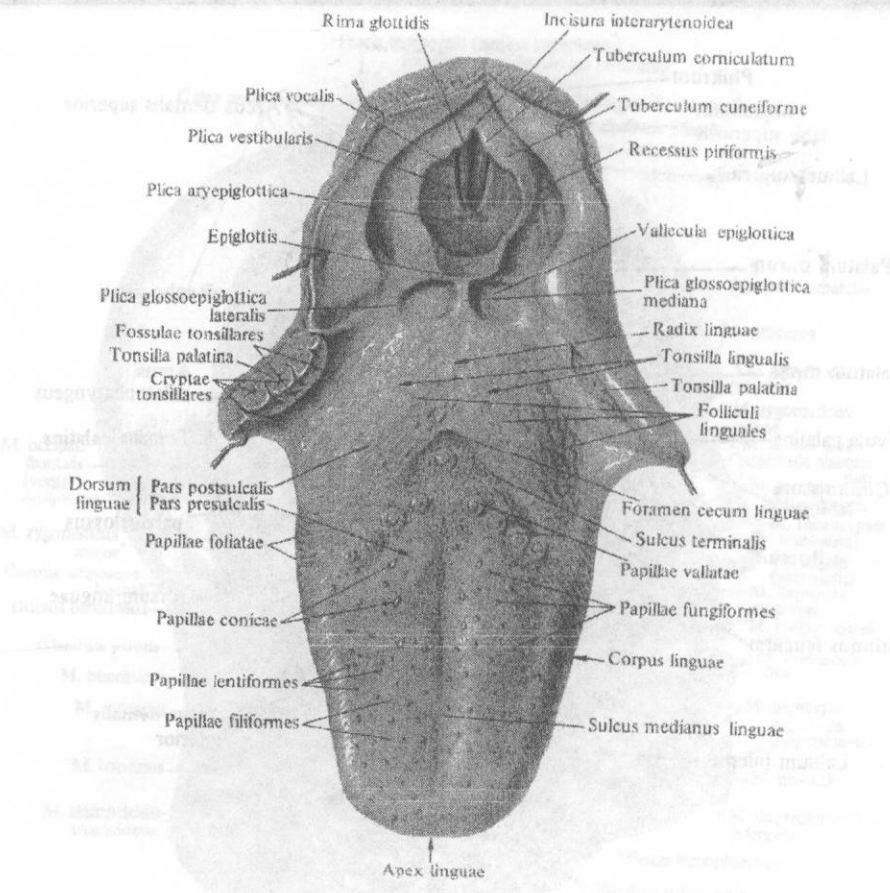


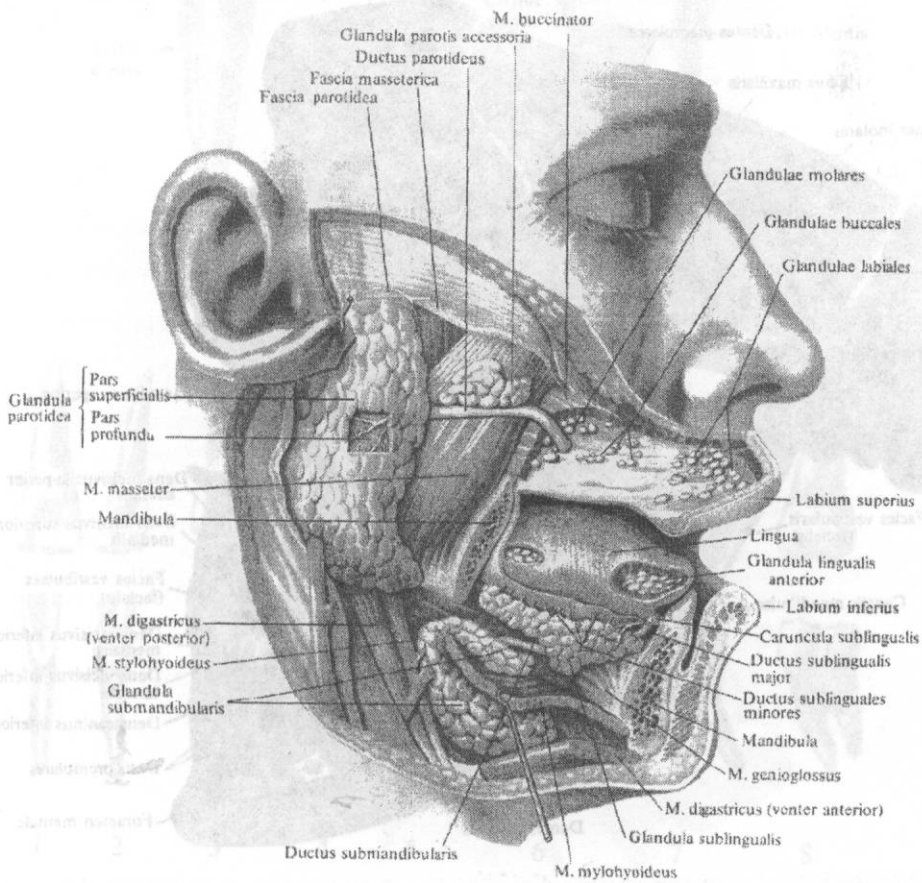
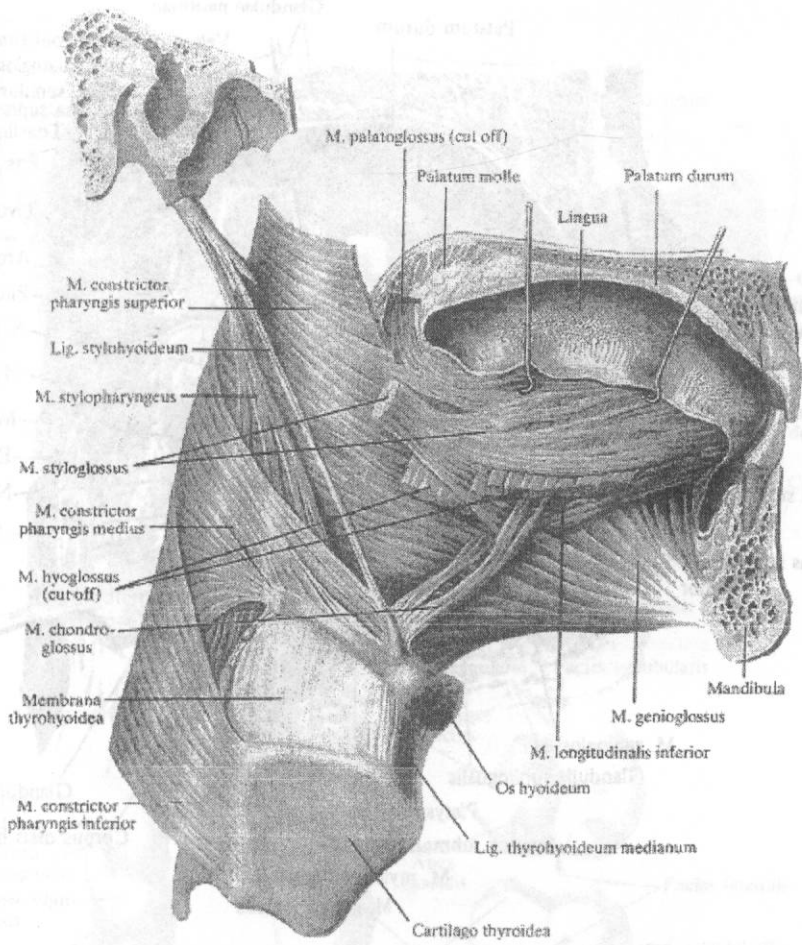
- 1 – *fossa retromandibularis*;
 2 – *m. trapezius*;
 3 – *m. sternocleidomastoideus*;
 4 – *tendo m. omohyoidei*;
 5 – *fossa supraclavicularis minor*;
 6 – *fossa jugularis*;
 7 – *m. omohyoideus*;
 8 – *os hyoideum*;
 9, 10 – *m. digastricus (venter anterior et venter posterior)*;

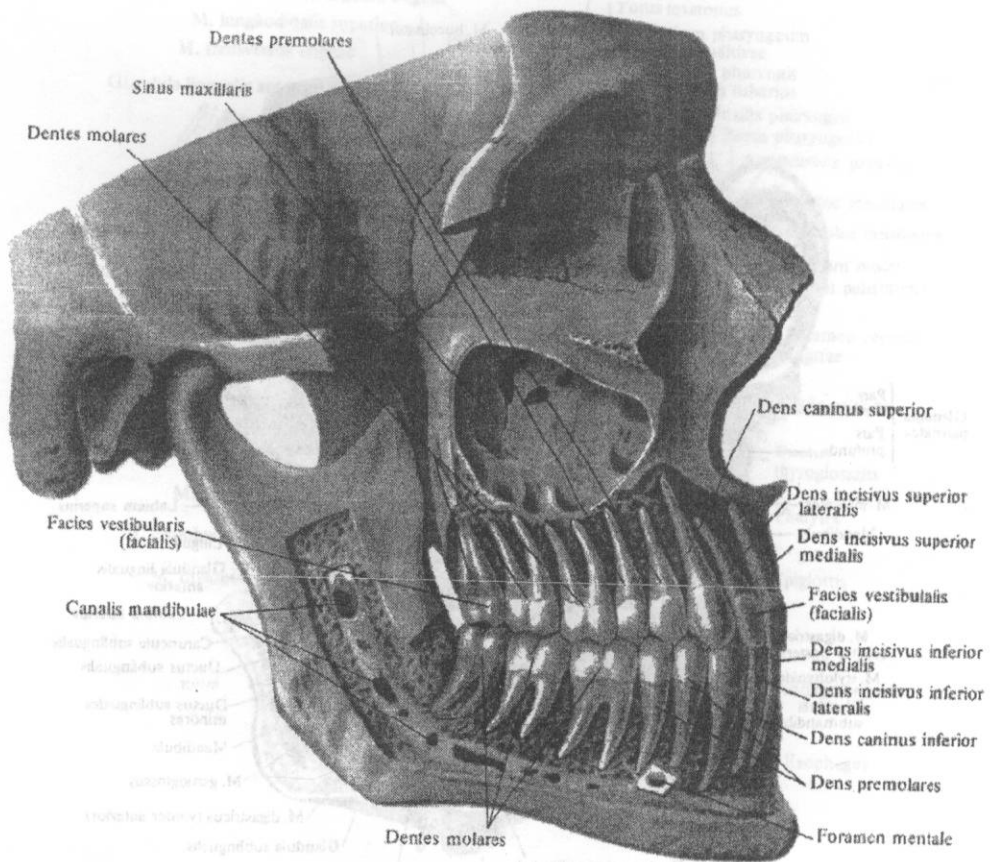
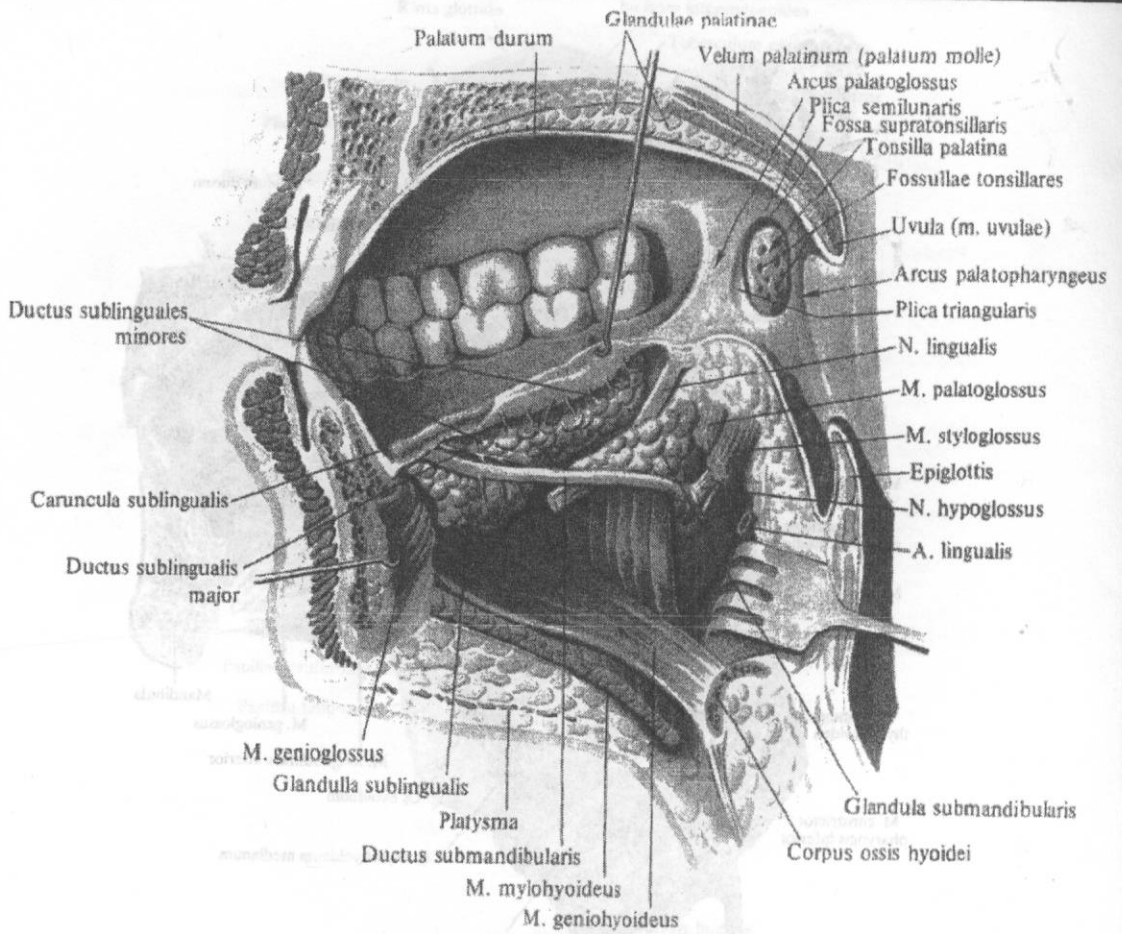
- 11 – *trigonum omotrapezoideum*;
 12 – *trigonum omoclaviculare*;
 13 – *trigonum omotracheale*;
 14 – *trigonum caroticum*;
 15 – *trigonum submandibulare*;
 16 – *trigonum submentale*;
 17 – *trigonum a. lingualis (Пупозов)*;
 18 – *m. mylohyoideus*;
 19 – *n. hypoglossus (XII)*.

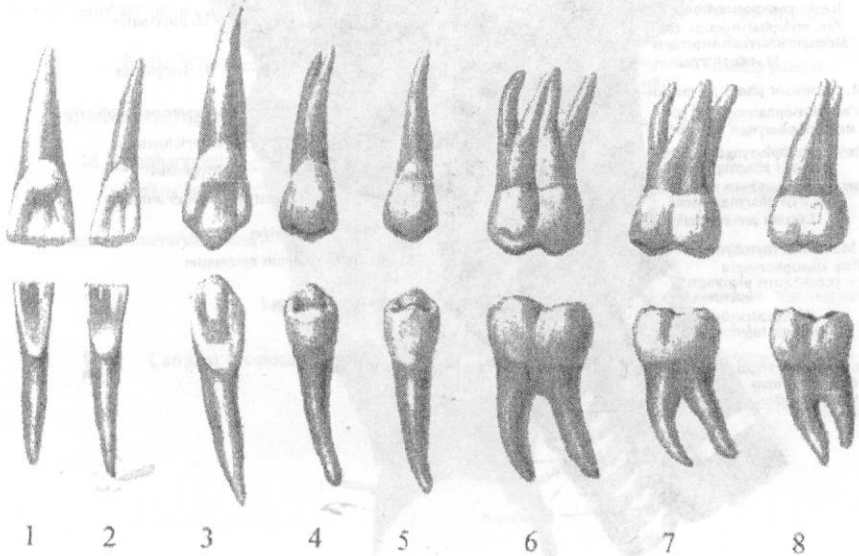
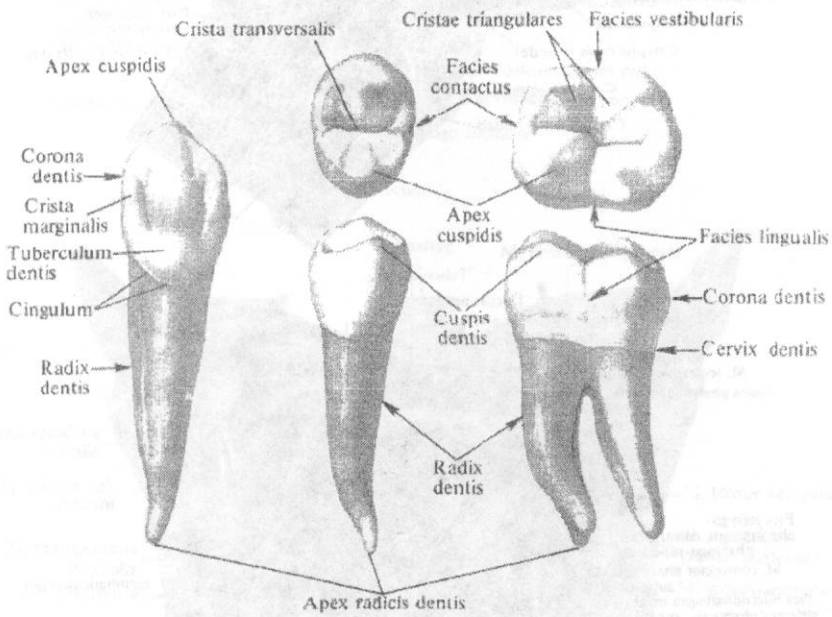
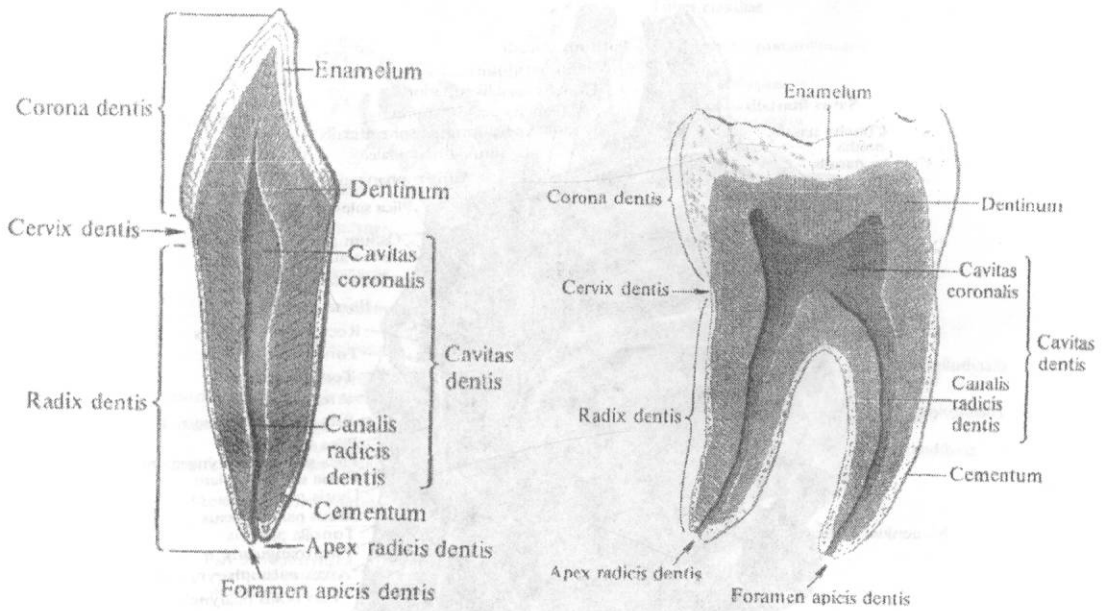


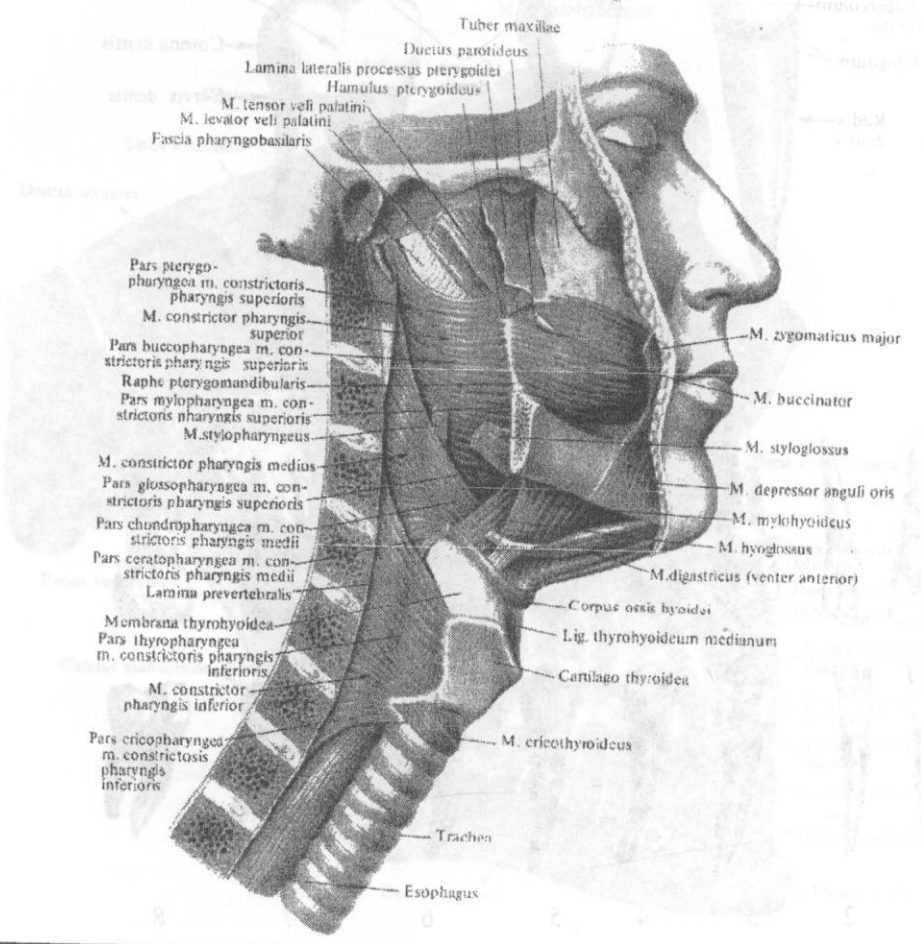
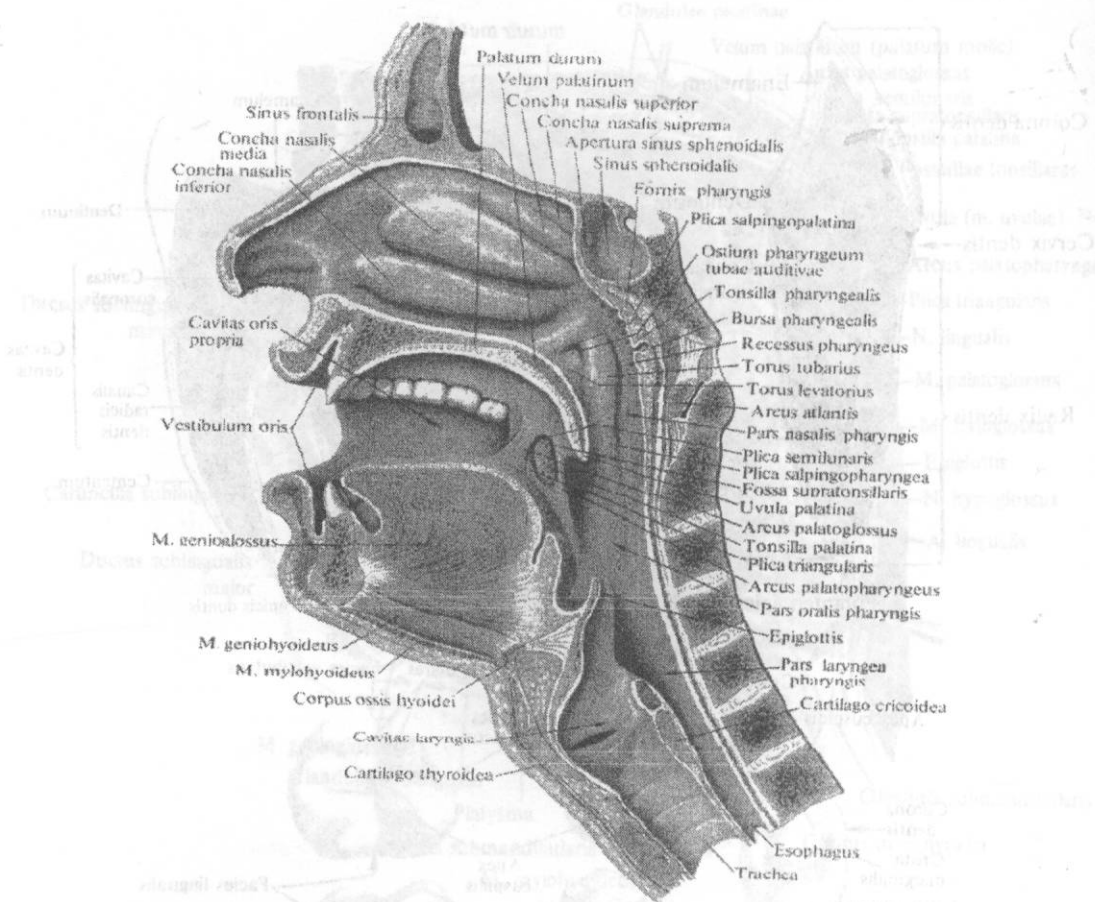


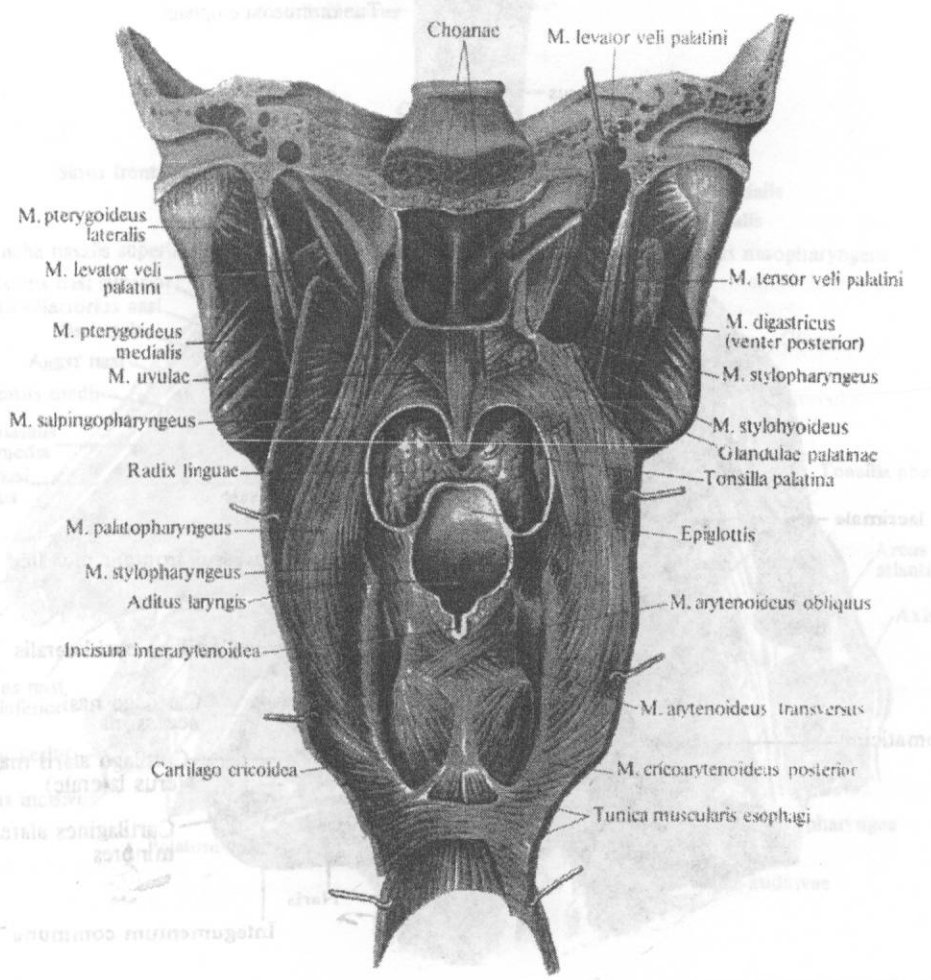
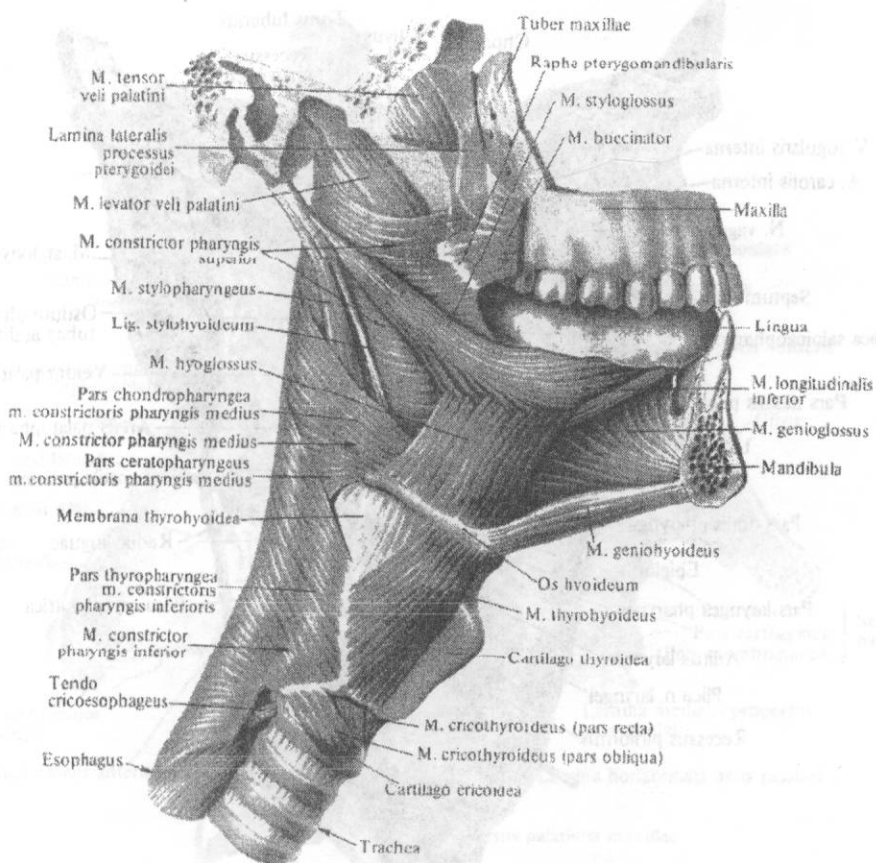


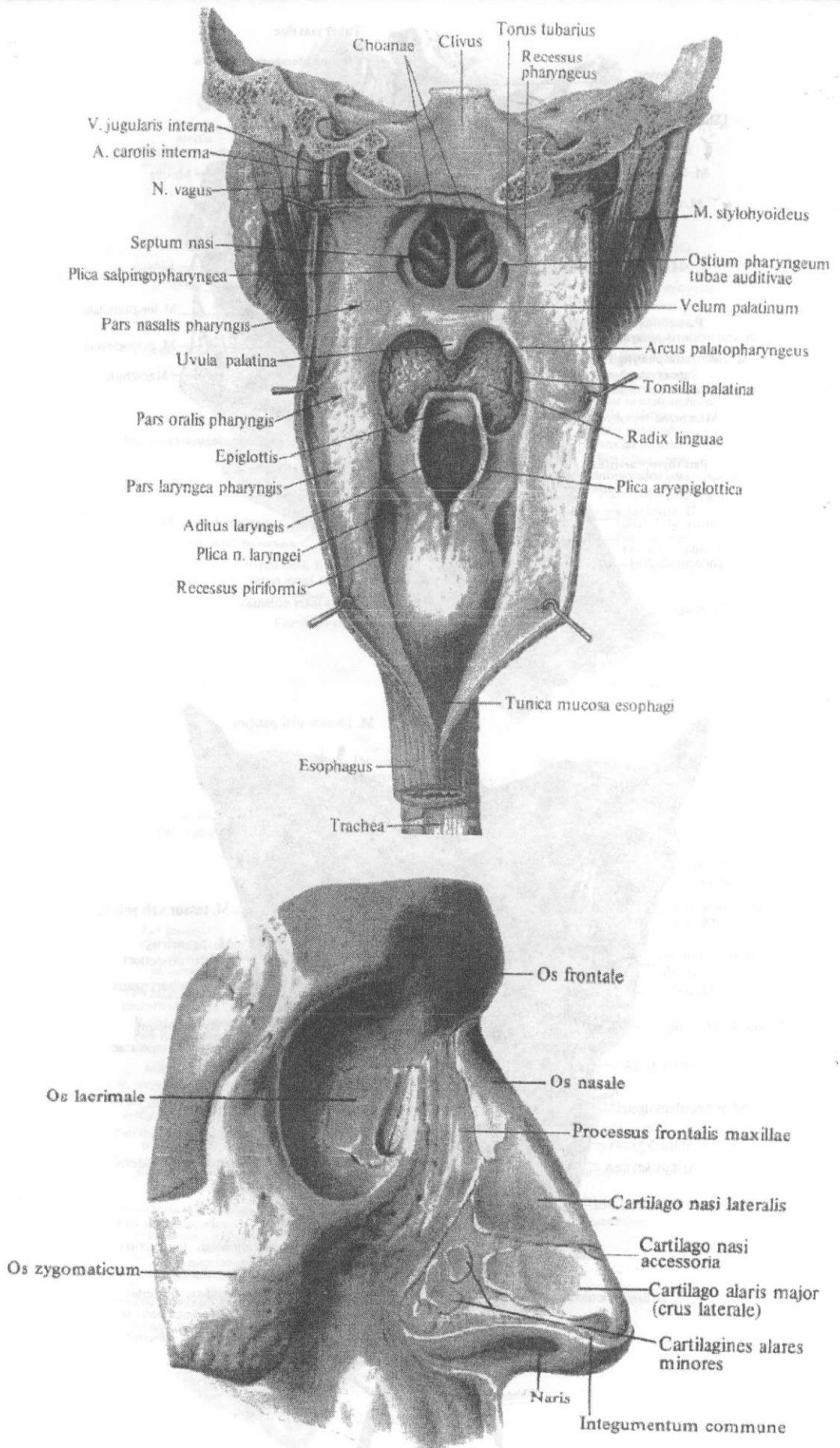


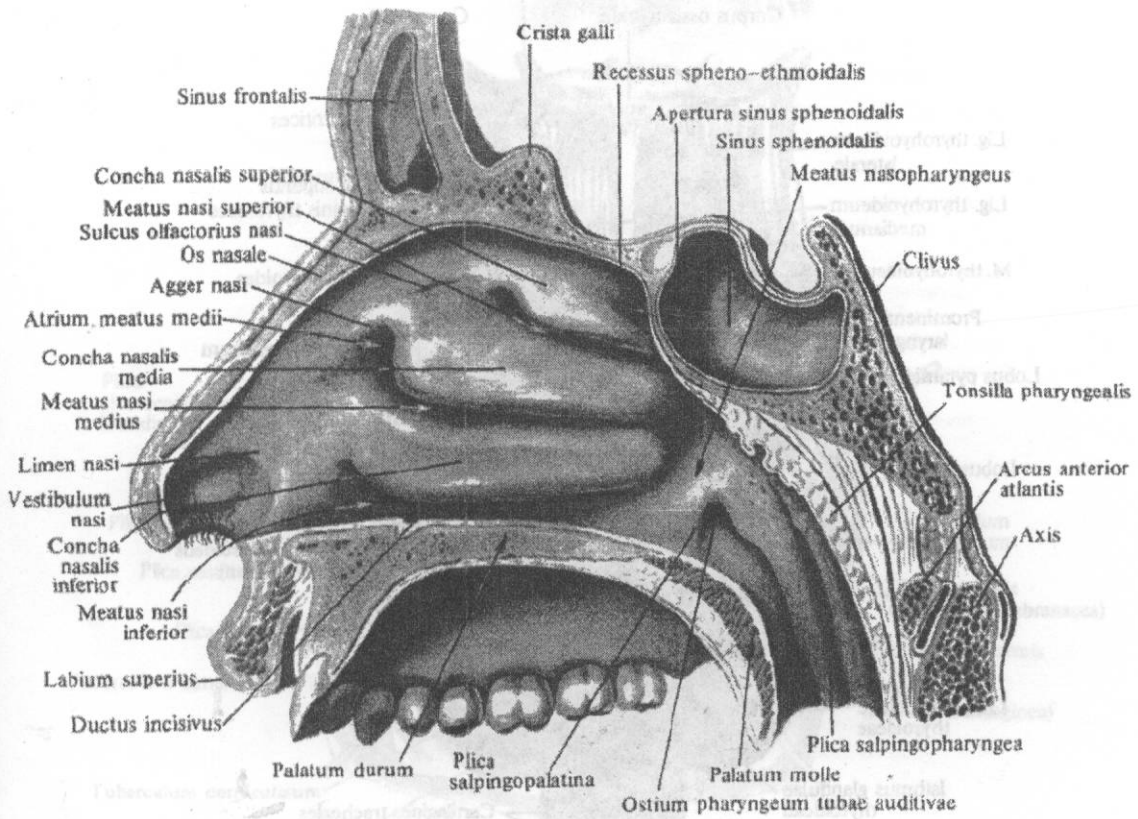
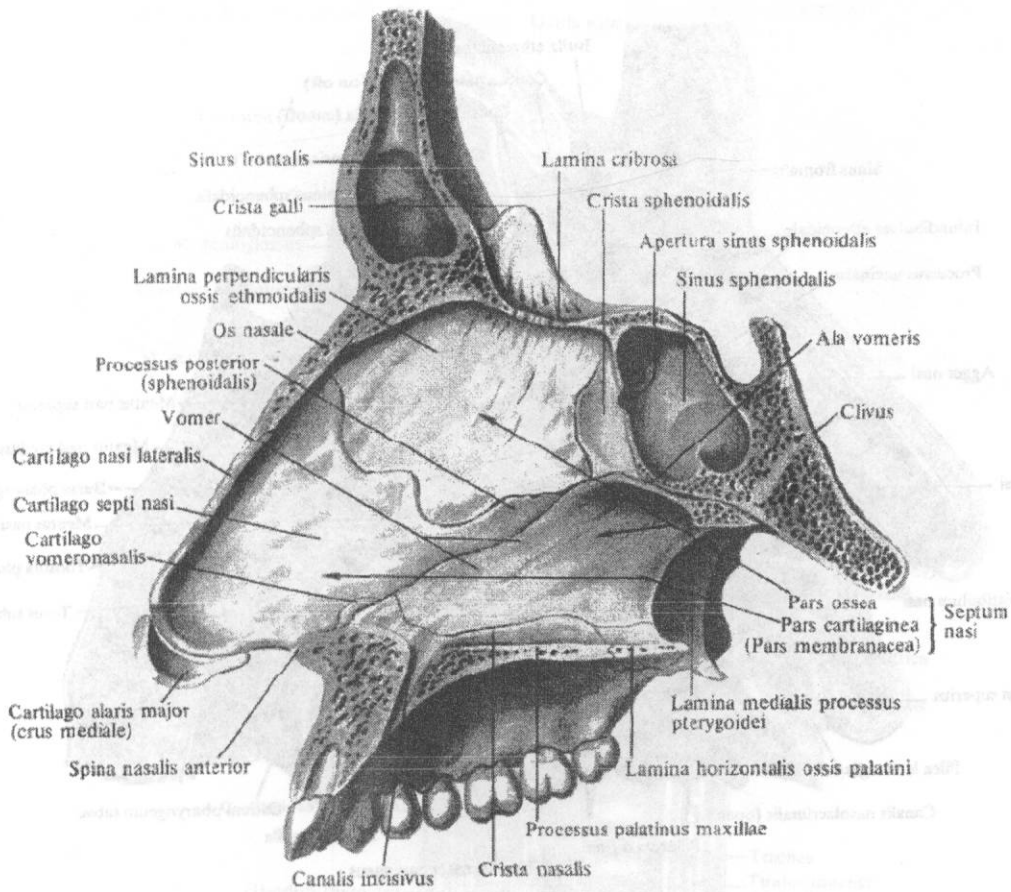


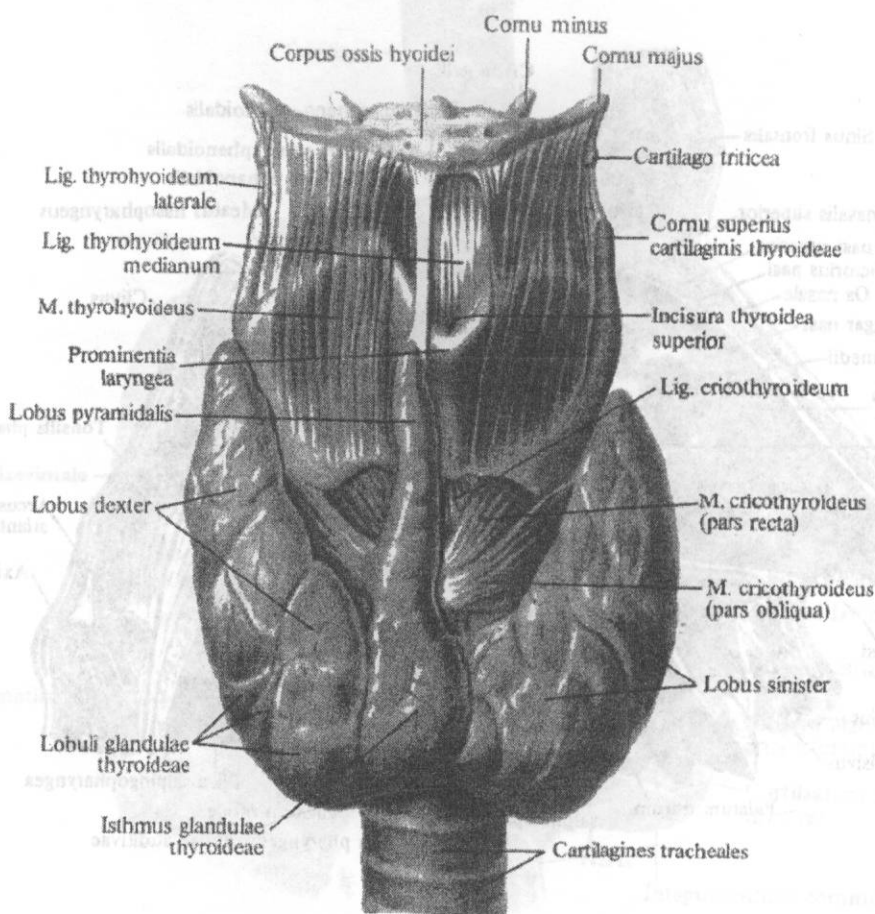
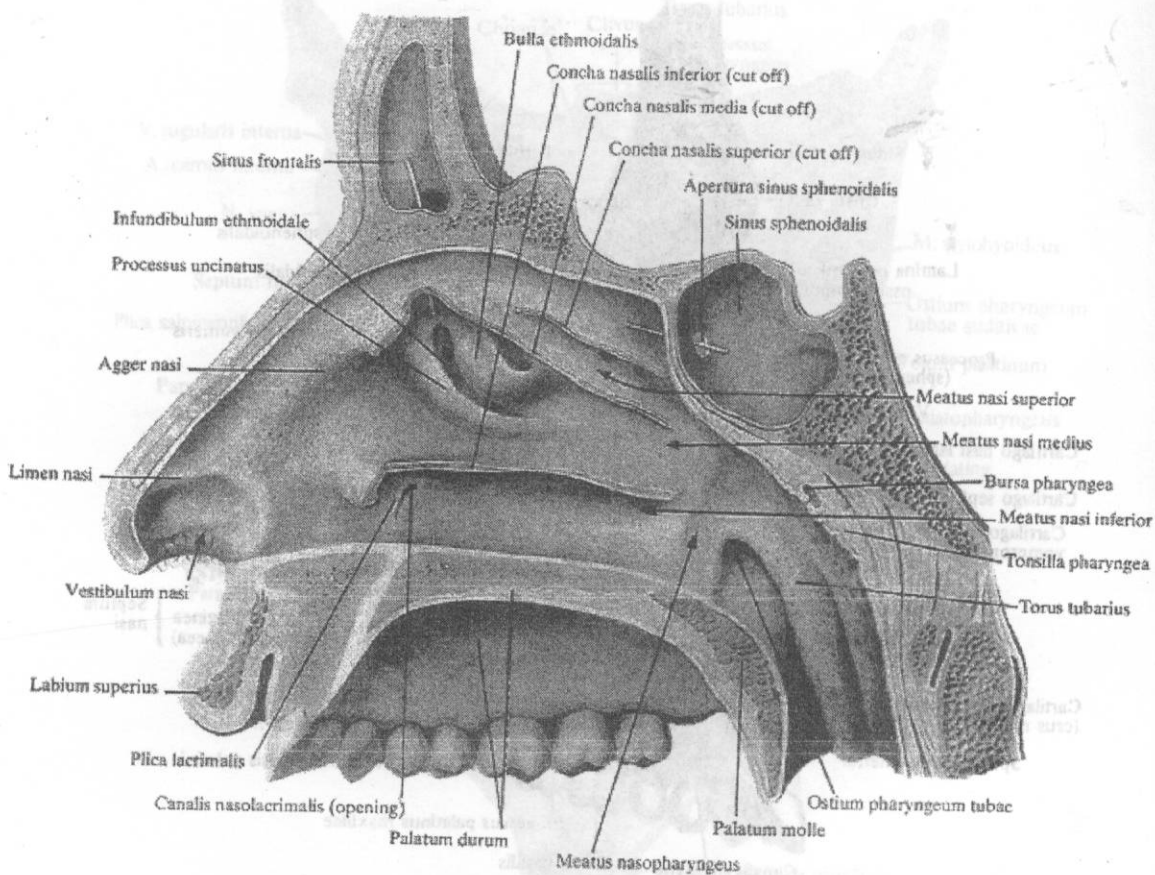


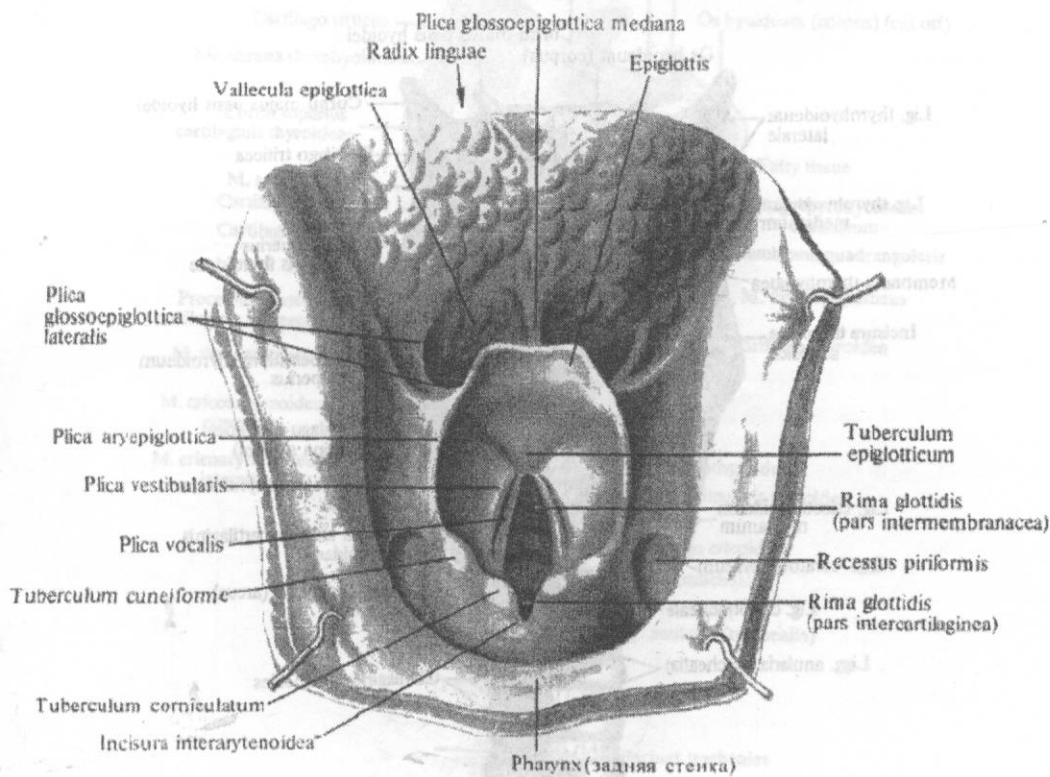
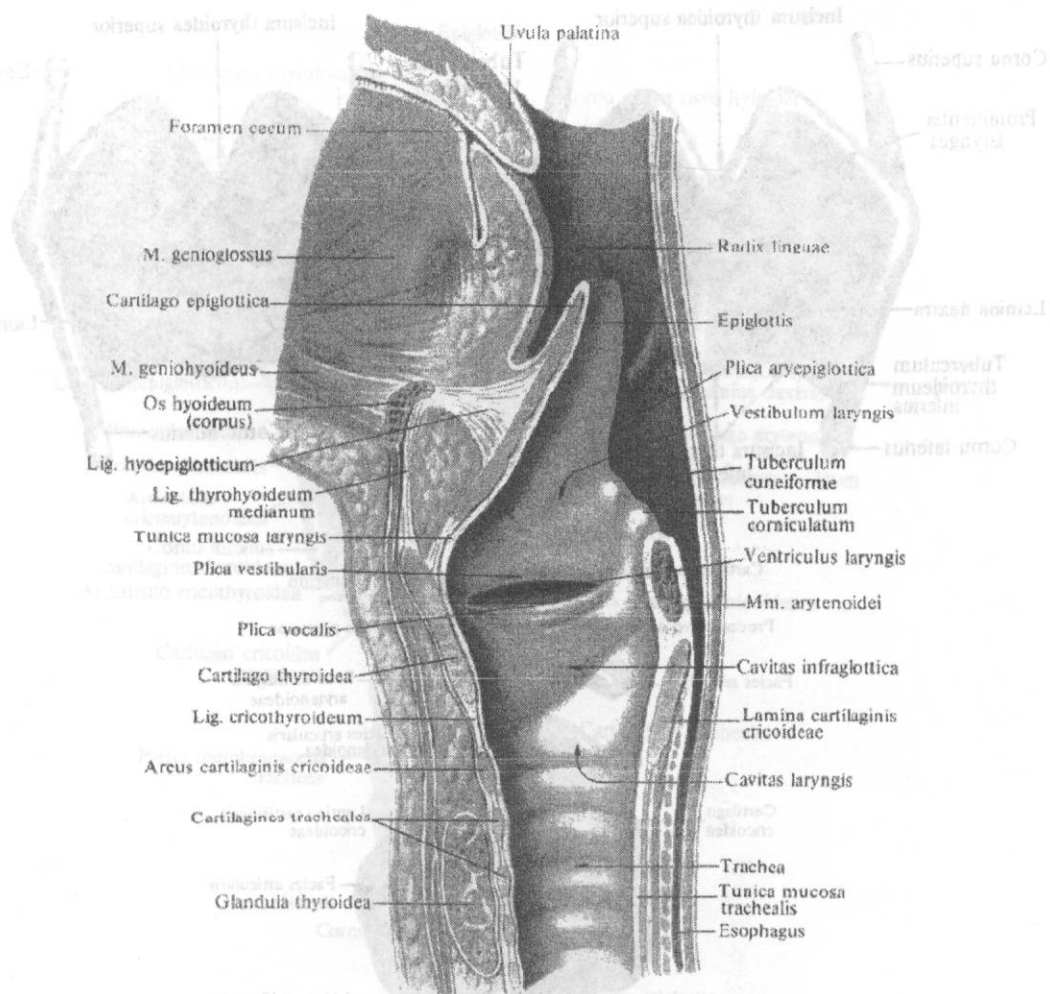


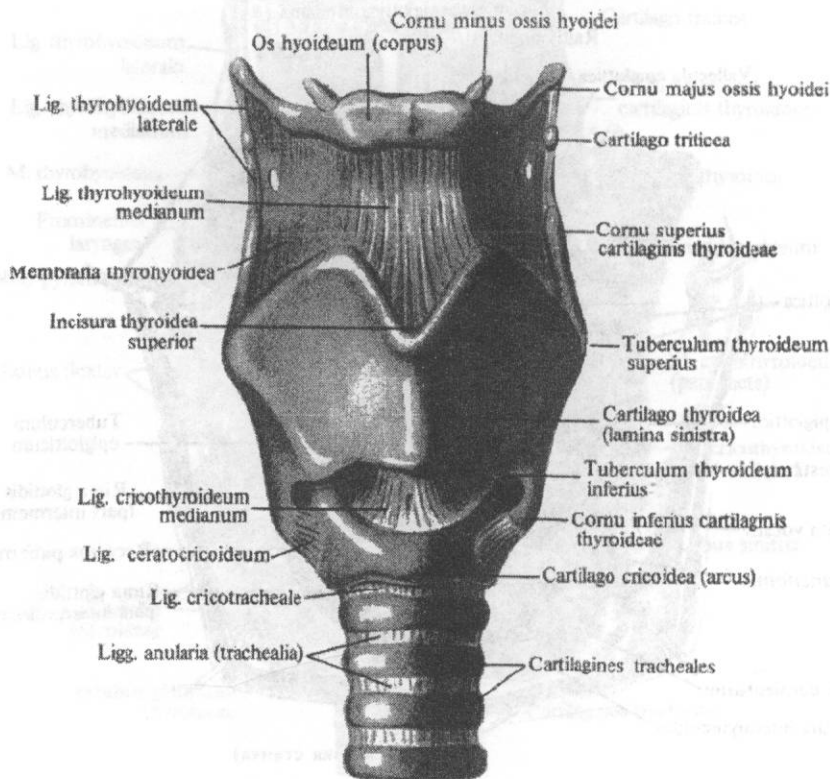
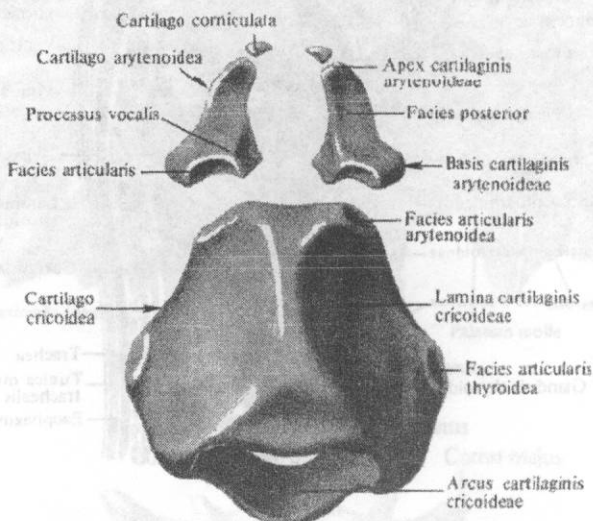
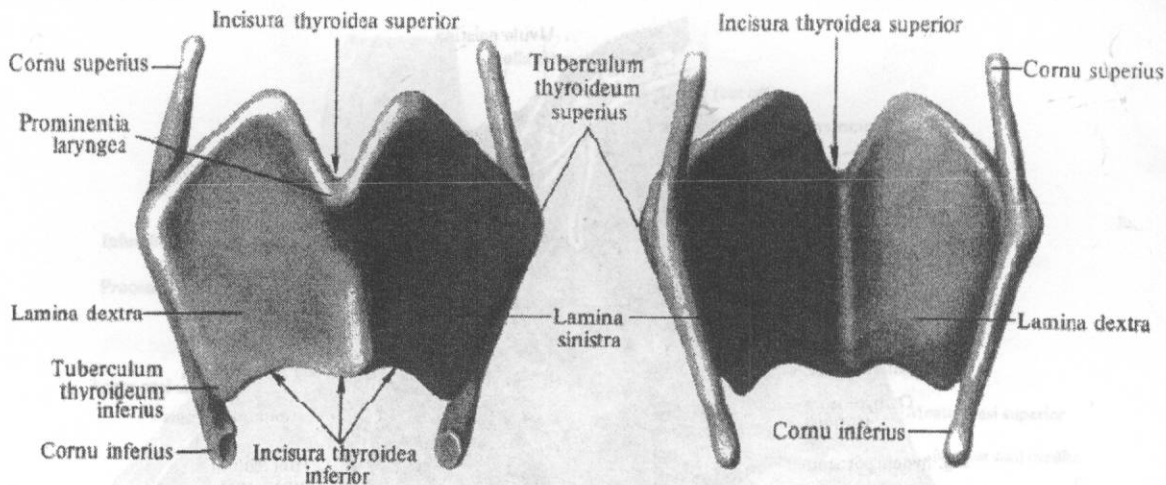


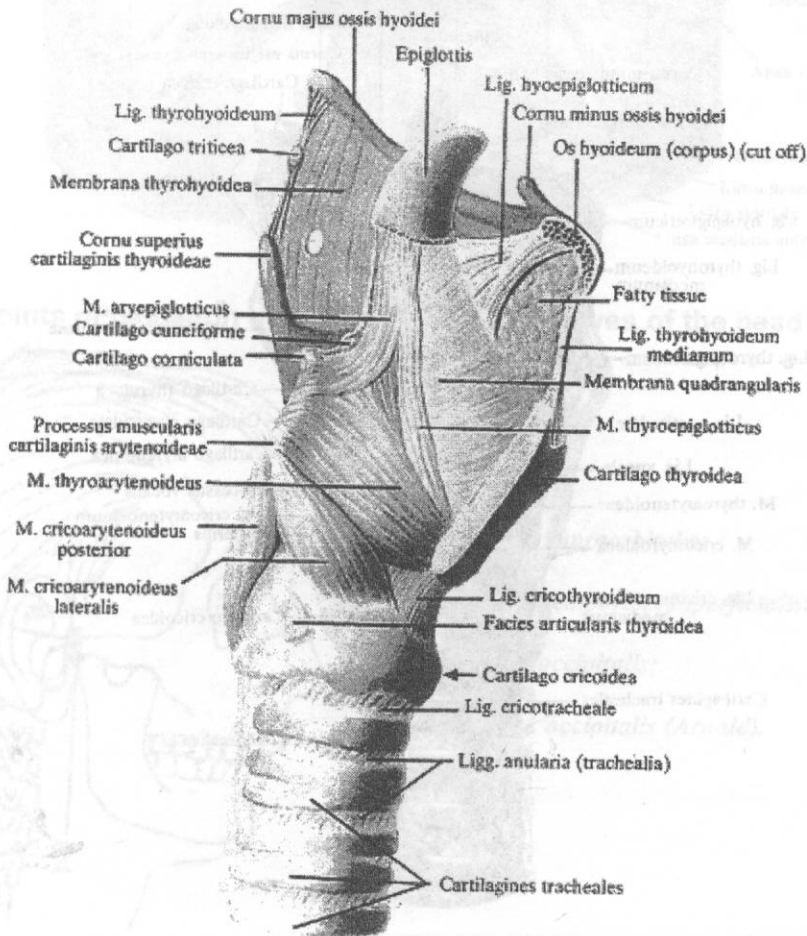
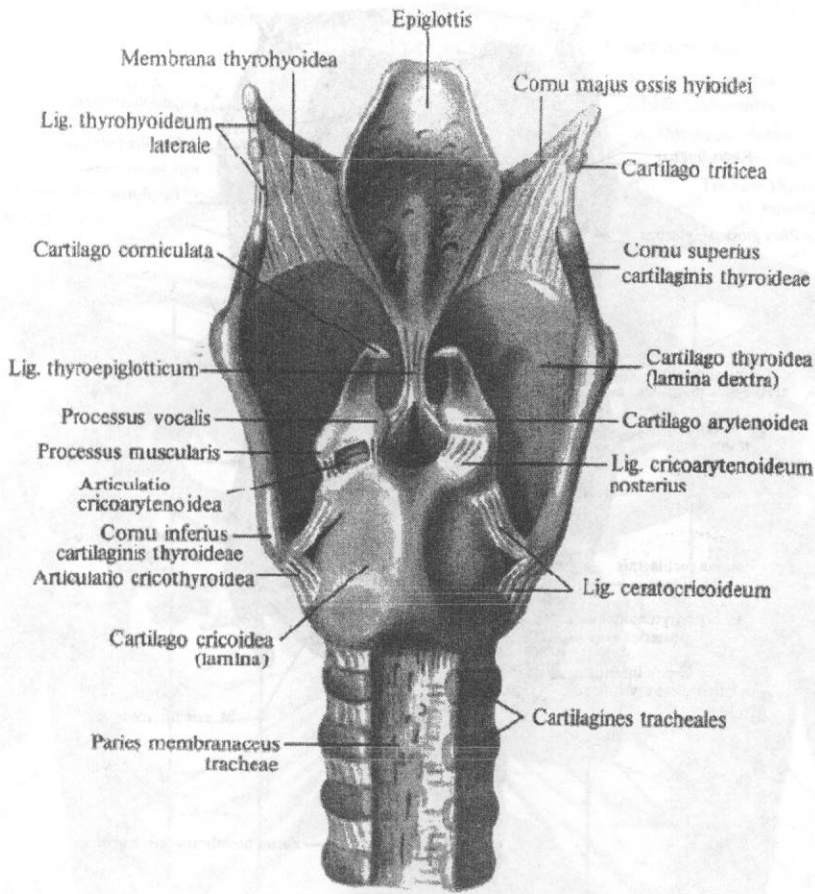


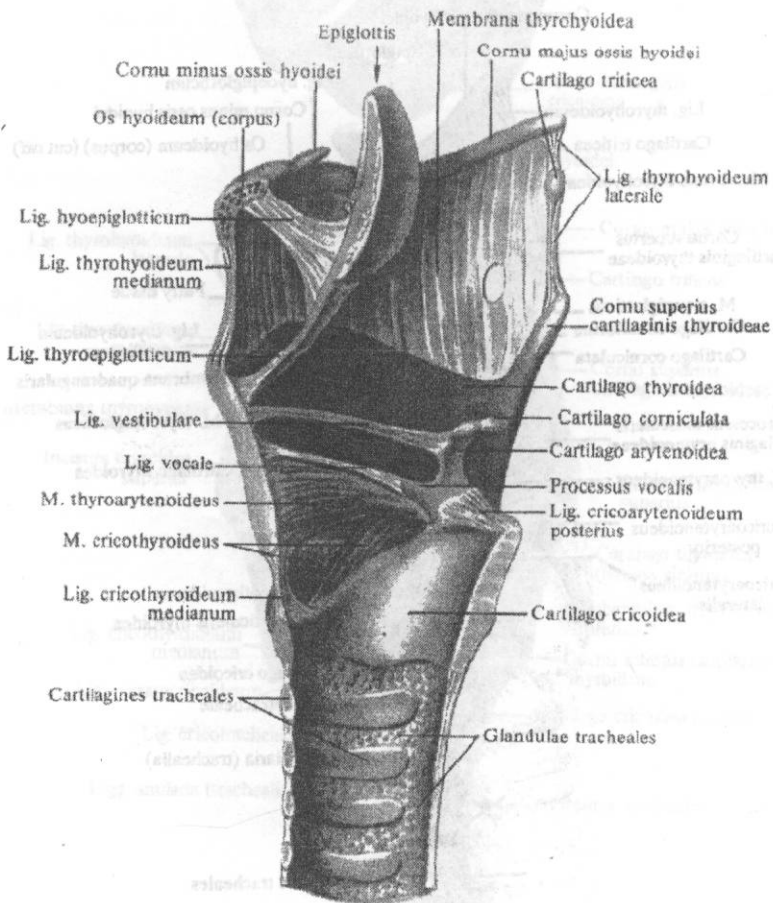
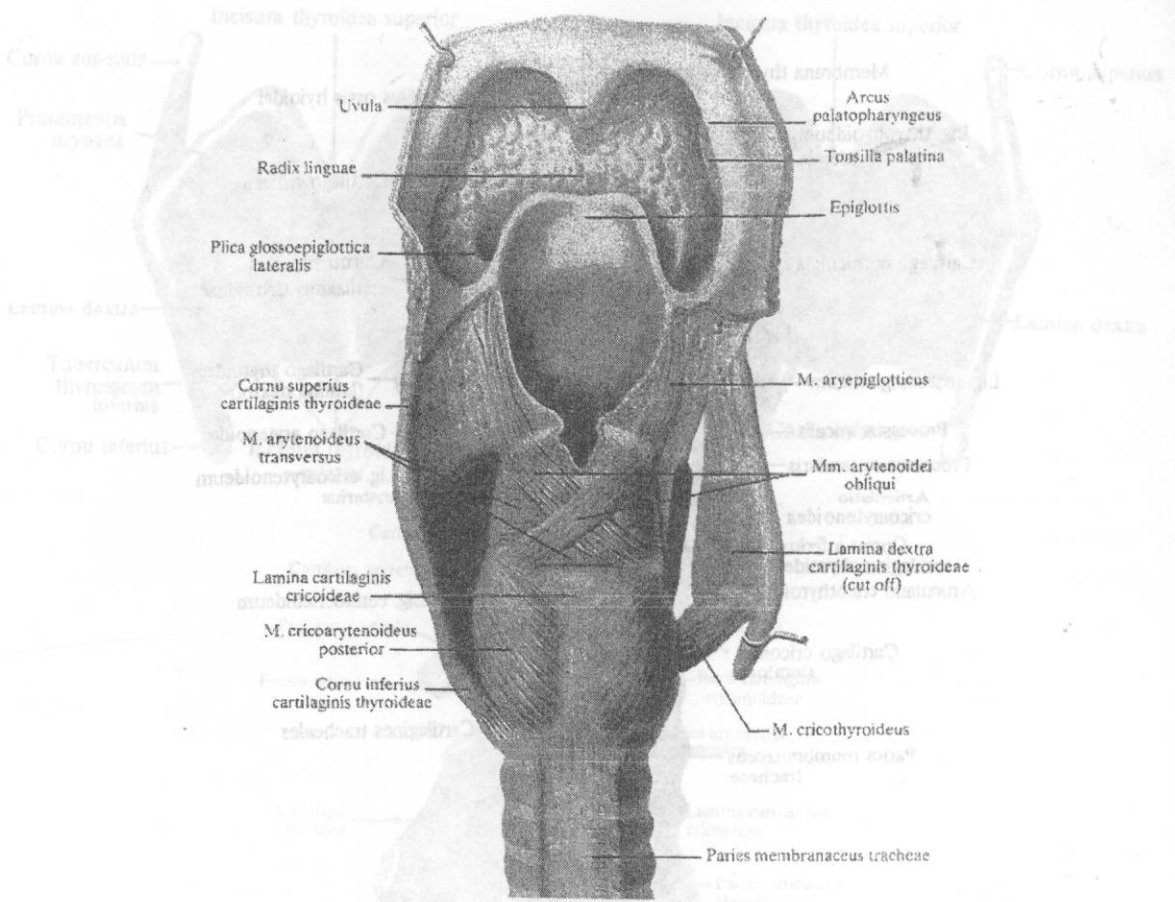


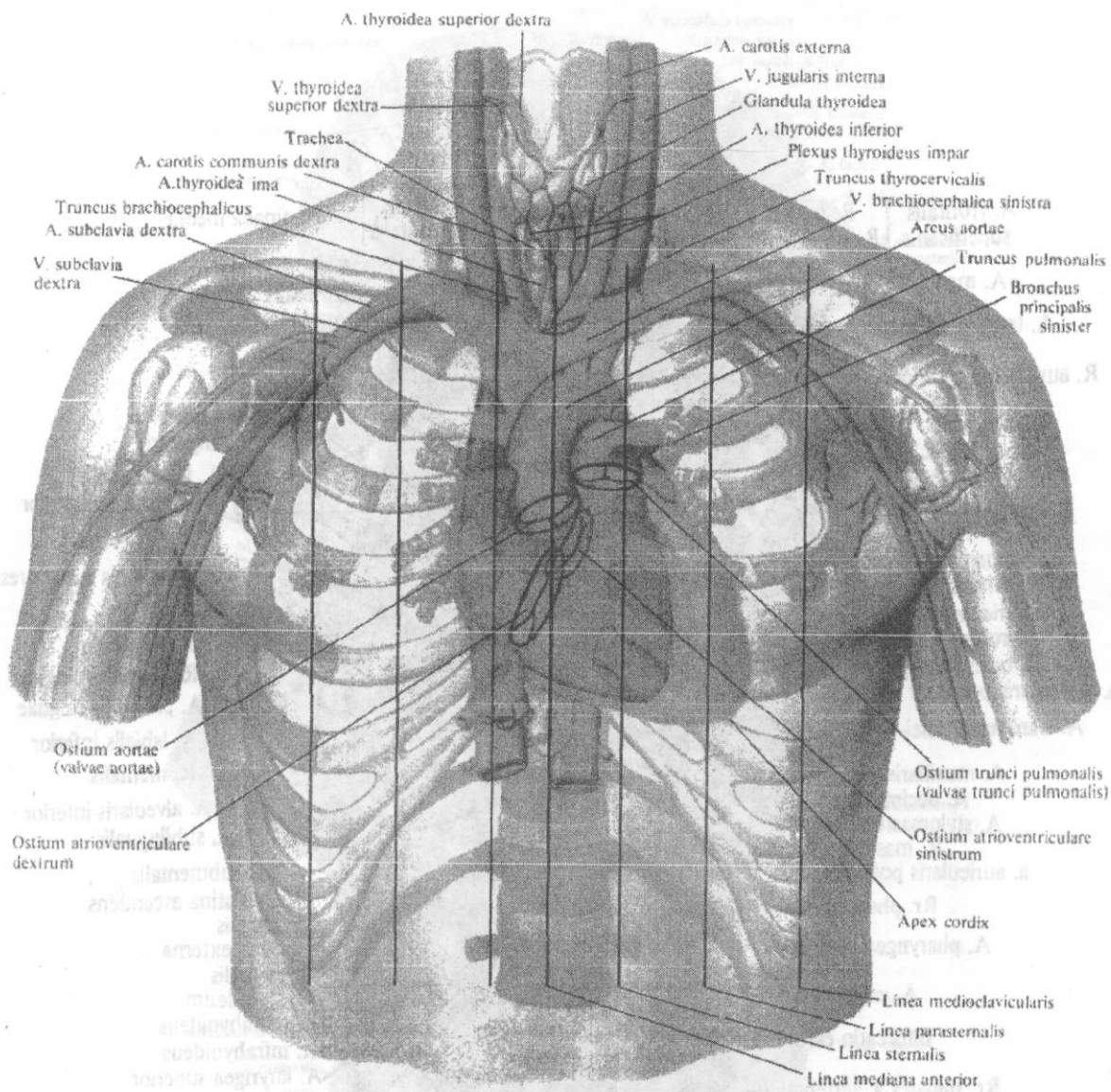




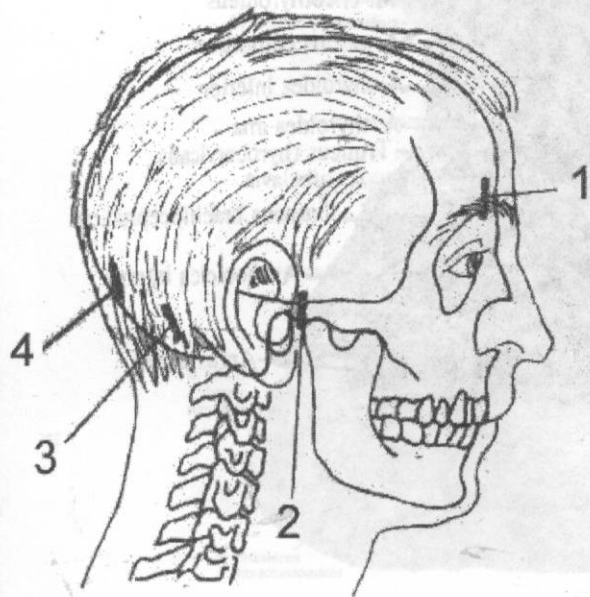








Points of palpation of some arteries and nerves of the head

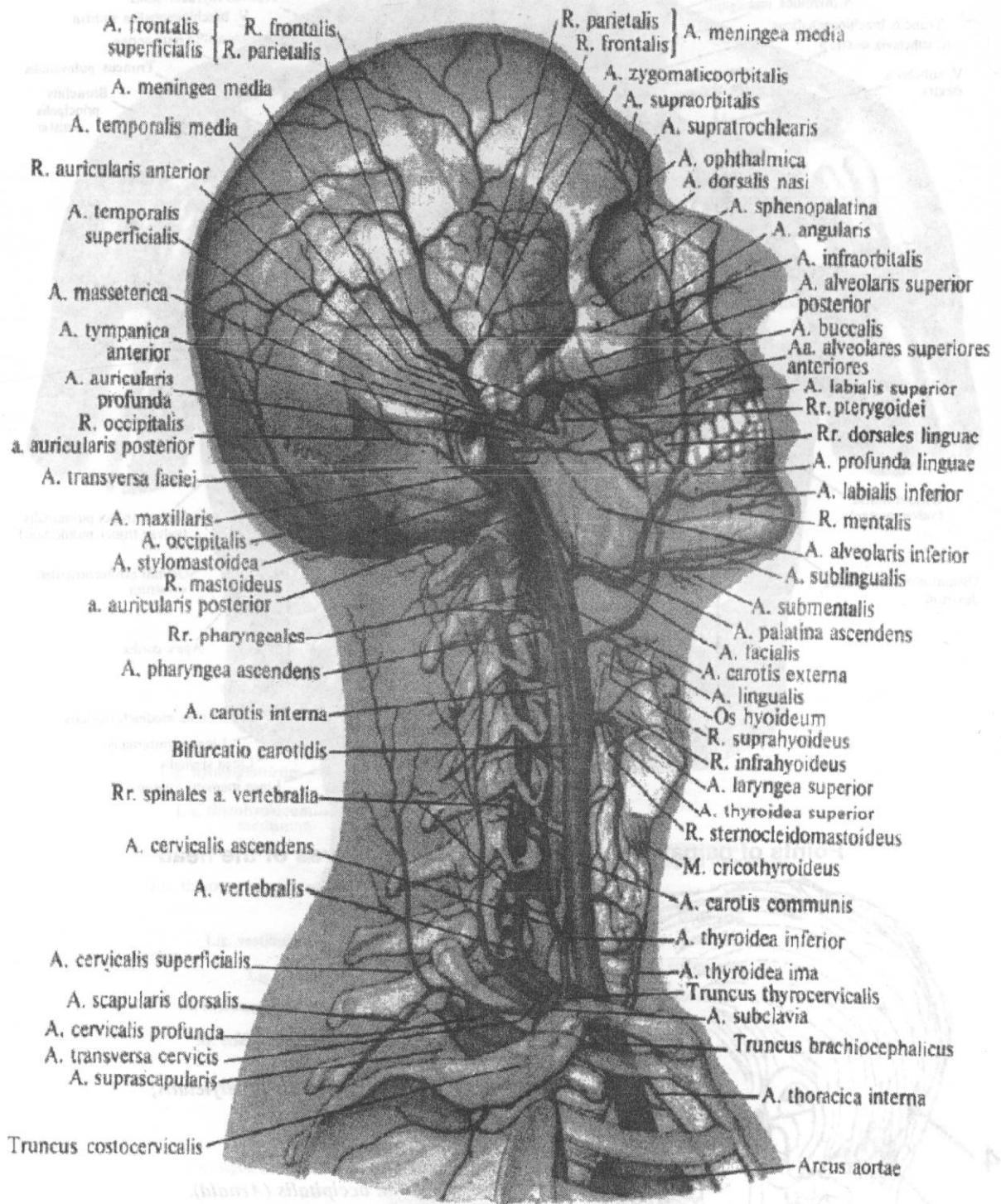


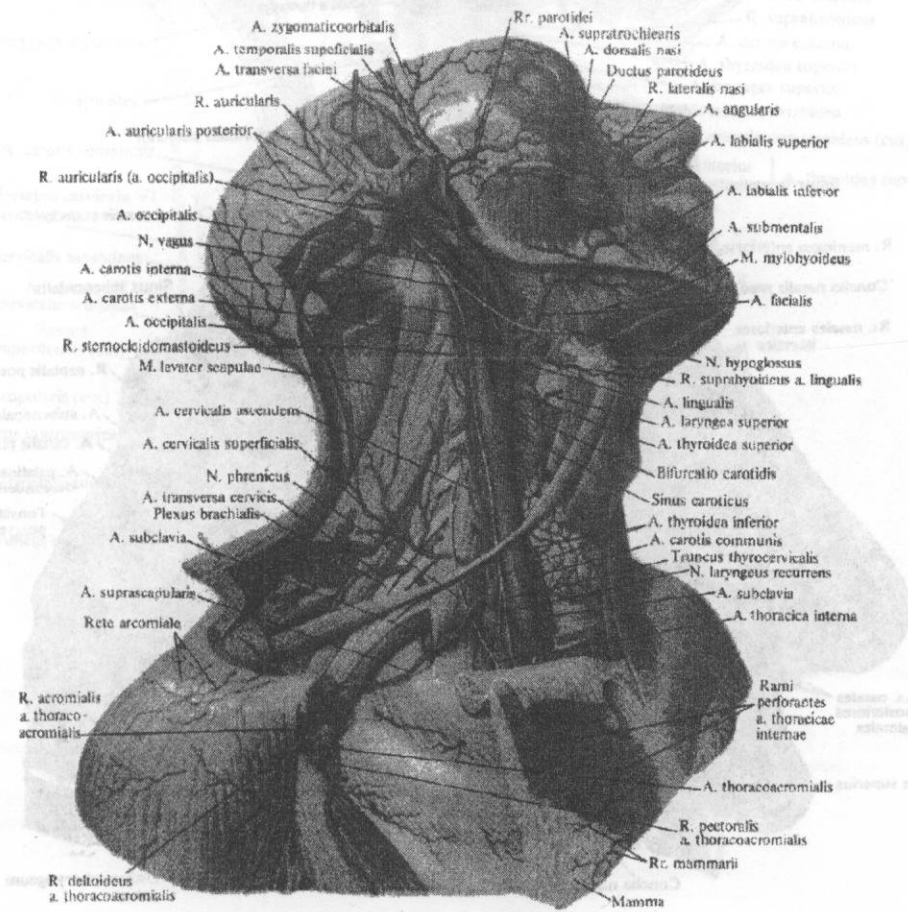
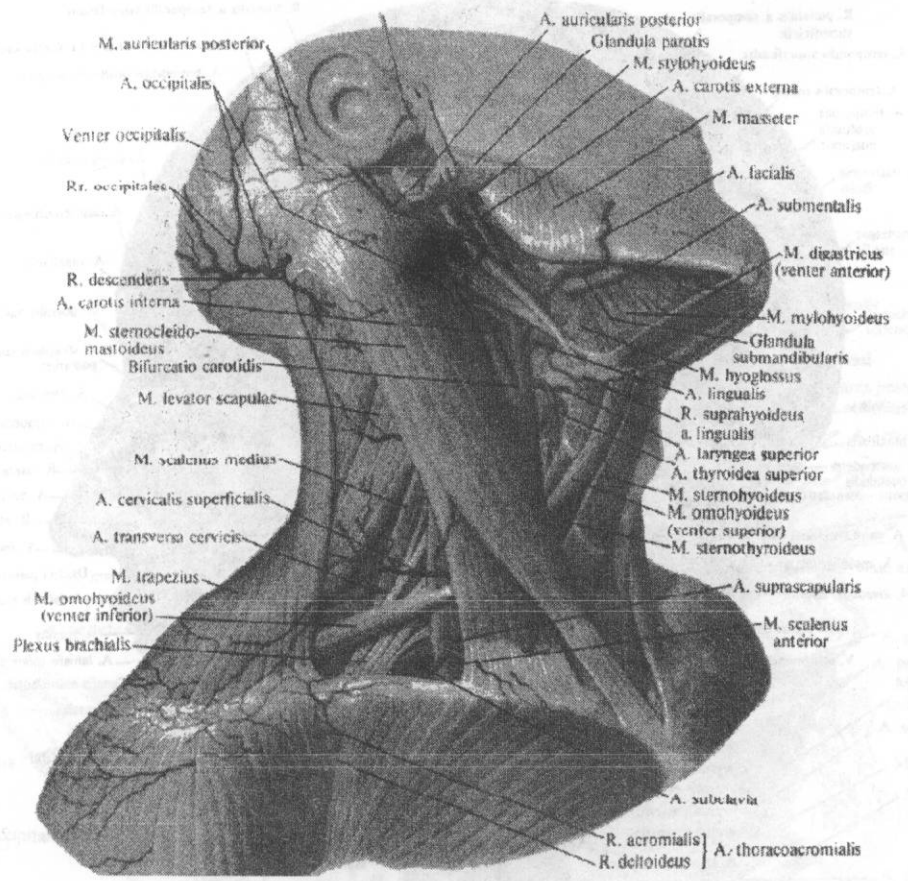
1 – *a. supraorbitalis*;

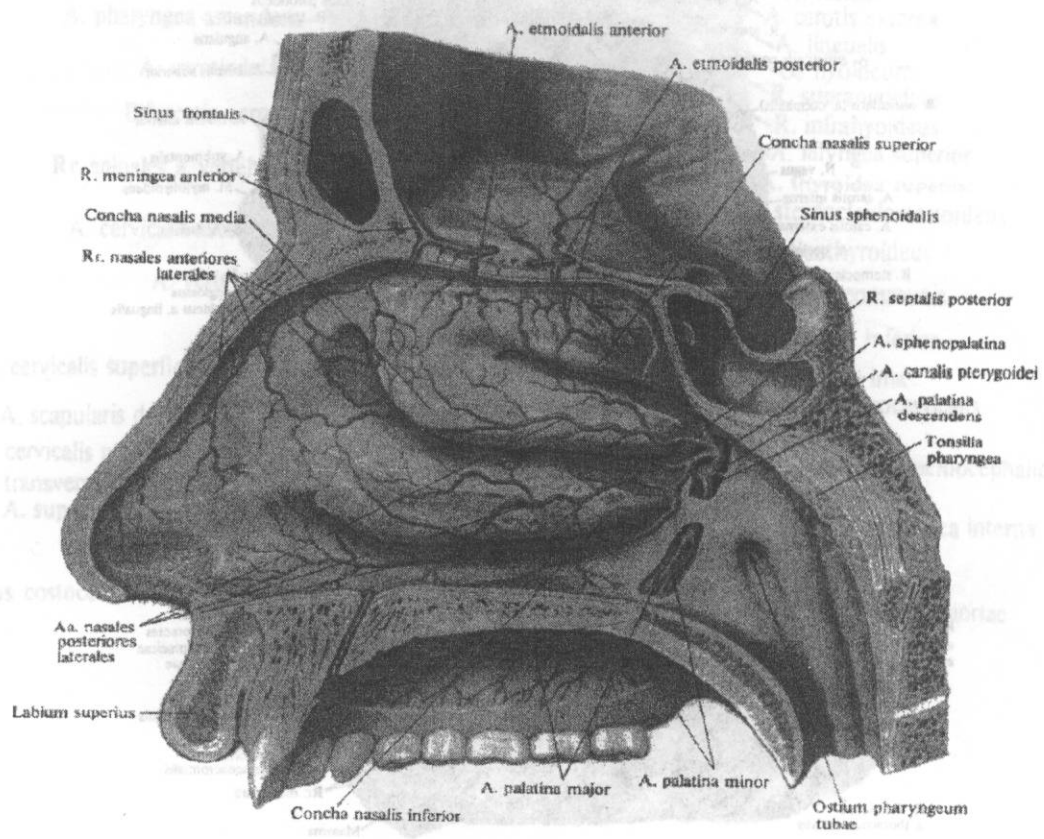
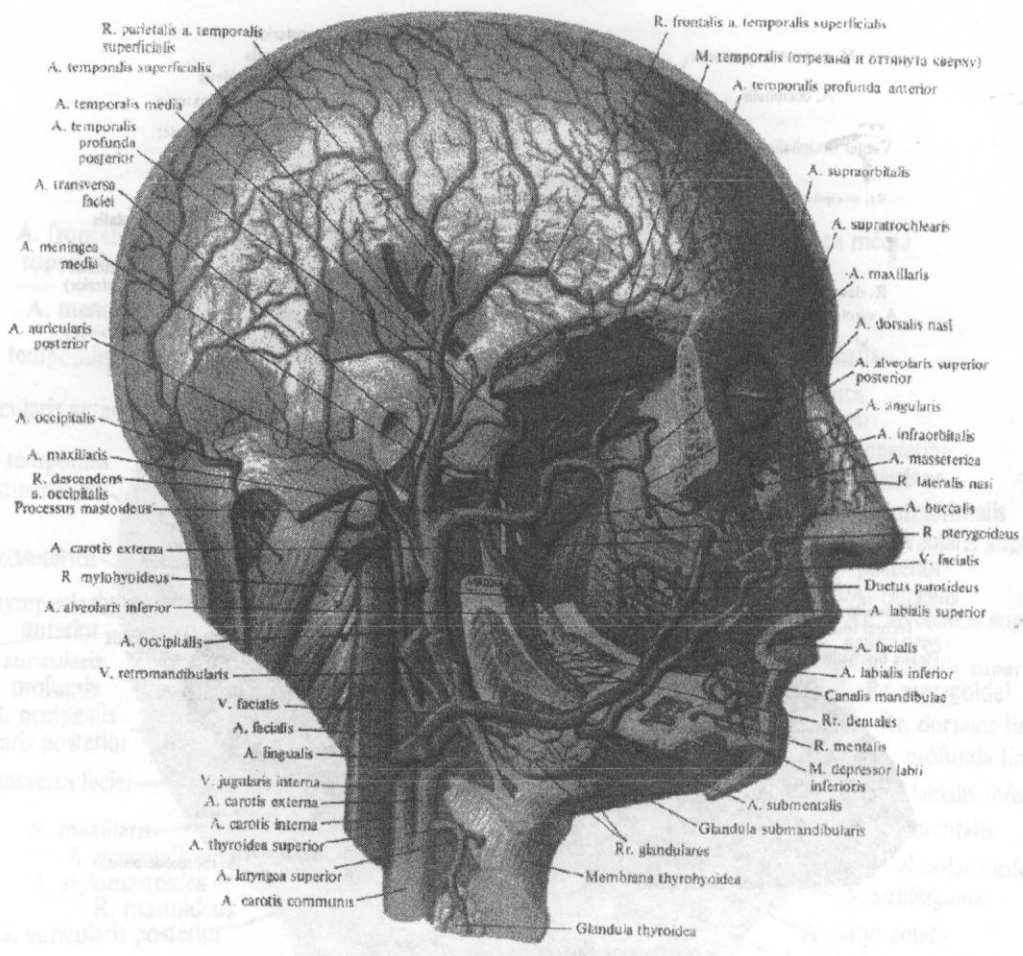
2 – *a. temporalis superficialis*;

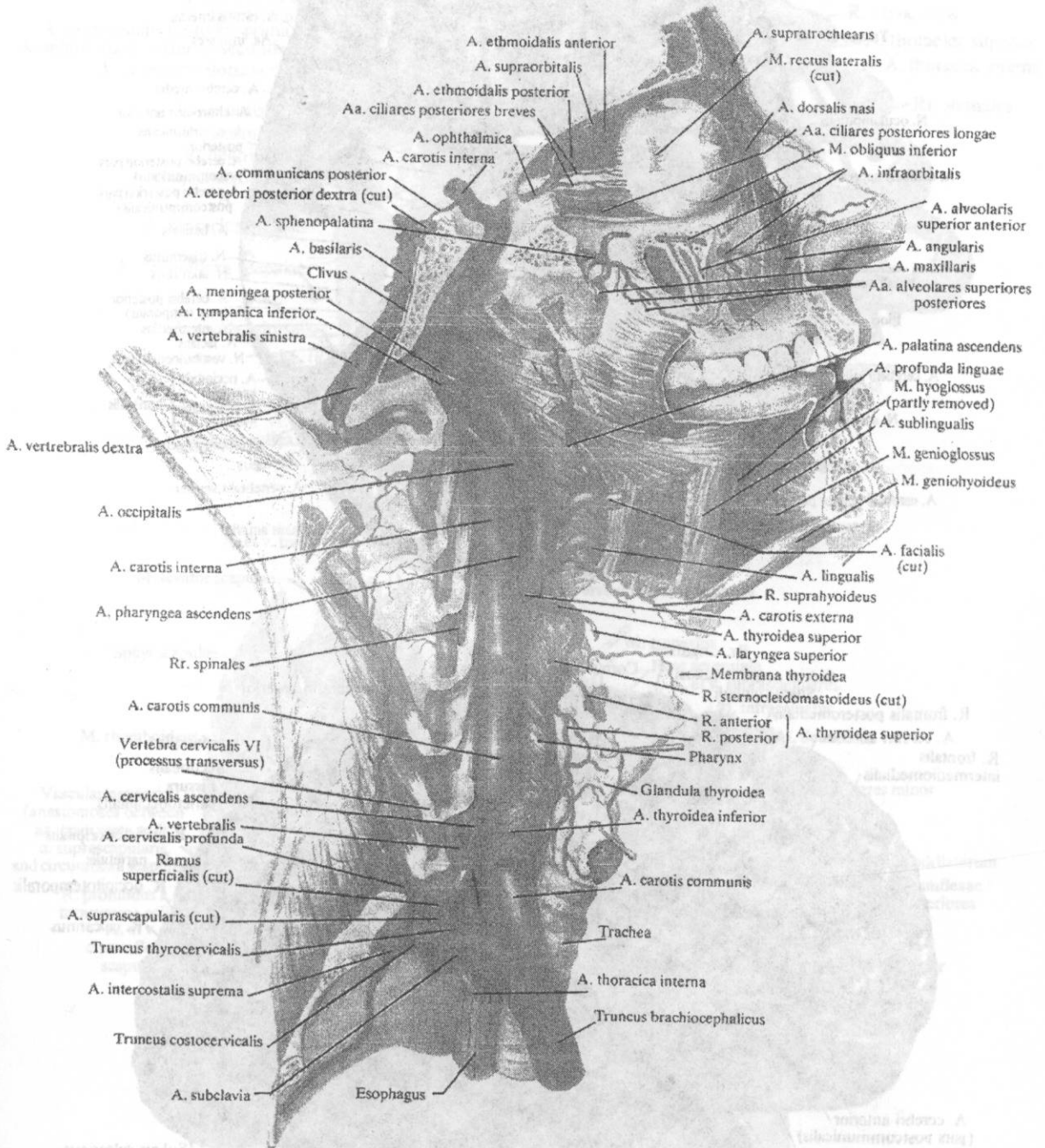
3 – *a. occipitalis*;

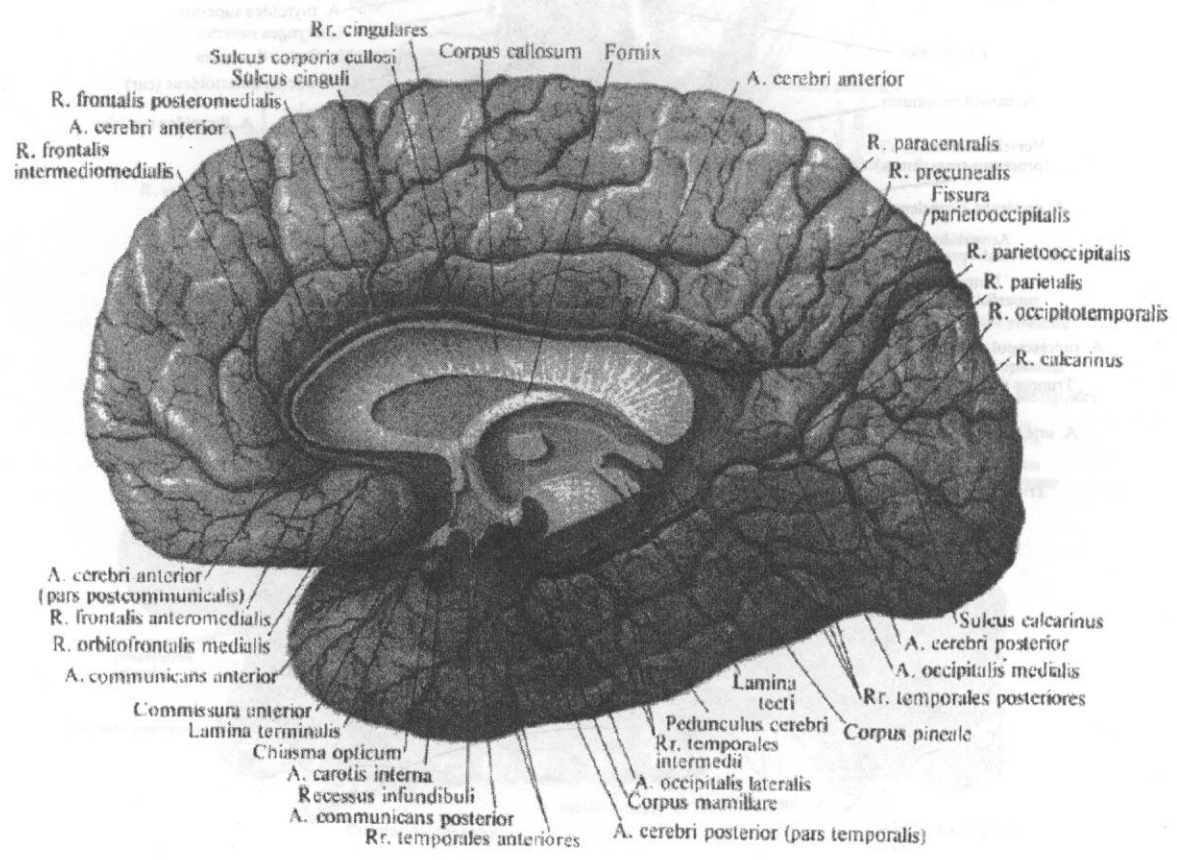
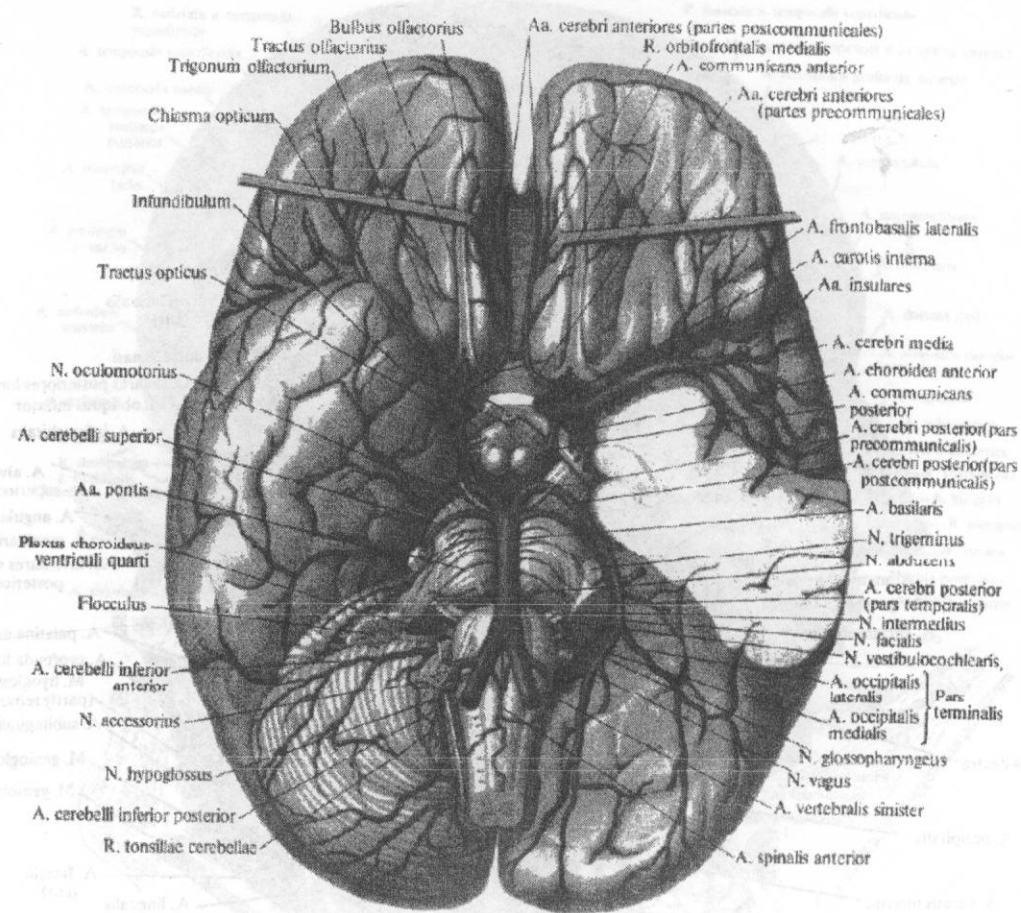
4 – *n. occipitalis (Arnald)*.

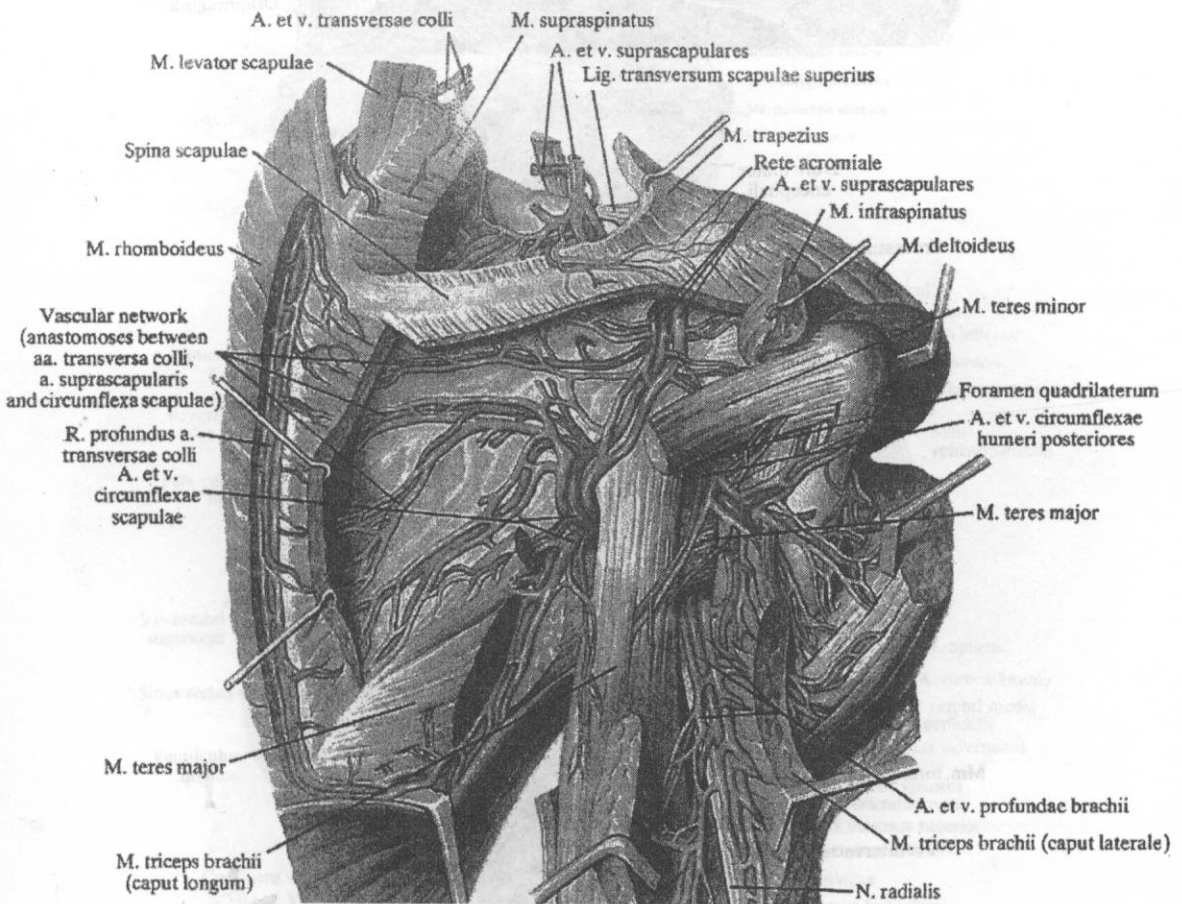
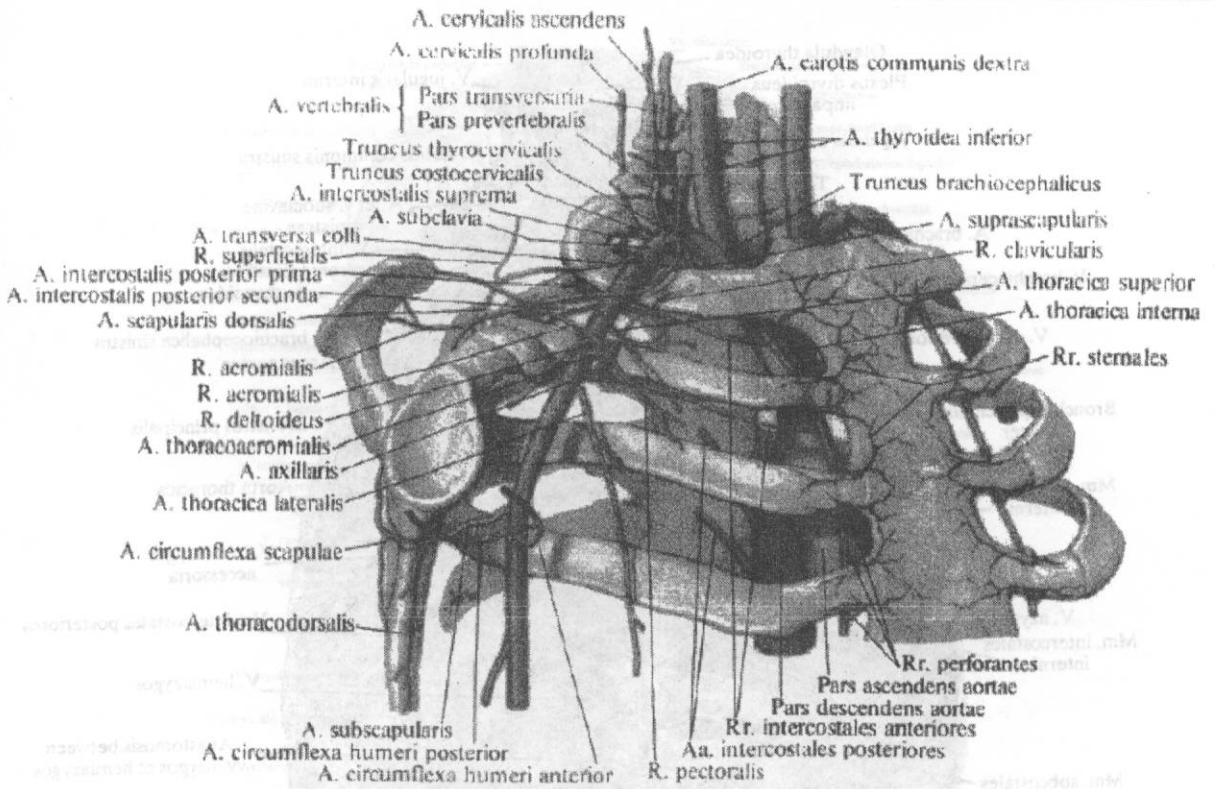


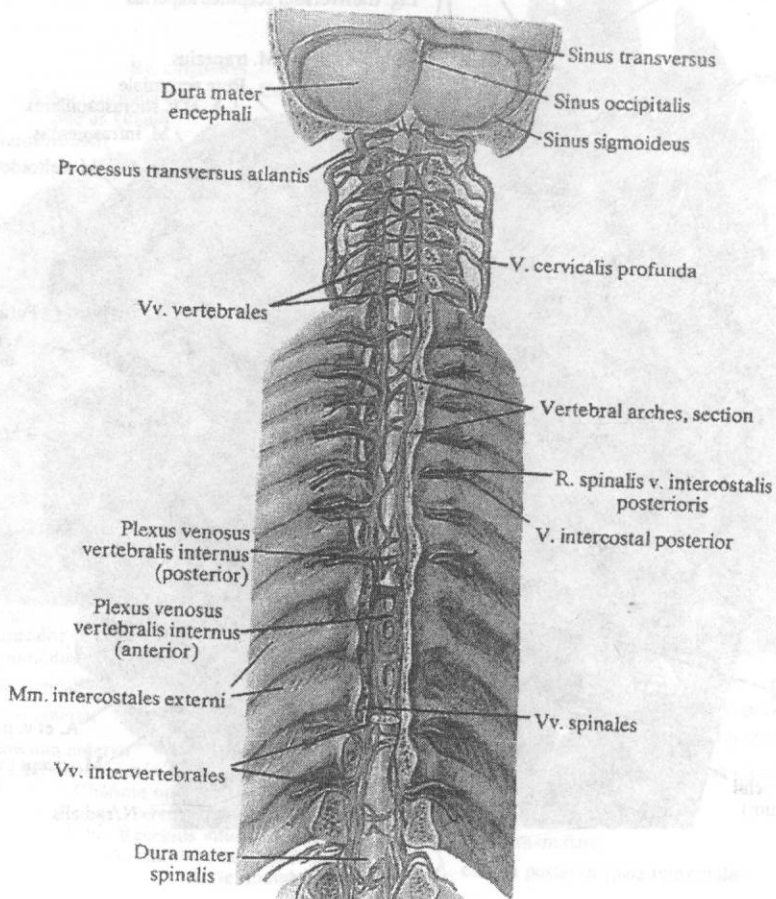
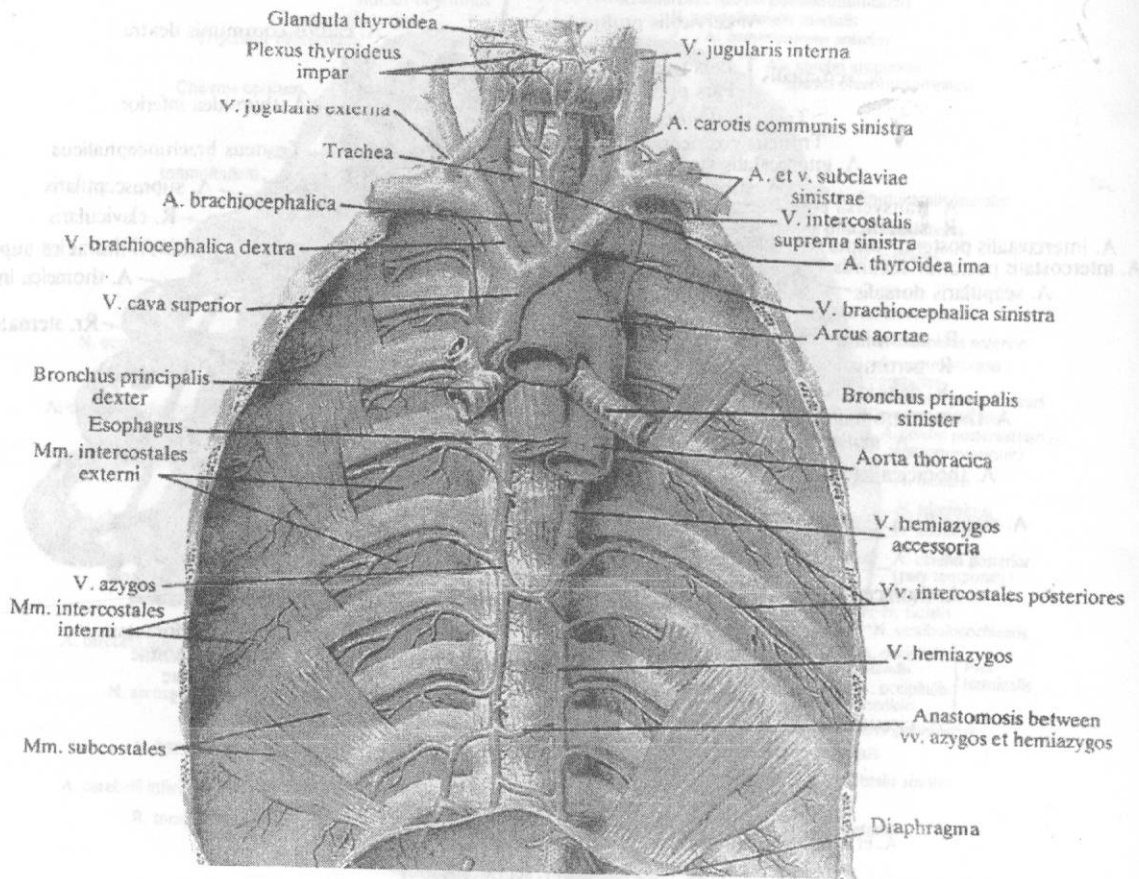


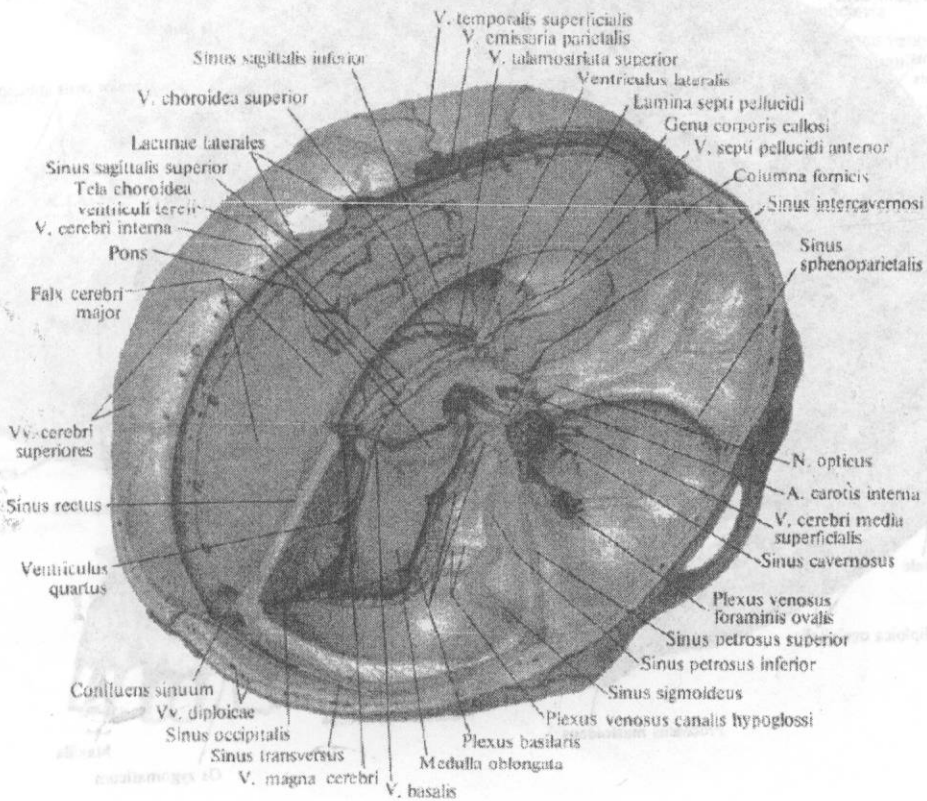
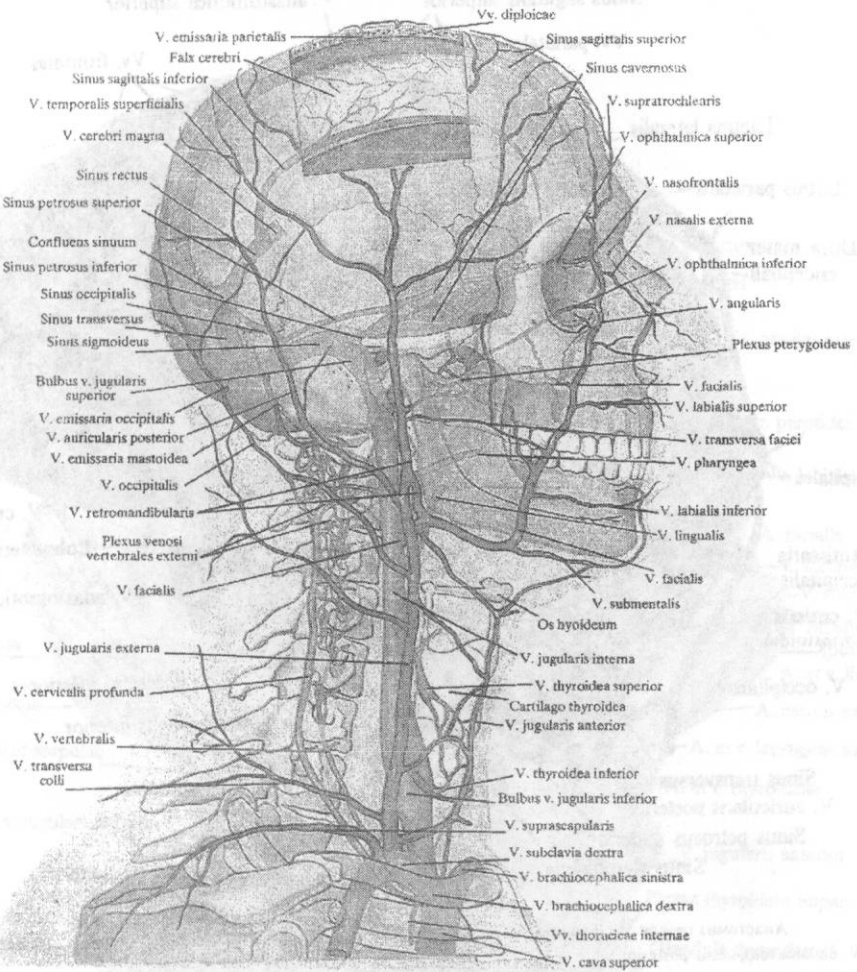


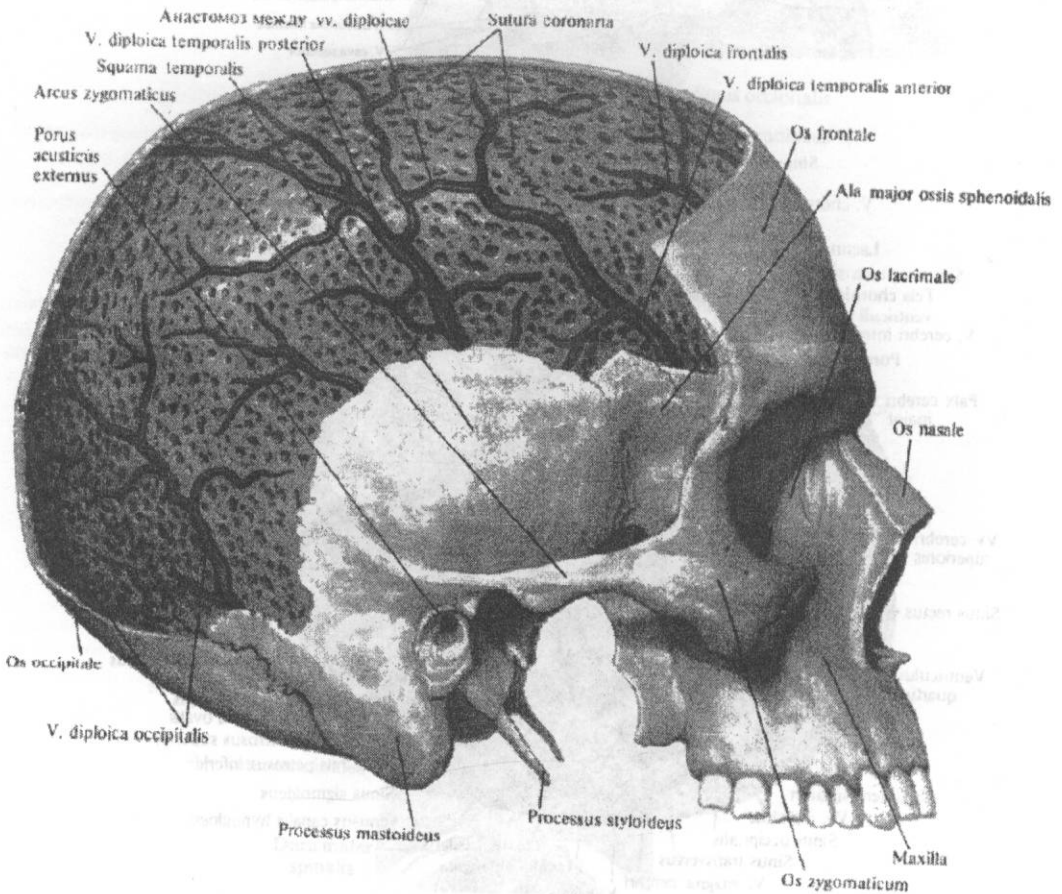
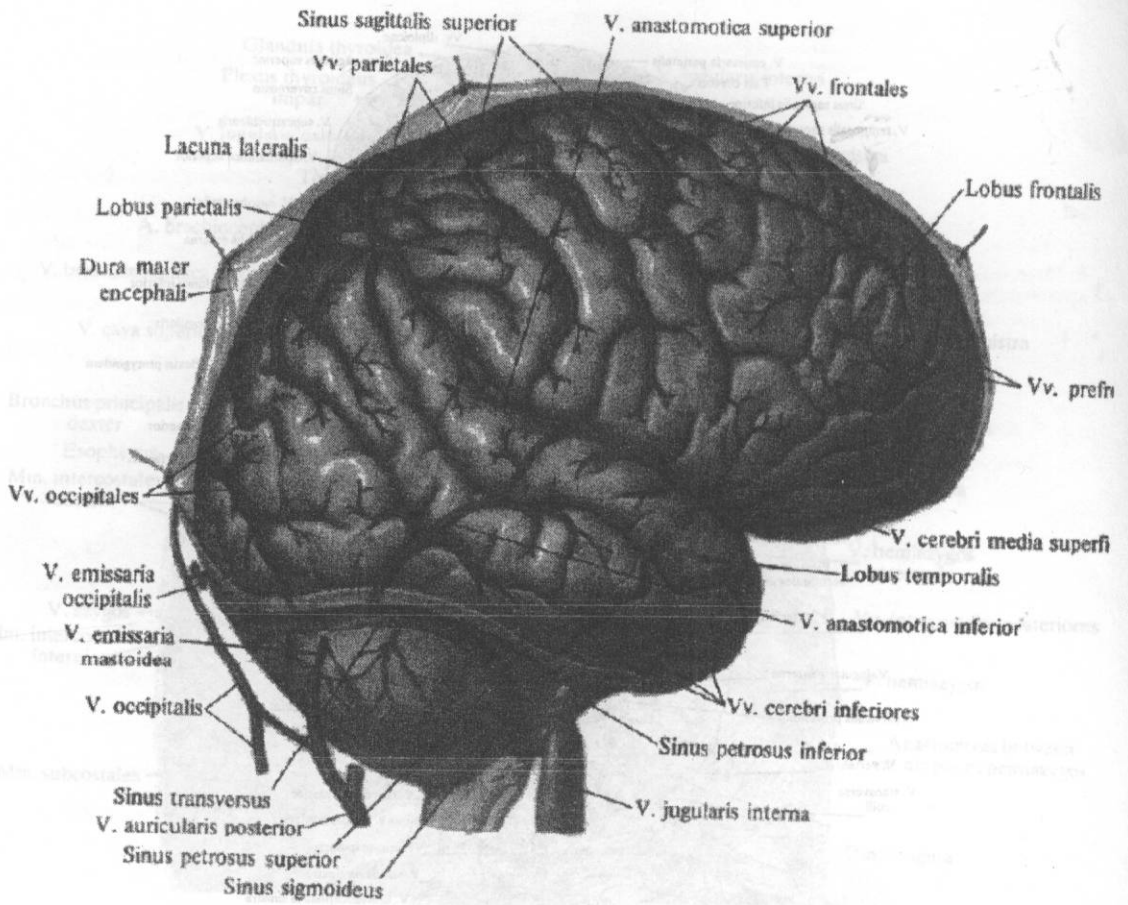


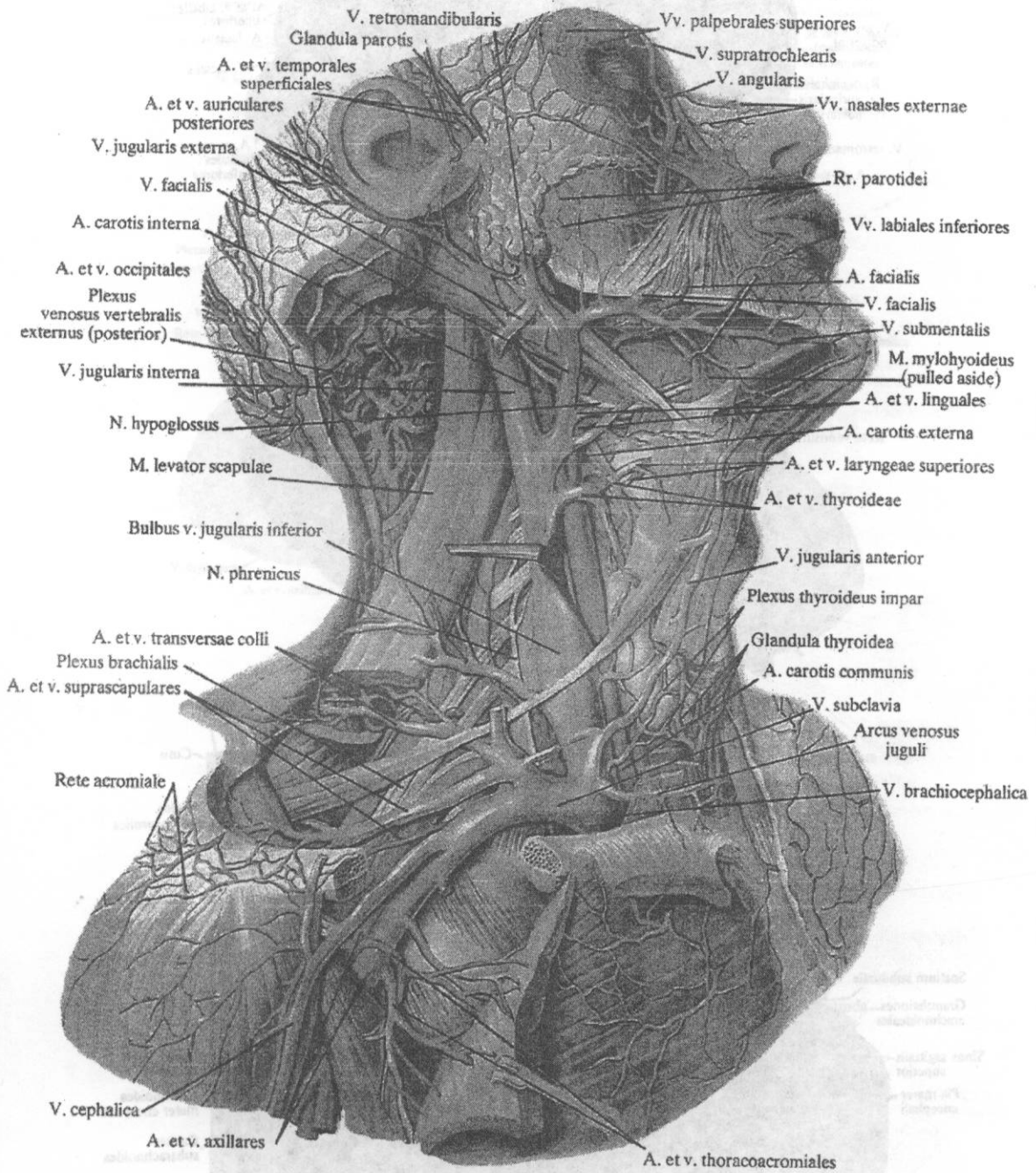


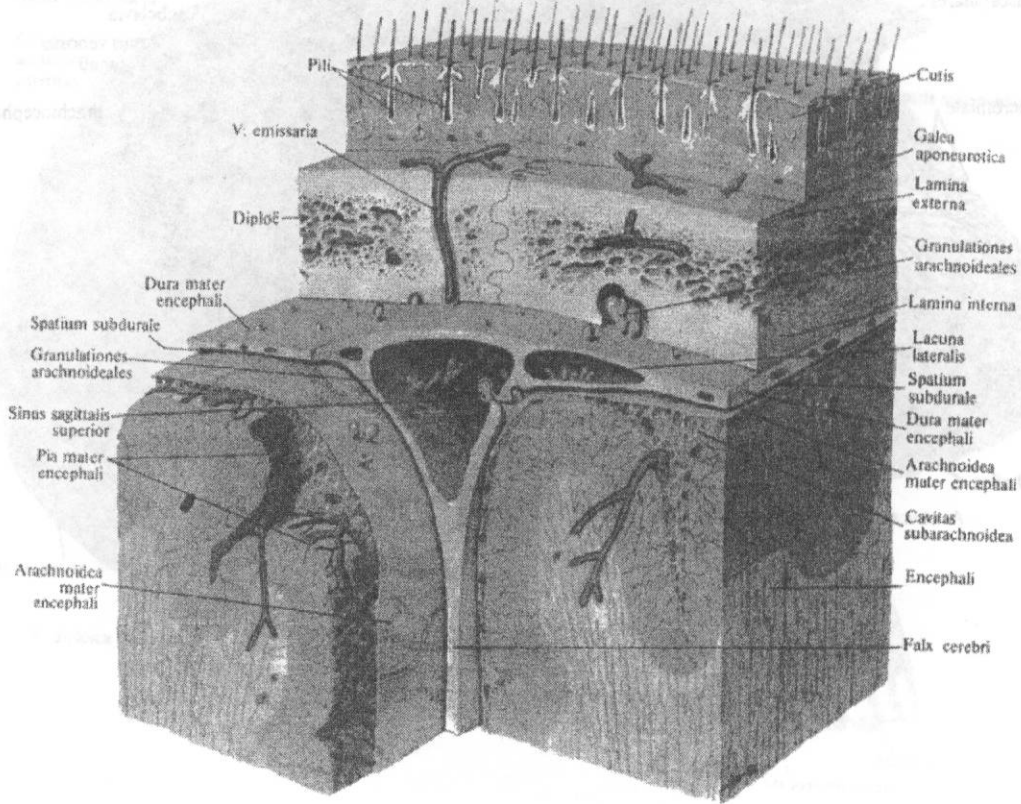
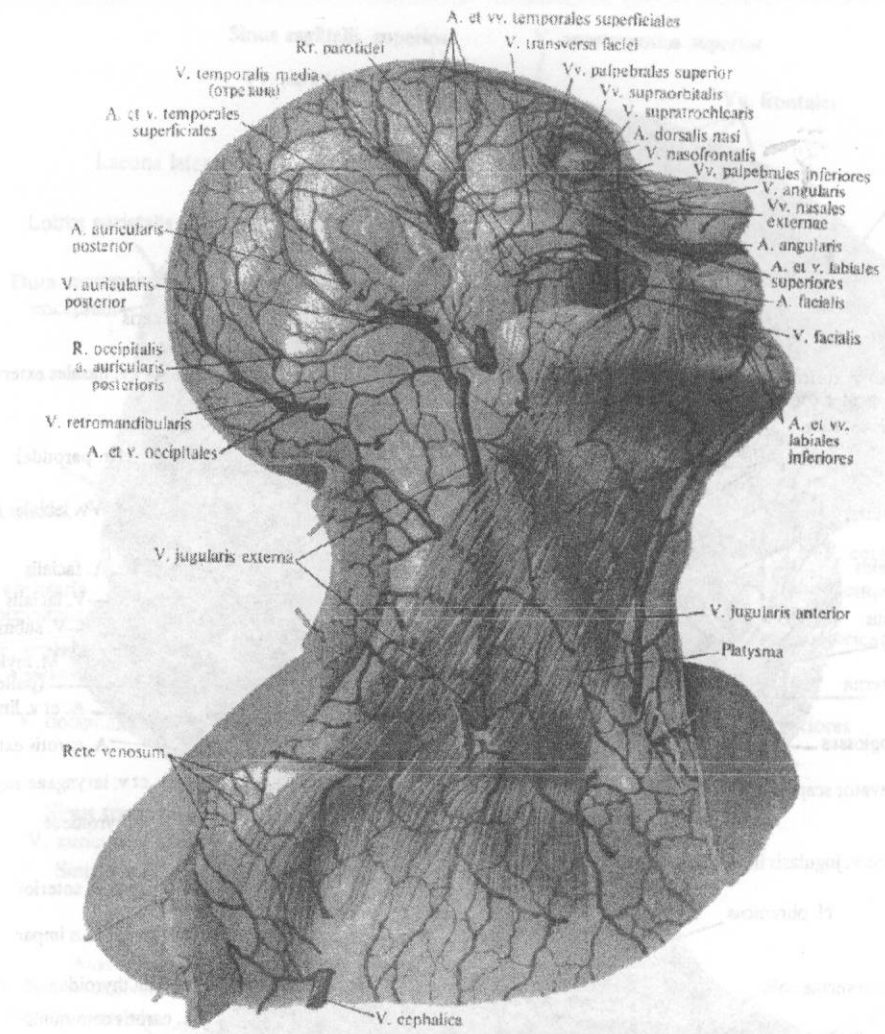


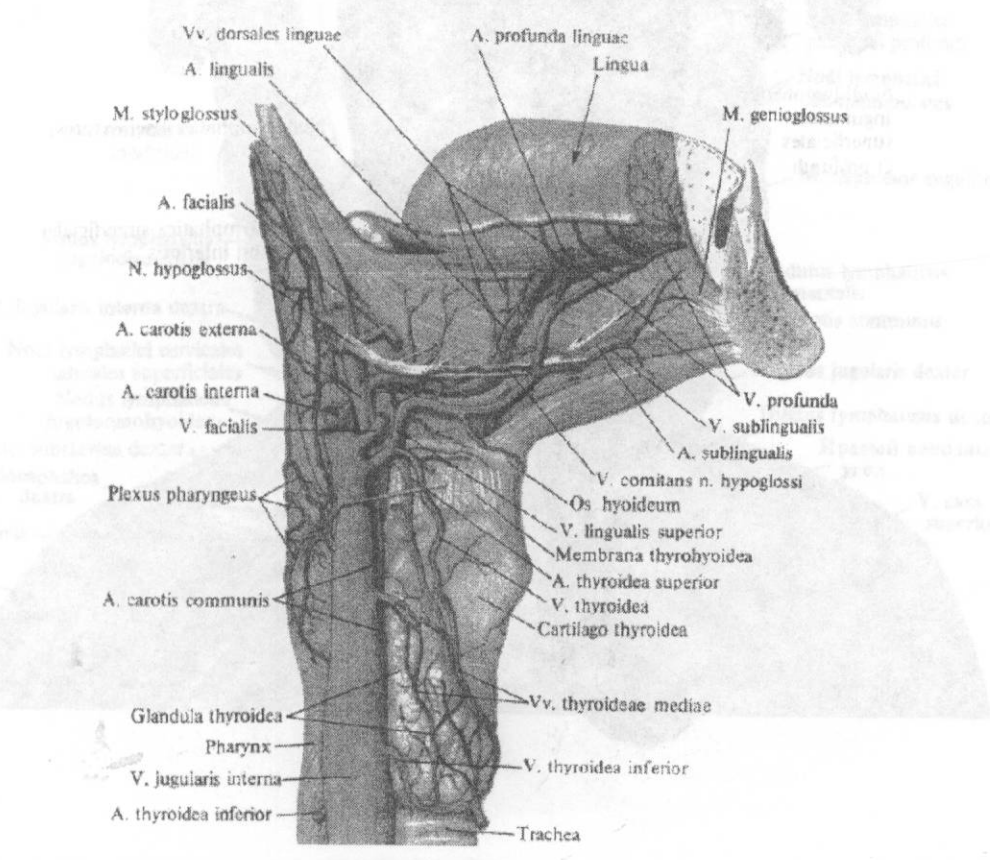
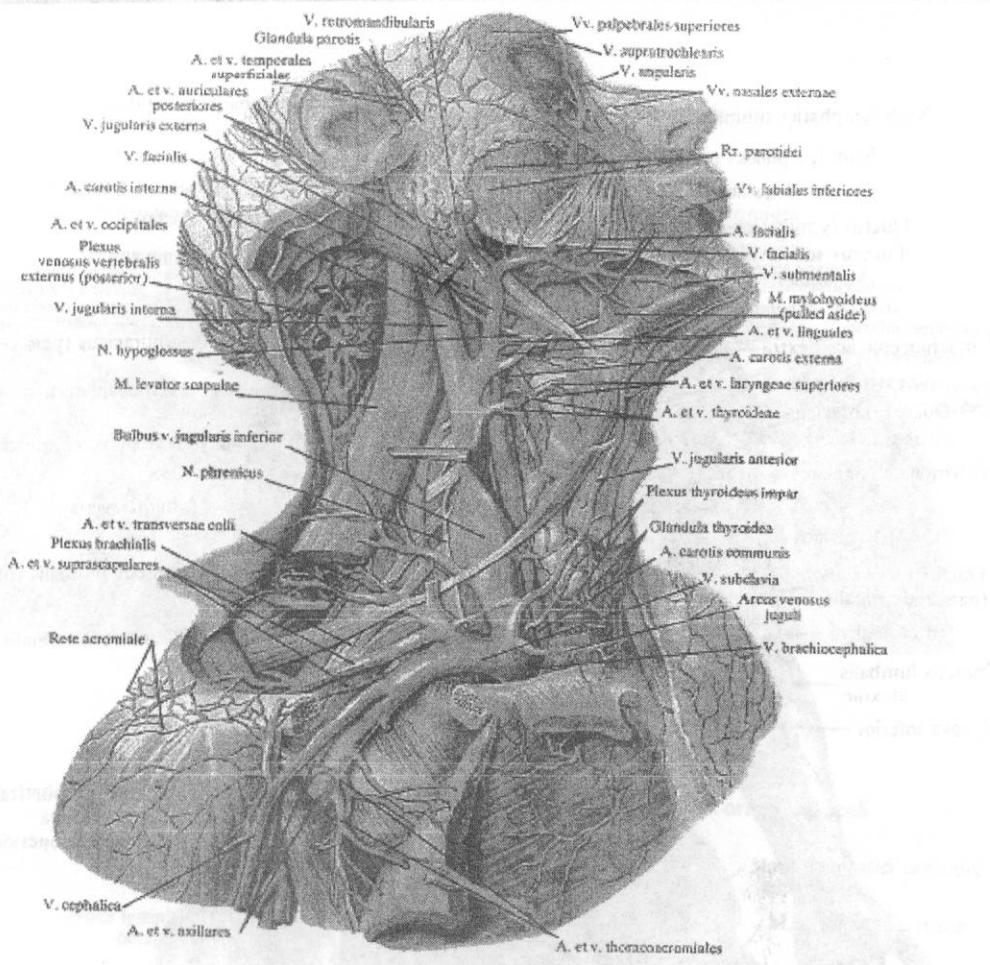


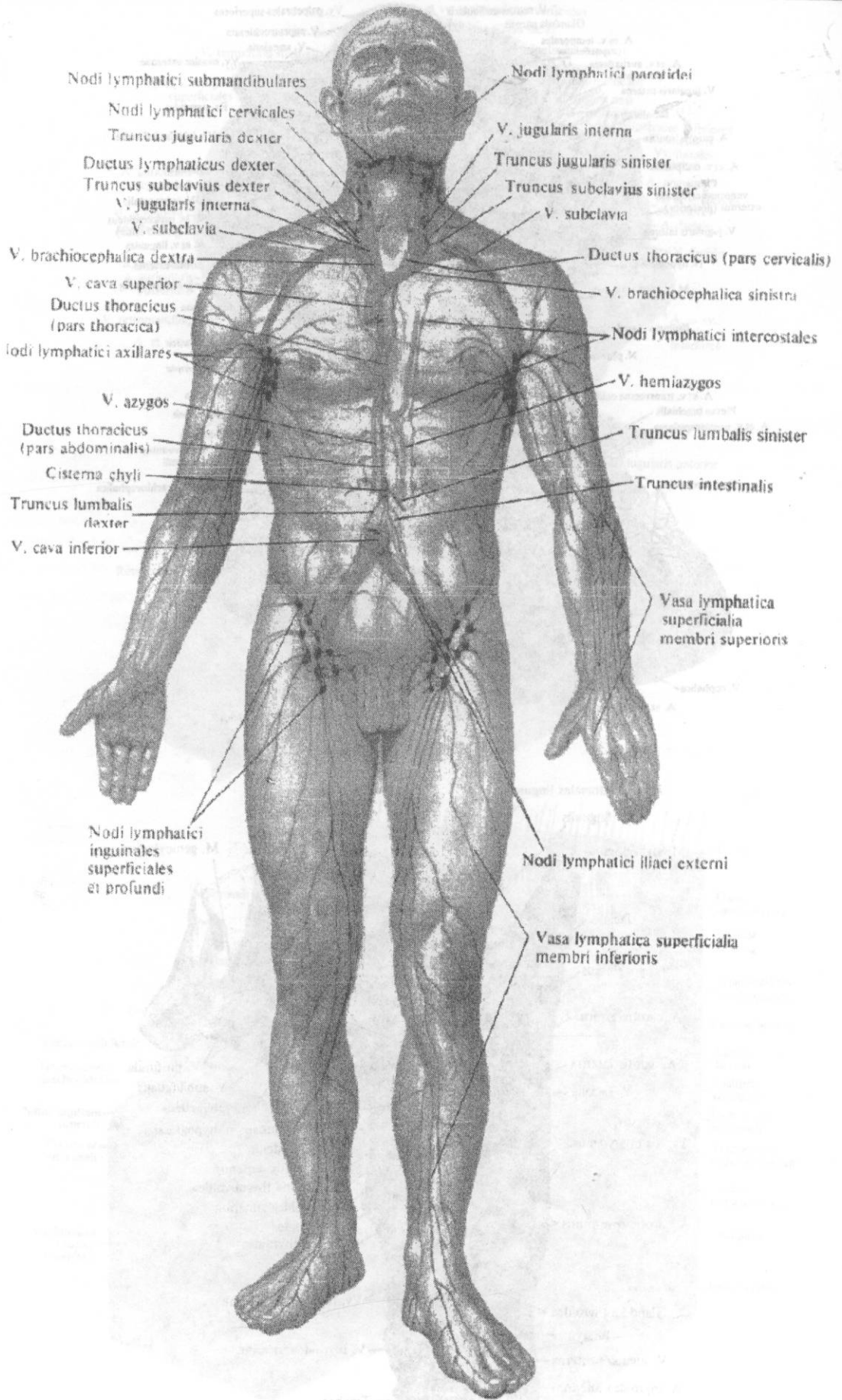


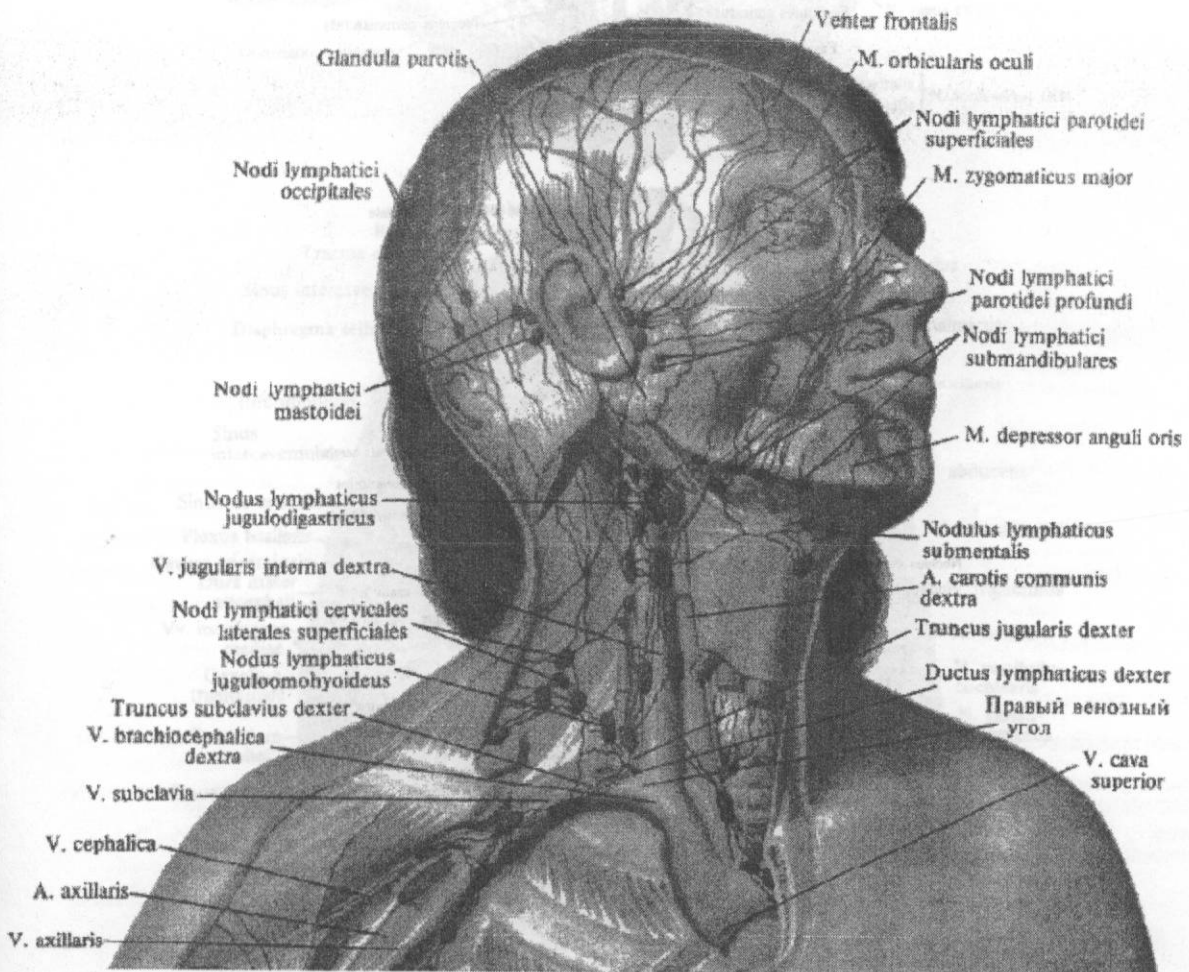
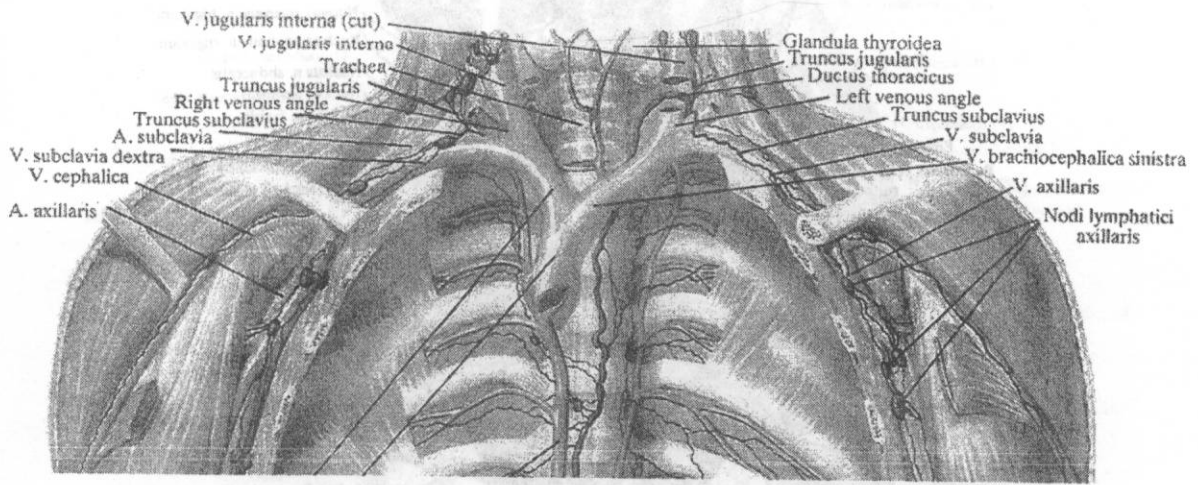


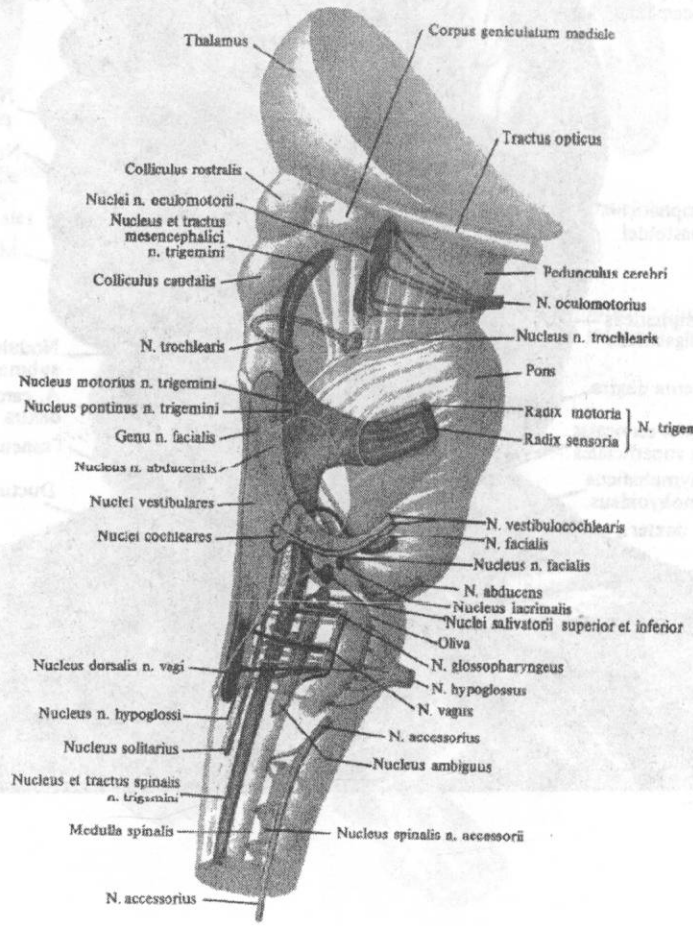
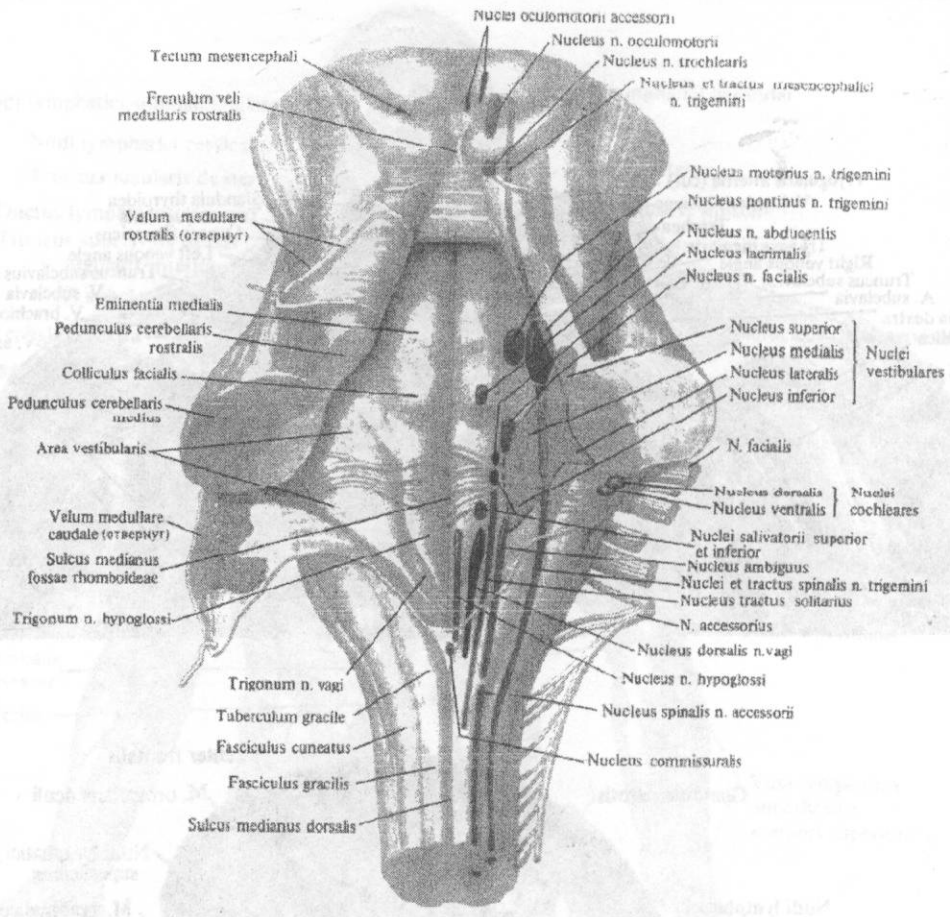


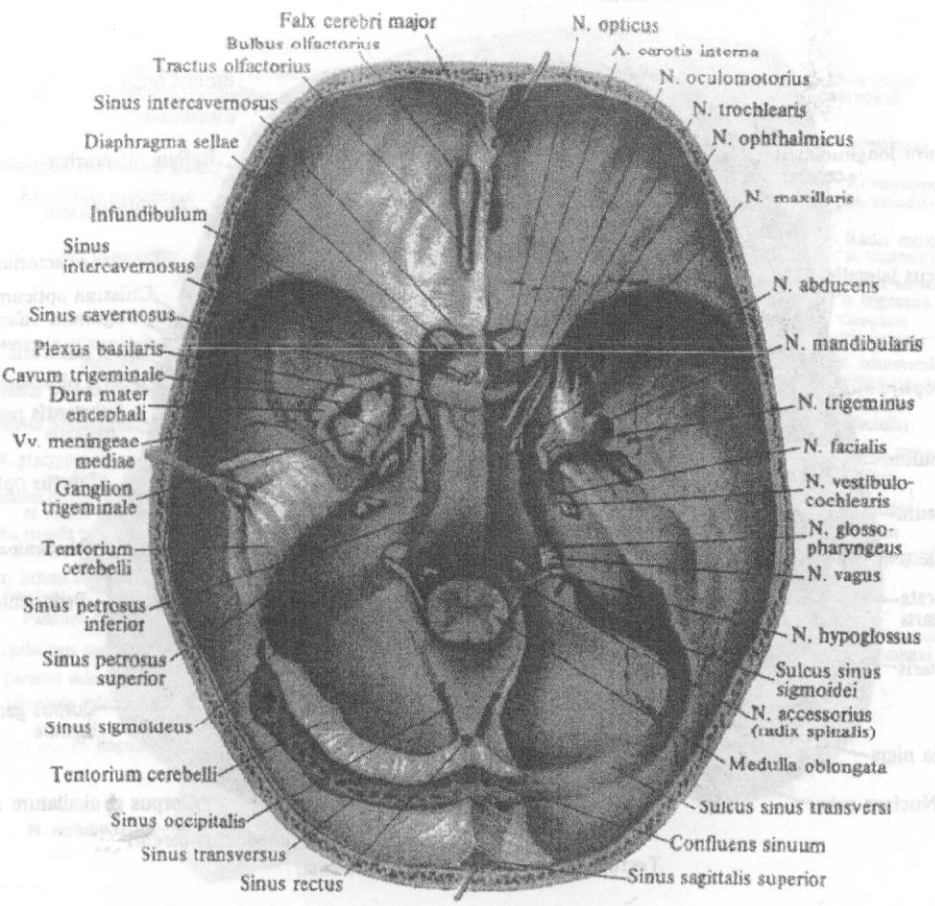
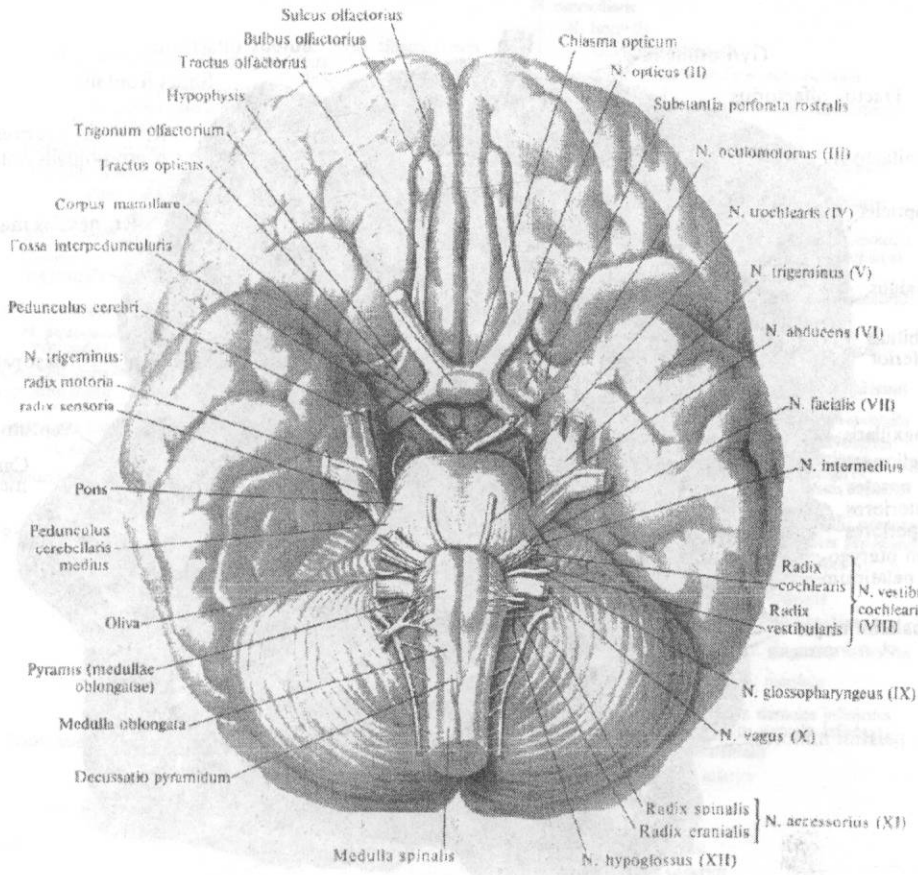


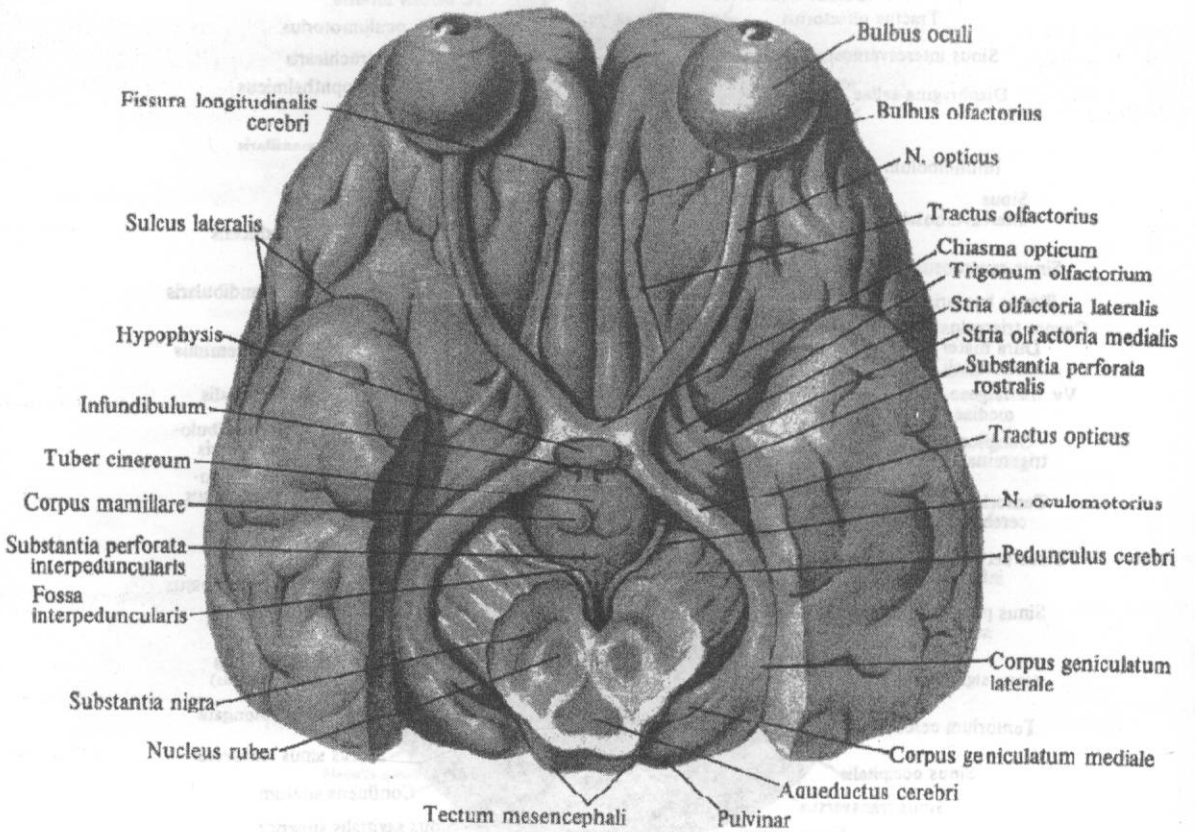
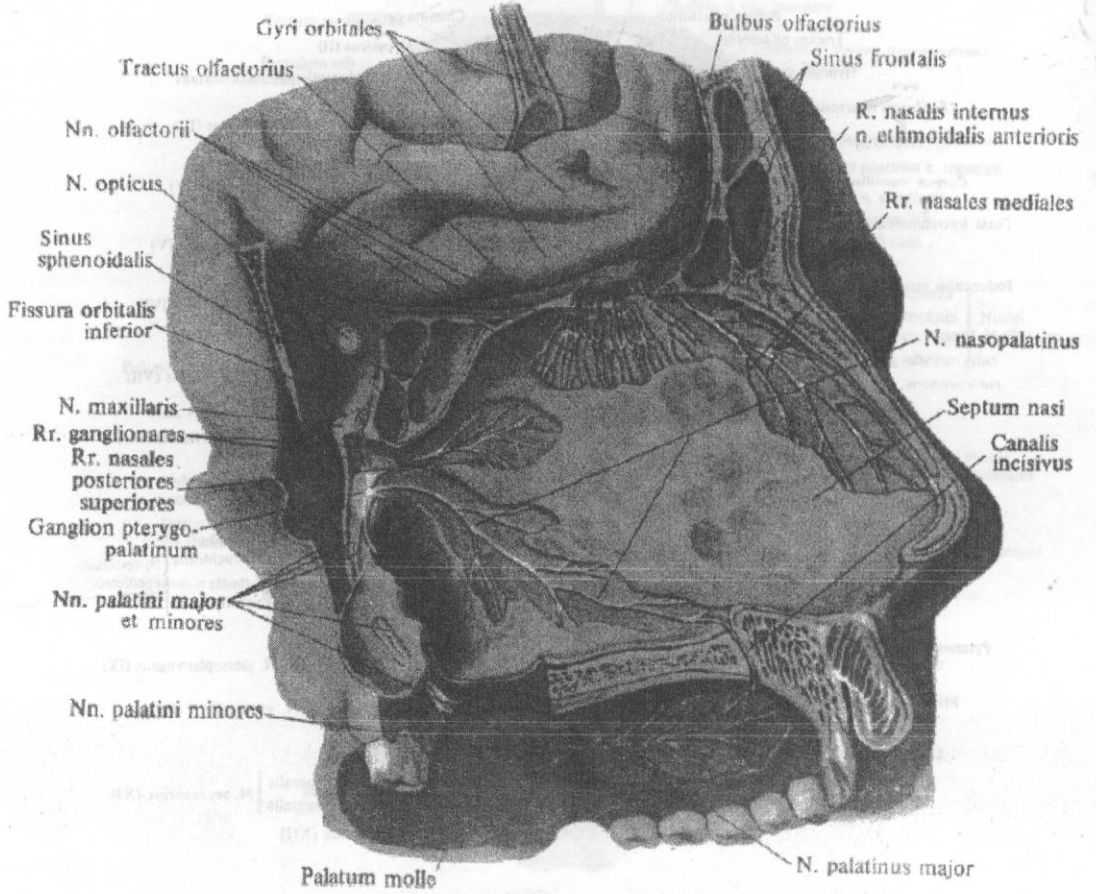


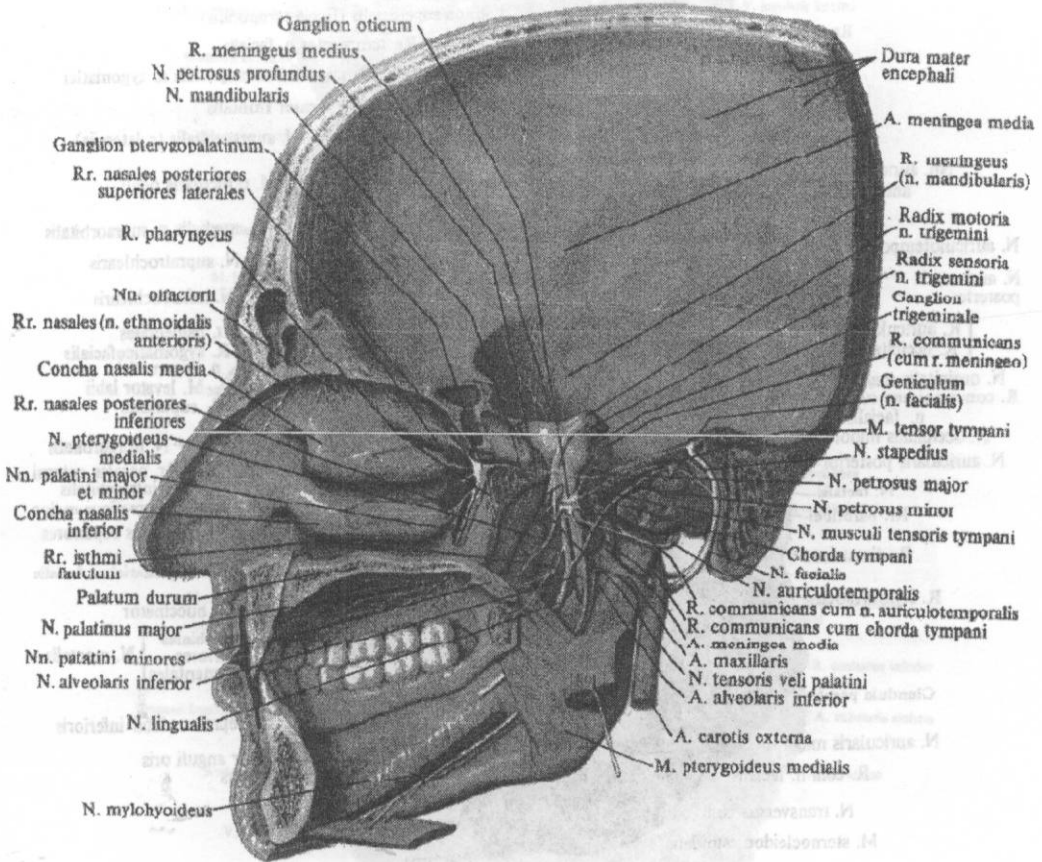
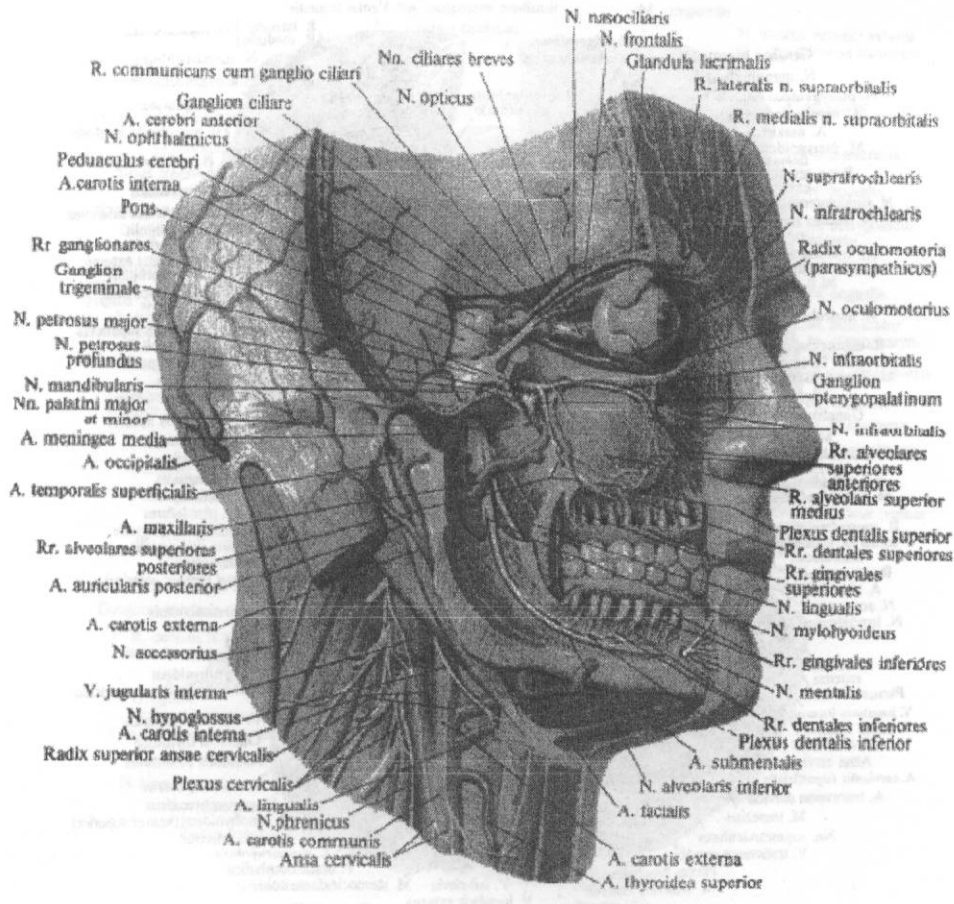


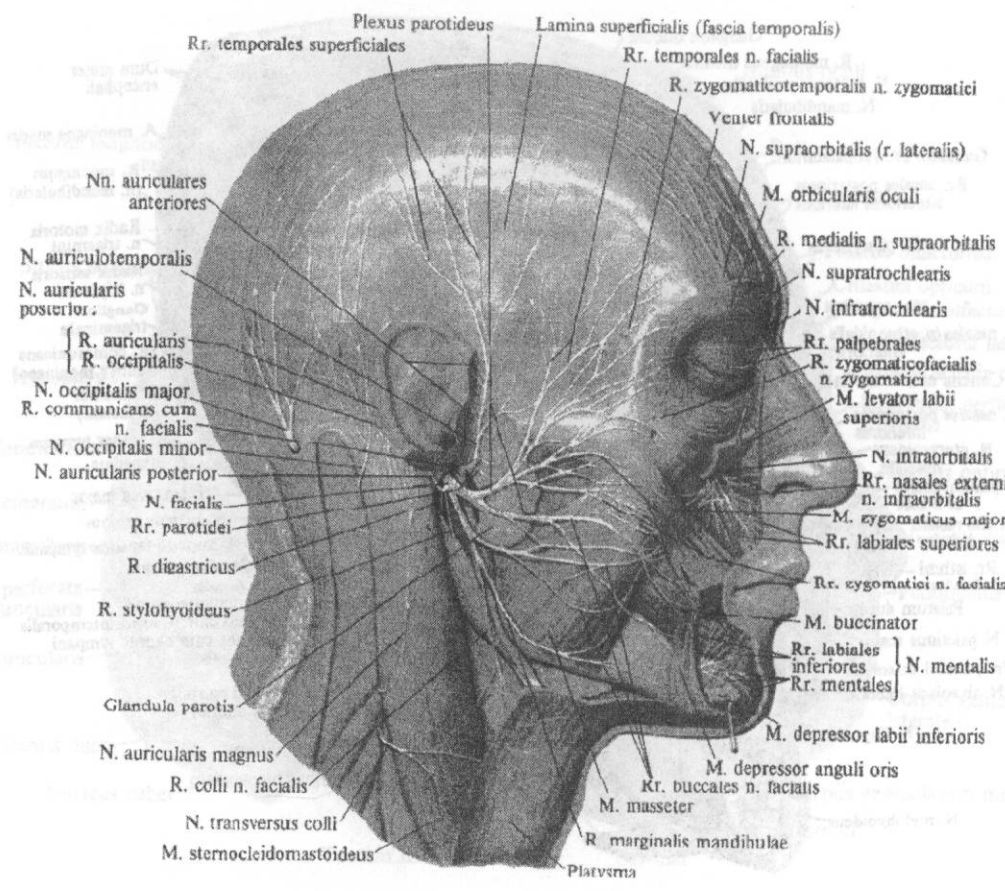
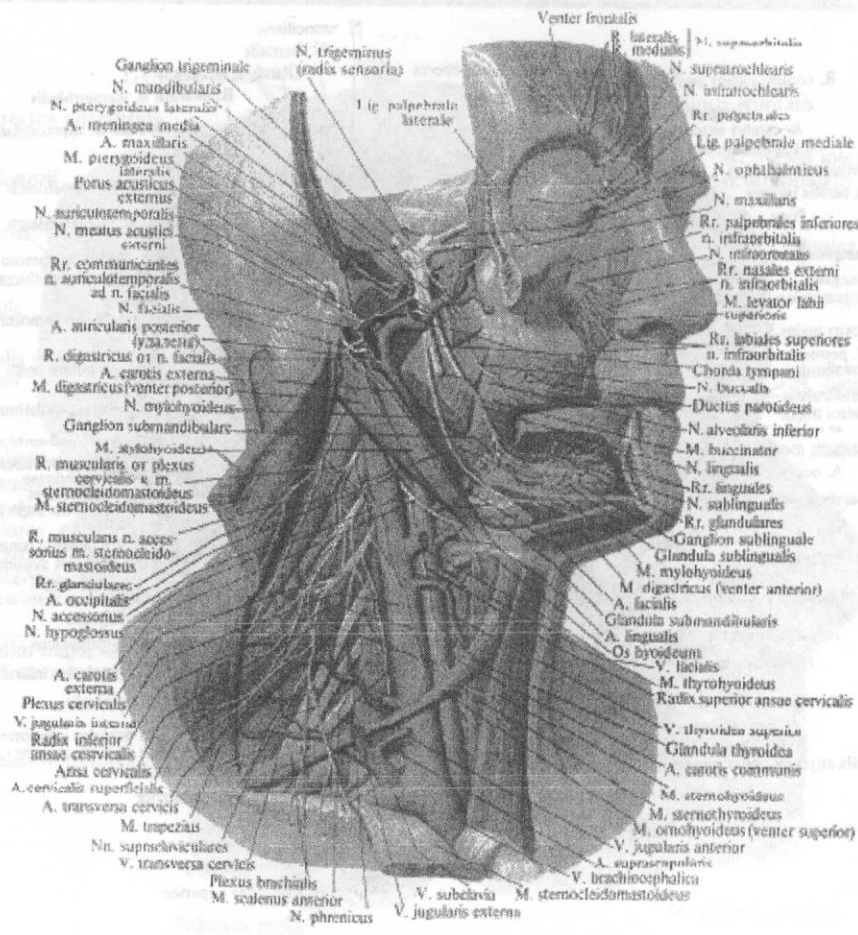


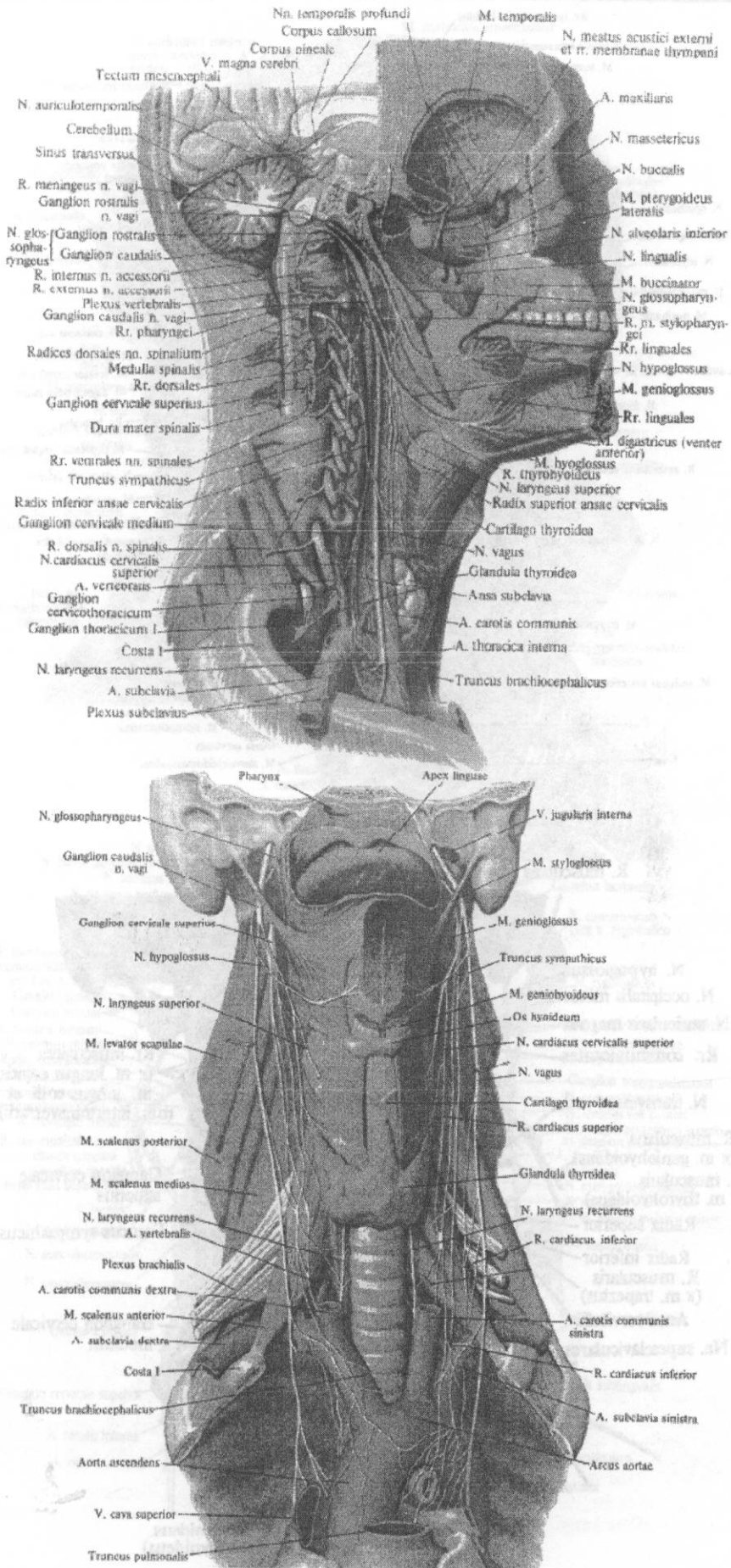


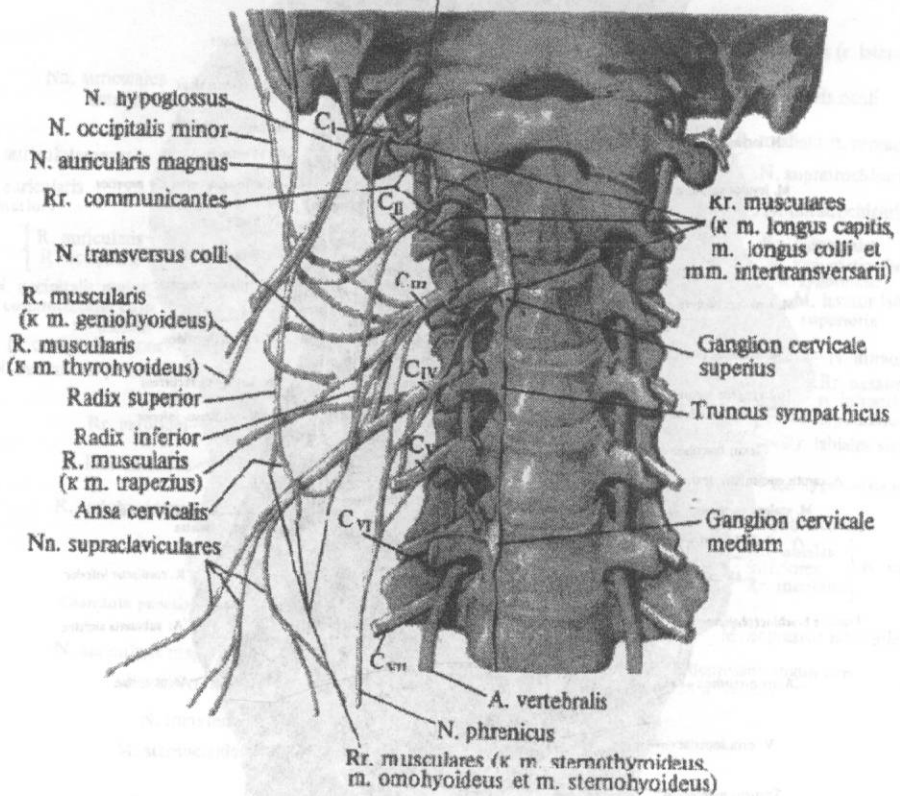
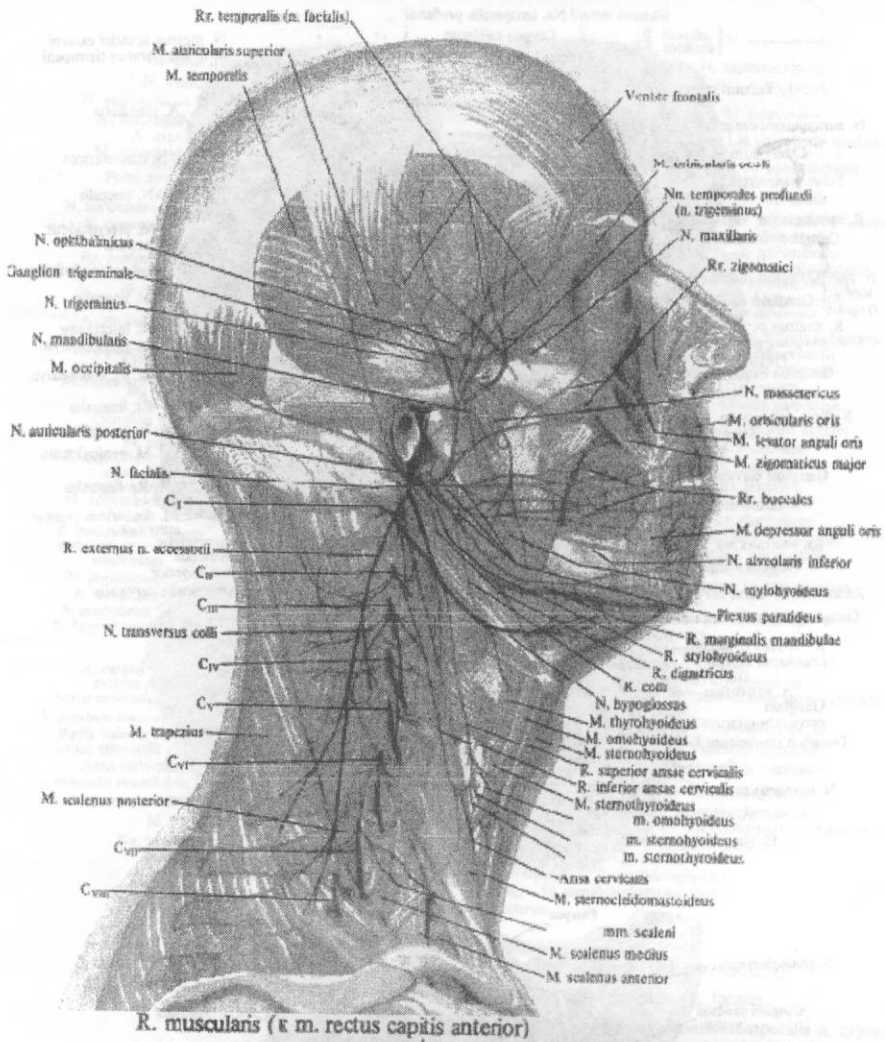


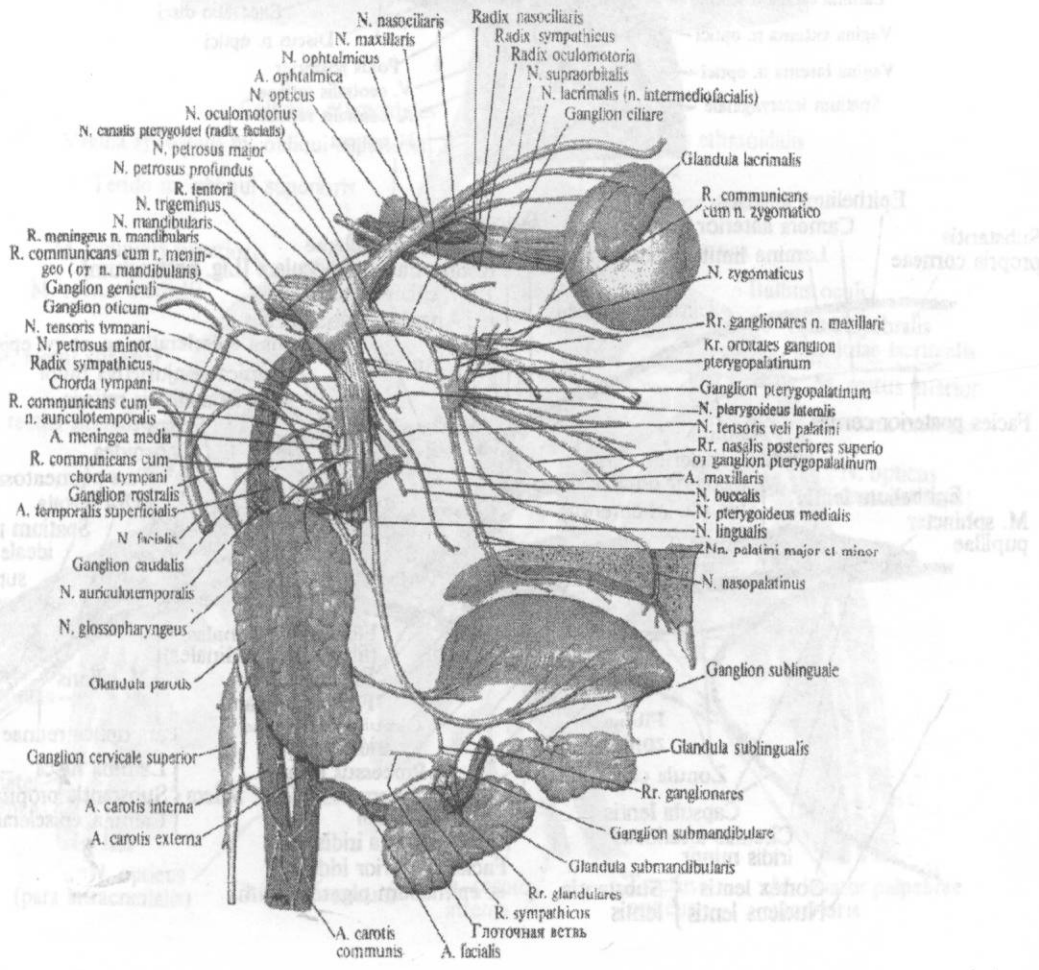
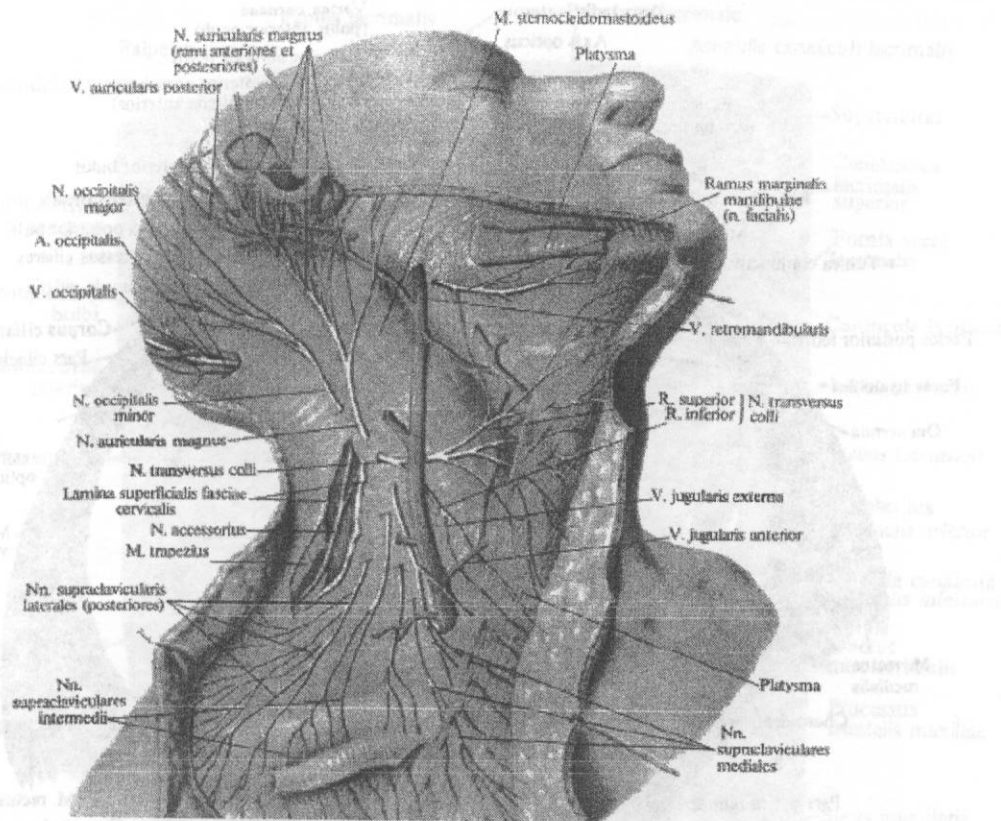


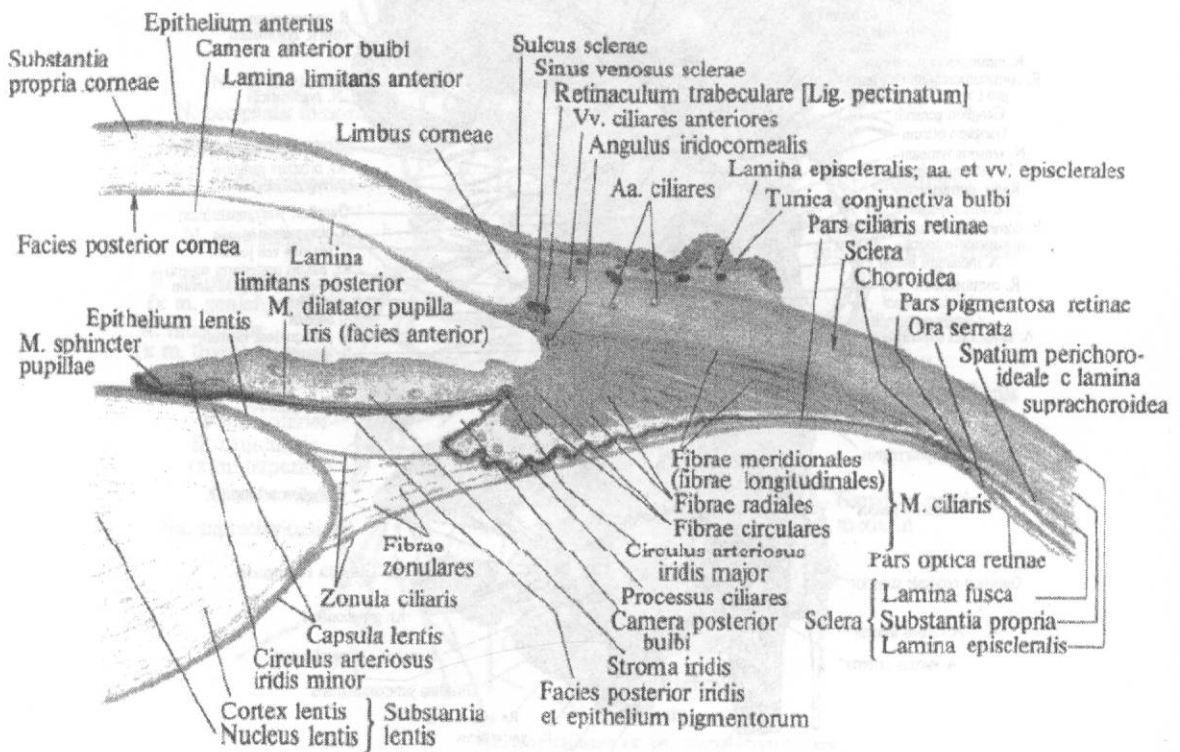
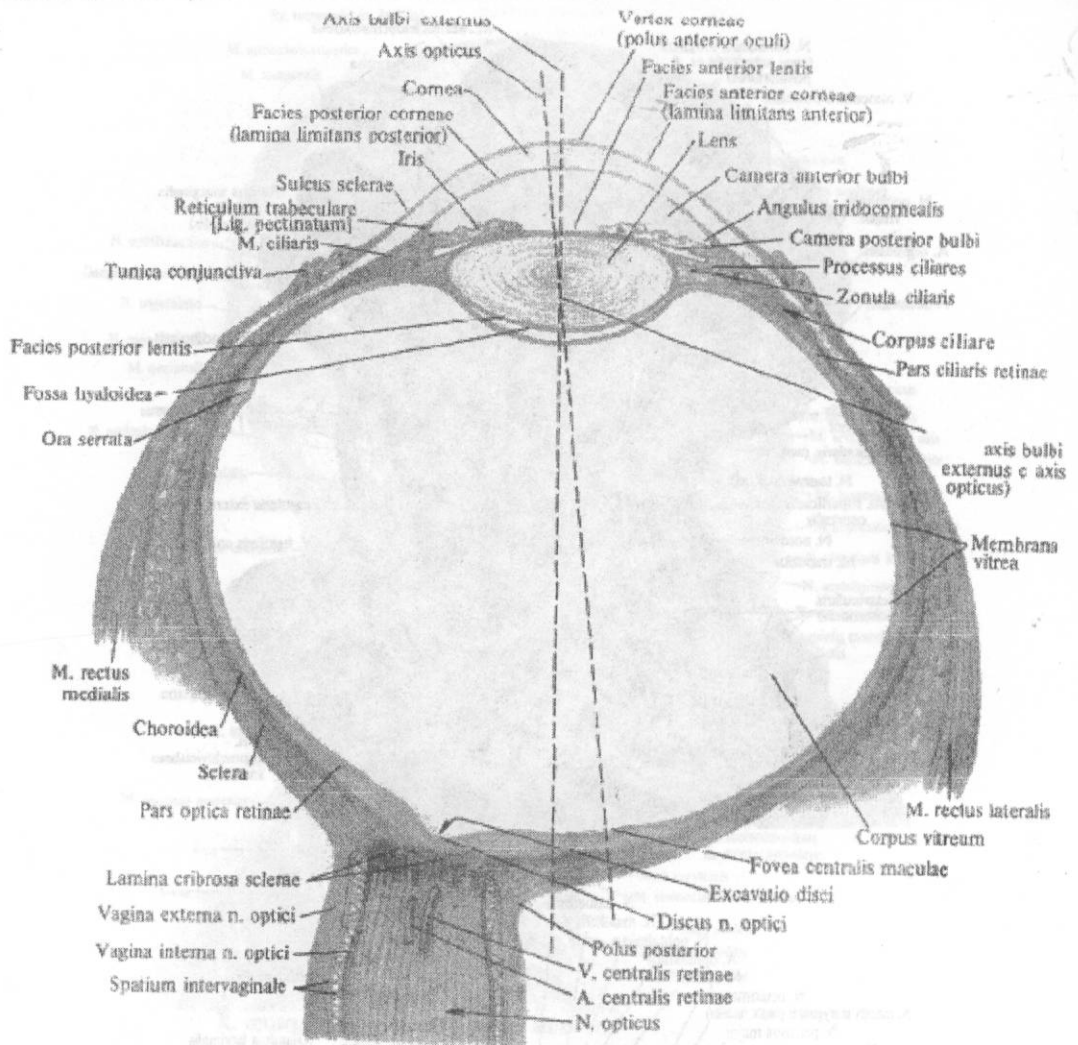


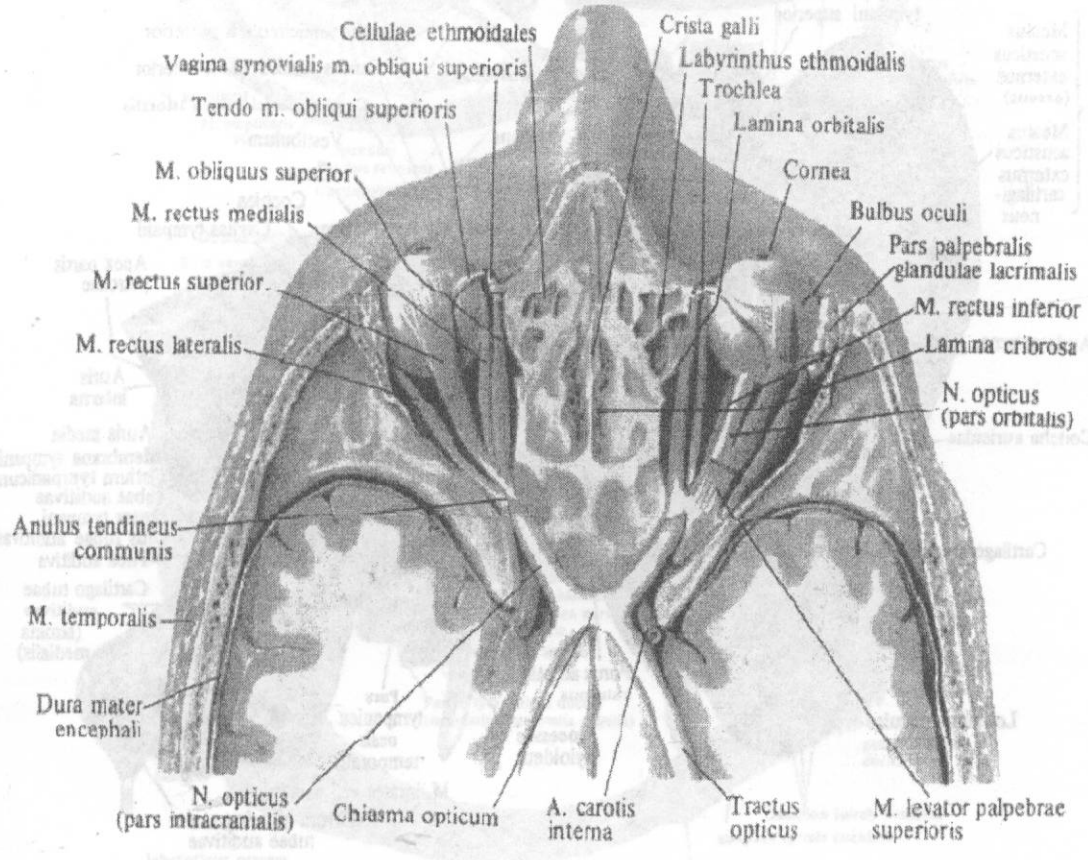
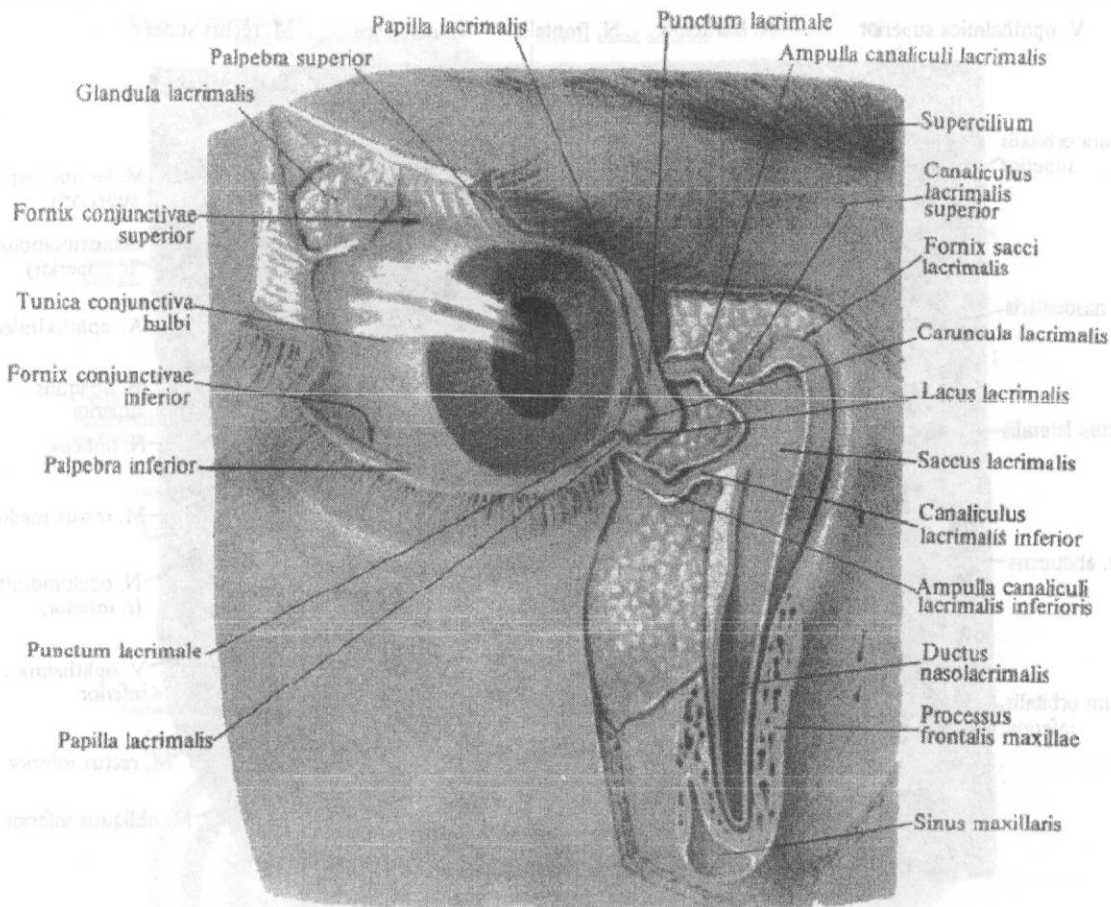


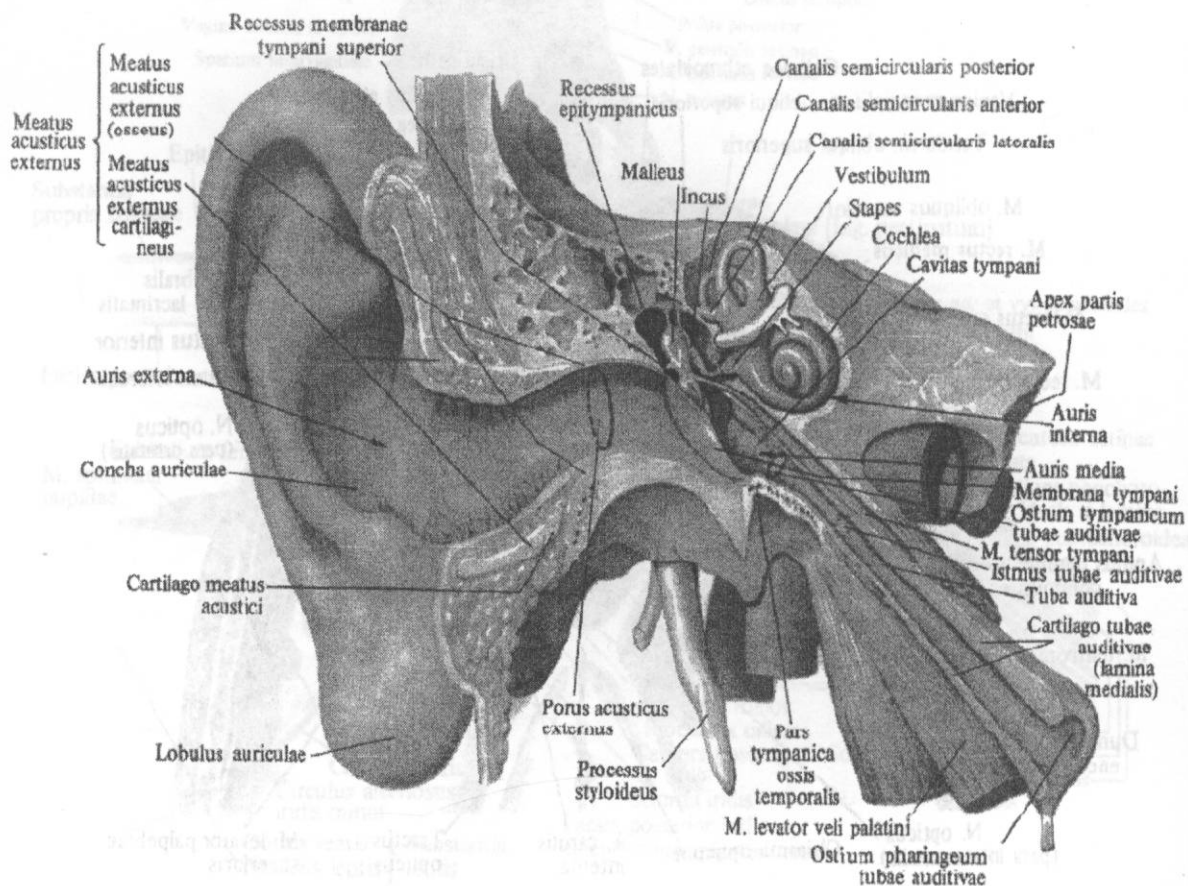
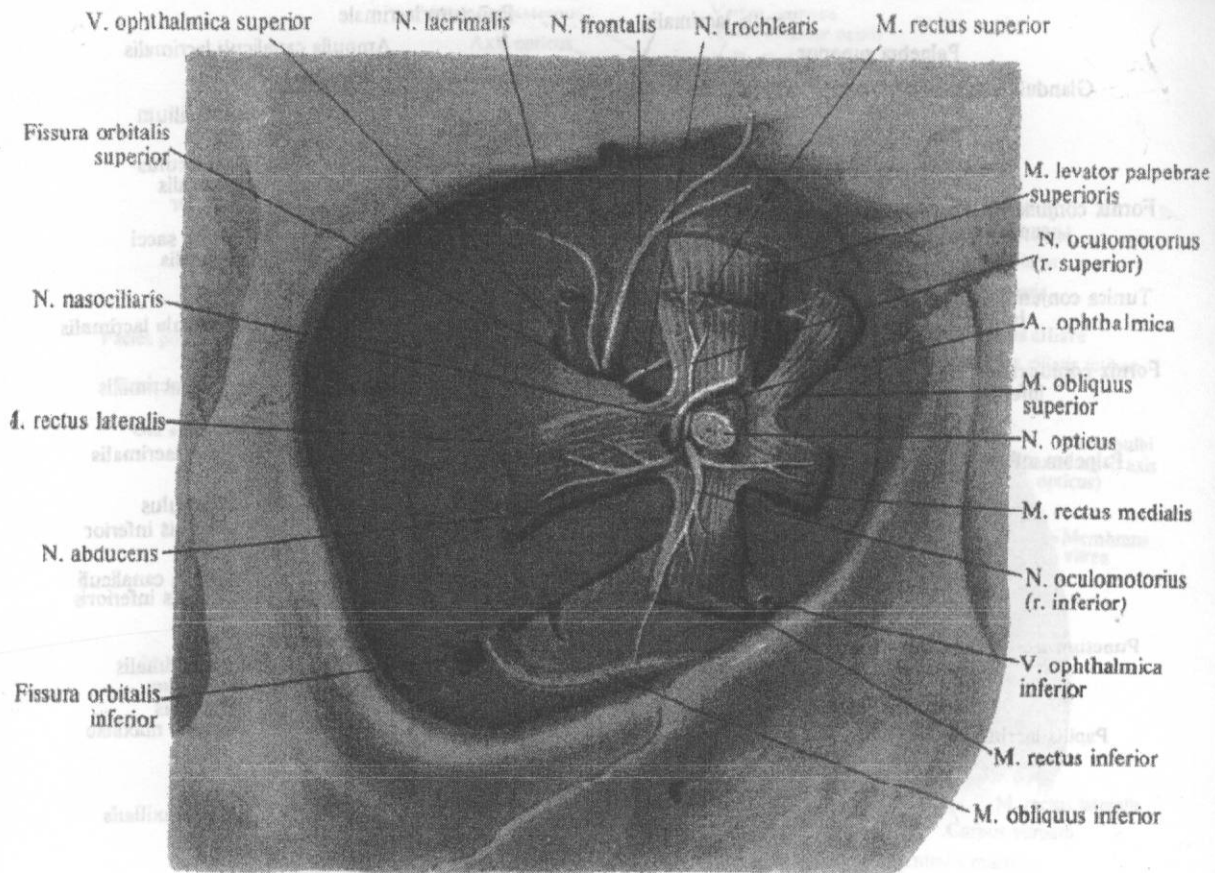


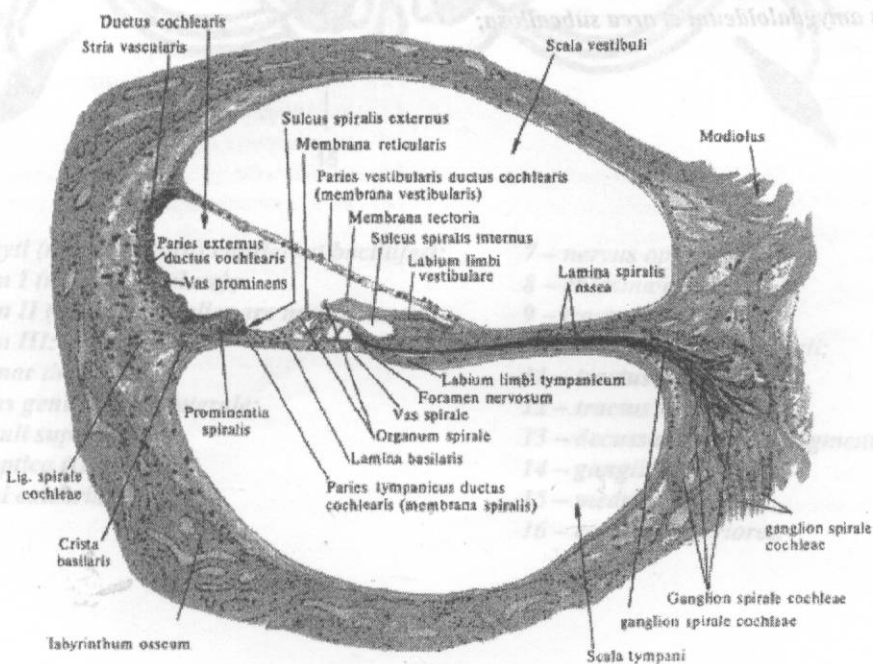
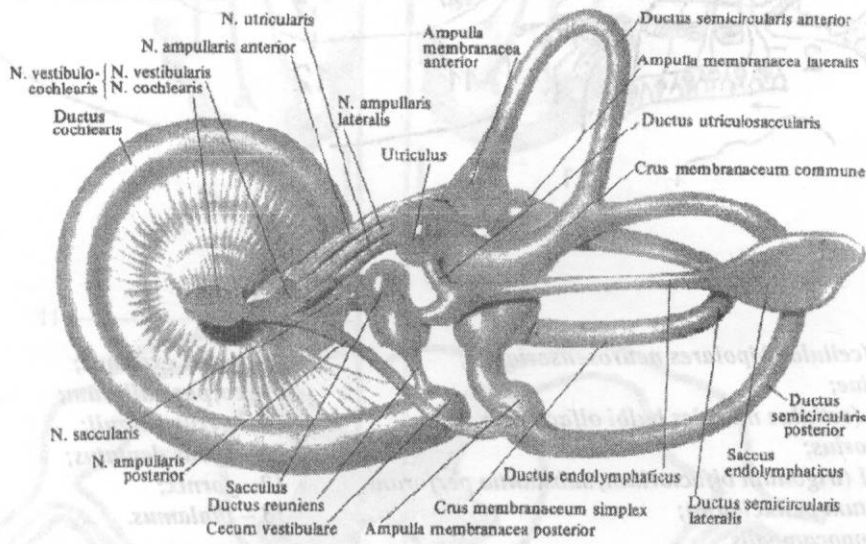
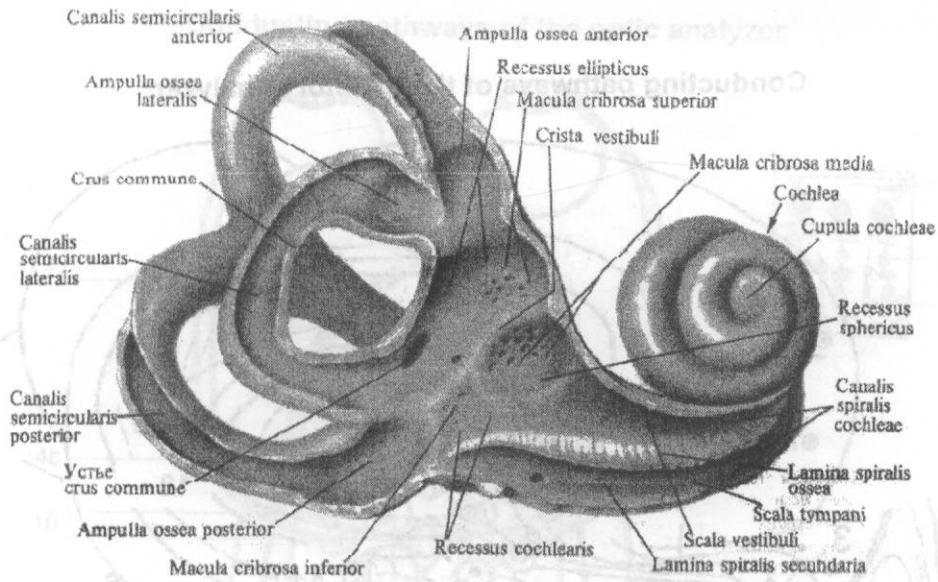




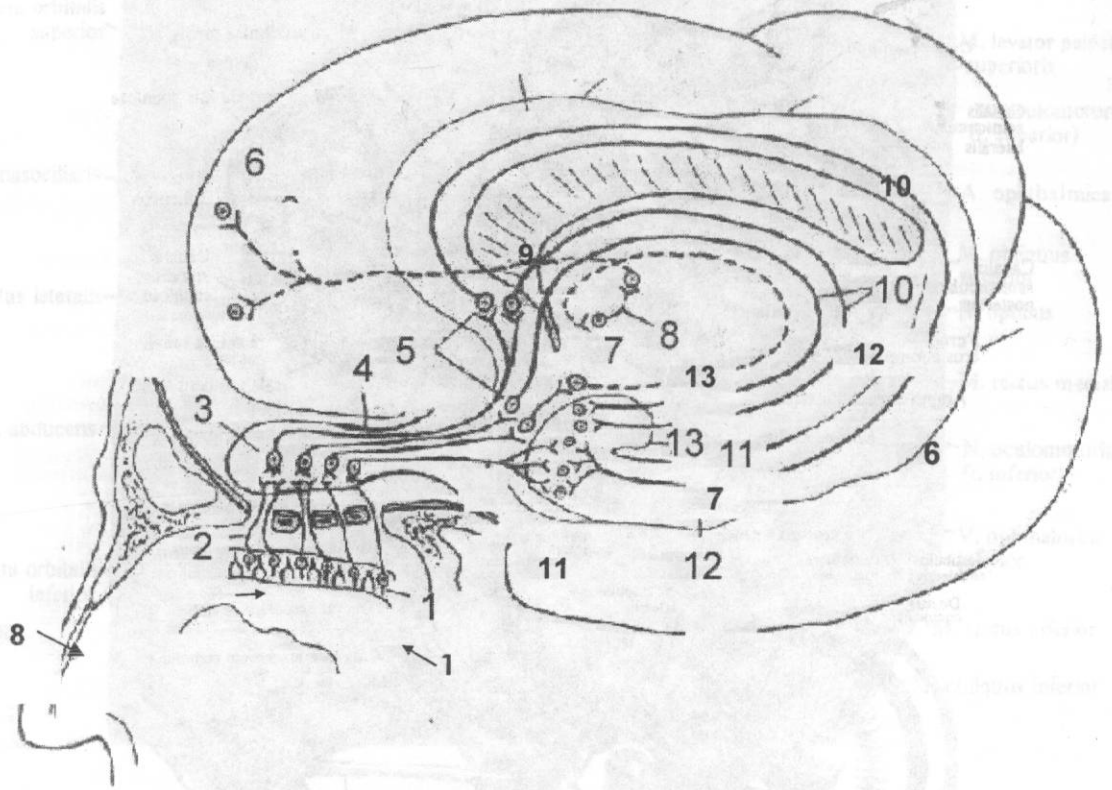








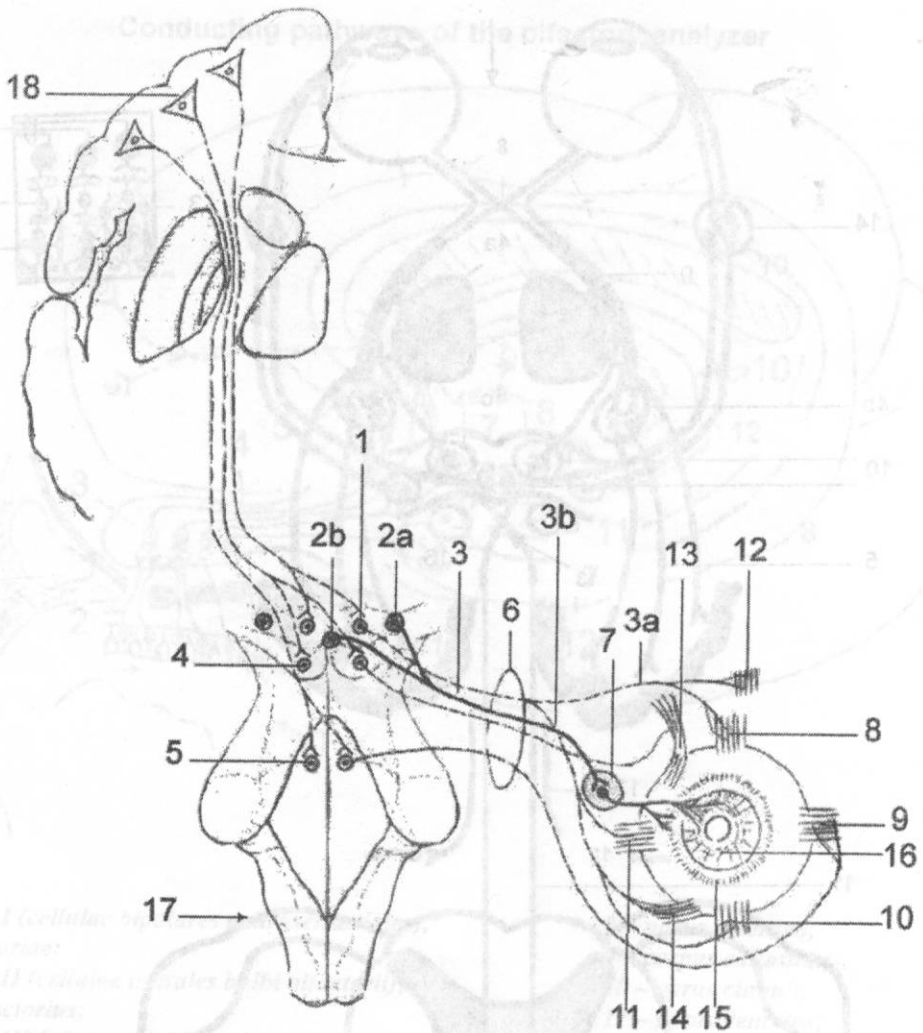
Conducting pathways of the olfactory analyzer



- 1 – neuronum I (cellulae bipolares neurosensoriales);
- 2 – filae olfactoriae;
- 3 – neuronum II (cellulae mitrales bulbi olfactorii);
- 4 – tractus olfactorius;
- 5 – neuronum III (trigonum olfactorium, substantia perforata anterior, septum pellucidum);
- 6 – gyrus parahippocampalis;
- 7 – uncus, corpus amygdaloideum et area subcallosa;

- 8 – nasus externus;
- 9 – corpus callosum;
- 10 – gyrus cinguli;
- 11 – gyrus dentatus;
- 12 – fornix;
- 13 – thalamus.

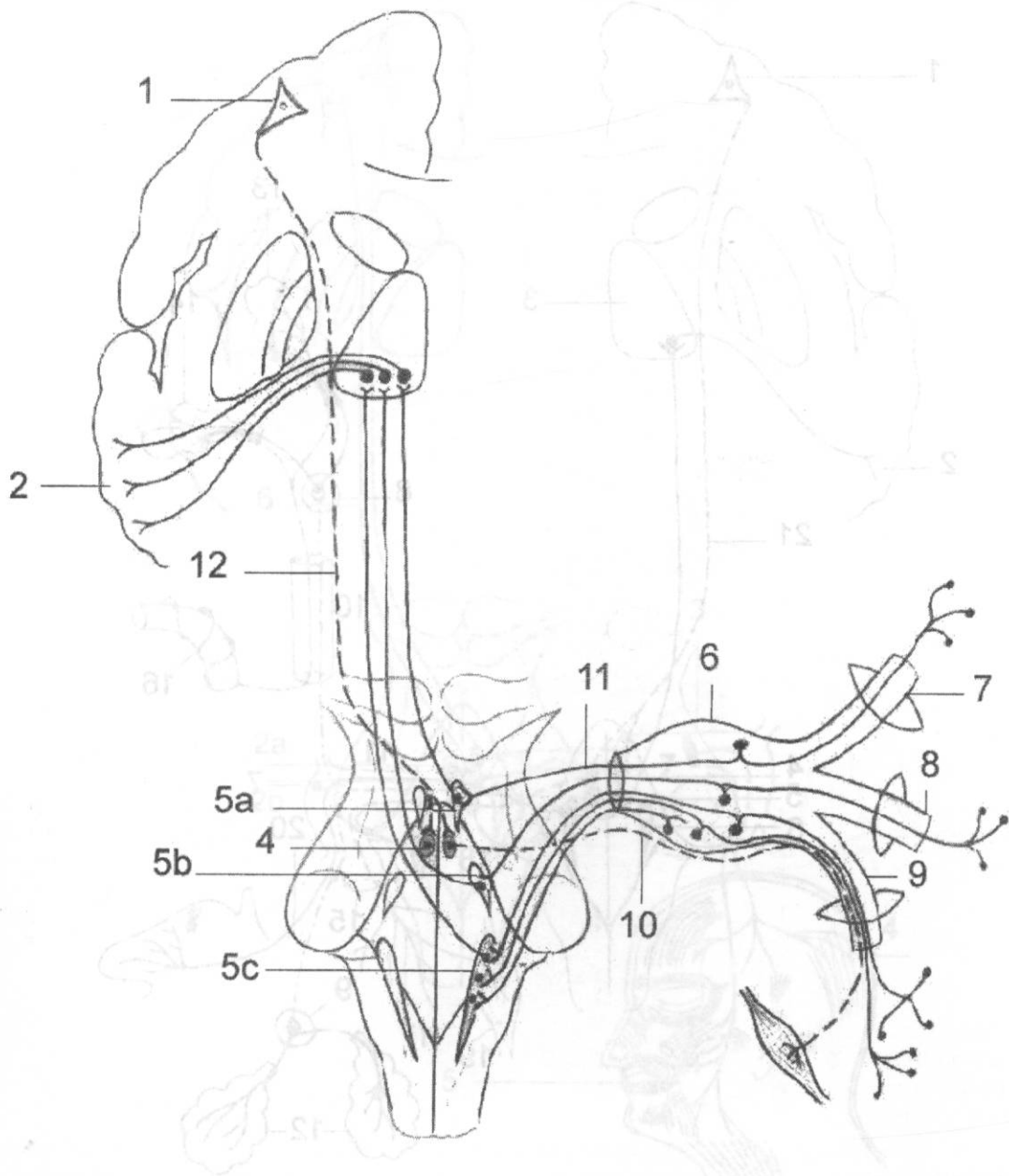
Innervation of the muscles of the eyeball



- 1 – nucl. n. oculomotorii (III);
- 2a – n. accessorius (Якубович-Edinger-Westfal);
- 2b – nucleus impar (Perl) (III);
- 3 – nervus oculomotorius;
- 3a – ramus superior;
- 3b – ramus inferior;
- 4 – nucl.n. trochlearis (IV);
- 5 – nucl.n. abducentis (VI);
- 6 – fissura orbitalis superior;
- 7 – ganglion ciliare;
- 8 – m. rectus superior;

- 9 – m. rectus lateralis;
- 10 – m. rectus inferior;
- 11 – m. rectus medialis;
- 12 – m. levator palpebrae superioris;
- 13 – m. obliquus superior;
- 14 – m. obliquus inferior;
- 15 – m. ciliaris;
- 16 – m. sphincter pupillae;
- 17 – truncus cerebri;
- 18 – neurocytus pyramidalis magnus (Betz).

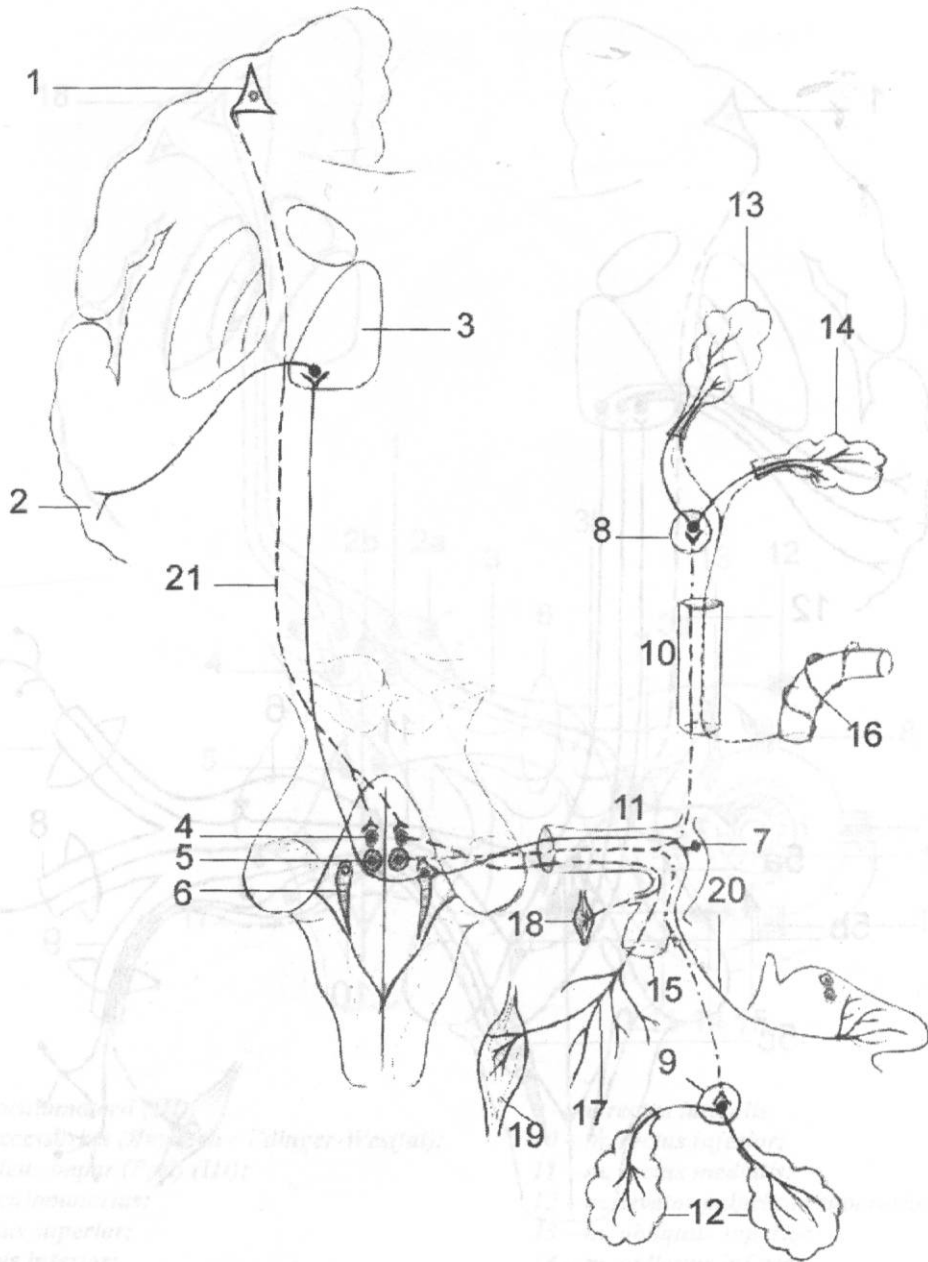
Conducting pathways of the trigeminal nerve (V)



- 1 – neuronum I (neocytus pyramidalis magnus, Betz) (gyrus precentralis);
 2 – gyrus postcentralis;
 3 – neuronum III (thalamus opticus);
 4 – nucl. n. trigemini (V);
 5 – nuclei sensoriales n. trigemini (V);
 5a – nucl. mesencephalicus n. trigemini (V);
 5b – nucl. pontinus (V);
 5c – nucl. spinalis nervi trigemini (V);

- 6 – ganglion trigeminale (Gasser);
 7 – n. ophthalmicus;
 8 – n. maxillaris;
 9 – n. mandibularis;
 10 – radix motoria n. trigemini;
 11 – radix sensoria n. trigemini;
 12 – tractus corticonuclearis.

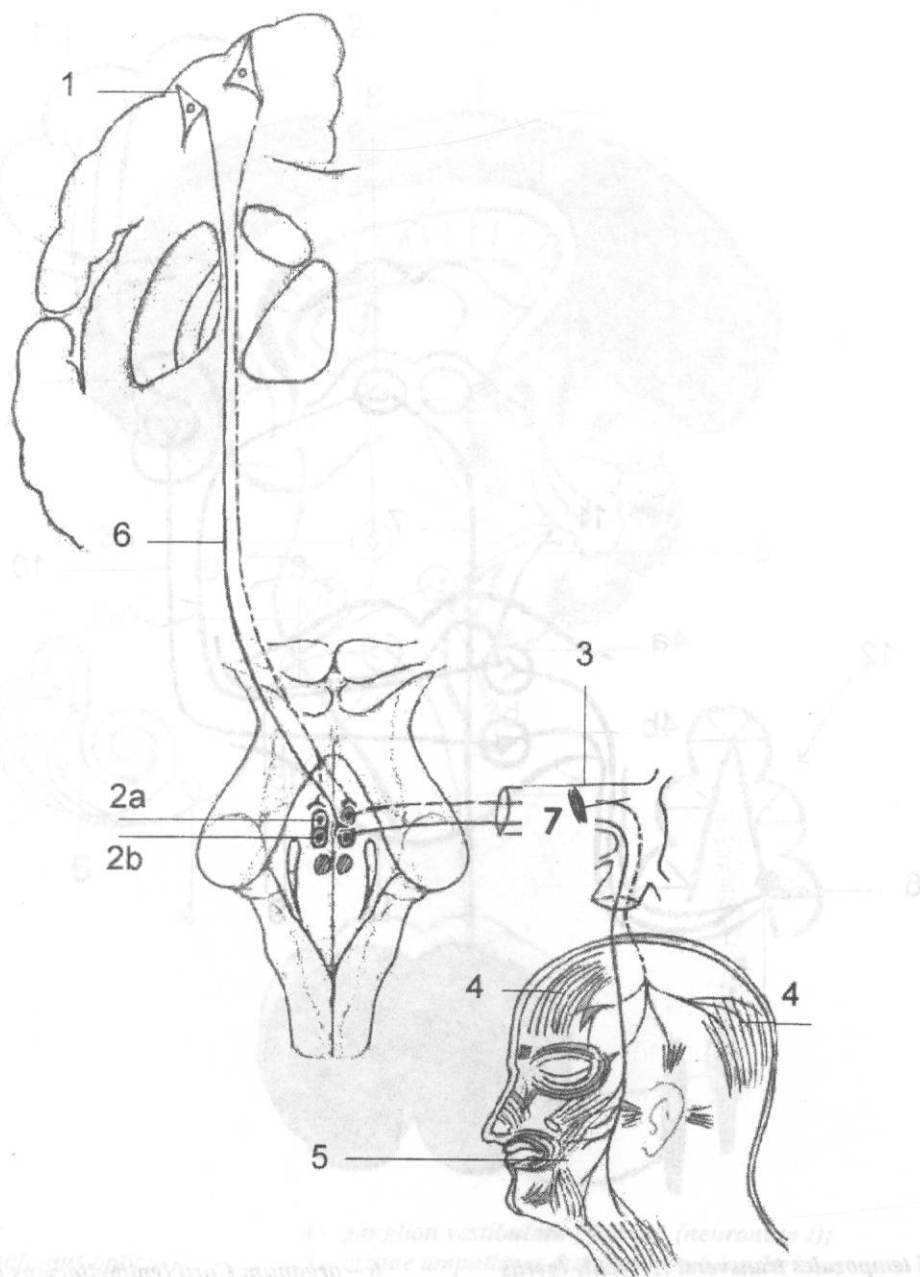
Conducting pathways of the facial nerve (VII)



- 1 – neuronum I (neurocytus pyramidalis magnus, Betz) (gyrus precentralis);
- 2 – girus parahipocampalis et uncus;
- 3 – thalamus opticus;
- 4 – nucl. n. facialis (motorius) (neuronum II) (VII);
- 5 – n. salivatorius superior (VII);
- 6 – n. tractus solitarii (VII);
- 7 – ganglion geniculi;
- 8 – ganglion pterygopalatinum;
- 9 – ganglia submandibularia et sublingualia;
- 10 – canalis pterygoideus;

- 11 – canalis n. facialis (Fallopium);
- 12 – glandulae sublingualis et submandibularis;
- 13 – glandula lacrimalis;
- 14 – glandulae nasales;
- 15 – foramen stylomastoideum;
- 16 – plexus caroticus internus;
- 17 – plexus parotideus;
- 18 – m. stapedius;
- 19 – mm. faciei;
- 20 – chorda tympani;
- 21 – tractus corticonuclearis.

Efferent, motor pathways of the facial nerve (VII)



1 – neuronum I (neurocytus pyramidalis magnus, Betz) (girus precentralis);

2 – neuronum II (nucl. n. facialis, motorius) (VII);

2a – pars superior;

2b – pars inferior;

3 – canalis n. facialis;

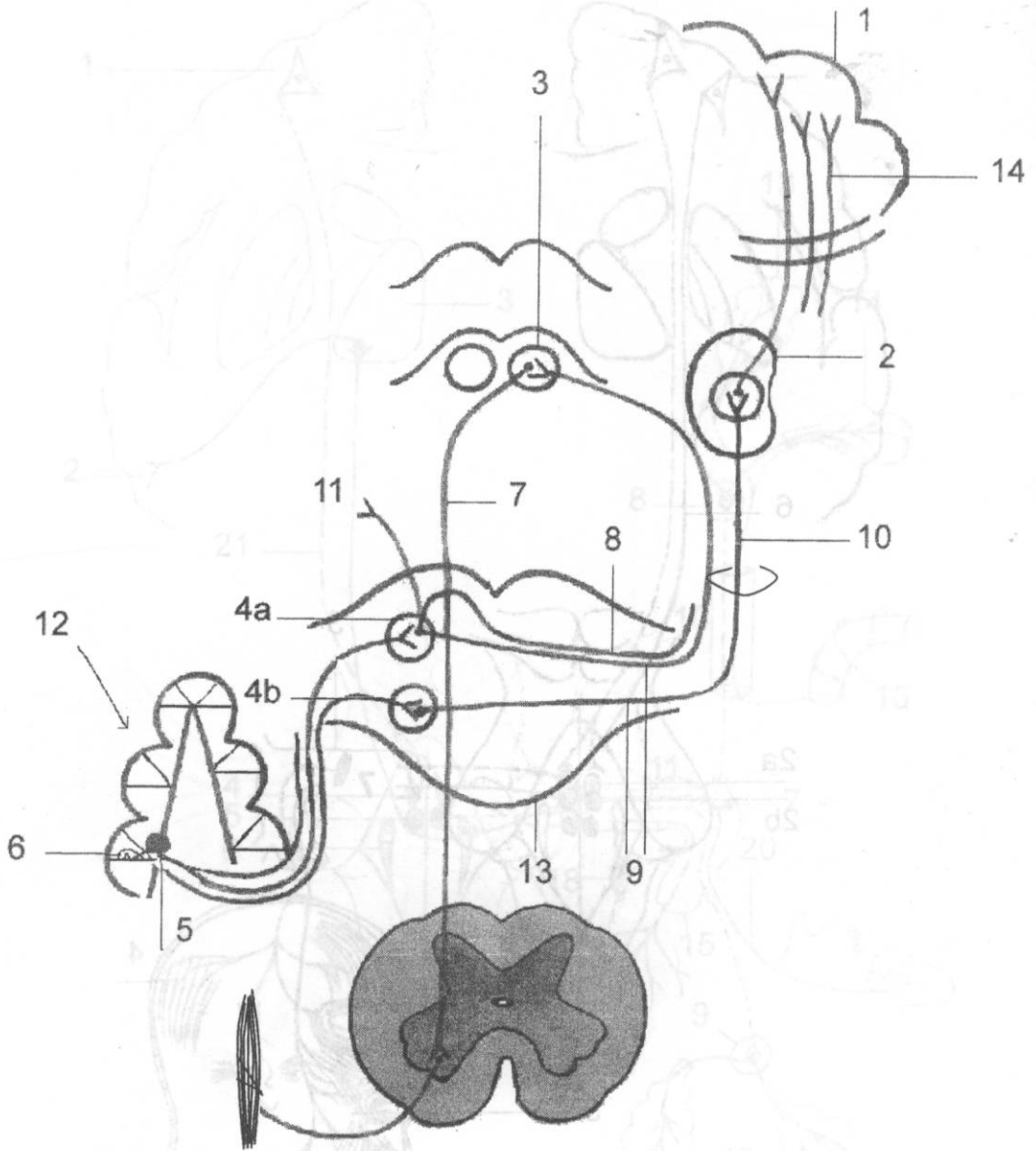
4 – mm. faciei superiores;

5 – mm. faciei inferiores;

6 – tractus corticonuclearis;

7 – m. stapedius.

(Conducting pathways of the auditory analyzer



1 – gyri temporales transversi (Heschl) (gyrus temporalis superior);

2 – neuronum III (corpus geniculatum mediale);

3 – neuronum III (colliculus inferior tecti mesencephali);

4 – neuronum II (nuclei partes cochlearis n. vestibulocochlearis);

4a – nucleus dorsalis;

4b – nucleus ventralis;

5 – neuronum I [ganglion spirale (Corti)];

6 – organum Corti (epitheliocytus neurosensorius);

7 – tractus tectospinalis;

8 – striae medullares;

9 – corpus trapezoideum;

10 – lemniscus lateralis;

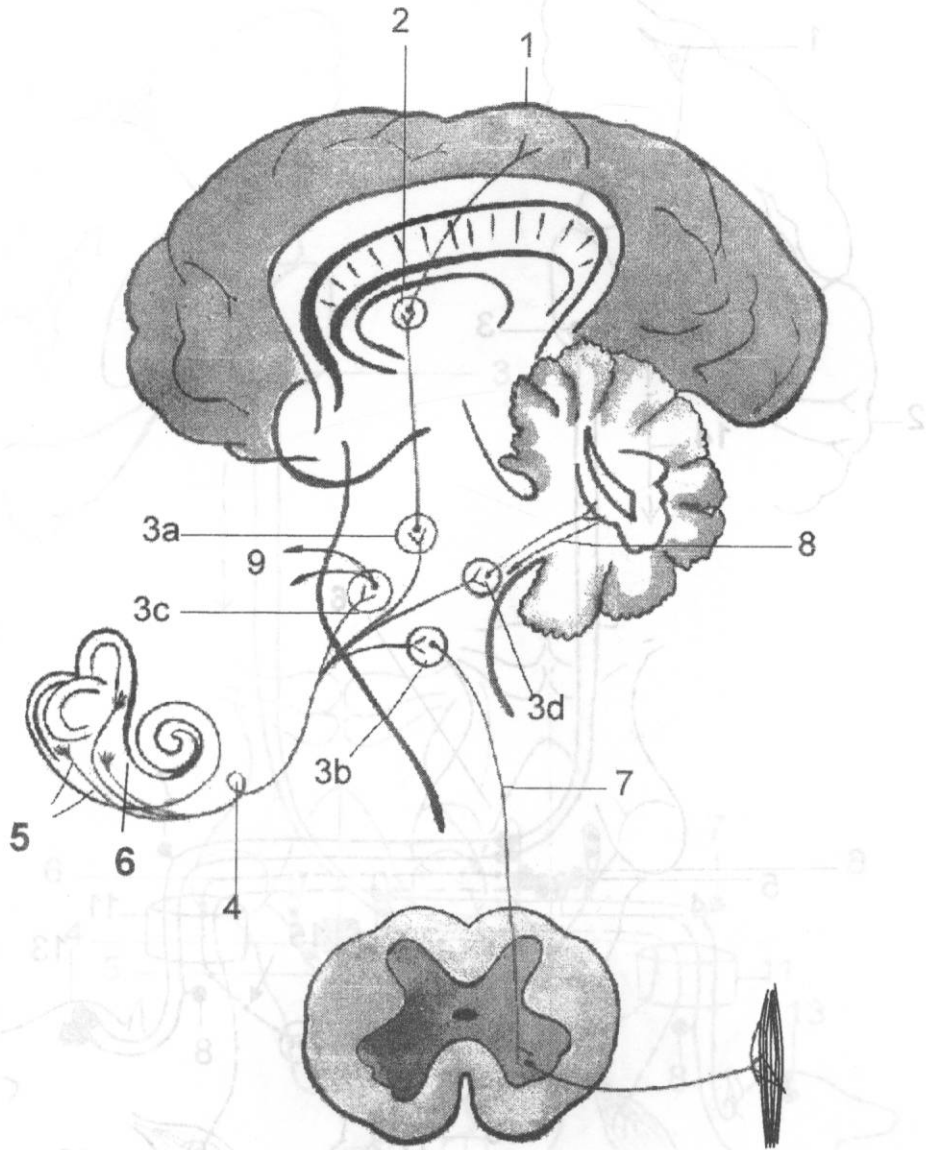
11 – conexiones ad nervos III, IV, VI;

12 – cochlea (labyrinthus osseus);

13 – pons Varolii;

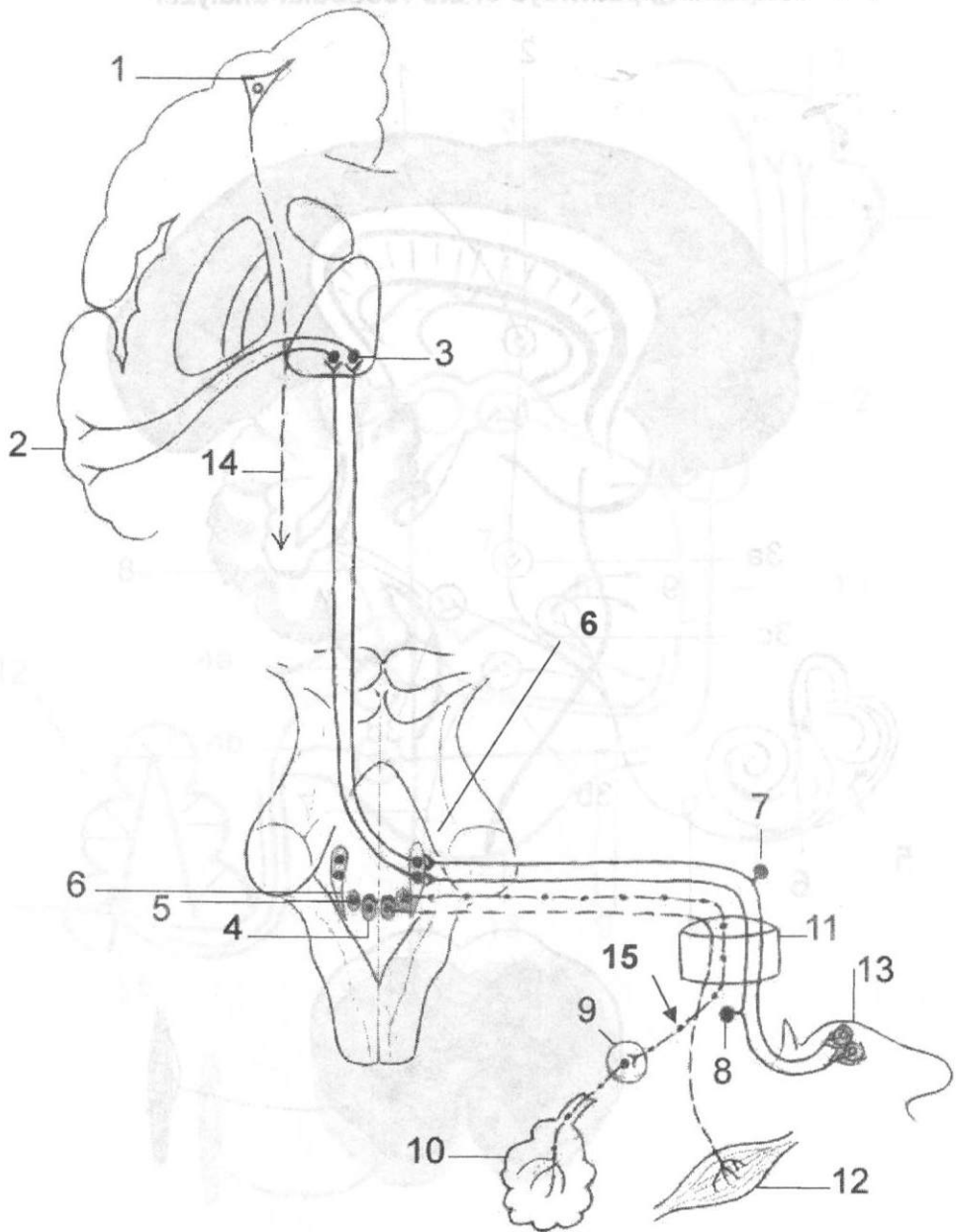
14 – radiatio acustica.

(XI) Conducting pathways of the vestibular analyzer



- | | |
|---|---|
| <p>1 – lobus temporalis;</p> <p>2 – neuronum III (thalamus opticus);</p> <p>3 – neuronum II (nuclei vestibulares n. vestibulocochlearis):</p> <p> a – superior (Бехмецев);</p> <p> b – inferior (Roller);</p> <p> c – lateralis (Deiters);</p> <p> d – medialis (Schwalbe);</p> | <p>4 – ganglion vestibulare (Scarpa) (neuronum I);</p> <p>5 – cristae ampullares ductuum semicircularium;</p> <p>6 – macula utriculi et macula sacculi;</p> <p>7 – tractus vestibulospinalis (Levental);</p> <p>8 – tractus vestibulocerebellaris et tractus cerebellovestibularis;</p> <p>9 – conexiones ad nervos craniales IX, X et III, IV, VI.</p> |
|---|---|

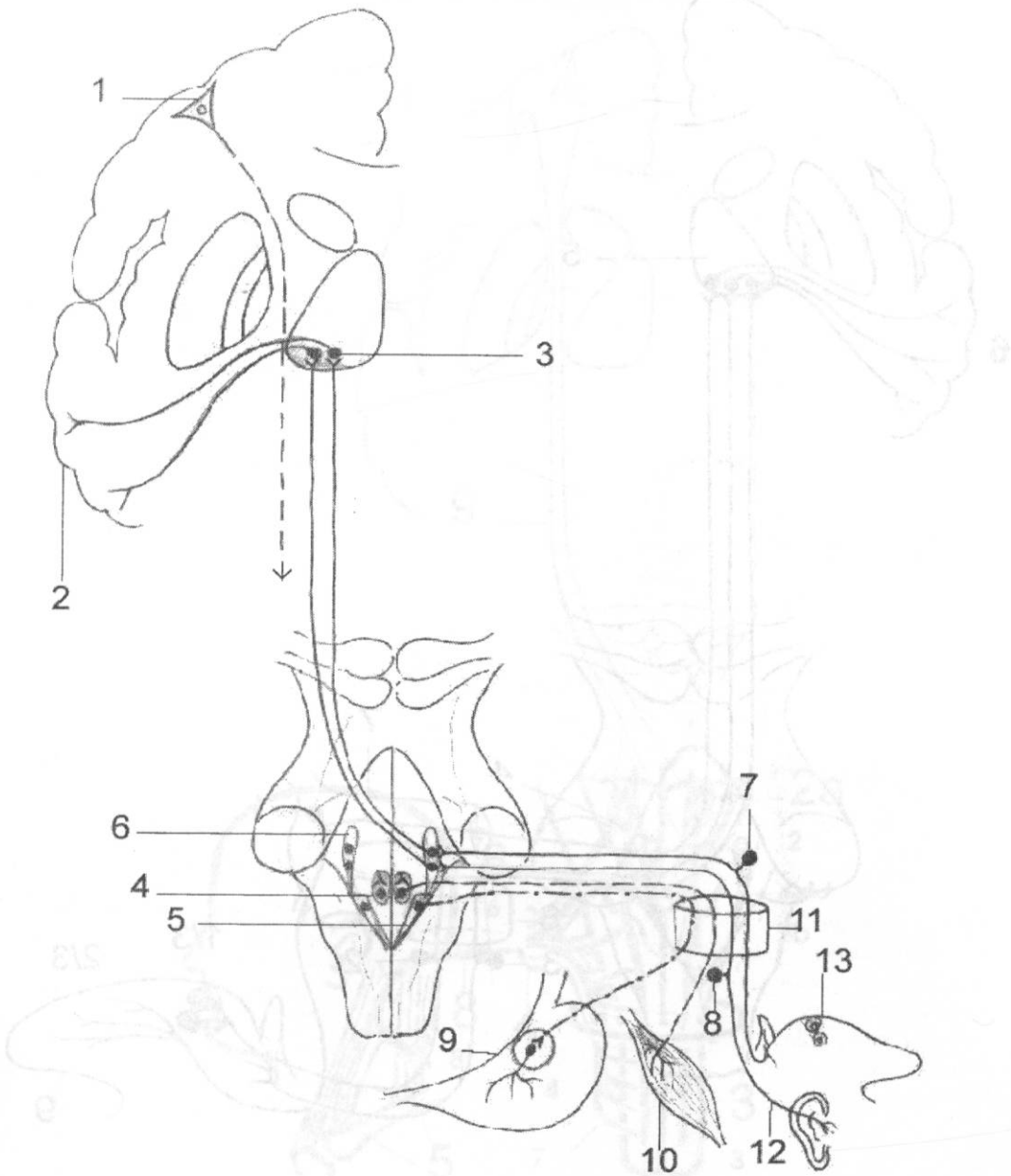
Conducting pathways of the glossopharyngeal nerve (IX)



- 1** – neuronum I (motorium) (gyrus precentralis, neurocytus pyramidalis magnus, Betz);
2 – uncus et gyrus postcentralis;
3 – neuronum III (thalamus opticus);
4 – neuronum II (motorium) (nucleus ambiguus);
5 – nucleus salivatorius inferior (neuronum I);
6 – neuronum II (sensitivum) (nucleus tractus solitarii);
7 – neuronum I (sensitivum) (ganglion superius);
8 – neuronum I (sensitivum) (ganglion inferius, nodosum);

- 9** – ganglion oticum (neuronum II);
10 – glandula parotis;
11 – foramen jugulare;
12 – ramus muscoli stylopharyngei;
13 – 1/3 posterior linguae (papillae valatae);
14 – tractus corticonuclearis;
15 – nervus tympanicus.

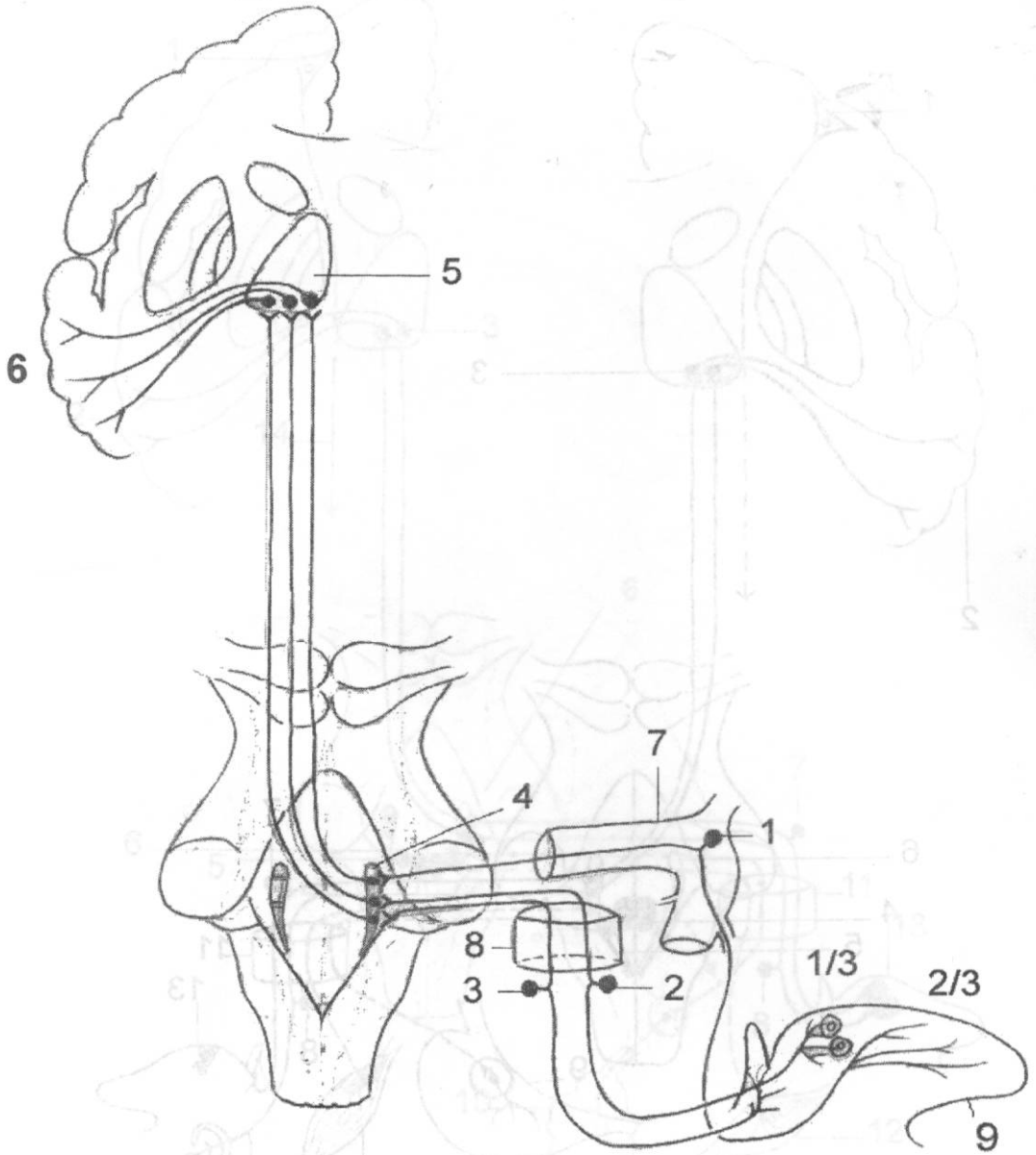
Conducting pathways of the vagus nerve (X)



1 – neuronum I (motorium) (gyrus precentralis, neurocytus pyramidalis magnus, Betz);
 2 – uncus et gyrus postcentralis;
 3 – neuronum III (sensitivum) (thalamus opticus);
 4 – neuronum II (motorium) (nucleus ambiguus);
 5 – nucleus dorsalis nervi vagi (neuronum I);
 6 – neuronum II (sensitivum) (nucleus tractus solitarii);

7 – neuronum I (sensitivum) (ganglion superius, jugulare);
 8 – neuronum I (sensitivum) (ganglion inferius, nodosum);
 9 – ganglia intravisceralia et paravisceralia (neuronum II);
 10 – mm. pharyngis, laryngis, palati mollis etc.;
 11 – foramen jugulare;
 12 – nervus auricularis posterior;
 13 – radix linguae.

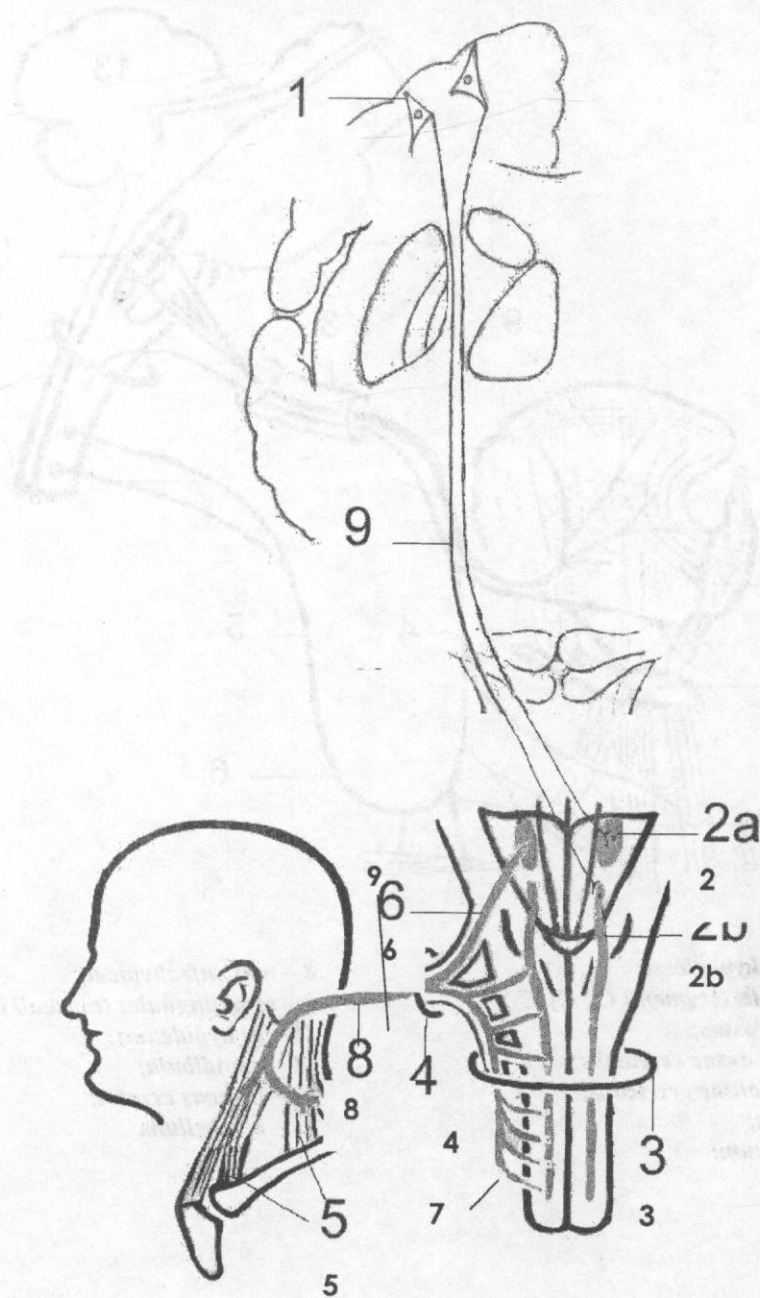
Conducting pathways of the taste analyzer



- 1 – neuronum I (ganglion geniculi, VII);
- 2 – neuronum I (ganglion inferius, IX);
- 3 – neuronum I (ganglion inferius, X);
- 4 – neuronum II [nucleus tractus solitarii (VII, IX, X)];
- 5 – neuronum III (thalamus opticus);

- 6 – gyrus parahippocampalis et uncus;
- 7 – canalis nervi facialis (Fallopianus);
- 8 – foramen jugulare;
- 9 – lingua.

Conducting pathways of the accessory nerve (XI)



1 – neuronum I (gyrus precentralis, neurocytus pyramidalis magnus, Betz);

2 – neuronum II [nuclei motorii n. accessorii:

a – nucleus ambiguus (IX, X, XI);

b – nucleus spinalis (XI);

3 – foramen occipitale magnum;

4 – foramen jugulare;

5 – mm. sternocleidomastoideus et trapezius;

6 – radices craniales nervi accessorii;

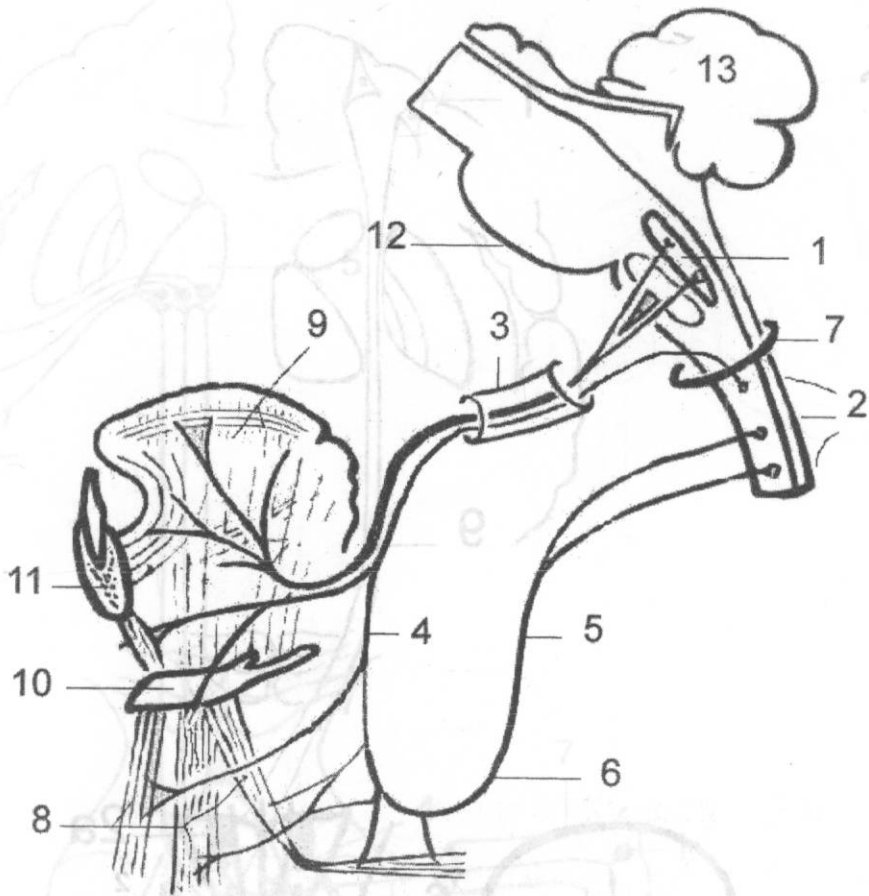
7 – radices spinales nervi accessorii;

8 – ramus externus;

9 – ramus internus;

10 – tractus corticonuclearis.

Conducting pathways of the hypoglossal nerve (XII)



1 - nucleus nervi hypoglossi;

2 - medulla spinalis (segmenti C₁, C₂, C₃);

3 - canalis hypoglossus;

4 - radix superior ansae cervicalis;

5 - radix inferior ansae cervicalis;

6 - ansa cervicalis;

7 - foramen magnum;

8 - mm. infrahyoidei;

9 - rami linguales (musculi linguae);

10 - os hyoideum;

11 - mandibula;

12 - truncus cerebri;

13 - cerebellum.