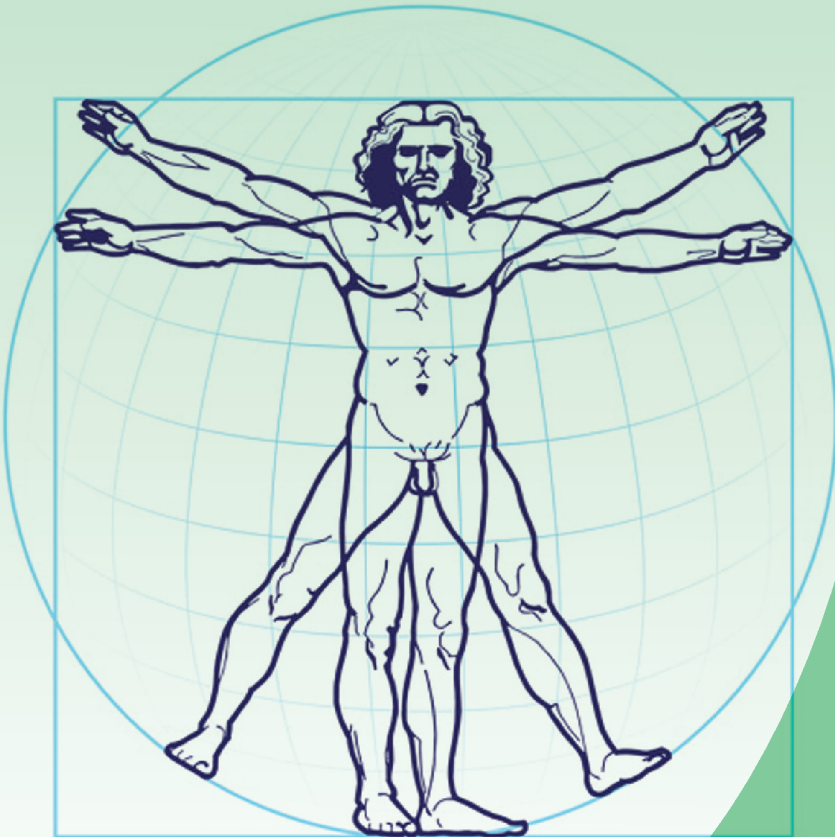


**CULEGERE DE SCHEME
LA ANATOMIA OMULUI
СБОРНИК СХЕМ
ПО АНАТОМИИ ЧЕЛОВЕКА
COLLECTION OF SCHEMES FOR
HUMAN ANATOMY**



MINISTERUL SĂNĂTĂȚII, MUNCII ȘI PROTECȚIEI
SOCIALE AL REPUBLICII MOLDOVA
UNIVERSITATEA DE STAT DE MEDICINĂ ȘI FARMACIE
NICOLAE TESTEMIȚANU
CATEDRA DE ANATOMIE A OMULUI

CULEGERE DE SCHEME LA ANATOMIA OMULUI

СБОРНИК СХЕМ ПО АНАТОМИИ ЧЕЛОВЕКА

COLLECTION OF SCHEMES FOR HUMAN ANATOMY

Ediția a VI-a
revăzută și completată

Chișinău 2019

**I. Catereniuc (sub redacția). Culegere de scheme la Anatomia omului.
Ediția a VI-a (revăzută și completată). Chișinău, 2019**

Aprobat la Consiliul Metodic Central USMF *Nicolae Testemițanu* (Ediția I).
Procesul verbal nr. 3 din 28.11.2000

Recenzenți: **Piotr I. Lobko** – Academician de Onoare al AȘM din R. Belarus,
dr. habilitat în științe medicale, profesor universitar,
Om emerit

Ion Podubnâi – dr. în științe medicale, prof. universitar, Om emerit

Redactor: **Teodor Lupașcu** – dr. în științe medicale, conferențiar universitar

Redactor terminologie latină: **Eleonora Ștefârța** – lector superior universitar

Procesare computerizată: **Mihail Tașnic**

Descrierea CIP a Camerei Naționale a Cărții

Culegere de scheme la anatomia omului = Сборник схем по анатомии человека =
Collection of schemes for human anatomy : [pentru uzul studenților] / col. de aut.: Teodor
Lupașcu, Mihail Tașnic, Eleonora Ștefârța [et al.] ; sub red.: Ilia Catereniuc ; Univ. de Stat
de Medicină și Farmacie „Nicolae Testemițanu”, Catedra de Anatomie a Omului. – Ed. a 6-a,
rev. și compl. – Chișinău : S. n., 2019 (Tipografia „Sirius”). – 268 p. : fig., tab.

Tit., text paral.: lb. rom., engl., rusă. – 1000 ex.

Sub redacția:

Ilia Catereniuc, dr. habilitat în științe medicale, profesor universitar

Colectivul de autori:

Teodor Lupașcu, dr. în științe medicale, conferențiar universitar

Mihail Tașnic, lector universitar

Eleonora Ștefârță, lector superior universitar

Zinovia Zorina, asistent universitar

Anastasia Bendelic, asistent universitar

Olga Belic, dr. habilitat în științe medicale, conferențiar universitar

Mihail Ștefanetș, dr. habilitat în științe medicale, profesor universitar

Angela Babuci, asistent universitar

Dumitru Batâr, dr. în științe medicale, conferențiar universitar

Tamara Titova, dr. în științe medicale, conferențiar universitar

Emilia Poburnaia, dr. în științe medicale, conferențiar universitar

Eugenia Lopotencu, dr. în științe medicale, conferențiar universitar

Lilian Globa, asistent universitar

Tatiana Botnari, asistent universitar

PREAMBUL

Culegerea de scheme pe care o prezentăm într-o nouă versiune, se deosebește de cele precedente prin anumite concretizări și completări.

Ea urmărește scopul de a facilita studierea unei din cele mai complicate și mai dificile discipline medicale fundamentale – *anatomia sistemică a omului*.

Schemele reproduse în lucrare au fost selectate din numeroase surse bibliografice moderne, o bună parte din ele fiind elaborate sau modificate de către prof. universitar I. Catereniuc cu contribuția nemijlocită a cadrului profesoral-didactic al catedrei.

În alegerea schemelor ne-am condus atât de importanța cunoașterii structurilor pe care acestea le ilustrează, cât și de rolul lor în studierea aprofundată a altor discipline medicale, evitându-se totodată aspectele discutabile sau ipotetice.

Necesitatea reeditării unei astfel de culegeri este evidentă, deoarece aceasta, după cum ne-am convins de la apariția primei ediții, contribuie la economisirea timpului pentru expunerea materialului din cadrul cursurilor și lucrărilor de laborator, la conștientizarea de către studenți a informației care ține de domeniul anatomiei omului și, nu în ultimul rând, la unificarea procesului de instruire la catedră.

Culegerea de față poate fi utilă atât studenților în pregătirea pentru lucrările de laborator, totalizări și examene, cât și rezidenților și specialiștilor din diverse domenii ale medicinei.

Nu pretindem la deținerea adevărului absolut, de aceea toate observațiile și sugestiile cititorilor vor fi binevenite și ne vor fi de un real folos.

Autorii

CUPRINS / СОДЕРЖАНИЕ / CONTENT

I. Aparatul de susținere mișcare / Опорно-двигательный аппарат /	
Locomotor apparatus	7
1.1. <i>Osteologia / Остеология / Osteology</i>	7
1.2. <i>Artrologia / Артрология / Arthrology</i>	30
1.3. <i>Miologia / Миология / Myology</i>	43
II. Splanhnologia / СПЛАНХНОЛОГИЯ / Splanchnology	65
2.1. <i>Sistemul digestiv / Пищеварительная система /</i> <i>Alimentary system</i>	66
2.2. <i>Sistemul respirator / Дыхательная система /</i> <i>Respiratory system</i>	94
2.3. <i>Inima și pericardul / Сердце и перикард /</i> <i>Heart and pericardium</i>	110
2.4. <i>Sistemul urinar / Мочевая система / Urinary system</i>	120
2.5. <i>Sistemele genitale / Половые системы / Genital systems</i>	130
III. Sistemul nervos central / Центральная нервная система /	
Central nervous system	148
IV. Sistemul nervos periferic / Периферическая нервная система /	
Peripheral nervous system	210
V. Sistemele vascular, endocrin și limfoid /	
Сосудистая, эндокринная и лимфоидная системы /	
Vascular, endocrine and lymphoid systems	245

ABREVIERI

a. – arteria

aa. – arteriae

c. – centrum

gangl. – ganglion

gangll. – ganglia

lig. – ligamentum

ligg. – ligamenta

m. – musculus

mm. – muscoli

n. – nervus

nn. – nervi

nucl. – nucleus

nucll. – nuclei

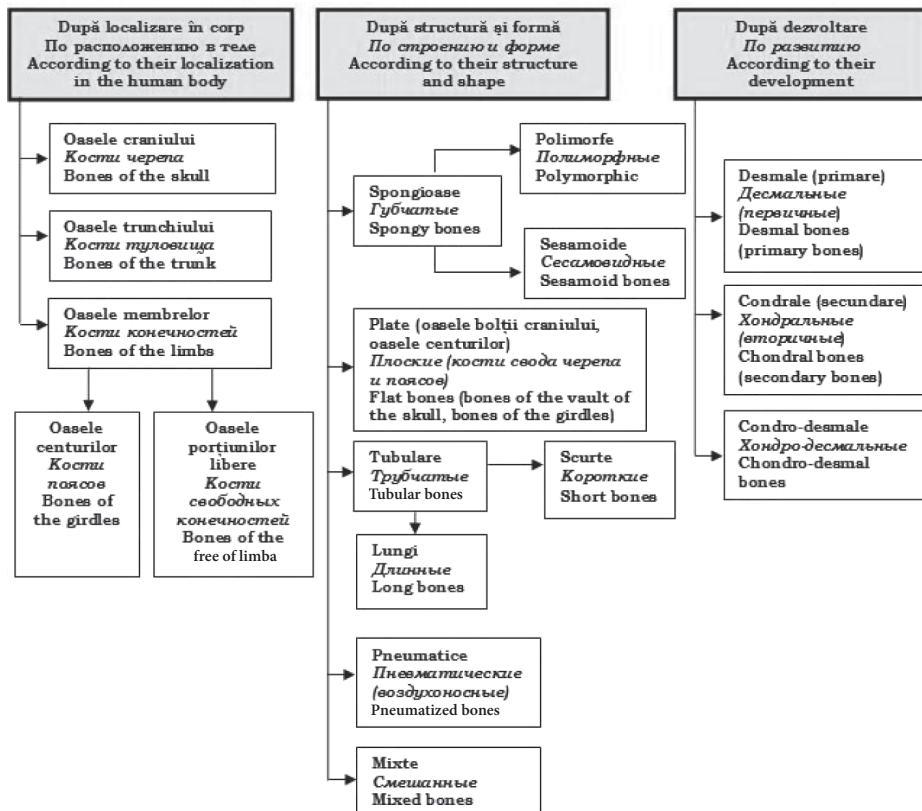
seg. – segmentum

tr. – tractus

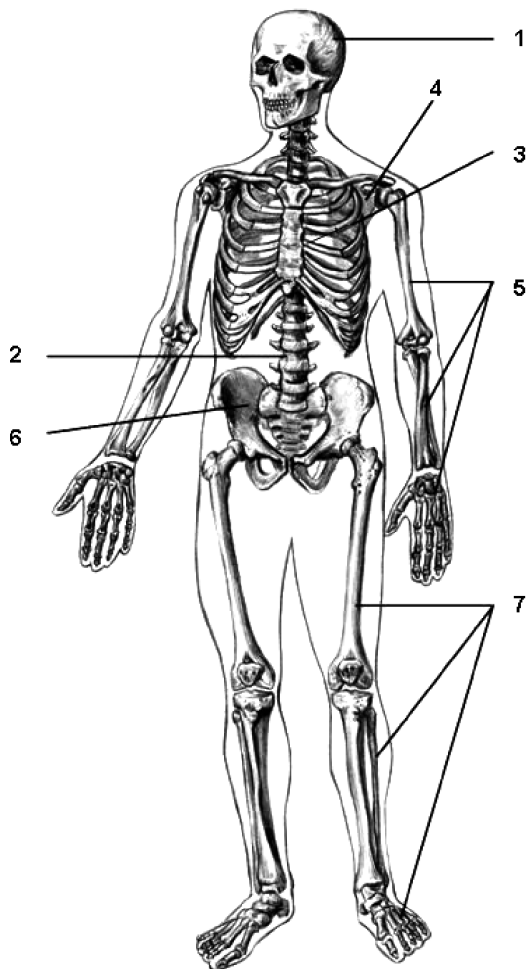
v. – vena

vv. – venae

CLASIFICAREA OASELOR КЛАССИФИКАЦИЯ КОСТЕЙ CLASSIFICATION OF BONES

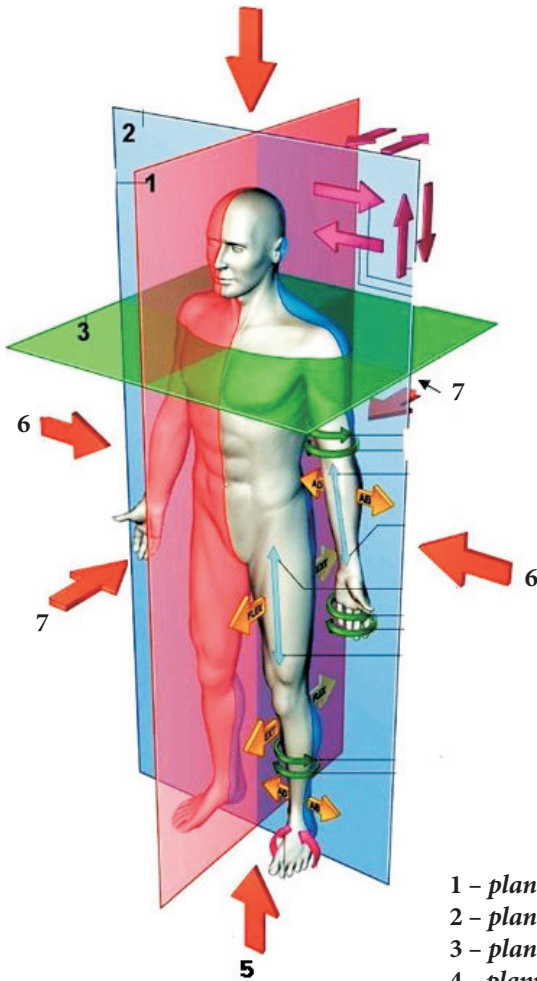


OASELE SCHELETULUI UMAN
КОСТИ СКЕЛЕТА ЧЕЛОВЕКА
BONES OF THE HUMAN SKELETON



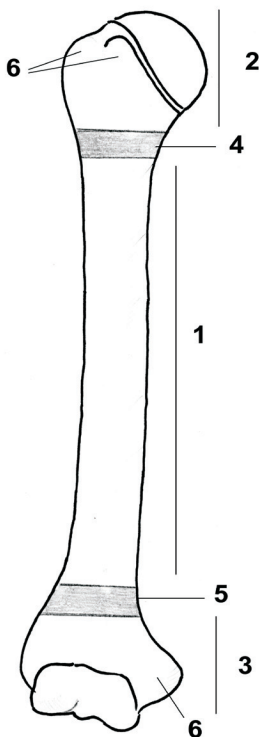
- 1 – ossa cranii;
- 2 – columna vertebralis;
- 3 – skeleton thoracis;
- 4 – ossa cinguli membri superioris (cingulum pectorale);
- 5 – ossa partis liberae membri superioris (humerus, ossa antebrachii, ossa manus);
- 6 – ossa cinguli membri inferioris (cingulum pelvicum);
- 7 – ossa partis liberae membri inferioris (femur, ossa cruris, ossa pedis).

AXELE ȘI PLANURILE CORPULUI UMAN
 ОСИ И ПЛОСКОСТИ ТЕЛА ЧЕЛОВЕКА
 AXES AND PLANES OF THE HUMAN BODY



- 1 – *planum sagittale (medianum)*;
- 2 – *planum frontale (coronale)*;
- 3 – *planum transversum (horizontale)*;
- 4 – *planum paramedianum (parsagittale)*;
- 5 – *axis verticalis*;
- 6 – *axis transversalis*;
- 7 – *axis sagittalis*.

PĂRȚILE UNUI OS TUBULAR LUNG
ЧАСТИ ДЛИННОЙ ТРУБЧАТОЙ КОСТИ
PARTS OF A LONG TUBULAR BONE



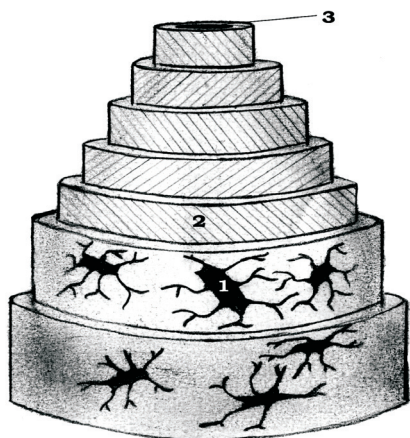- 1 - diaphysis;
- 2 - epiphysis proximalis;
- 3 - epiphysis distalis;
- 4 - metaphysis proximalis;
- 5 - metaphysis distalis;
- 6 - apophyses.

SCHEMA OSTEONULUI (SISTEMUL HAVERSIAN)

(după H.K. Лысенков, 1958)

СХЕМА ОСТЕОНА (ГАВЕРСОВА СИСТЕМА)

THE SCHEME OF THE OSTEON (HAVERSIAN SYSTEM)

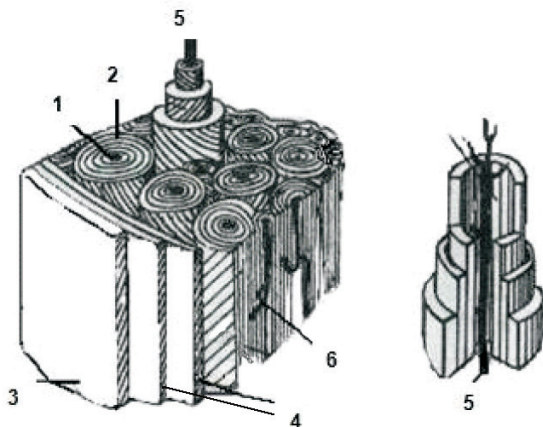


A

1 – osteocytus;

2 – lamella osteoni;

3 – canalis centralis osteoni.



B

1 – canalis centralis osteoni;

2 – lamellae osteoni;

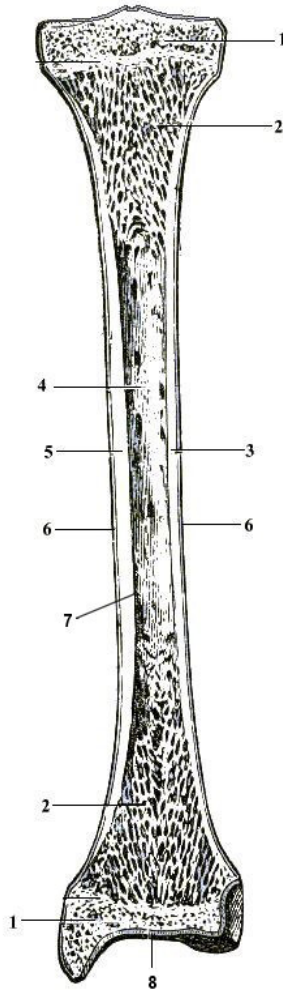
3 – periosteum;

4 – lamellae circumferentiales externae;

5 – vas sanguineum (Havers);

6 – canalis anastomoticus [perforans (ossis)] (Volkmann).

STRUCTURA OSULUI ÎN SECȚIUNE LONGITUDINALĂ
СТРОЕНИЕ КОСТИ НА ПРОДОЛЬНОМ РАЗРЕЗЕ
STRUCTURE OF THE BONE IN A LONGITUDINAL SECTION

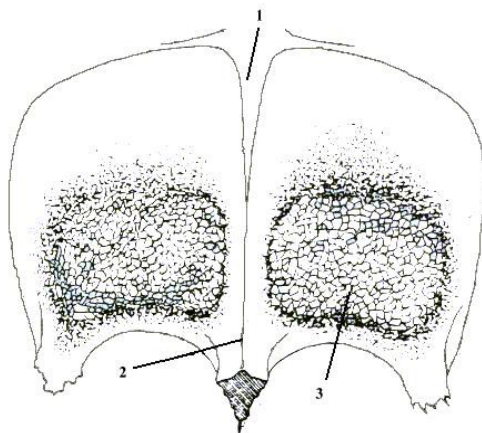


- 1, 2 – *substantia spongiosa (trabecularis)*;
3, 5 – *substantia compacta*;
4 – *cavitas medullaris*;
6 – *periosteum*;
7 – *endosteum*;
8 – *cartilago epiphysialis*.

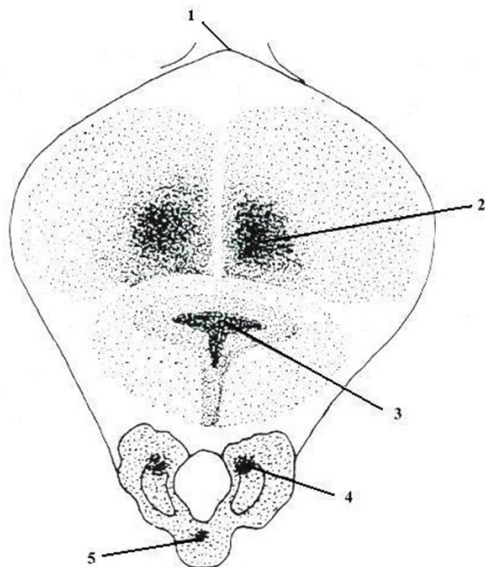
CENTRII DE OSIFICARE AI OASELOR FRONTAL ȘI OCCIPITAL

(după A. Andronescu, 1972)

ТОЧКИ ОКостЕНЕНИЯ ЛОБНОЙ И ЗАТЫЛОЧНОЙ КОСТЕЙ
OSSIFICATION CENTRES OF THE FRONTAL AND OCCIPITAL BONES



- 1 – fonticulus anterior (coronalis, bregmaticus);
- 2 – sutura metopica;
- 3 – centrum ossificationis primarium.



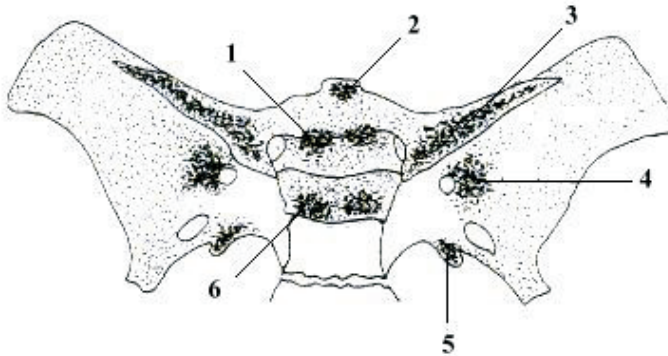
- 1 – fonticulus posterior (lambdoideus);
- 2, 3 – centra squamae occipitalis;
- 4 – centra partium lateralium;
- 5 – centrum partis basilaris.

**CENTRII DE OSIFICARE AI OSULUI SFENOID
ȘI A MANDIBULEI**

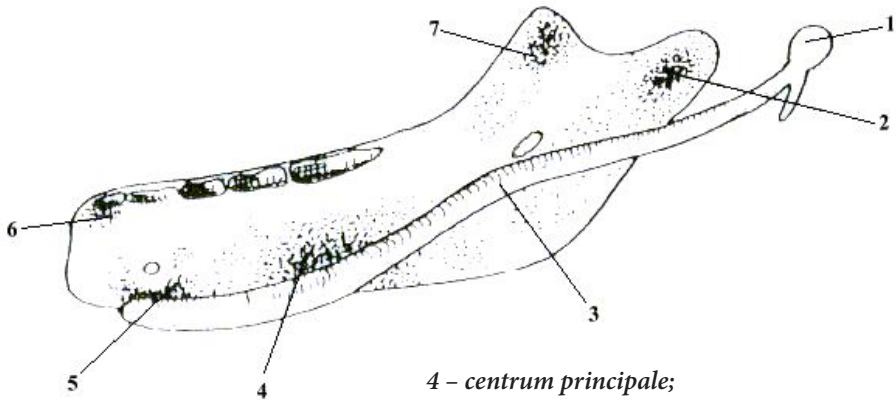
(după A. Andronescu, 1972)

**ТОЧКИ ОКостЕНЕНИЯ КЛИНОВИДНОЙ КОСТИ И
НИЖНЕЙ ЧЕЛЮСТИ**

**OSSIFICATION CENTRES OF THE SPHENOID
BONE AND OF THE MANDIBLE**

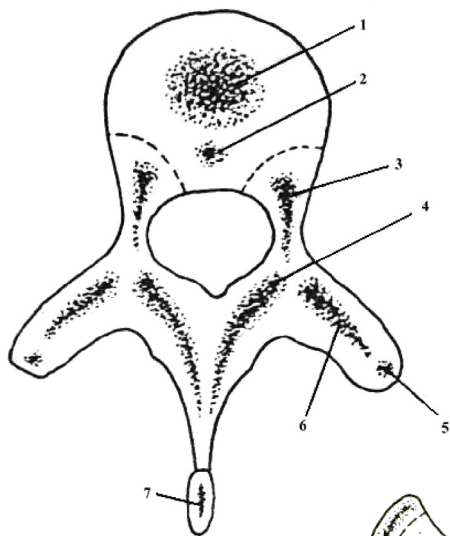


- 1 - centrum presphenoidale;
- 2 - centrum rostrale;
- 3 - centrum alae minoris;
- 4 - centrum alae majoris;
- 5 - centrum ossis sphenoidalis (sphenoticum);
- 6 - centrum basis ossis sphenoidalis.

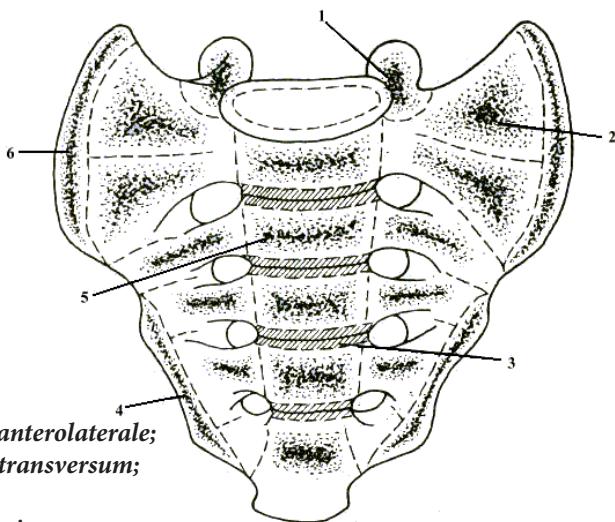


- 1 - malleus;
- 2 - centrum condylare;
- 3 - cartilago Meckeli;
- 4 - centrum principale;
- 5 - centrum mentale;
- 6 - centrum incisivum;
- 7 - centrum processus coronoidei.

**CENTRII DE OSIFICARE AI UNEI VERTEBRE
TORACICE TIP ȘI A SACRULUI**
(după A. Andronescu, 1972)
**ТОЧКИ ОКОСТЕНЕНИЯ ТИПИЧНОГО
ГРУДНОГО ПОЗВОНКА И КРЕСТЦА**
**OSSIFICATION CENTRES OF A TYPICAL THORACIC
VERTEBRA AND OF THE SACRUM**



- 1 – *centrum ossificationis principale;*
- 2 – *centrum accessorium;*
- 3 – *centrum laterale anterius;*
- 4 – *centrum laterale posterius;*
- 5 – *centrum primarium transversale;*
- 6 – *centrum ossificationis secundarium;*
- 7 – *processus spinosus.*

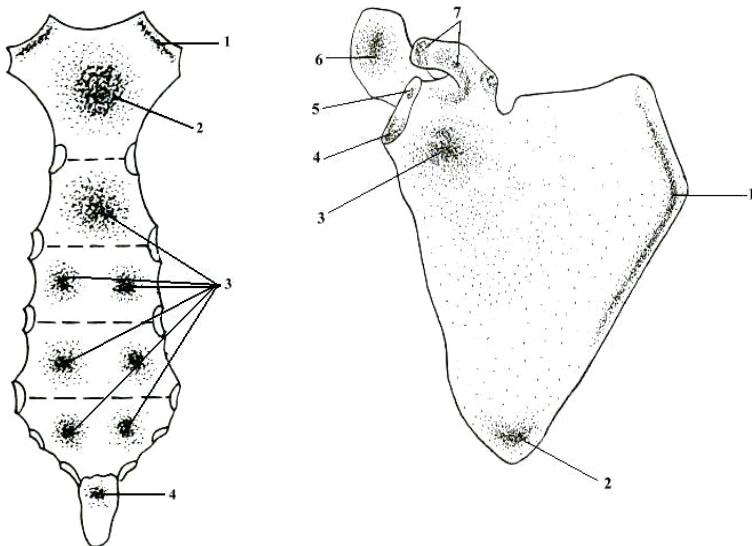


- 1 – *centrum ossificationis anterolaterale;*
- 2 – *centrum ossificationis transversum;*
- 3 – *anulus epiphysialis;*
- 4 – *lamina marginalis inferior;*
- 5 – *centrum ossificationis medianum;*
- 6 – *lamina marginalis superior.*

CENTRII DE OSIFICARE AI STERNULUI, SCAPULEI ȘI CLAVICULEI

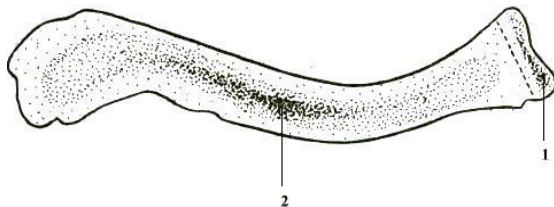
(după A. Andronescu, 1972)

ТОЧКИ ОКОНСТЕНЕНИЯ ГРУДИНЫ, ЛОПАТКИ И КЛЮЧИЦЫ OSSIFICATION CENTRES OF THE BREASTBONE, OF THE SCAPULA AND OF THE CLAVICLE



- 1 – *centra incisurarum clavicularem;*
- 2 – *centrum manubrii;*
- 3 – *centra corporis sterni;*
- 4 – *centrum xiphoideum.*

- 1 – *centrum marginis vertebralis;*
- 2 – *centrum anguli inferioris;*
- 3 – *centrum subglenoidale;*
- 4 – *centrum infraglenoidale;*
- 5 – *centra supraglenoidalia;*
- 6 – *centra acromii;*
- 7 – *centra coracoidea.*



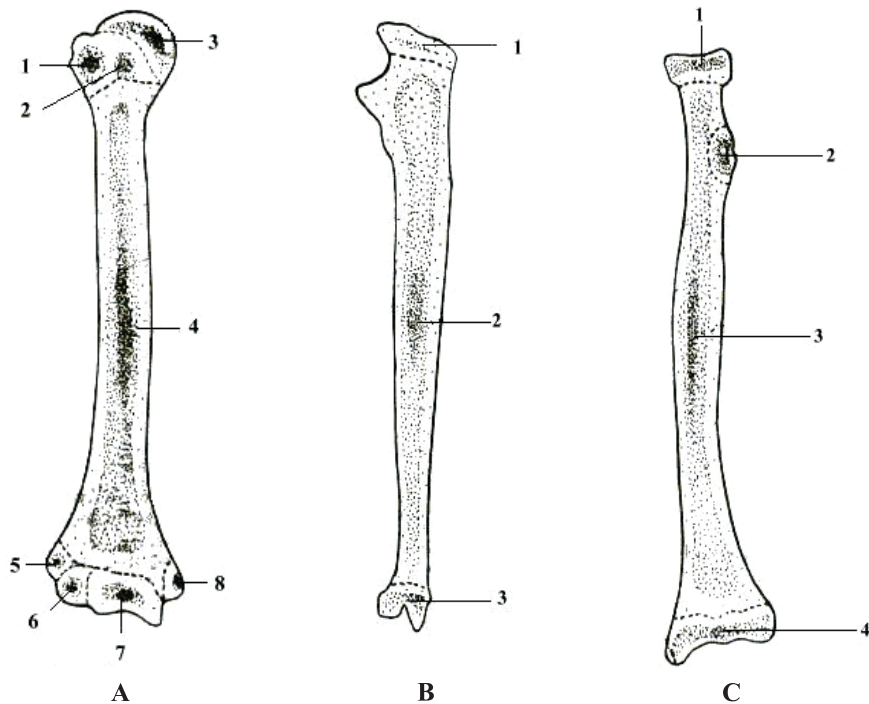
- 1 – *centrum epiphysiale;*
- 2 – *centrum diaphysiale.*

CENTRII DE OSIFICARE AI HUMERUSULUI, ULNEI ȘI RADIUSULUI

(după A. Andronescu, 1972)

ТОЧКИ ОКОСТЕНЕНИЯ ПЛЕЧЕВОЙ, ЛОКТЕВОЙ И ЛУЧЕВОЙ КОСТЕЙ

OSSIFICATION CENTRES OF THE HUMERUS, ULNA AND RADIUS



A

- 1 – *centrum tuberculi majoris;*
- 2 – *centrum tuberculi minoris;*
- 3 – *centrum capituli humeri;*
- 4 – *centrum diaphysiale;*
- 5 – *centrum epicondyli lateralis;*
- 6 – *centrum capituli humeri;*
- 7 – *centrum trochleae humeri;*
- 8 – *centrum epicondyli medialis.*

B

- 1 – *centrum epiphysiale superius;*
- 2 – *centrum diaphysiale;*
- 3 – *centrum epiphysiale inferius.*

C

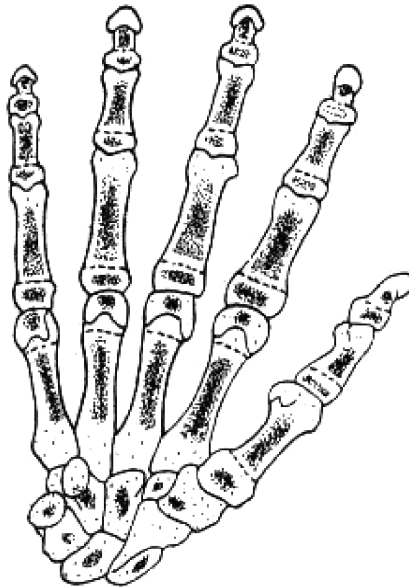
- 1 – *centrum epiphysiale superius;*
- 2 – *centrum tuberositatis radialis;*
- 3 – *centrum diaphysiale;*
- 4 – *centrum epiphysiale inferius.*

**CENTRII DE OSIFICARE AI OASELOR CARPIENE,
METACARPIENE ȘI FALANGELOR**

(după A. Andronescu, 1972)

**ТОЧКИ ОКОСТЕНЕНИЯ КОСТЕЙ ЗАПЯСТЬЯ,
ПЯСТЬЯ И ФАЛАНГ ПАЛЬЦЕВ**

**OSSIFICATION CENTRES OF THE CARPAL BONES,
METACARPAL BONES AND OF THE PHALANGES**



Centrii primari de osificare apar în oasele carpiene și în corpul oaselor metacarpiene și a falangelor, iar cei secundari – în baza metacarpianului I și a falangelor și în capul oaselor metacarpiene (cu excepția primului) și a falangelor.

Первичные точки окостенения появляются в костях запястья и в теле костей пястья и фаланг пальцев, а вторичные – в основании первой пястной кости и фаланг пальцев, в головках костей пястья (за исключением первой) и фаланг.

The primary centers of ossification appear in the carpal bones and in the bodies of the metacarpal bones and phalanges, but the secondary centers appear in the base of the 1st metacarpal bone and bases of the phalanges and in the heads of the metacarpal bones (excepting the first one) and phalanges.

**TERMENELE APARIȚIEI ȘI CONTOPIRII CENTRILOR DE OSIFICARE
A OASELOR MEMBRULUI SUPERIOR**

(după A. Andronescu, 1972)

**СРОКИ ПОЯВЛЕНИЯ И СЛИЯНИЯ ТОЧЕК ОКОСТЕНЕНИЯ КОСТЕЙ
ВЕРХНЕЙ КОНЕЧНОСТИ**

**TERMS OF APPEARANCE AND FUSION OF THE OSSIFICATION
POINTS IN THE BONES OF THE UPPER LIMB**

Osul Кость Bone	Centrii primari Первичные точки Primary centres	Centrii secundari Вторичные точки Secondary centres	Termenele contopirii centrilor secundari Время сращения вторичных точек Terms of fusion of the secondary centres	Termenele contopirii centrilor secundari cu cei principali Время сращения основных и вторичных точек Terms of fusion of the main and of the secondary centres
Scapula	45-60 dies	C. coracoideum principale C. coracoideum accessorium C. glenoidale superius C. glenoidale inferius C. acromiale (1-2) C. marginis vertebrae C. anguli inferioris	16-18 anni 10-12 anni 16-18 anni 14-18 anni 15-20 anni 16-18 anni	15-18 anni 16-18 anni 20 anni 18-20 anni 22-25 anni 22-25 anni
Clavicula	30 dies		18-22 anni	22-25 anni
Humerus	40-45 dies	C. cephalicum (interdum) C. tuberculi majoris C. tuberculi minoris C. capitatum C. trochleare C. epicondylis medialis C. epicondylis lateralis	3-6 menses 2-2,5 anni 3-4 anni 1-2 anni 8-15 anni 4-8 anni 10-12 anni	20-25 anni 17-20 anni
Radius	40 dies	C. cephalicum C. epiphysiale inferius C. bicipitale	3-6 anni 1 annus 13-14 anni	15-18 anni 17-25 anni 17 anni
Ulna	35-40 dies	C. olecrani C. cephalicum	9-14 anni 6-9 anni	16-20 anni 18-22 anni
Os scaphoideum Os lunatum Os pyramidale Os pisiforme Os trapezium Os trapezoideum	5-6 anni 3-5 anni 2-4 anni 8-11 anni 4,5-6 anni 4,5-6 anni			
Os magnum Os hamatum	4-5 menses 4-5 menses	C. apophysiale inconstans	9-11 anni	12 anni
Metacarpus I	3 menses	C. epiphysiale superius	3,5-4 anni	14-16 anni
Metacarpus II	3 menses	C. epiphysiale inferius	3-4 anni	
Metacarpus III	3 menses	C. epiphysiale inferius	1,5-2,5 anni	14-16 anni
Metacarpus IV	3 menses	C. epiphysiale inferius	3-4 anni	14-16 anni
Metacarpus V	3 menses	C. epiphysiale inferius	3,5-4 anni	14-16 anni
Phalanx I	2 menses		1-2,5 anni	16-20 anni
Phalanx II	2,5-3 menses			16-20 anni
Phalanx III	2,5-3 menses		2,5-3 anni	

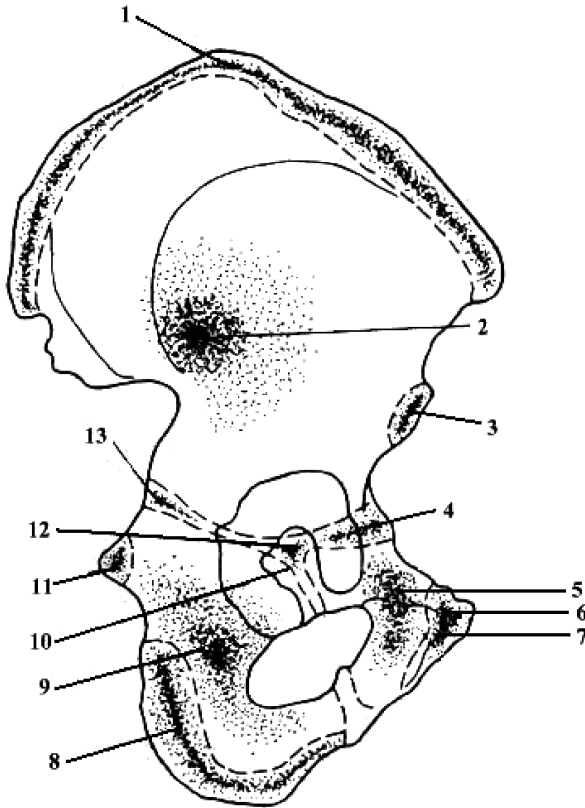
C - centrum

CENTRII DE OSIFICARE AI COXALULUI

(după A. Andronescu, 1972)

ТОЧКИ ОКОСТЕНЕНИЯ ТАЗОВОЙ КОСТИ

OSSIFICATION CENTRES OF THE HIP BONE



1 – *centrum cristae iliacaе;*

2 – *centrum iliacum;*

3 – *centrum spinae iliacaе anterioris inferioris;*

4 – *centrum acetabuli anterioris;*

5 – *centrum ossis pubis;*

6 – *centrum tuberculi pubici;*

7 – *centrum anguli ossis pubis;*

8 – *centrum tuberis ischiadici;*

9 – *centrum ischiadicum;*

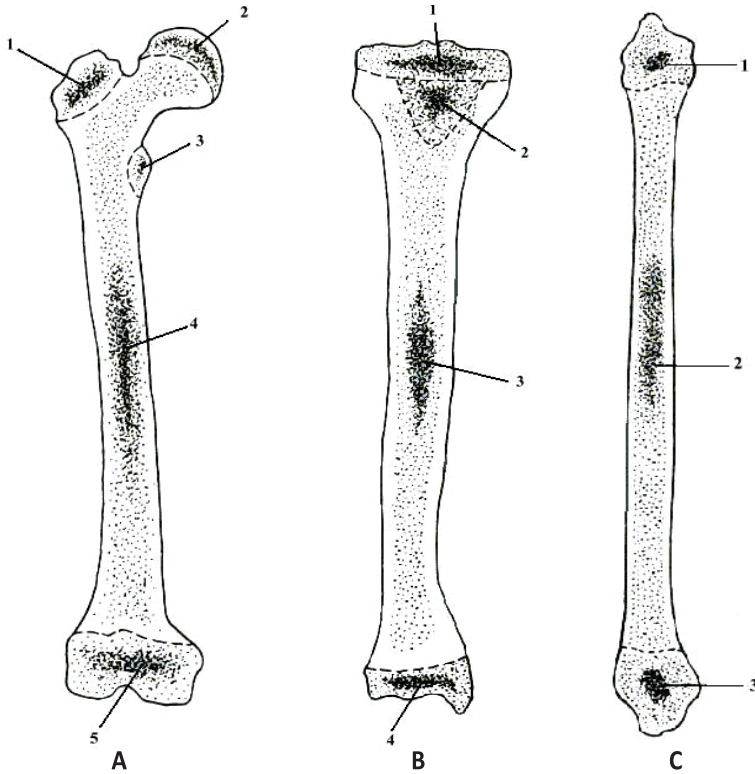
10 – *cartilago;*

11 – *centrum spinae ischiadicae;*

12 – *centrum medianum;*

13 – *centrum acetabulare posterius.*

CENTRII DE OSIFICARE AI FEMURULUI, TIBIEI ȘI FIBULEI
(după A. Andronescu, 1972)
**ТОЧКИ ОКОНСТЕНЕНИЯ БЕДРЕННОЙ, БОЛЬШЕБЕРЦОВОЙ
 И МАЛОБЕРЦОВОЙ КОСТЕЙ**
OSSIFICATION CENTRES OF THE FEMUR, TIBIA AND FIBULA



- A**
 1 – *centrum trochanteris majoris*;
 2 – *centrum capitis femoris*;
 3 – *centrum trochanteris minoris*;
 4 – *centrum diaphysiale*;
 5 – *centrum epiphysiale inferius*.

- B**
 1 – *centrum epiphysiale superius*;
 2 – *centrum tuberositatis tibiae*;
 3 – *centrum diaphysiale*;
 4 – *centrum epiphysiale inferius*.

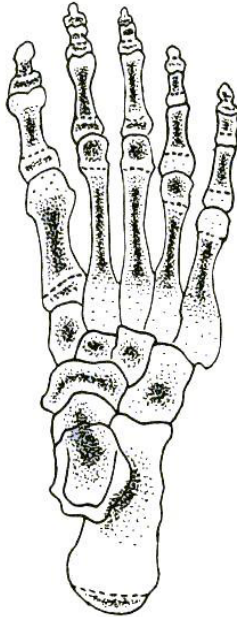
- C**
 1 – *centrum epiphysiale superius*;
 2 – *centrum diaphysiale*;
 3 – *centrum epiphysiale inferius*.

NUCLEII DE OSIFICARE AI OASELOR TARSULUI, METATARSULUI ȘI FALANGELOR

(după A. Andronescu, 1972)

ТОЧКИ ОКОСТЕНЕНИЯ КОСТЕЙ ПРЕДПЛЮСНЫ, ПЛЮСНЫ И ФАЛАНГ ПАЛЬЦЕВ

OSSIFICATION CENTRES OF THE TARSAL AND METATARSAL BONES AND OF THE PHALANGES OF THE TOES



Centrii primari de osificare apar în oasele tarsiene și în corpul oaselor metatarsiene și a falangelor, iar cei **secundari** – în baza metatarsianului I și a falangelor și în capul oaselor metatarsiene (cu excepția primului) și a falangelor.

Первичные точки окостенения появляются в костях предплюсны и в теле костей плюсны и фаланг пальцев, а *вторичные* – в основании первой плюсневой кости и фаланг пальцев, в головках костей плюсны (за исключением первой) и фаланг.

The **primary centers** of ossification appear in the tarsal bones and in the bodies of the metatarsal bones and phalanges, but the **secondary centers** appear in the base of the 1st metatarsal bone and bases of the phalanges and in the heads of the metatarsal bones (excepting the first one) and phalanges.

**TERMENELE APARIȚIEI ȘI CONTOPIRII CENTRILOR DE
OSIFICARE A OASELOR MEMBRULUI INFERIOR**

(după A. Andronescu, 1972)

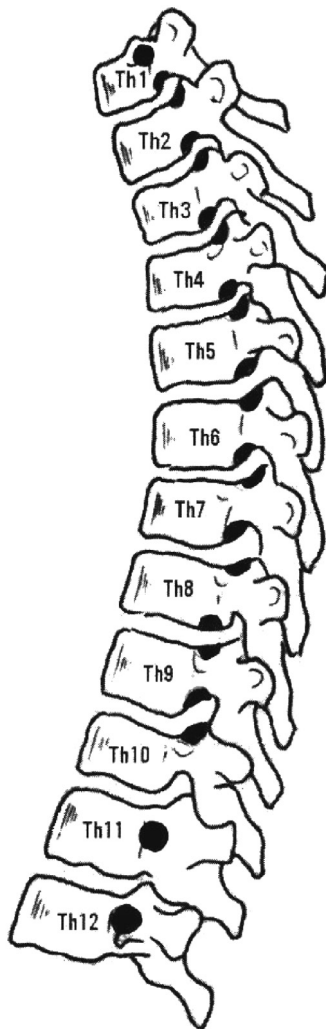
**СРОКИ ПОЯВЛЕНИЯ И СЛИЯНИЯ ТОЧЕК ОКОСТЕНЕНИЯ КОСТЕЙ
НИЖНЕЙ КОНЕЧНОСТИ**

**TERMS OF APPEARANCE AND FUSION OF THE OSSIFICATION
POINTS IN THE BONES OF THE LOWER LIMB**

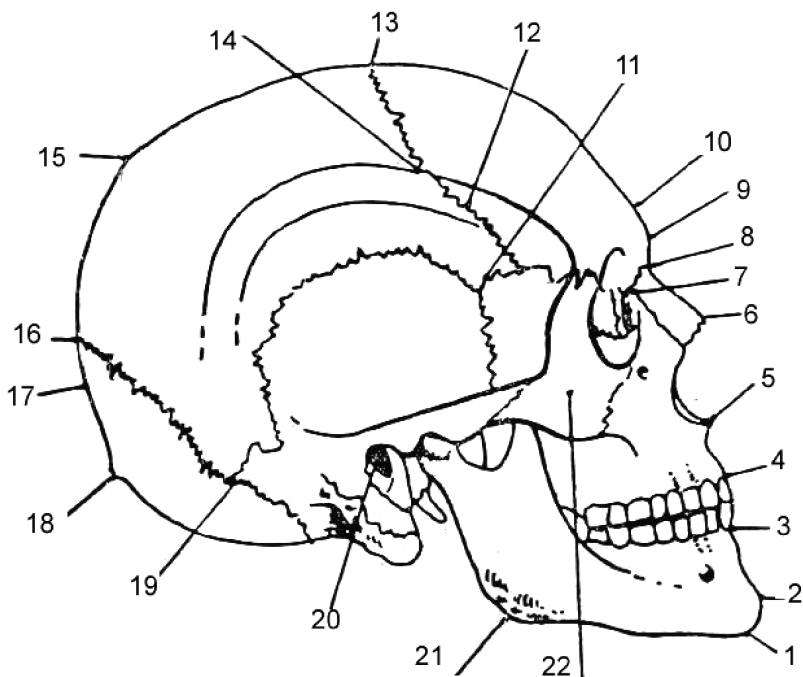
Osul Кость Bone	Centrii primari <i>Первичные точки</i> Primary centres	Centrii secundari <i>Вторичные точки</i> Secondary centres	Termenele contopirii centrilor secundari <i>Сроки сращения вторичных точек</i> Terms of fusion of the secondary centres	Termenele contopirii centrilor secundari cu cei principali <i>Сроки сращения основных и вторичных точек</i> Terms of fusion of the main and of the secondary centres
Femur	40-50 dies intrauterini	C. cephalicum 6-12 menses C. trochanteris majoris 3-5 anni C. trochanteris minoris 8-10 anni C. intercondylare 9 menses fetales		18-20 anni 16-18 anni 18-20 anni
Patella	2-4 anni		16-19 anni	
Tibia	45-60 dies intrauterini	C. epiphysiale superius 9 menses fetales C. tuberositatis 11-12 anni C. epiphysiale inf. 6-8 menses	13 anni	19-20 anni 18 anni 17-18 anni
Fibula	60-70 dies intrauterini	C. epiphysiale sup. 3-5,5 anni C. epiphysiale inferius 8-12 menses		19-21 anni 17-20 anni
Talus	8-9 menses fetales	C. ossis trigoni 8 anni		
Calcaneus	5-6 menses fetales	7-9 anni		16-20 anni
Os naviculare	3-5 anni			
Os cuboideum	3-6 menses			
Os cuneiforme I Os cuneiforme II Os cuneiforme III	2-3 anni 2-3 anni 10-12 menses			
Ossa metatarsi	3 menses fetales	C. epiphysiale 3-4 anni		15-19 anni
Phalanges	2,5-9 menses fetales	3-4 anni		15-22 anni

C - centrum

**DISTRIBUIREA FAȚETELOR/SEMIFAȚETELOR ARTICULARE
PE CORPURILE VERTEBRELOR TORACICE
РАСПРЕДЕЛЕНИЕ СУСТАВНЫХ ЯМОК/ПОЛУЯМОК
НА ТЕЛАХ ГРУДНЫХ ПОЗВОНКОВ
DISTRIBUTION OF THE COSTAL FACETS
ON THE VERTEBRAL BODIES**



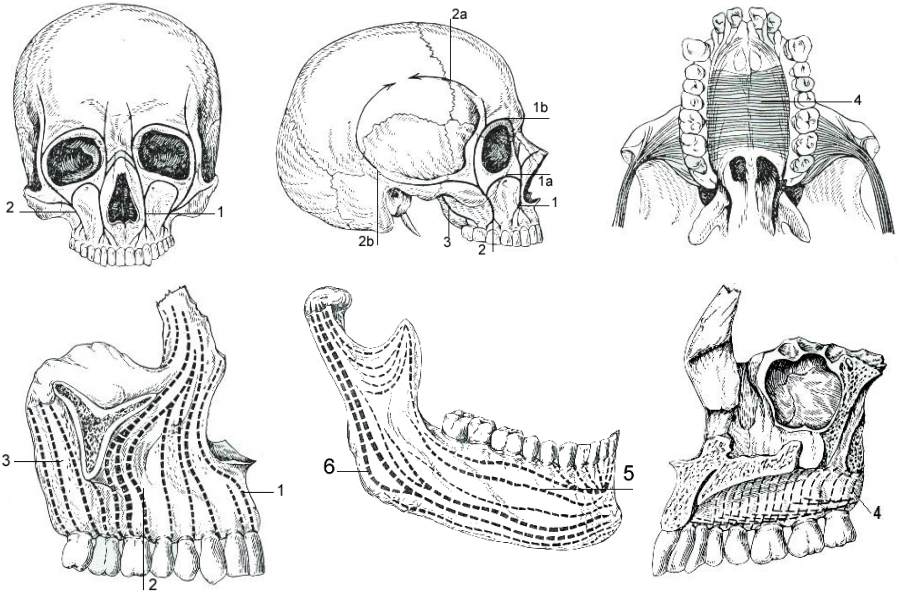
SCHEMA PUNCTELOR CRANIOMETRICE
 (după N. Diaconescu, N. Rottemberg, V. Niculescu, 1979)
СХЕМА КРАНИОМЕТРИЧЕСКИХ ТОЧЕК
THE SCHEME OF THE CRANIOMETRICAL POINTS



1 - gnathion;
 2 - spina mentalis;
 3 - punctum incisivum inferius;
 4 - punctum incisivum superius;
 5 - punctum nasospinale;
 6 - rhinyon;
 7 - dakryon;
 8 - nasion;
 9 - glabella;
 10 - ophrion;
 11 - pterion;

12 - sutura coronalis;
 13 - bregma;
 14 - stephanion;
 15 - obelion;
 16 - lambda;
 17 - opistocranium;
 18 - inion;
 19 - asterion;
 20 - punctum auriculare;
 21 - gonion;
 22 - punctum ossis zygomatici.

STĂLPII ȘI CĂPRIORII DE REZISTENȚĂ AI VISCEROCRANIULUI
 (după С.С. Михайлов, 1984)
КОНТРОРСЫ ЛИЦЕВОГО ЧЕРЕПА
RESISTANCE PILLARS OF THE VISCERAL CRANIUM



1. *Sustentaculum (columna, linea sustentaculi) anterior (caninum seu nasofrontale);*
 1a – *linea infraorbitalis;*
 1b – *linea supraorbitalis;*
2. *Sustentaculum medium (zygomaticum seu alveolo-zygomaticum);*
 2a – *linea anterior;*
 2b – *linea posterior;*
3. *Sustentaculum posterius (pterygopalatinum seu pterygoideum);*
4. *Linea resistentiae palati (palati ossei);*
5. *Linea trajecta alveolaris;*
6. *Linea trajecta ascendens.*

**CĂPRIORII ȘI ARCURILE DE REZISTENȚĂ ALE BAZEI CRANIULUI.
LINIILE CELOR MAI FRECVENTE FRACTURI**

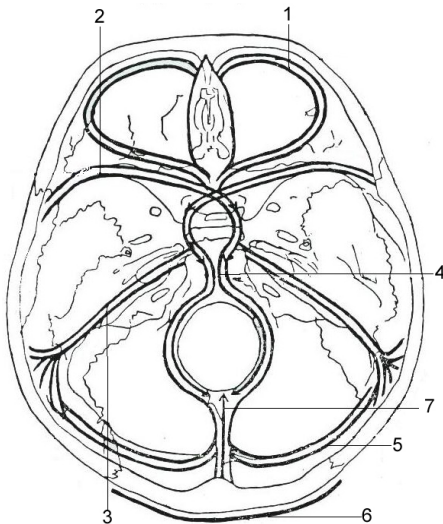
(după I.Pasat, 1995)

КОНТРОРСЫ ОСНОВАНИЯ ЧЕРЕПА.

ЛИНИИ НАИБОЛЕЕ ЧАСТЫХ ПЕРЕЛОМОВ

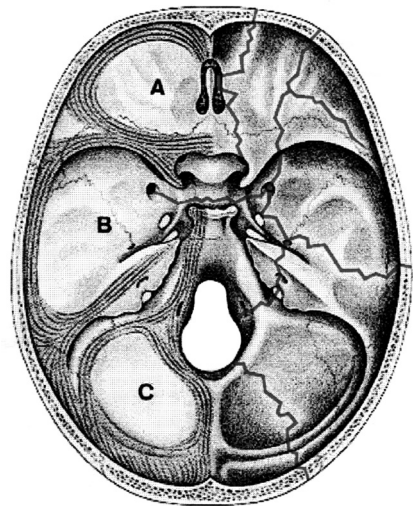
STRUCTURES OF RESISTANCE OF THE BASE OF THE SKULL.

THE LINES OF THE MOST FREQUENT FRACTURES

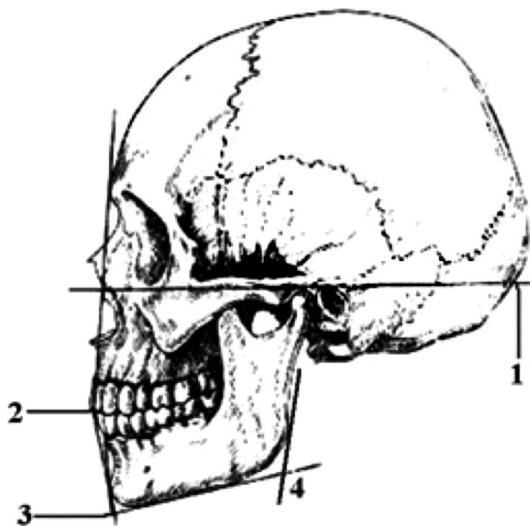


1. *Arcus orbitalis seu arcus transversus I (frontalis), seu linea sustentaculi (resistentiae frontalis);*
2. *Jugum sphenoidale et alae minores ossis sphenoidalis (arcus transversus II, orbitosphenoidalis seu columna anterior);*
3. *Margo inferior partium petrosarum temporalium (arcus transversus III, petromastoideus seu posterior);*
4. *Basis ossea mediosagittalis;*
5. *Sinus transversus (arcus transversus IV);*
6. *Linea resistentiae occipitalis;*
7. *Linea cristae occipitalis.*

*A – fossa cranii anterior;
B – fossa cranii media;
C – fossa cranii posterior.*

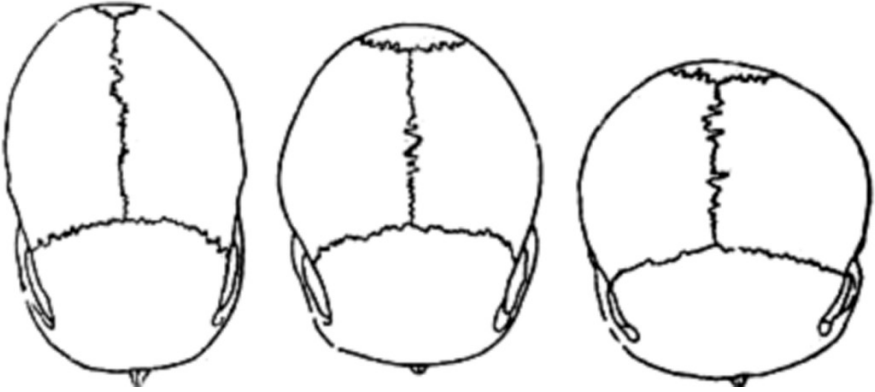


ORIZONTALA FRANKFURT,
UNGHIU SIMFIZIAN ȘI CEL MAXILAR
(după N. Diaconescu, 1979)
ФРАНКФУРТСКАЯ ГОРИЗОНТАЛЬ, СИМФИЗИАЛЬНЫЙ
И ЧЕЛЮСТНОЙ УГЛЫ
FRANKFURT HORIZONTAL LINE,
THE SYMPHISIAL AND MAXILLARY ANGLES



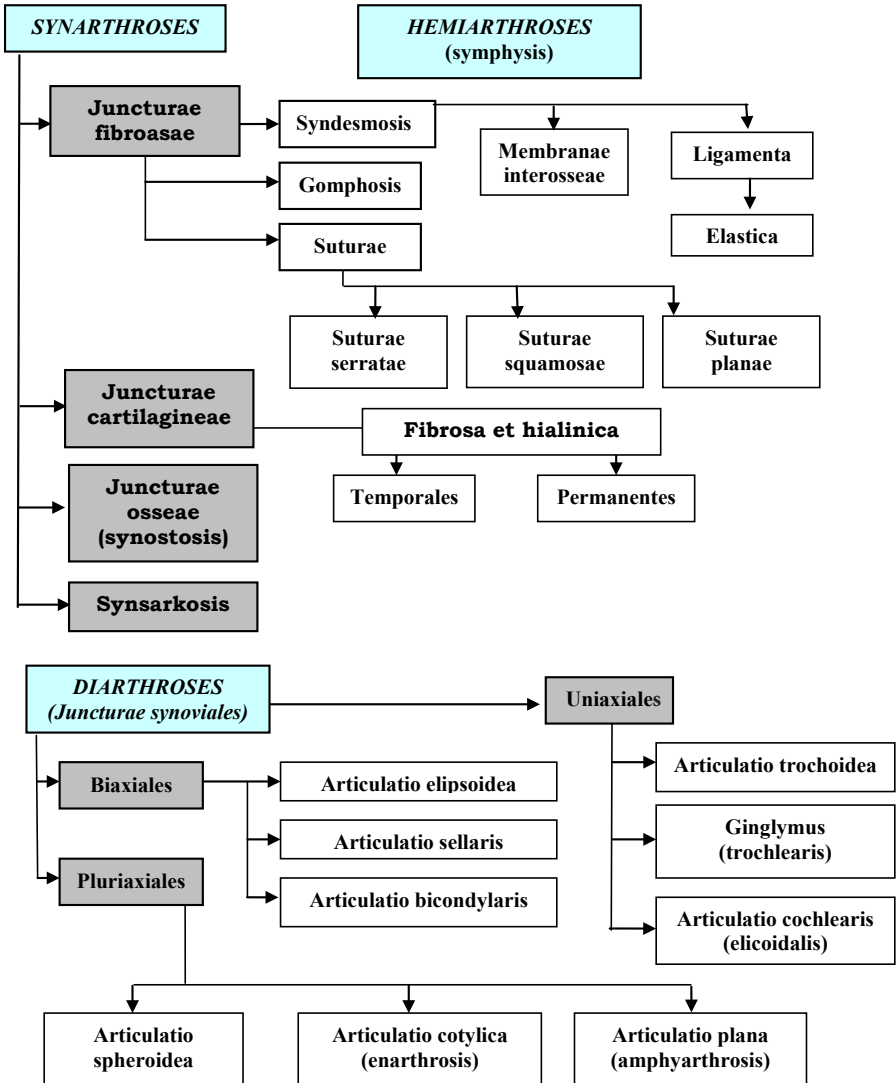
- 1 - *planum horizontale (Frankfurt)*;
- 2 - *angulus maxillaris*;
- 3 - *angulus symphysialis*;
- 4 - *angulus mandibulae*.

TIPURI DE CRANII
ТИПЫ ЧЕРЕПА
SHAPES OF THE SKULL



- 1 - *dolichocephalia*;
2 - *mesocephalia*;
3 - *brachicephalia*.

CLASIFICAREA JONCTIUNILOR OASELOR
КЛАССИФИКАЦИЯ СОЕДИНЕНИЙ КОСТЕЙ
CLASSIFICATION OF THE BONE JOINING

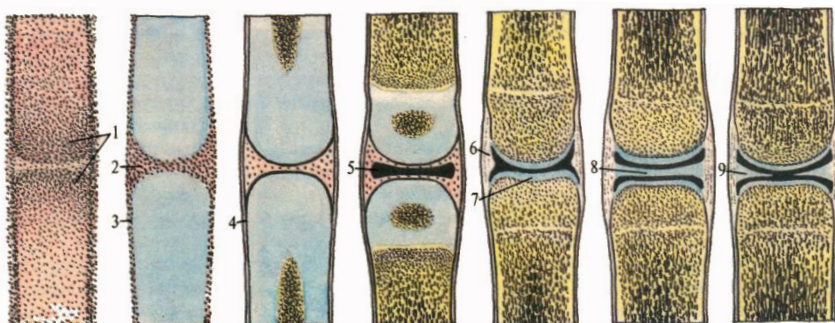


DEZVOLTAREA UNEI ARTICULAȚII (DIARTROZE)

(după P.Д. Синельников, Я.Р. Синельников, 1989)

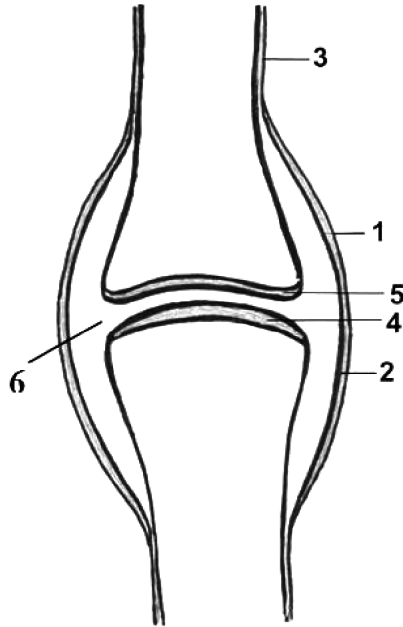
РАЗВИТИЕ СУСТАВА

DEVELOPMENT OF A JOINT

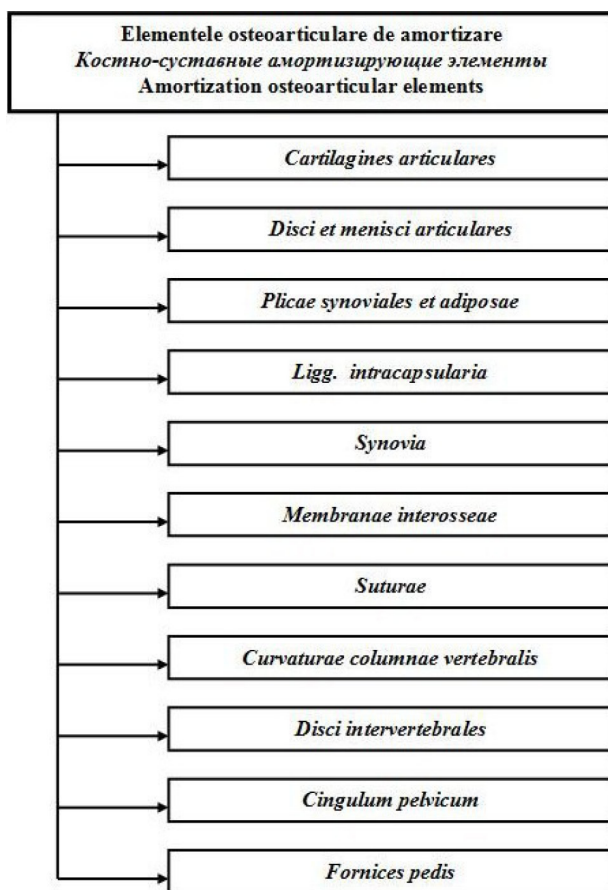
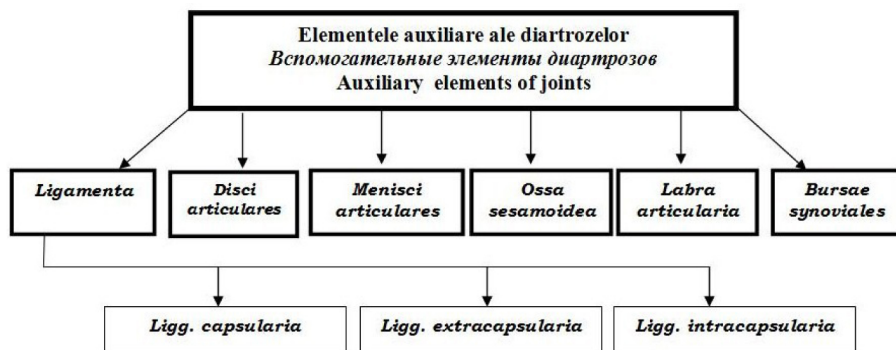


- 1 – *syncytium mesenchymatis (status praecartilaginosus)*;
- 2 – *locus cavitationis articulationis futurae*;
- 3 – *perichondrium*;
- 4 – *periosteum*;
- 5 – *cavum articulationis*;
- 6 – *capsula articularis*;
- 7 – *cartilago articularis*;
- 8 – *discus articularis*;
- 9 – *meniscus*.

ELEMENTELE PRINCIPALE ALE UNEI DIARTROZE
ОСНОВНЫЕ ЭЛЕМЕНТЫ ДИАРТРОЗОВ
THE MAIN ELEMENTS OF A DIARTHROSIS



- 1 – *capsula articularis: membrana fibrosa (stratum fibrosum);*
- 2 – *capsula articularis: membrana synovialis (stratum synoviale);*
- 3 – *periosteum;*
- 4, 5 – *facies articulares et cartilago articularis;*
- 6 – *cavitas articularis.*

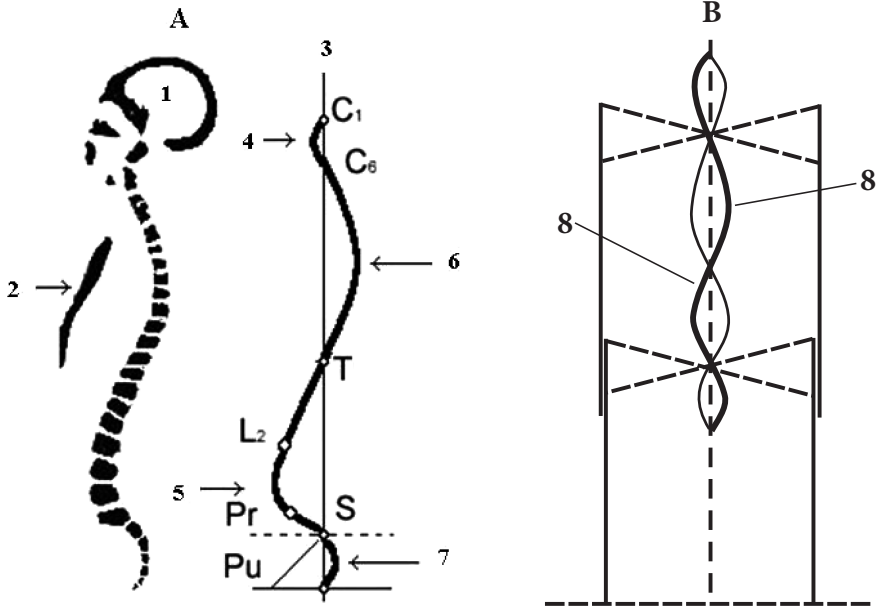


CURBURILE COLOANEI VERTEBRALE

(după Г.Ф. Иванов)

ИЗГИБЫ ПОЗВОНОЧНОГО СТОЛБА

CURVATURES OF THE SPINAL COLUMN



A. Planum sagittale
(lordosis et kyphosis)

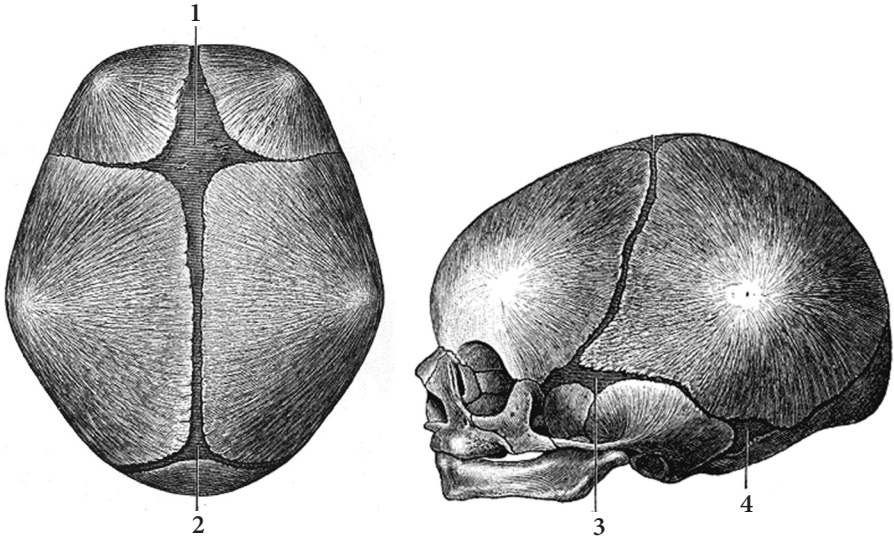
- 1 - cranium;
- 2 - sternum;
- 3 - axis verticalis;
- 4 - lordosis cervicalis (lordosis colli);
- 5 - lordosis lumbalis;
- 6 - kyphosis thoracica;
- 7 - kyphosis sacralis.

B. Planum frontale

8 - scoliosis;

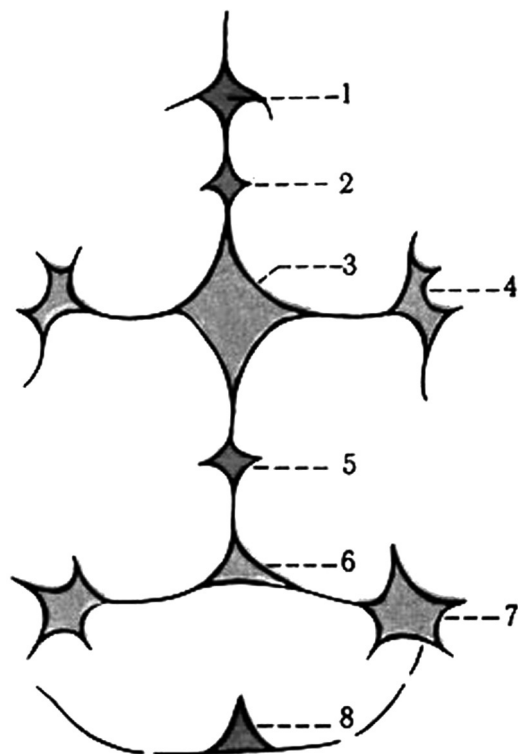
- Pr. - promontorium;
- Pu. - pubis;
- C. - regio cervicalis;
- T. - regio thoracica;
- L. - regio lumbalis;
- S. - regio sacralis.

FONTANELELE
РОДНИЧКИ
FONTANELLES



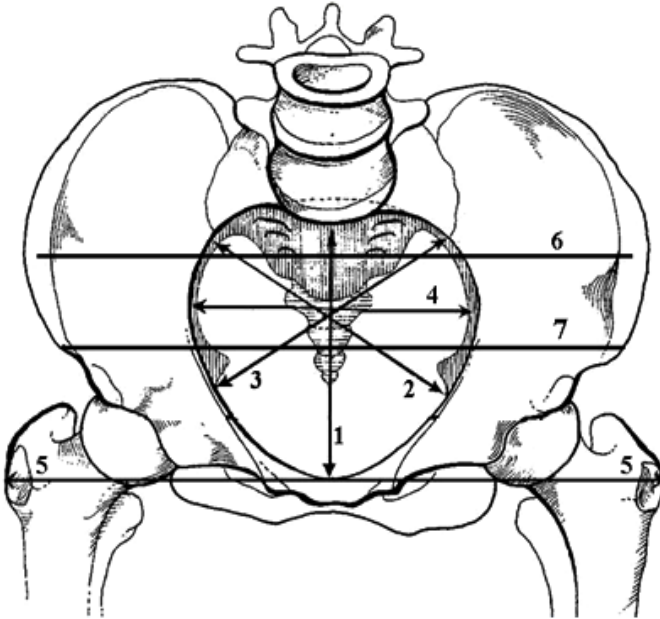
- 1 – fonticulus anterior, frontalis seu coronarius, seu bregmaticus;
2 – fonticulus posterior, occipitalis seu lambdoideus;
3 – fonticulus sphenoidalis seu ptericus;
4 – fonticulus mastoideus seu astericus.

FONTANELELE SUPLIMENTARE
ДОБАВОЧНЫЕ РОДНИЧКИ
SUPPLEMENTARY FONTANELLES



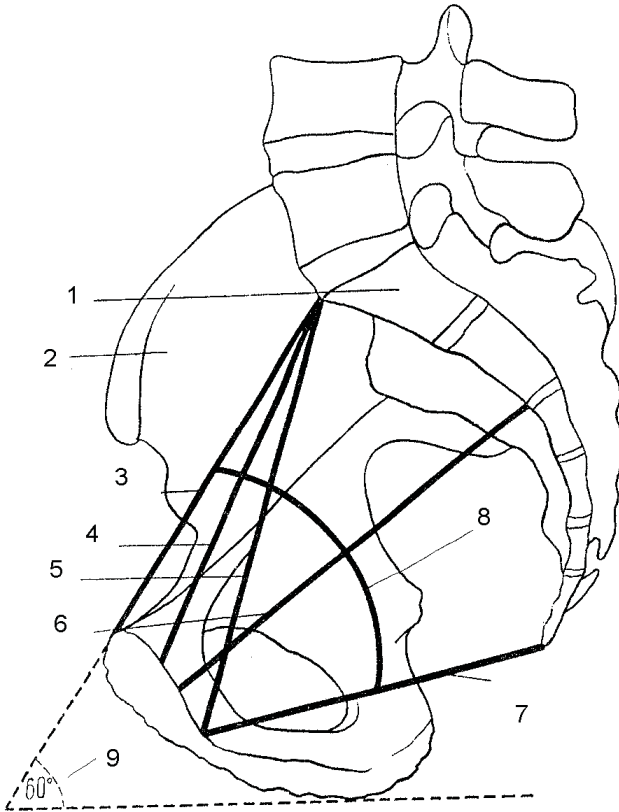
- 1 - *fonticulus nasofrontalis seu glabellaris*;
- 2 - *fonticulus mediofrontalis*;
- 3 - *fonticulus anterior, frontalis seu coronarius*;
- 4 - *fonticulus sphenoidalis seu ptericus*;
- 5 - *fonticulus sagittalis*;
- 6 - *fonticulus posterior, occipitalis seu bregmaticus*;
- 7 - *fonticulus mastoideus seu astericus*;
- 8 - *fonticulus cerebellaris*.

DIAMETRELE BAZINULUI (VEDERE SUPERIOARĂ)
РАЗМЕРЫ ТАЗА (ВИД СВЕРХУ)
DIAMETERS OF THE PELVIS (SUPERIOR VIEW)



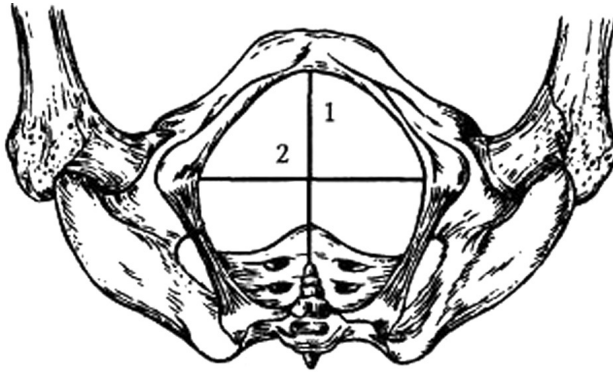
- 1 - *conjugatae*;
- 2 - *diameter obliqua sinistra (distantia obliqua sinistra)*;
- 3 - *diameter obliqua dextra (distantia obliqua dextra)*;
- 4 - *diameter transversa*;
- 5 - *distantia intertrochanterica*;
- 6 - *distantia intercrystalis*;
- 7 - *distantia interspinosa*.

DIAMETRELE BAZINULUI (VEDERE LATERALĂ)
РАЗМЕРЫ ТАЗА (САГИТТАЛЬНЫЙ РАСПИЛ)
DIAMETERS OF THE PELVIS (LATERAL VIEW)



- 1 – *os sacrum;*
- 2 – *os coxae;*
- 3 – *conjugata anatomica;*
- 4 – *conjugata vera;*
- 5 – *conjugata diagonalis;*
- 6 – *conjugata recta cavitatis pelvis (diameter recta);*
- 7 – *conjugata recta aperturae pelvis inferioris (diameter recta);*
- 8 – *axis pelvis;*
- 9 – *inclinatio pelvis.*

DIAMETRELE BAZINULUI (VEDERE INFERIOARĂ)
РАЗМЕРЫ ТАЗА (ВИД СНИЗУ)
DIAMETERS OF THE PELVIS (INFERIOR VIEW)



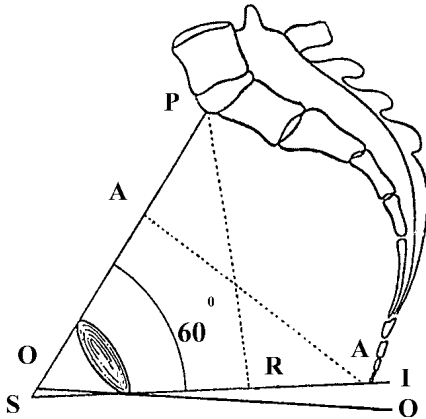
- 1 - *diameter recta*;
2 - *diameter transversa*.

ÎNCLINAȚIA PELVISULUI

(după V.Papilian, 1998)

НАКЛОН ТАЗА

INCLINATION OF THE PELVIS



P.S. - planum aperturae pelvis superioris;

S. I. - planum aperturae pelvis inferioris;

O.O. - planum horizontale;

A.A. - axis aperturae pelvis superioris;

P.R. - axis aperturae pelvis inferioris.

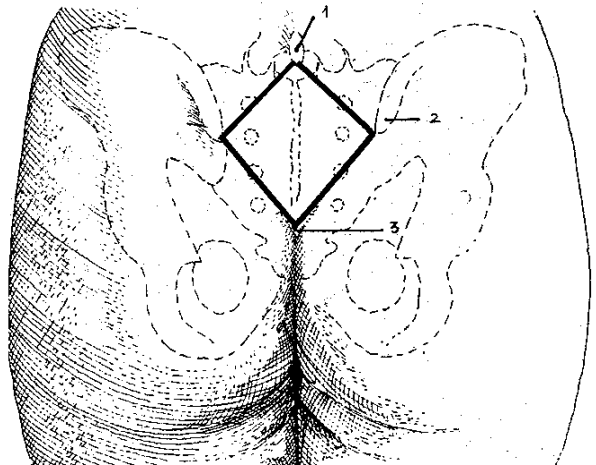
ROMBUL LUI MICHAELIS

(după N.Diaconescu, N.Rottemberg, V.Niculescu, 1979)

РОМБ МИХАЕЛИС

MICHAELIS' RHOMB

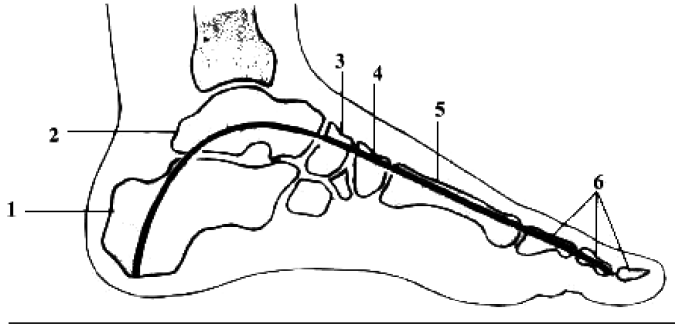
- 1 - processus spinosus L5;
- 2 - spina iliaca posterior superior;
- 3 - apex plicae intergluteae.



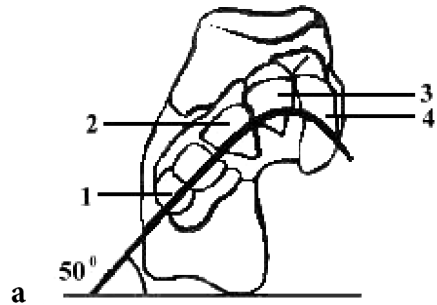
**BOLȚILE LONGITUDINALĂ ȘI TRANSVERSALĂ
ALE PICIORULUI**

(după H.K. Лысенков, 1958)

**ПРОДОЛЬНЫЙ И ПОПЕРЕЧНЫЙ СВОДЫ СТОПЫ
LONGITUDINAL AND TRANSVERSE ARCHES OF THE FOOT**

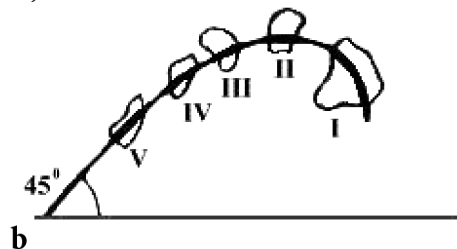


- 1 - calcaneus;
- 2 - talus;
- 3 - os naviculare;
- 4 - os cuneiforme intermedium;
- 5 - os metatarsi II;
- 6 - ossa (phalanges) digitorum II.



- a. Sectio articulationum tarsometatarsalium;
- b. Sectio ossium metatarsalium;

- 1 - os cuboideum;
- 2, 3, 4 - ossa cuneiformia;
- I - V - ossa metatarsi.

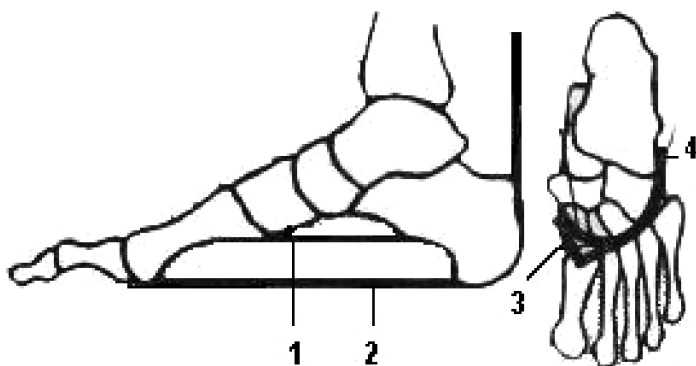


“TIRANȚII” PLANTARI

(după Л.В. Пупышев, 1999)

«ЗАТЯЖКИ» СВОДОВ СТОПЫ

PLANTAR TIGHTENING DEVICES OF THE FOOT



- 1 - *lig. plantare longum*;
- 2 - *aponeurosis plantaris*;
- 3 - *tendo m. tibialis anterioris*;
- 4 - *tendo m. fibularis (peronei) longi*.

CLASIFICAREA MUȘCHILOR
КЛАССИФИКАЦИЯ МЫШЦ
CLASSIFICATION OF MUSCLES

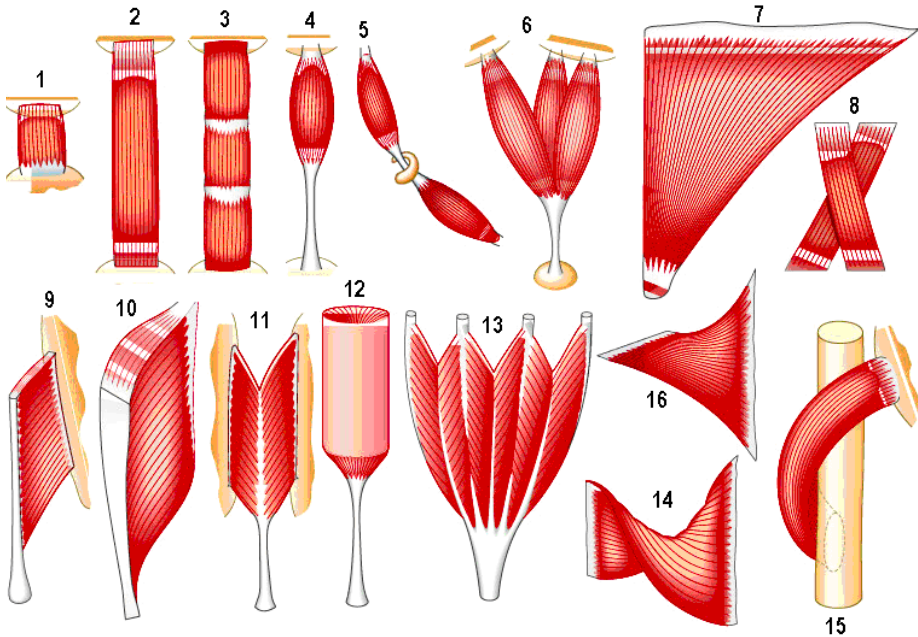
I	II	III	IV	V	VI	VII
După geneză	După topografie	După funcție	După formă	După orientarea fibrelor musculare	În raport cu articulațiile	Sub aspect histologic
Mm. autohtoni, mm. truncopetali, mm. truncofugali.	Mm. capului și gâtului, mm.trunchiului, mm.membrelor.	Mm. sinergiști, mm. antagoniști, mm. flexori, mm. extensori, mm. pronatori, mm. supinatori, mm. abductori, mm. adductori, mm. rotatori, mm. levatori, mm. depresori, mm. constrictori	Mm. lungi, mm. scurți, mm. lați, mm. rotunzi, mm. pătrați, mm. triunghiulari, mm. piramidali, mm. dințați, mm. romboizi, mm. bicipitali, mm. tricipitali, mm. cvadricipitali, mm. biventerii.	Mm. fusiformi, mm. recti, mm. oblici, mm. transversali, mm. orbiculari, mm. unipenați, mm. bipenați, mm. multipenați, mm. spiralați, mm. radiari, mm. circulari.	Mm. nuliarticulari, mm. uniarticulari, mm. biarticulari, mm. multiarticulari.	Mm. striati, mm. netezi, m.cardiac.

I	II	III	IV	V	VI	VII
По происхождению	По топографии	По функции	По форме	По направлению мышечных волокон	По отношению к суставам	В гистологическом аспекте
<p>Аутохтонные (местные) мышцы</p> <p>Трункотетальные мышцы</p> <p>Трункофугальные мышцы</p>	<p>Мышцы головы и шеи</p> <p>Мышцы туловища</p> <p>Мышцы конечностей</p>	<p>Синергисты</p> <p>Антагонисты</p> <p>Сгибатели</p> <p>Разгибатели</p> <p>Пронаторы</p> <p>Супинаторы</p> <p>Приводящие</p> <p>Отводящие</p> <p>Вращатели</p> <p>Поднимающие</p> <p>Опускающие</p> <p>Сжиматели</p>	<p>Длинные мышцы</p> <p>Короткие мышцы</p> <p>Широкие мышцы</p> <p>Круглые мышцы</p> <p>Четырёхугольные мышцы</p> <p>Трёхугольные мышцы</p> <p>Пирамидальные мышцы</p> <p>Вращатели</p> <p>Поднимающие</p> <p>Опускающие</p> <p>Ромбовидные мышцы</p> <p>Двуглавые мышцы</p> <p>Трёхглавые мышцы</p> <p>Четырёхглавые мышцы</p> <p>Двубрюшные мышцы</p>	<p>Веретенообразные мышцы</p> <p>Прямые мышцы</p> <p>Косые мышцы</p> <p>Поперечные мышцы</p> <p>Круговые мышцы</p> <p>Одноперистые мышцы</p> <p>Двуперистые мышцы</p> <p>Многоперистые мышцы</p> <p>Спиралевидные мышцы</p> <p>Лучистые мышцы</p> <p>Циркулярные мышцы</p>	<p>Мышцы не действующие на суставы</p> <p>Одноуставные мышцы</p> <p>Двуставные мышцы</p> <p>Многоуставные мышцы</p>	<p>Поперечно-полосатые мышцы</p> <p>Гладкие мышцы</p> <p>Сердечная мышца</p>

I	II	III	IV	V	VI	VII
According to their development	According to their topography	According to the function	According to their shape	According to the direction of the fibers	According to the relation to the joints	According to histological structure
Autochthonous muscles Truncipetal muscles Truncifugal muscles	Muscles of the head and neck Muscles of the trunk Muscles of the limbs	Synergetic Antagonistic Flexors Extensors Pronators Supinators Abductors Adductors Rotators Levators Depressors Constrictors	Long Short Broad Rounded Quadrate Triangular Pyramidal Serrate Rhomboid Bicipital Tricipital Quadriceptal Biventer	Fusiform Straight Oblique Transverse Orbicular Unipennate Bipennate Multipennate Spiral Radial Circular	Nonarticular Uniauticular Biauticular Multiauticular	Striped Smooth Cardiac

I	II	III	IV	V	VI	VII
Secundum genesis	Secundum topographiam	Secundum functionem	Secundum formam	Secundum directionem fibrarum musculorum	Secundum articulationem	Secundum structuram hystologicam
Mm. autochthoni Mm. truncopetales Mm. truncofugales	Mm. capitis et colli Mm. trunci Mm. membrorum (extremitatum)	Mm. synergici Mm. antagonisti Mm. flexores Mm. extensores Mm. pronatores Mm. supinatores Mm. abductores Mm. adductores Mm. rotatores Mm. levatores Mm. depressores Mm. constrictores	Mm. longi Mm. breves Mm. lati Mm. teretes Mm. quadrati Mm. triangulares Mm. pyramidales Mm. serrati Mm. rhomboidei Mm. bicipites Mm. tricipites Mm. quadricipites Mm. biventri	Mm. fusiformes Mm. recti Mm. obliqui Mm. transversi Mm. orbiculares Mm. unipennati Mm. bipennati Mm. multipennati Mm. spirales Mm. radiales Mm. circulares	Mm. uniarticulares Mm. biarticulares Mm. multiarticulares	Mm. striati Mm. nonstriati M. cardiacus

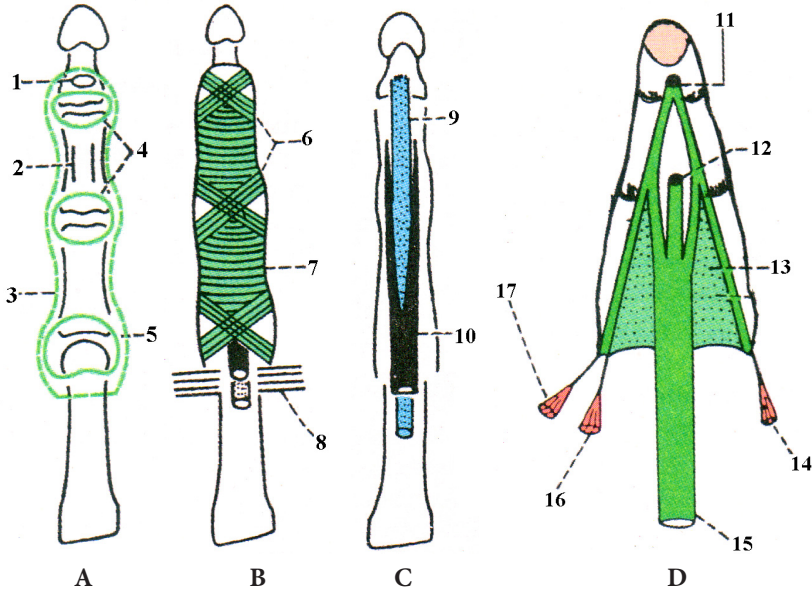
CLASIFICAREA MUȘCHILOR
DUPĂ ORIENTAREA FIBRELOR MUSCULARE
КЛАССИФИКАЦИЯ МЫШЦ
ПО НАПРАВЛЕНИЮ МЫШЕЧНЫХ ВОЛОКОН
CLASSIFICATION OF MUSCLES ACCORDING
TO THE ORIENTATION OF THE MUSCULAR FIBERS



- 1 – *m. quadratus*;
- 2 – *m. rectus*;
- 3 – *m. rectus (intersecciones tendineae)*;
- 4 – *m. fusiformis*;
- 5 – *m. biventer*;
- 6 – *m. triceps*;
- 7 – *m. triangularis*;

- 8 – *m. cruciformis*;
- 9, 10 – *m. unipennatus*;
- 11 – *m. bipennatus*;
- 12 – *m. radialis*;
- 13 – *m. multipennatus*;
- 14, 15, 16 – *mm. spirales*.

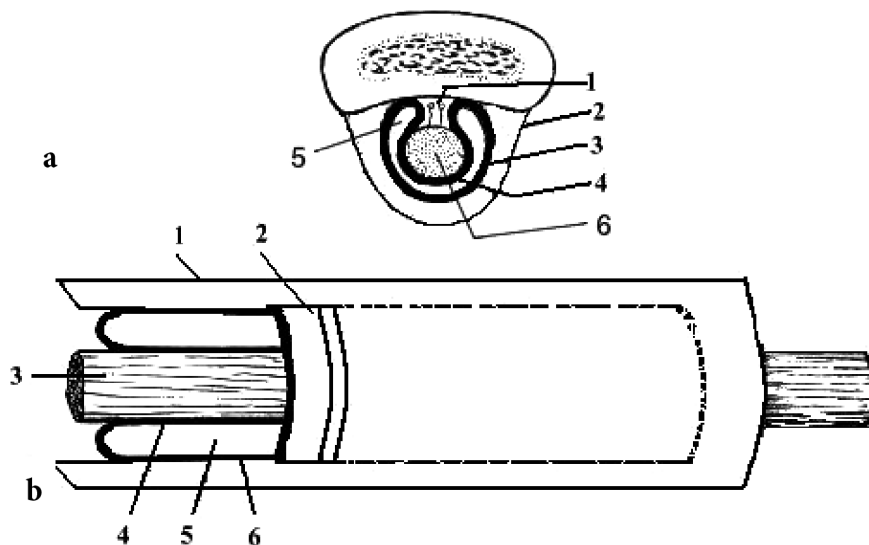
**TENDOANELE ȘI TECILE FIBROASE ALE FLEXORILOR
(A, B, C) ȘI EXTENSORILOR (D) CU FORMAȚIUNILE ADIACENTE**
СУХОЖИЛИЯ И ФИБРОЗНЫЕ ВЛАГАЛИЩА СГИБАТЕЛЕЙ (А, В, С) И
РАЗГИБАТЕЛЕЙ (D) С ПРИЛЕГАЮЩИМИ СТРУКТУРАМИ
**TENDONS AND SYNOVIAL SHEATHS OF THE FLEXOR MUSCLES
(A, B, C) AND EXTENSOR MUSCLES (D) WITH ADJACENT FORMATIONS**



- 1 – insertio *m. flexoris digitorum profundi*;
- 2 – insertio *m. flexoris digitorum superficialis*;
- 3 – *vagina fibrosa mm. flexorum*;
- 4 – *capsula art. interphalangeae*;
- 5 – *capsula art. metacarpophalangeae*;
- 6 – *decussatio fibrosa vaginae fibrosae*;
- 7 – *fibrae transversales vaginae fibrosae*;
- 8 – *lig. metacarpeum transversum profundum*;
- 9 – *tendo m. flexoris digitorum profundi*;

- 10 – *m. flexor digitorum superficialis*;
- 11 – *basis phalangis distalis (facies dorsalis)*;
- 12 – *basis phalangis media (facies dorsalis)*;
- 13 – *extensio tendinis m. extensoris digitorum*;
- 14 – *m. interosseus dorsalis III*;
- 15 – *tendo m. extensoris digitorum*;
- 16 – *m. interosseus dorsalis II*;
- 17 – *m. lumbricalis II*.

STRUCTURA TECILOR SINOVIALE
СТРОЕНИЕ СИНОВИАЛЬНЫХ ВЛАГАЛИЩ
STRUCTURE OF THE SYNOVIAL SHEATHS



a. Sectio transversalis

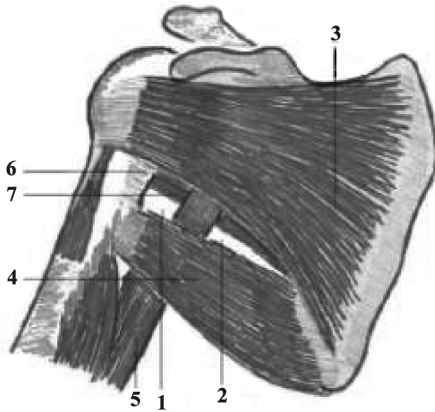
- 1 – mesotendineum;
- 2 – vagina osteofibrosa;
- 3 – lamina parietalis vaginae synovialis tendinis;
- 4 – lamina visceralis vaginae synovialis tendinis;
- 5 – cavitas vaginae synovialis;
- 6 – tendo.

b. Sectio longitudinalis

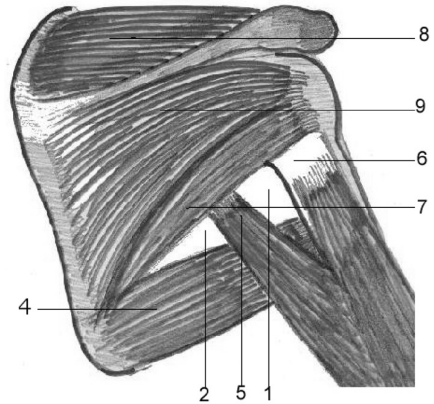
- 1 – vagina fibrosa tendinis;
- 2 – vagina synovialis tendinis;
- 3 – tendo;
- 4 – lamina visceralis vaginae synovialis tendinis;
- 5 – cavitas vaginae synovialis;
- 6 – lamina parietalis vaginae synovialis tendinis.

ORIFICIILE TRILATER ȘI PATRULATER
ЧЕТЫРЕХ- И ТРЕХСТОРОННЕЕ ОТВЕРСТИЯ
TRIANGULAR AND QUADRANGULAR ORIFICES (openings)

A. Facies anterior

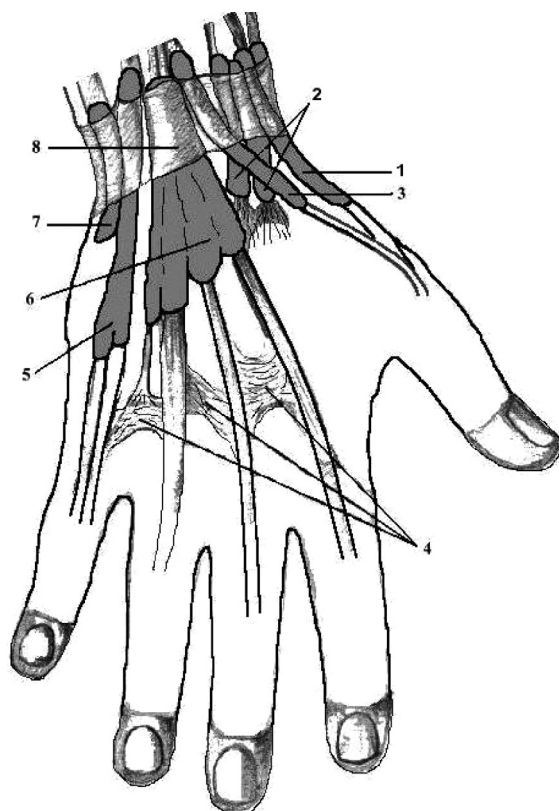


B. Facies posterior



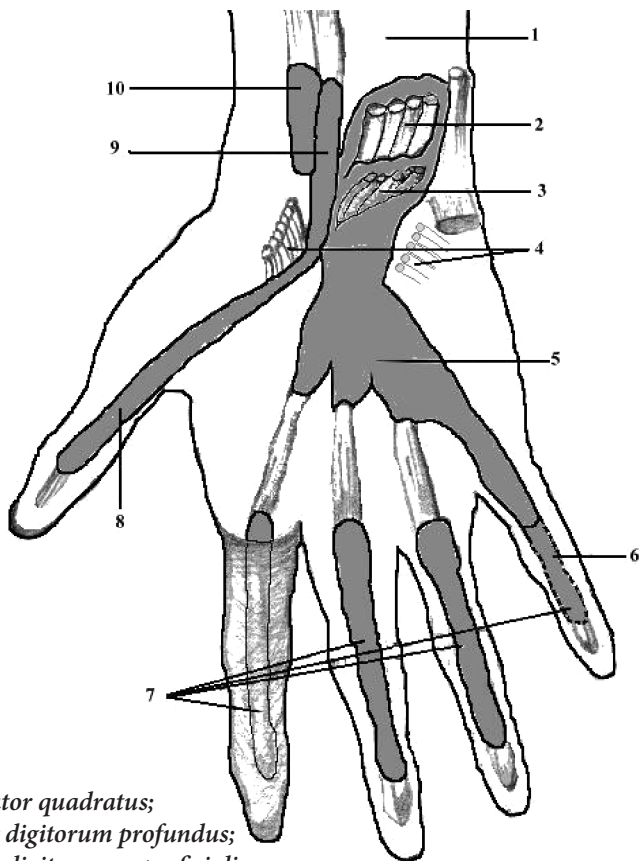
- 1 – foramen quadrilaterum;**
- 2 – foramen trilaterum;**
- 3 – m. subscapularis;**
- 4 – m. teres major;**
- 5 – caput longum m. tricipitis brachii;**
- 6 – collum chirurgicum humeri;**
- 7 – m. teres minor;**
- 8 – m. supraspinatus;**
- 9 – m. infraspinatus.**

TECILE SINOVIALE ALE MĂINII (FAȚA DORSALĂ)
 СИНОВИАЛЬНЫЕ ВЛАГАЛИЩА КИСТИ (ТЫЛЬНАЯ ПОВЕРХНОСТЬ)
 SYNOVIAL SHEATHS OF THE HAND (DORSAL SURFACE)



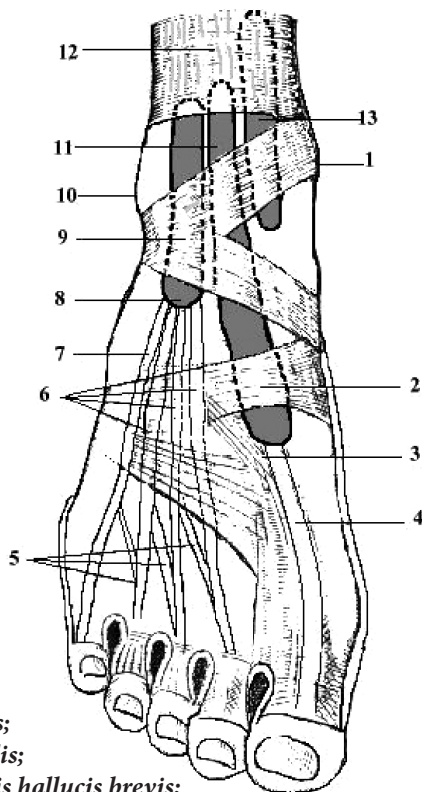
- 1 – *vagina synovialis tendinum mm. abductoris longi et extensoris brevis pollicis;*
 2 – *vagina synovialis tendinum mm. extensorum carpi radialium (longus et brevis);*
 3 – *vagina synovialis tendinis m. extensoris pollicis longi;*
 4 – *connexus intertendineus;*
 5 – *vagina synovialis tendinis m. extensoris digiti minimi;*
 6 – *vagina synovialis tendinum mm. extensoris digitorum et extensoris indicis;*
 7 – *vagina synovialis tendinis m. extensoris carpi ulnaris;*
 8 – *retinaculum musculorum extensorum.*

TECILE SINOVIALE ALE MĂINII (FAȚA PALMARĂ)
 СИНОВИАЛЬНЫЕ ВЛАГАЛИЩА КИСТИ
 (ЛАДОННАЯ ПОВЕРХНОСТЬ)
 SYNOVIAL SHEATHS OF THE HAND (PALMAR SURFACE)



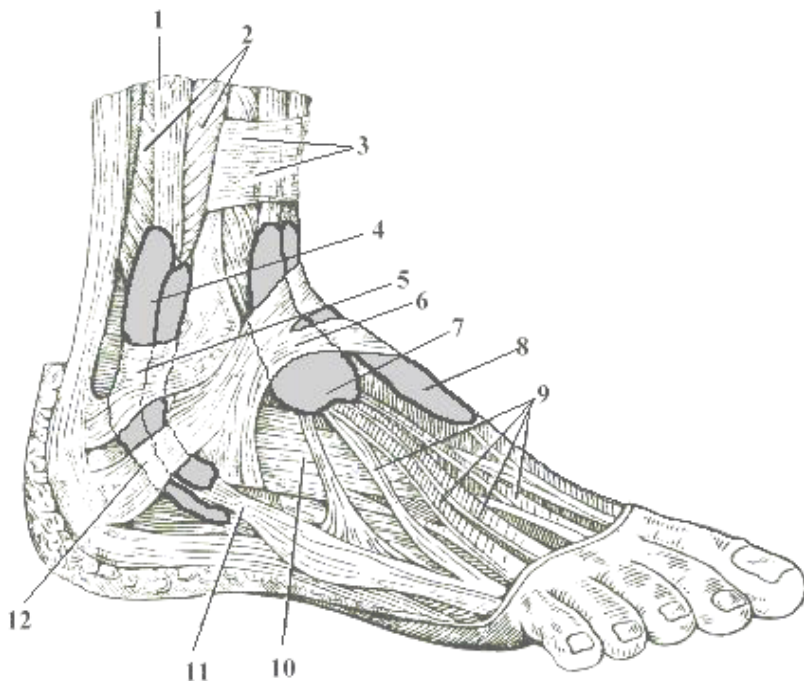
- 1 - *m. pronator quadratus*;
 2 - *m. flexor digitorum profundus*;
 3 - *m. flexor digitorum superficialis*;
 4 - *retinaculum musculorum flexorum*;
 5 - *vagina synovialis communis mm. flexorum*;
 6 - *vagina synovialis tendinum mm. flexorum digiti minimi*;
 7 - *vagina synovialis tendinum digitorum manus*;
 8, 9 - *vagina synovialis tendinis m. flexoris pollicis longi*;
 10 - *vagina synovialis tendinis m. flexoris carpi radialis*.

TECILE SINOVIALE ALE PICIORULUI (FAȚA DORSALĂ)
 СИНОВИАЛЬНЫЕ ВЛАГАЛИЩА СТОПЫ
 (ТЫЛЬНАЯ ПОВЕРХНОСТЬ)
 SYNOVIAL SHEATHS OF THE FOOT (DORSAL SURFACE)



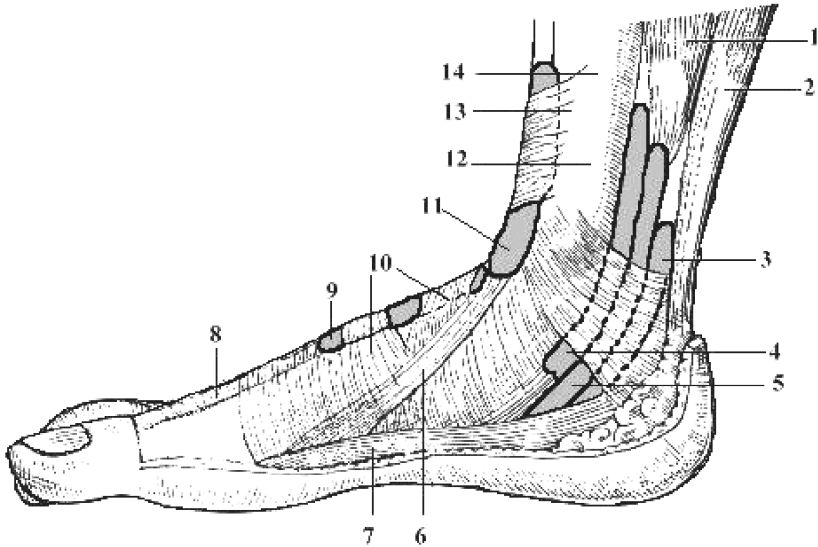
- 1 - malleolus medialis;
 2 - fascia dorsalis pedis;
 3 - tendo m. extensoris hallucis brevis;
 4 - tendo m. extensoris hallucis longi;
 5 - tendines m. extensoris digitorum brevis;
 6 - tendines m. extensoris digitorum longi;
 7 - tendo m. peronei (fibularis) tertii;
 8 - vagina synovialis tendinum m. extensoris digitorum longi;
 9 - retinaculum mm. extensorum inferius;
 10 - malleolus lateralis;
 11 - vagina synovialis tendinis m. extensoris hallucis longi;
 12 - retinaculum mm. extensorum superius;
 13 - vagina synovialis tendinis m. tibialis anterioris.

**TECILE SINOVIALE ALE PICIORULUI
(ASPECT DORSOLATERAL)
СИНОВИАЛЬНЫЕ ВЛАГАЛИЩА СТОПЫ
(ЛАТЕРАЛЬНАЯ ПОВЕРХНОСТЬ)
SYNOVIAL SHEATHS OF THE FOOT (LATERAL VIEW)**



- 1 – *m. peroneus (fibularis) longus*;
- 2 – *m. peroneus (fibularis) brevis*;
- 3 – *retinaculum mm. extensorum superius*;
- 4 – *vagina synovialis mm. peroneorum (fibularium) communis*;
- 5 – *retinaculum mm. peroneorum (fibularium) superius*;
- 6 – *retinaculum mm. extensorum inferius*;
- 7 – *vagina synovialis tendinum m. extensoris digitorum pedis longi*;
- 8 – *vagina synovialis tendinis m. extensoris hallucis longi*;
- 9 – *tendines m. extensoris digitorum longi*;
- 10 – *m. extensor digitorum brevis*;
- 11 – *tendo m. peronei (fibularis) brevis*;
- 12 – *retinaculum mm. peroneorum (fibularium) inferius*.

TECILE SINOVIALE ALE PICIORULUI (FAȚA MEDIALĂ)
СИНОВИАЛЬНЫЕ ВЛАГАЛИЩА СТОПЫ
(МЕДИАЛЬНАЯ ПОВЕРХНОСТЬ)
SYNOVIAL SHEATHS OF THE FOOT (MEDIAL SURFACE)



- 1 – *m. flexor digitorum longus*;
- 2 – *tendo calcanei (Achillis)*;
- 3 – *vagina synovialis tendinis m. flexoris hallucis longi*;
- 4 – *vagina synovialis tendinis m. tibialis posterioris*;
- 5 – *vagina synovialis tendinum m. flexoris digitorum pedis longi*;
- 6 – *tendo m. tibialis anterioris*;
- 7 – *m. abductor hallucis*;
- 8 – *tendo m. extensoris hallucis longi*;
- 9 – *vagina synovialis tendinis m. extensoris hallucis longi*;
- 10 – *retinaculum mm. extensorum inferius*;
- 11 – *vagina synovialis tendinis m. tibialis anterioris*;
- 12 – *malleolus medialis*;
- 13 – *retinaculum mm. extensorum superius*;
- 14 – *tibia*.

SECȚIUNE TRANSVERSALĂ PRIN TEACA
MUȘCHIULUI DREPT ABDOMINAL

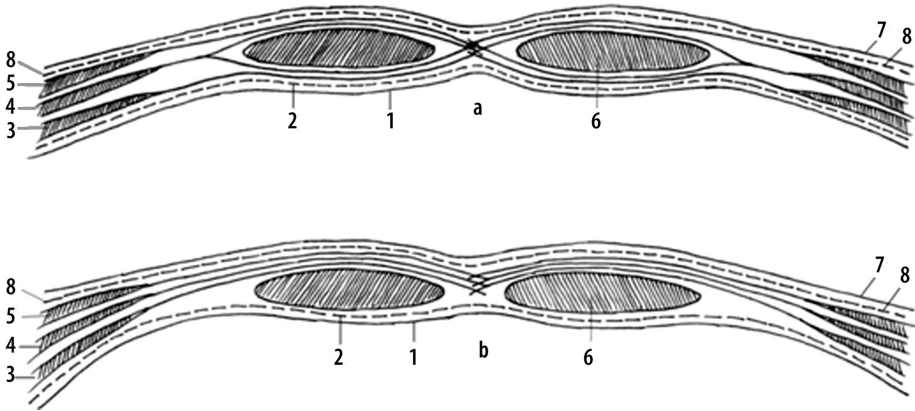
(a. mai sus de linea arcuată (Douglas); b. mai jos de linea arcuată)

ПОПЕРЕЧНЫЙ РАЗРЕЗ ЧЕРЕЗ ВЛАГАЛИЩЕ
ПРЯМЫХ МЫШЦ ЖИВОТА

(a. выше дугообразной линии (Douglas); b. ниже дугообразной линии)

TRANSVERSE SECTION THROUGH THE SHEATH
OF THE RECTUS ABDOMINIS MUSCLE

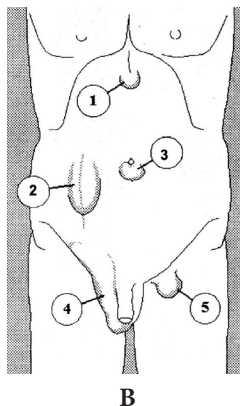
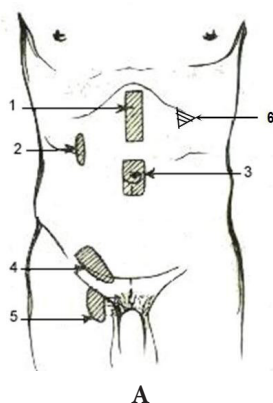
(a. above the arcuate line (Douglas); b. below the arcuate line)



- 1 - *peritoneum parietale*;
- 2 - *fascia transversalis*;
- 3 - *m. transversus abdominis*;
- 4 - *m. obliquus internus abdominis*;
- 5 - *m. obliquus externus abdominis*;
- 6 - *m. rectus abdominis*;
- 7 - *cutis*;
- 8 - *fascia abdominis propria*.

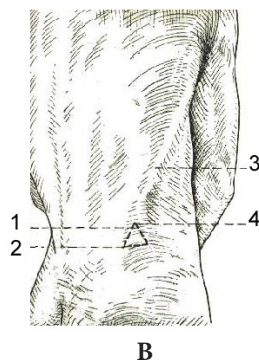
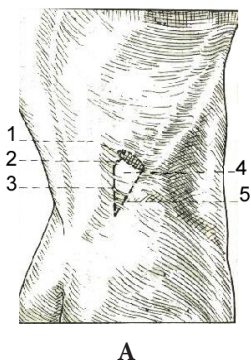
**ZONELE SLABE ALE ABDOMENULUI
ȘI UNELE TIPURI DE HERNII**

СЛАБЫЕ МЕСТА ЖИВОТА И НЕКОТОРЫЕ ВИДЫ ГРЫЖ
WEAK AREAS OF THE ABDOMINAL WALL AND SOME TYPES OF HERNIAS



- 1 – *linea alba*;
2 – *linea semilunaris (Spigelius)*;
3 – *annulus umbilicalis*;
4 – *canalis inguinalis (paries posterior)*;
5 – *canalis femoralis (annulus femoralis)*;
6 – *trigonum subcostale (Волынский)*.

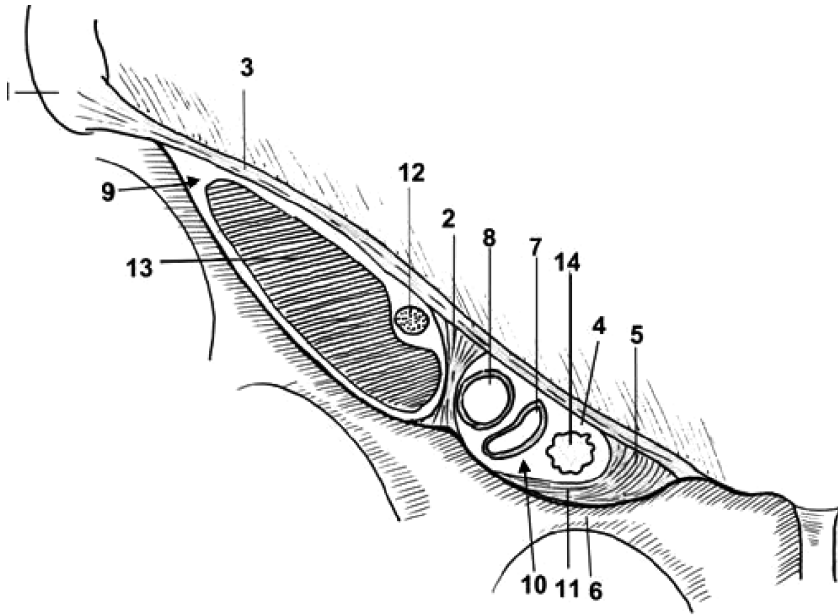
- 1 – *hernia lineae albae*;
2 – *hernia lineae semilunaris*;
3 – *hernia umbilicalis*;
4 – *hernia inguinalis*;
5 – *hernia femoralis*.



- 1 – *costae XII*;
2 – *m. serratus posterior inferior*;
3 – *m. erector spinae*;
4 – *tetragonum lumbale (Grynfeld - Лесгафм, Krause)*;
5 – *m. obliquus internus abdominis*.

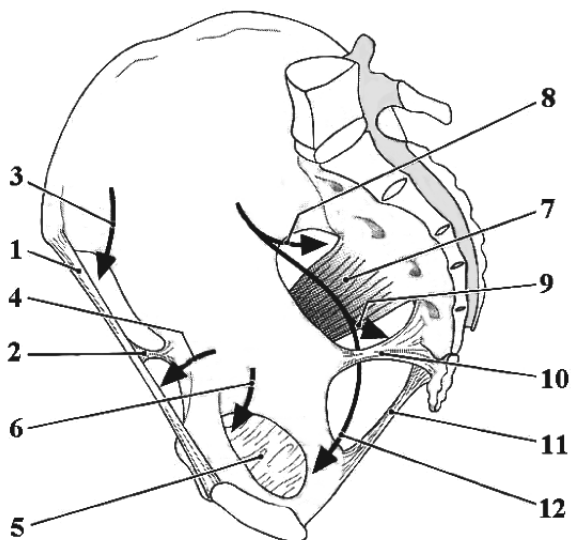
- 1 – *trigonum lumbale (Petit)*;
2 – *crista iliaca*;
3 – *margo anterior m. latissimi dorsi*;
4 – *margo posterior m. obliqui externi abdominis*.

LACUNELE VASCULARĂ ȘI MUSCULARĂ
СОСУДИСТАЯ И МЫШЕЧНАЯ ЛАКУНЫ
LACUNA VASORUM AND LACUNA MUSCULORUM



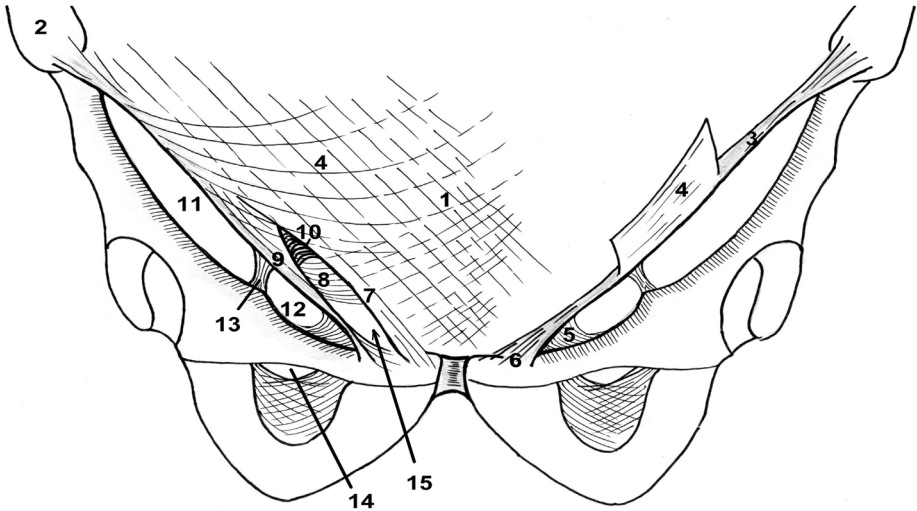
- 1 - spina iliaca anterior superior;
- 2 - arcus iliopectineus;
- 3 - lig. inguinale (Poupartii);
- 4 - annulus femoralis;
- 5 - lig. lacunare (Gimbernati);
- 6 - ramus superior ossis pubis;
- 7 - v. femoralis;
- 8 - a. femoralis;
- 9 - lacuna musculorum;
- 10 - lacuna vasorum;
- 11 - lig. pectineale (Cooperi);
- 12 - n. femoralis;
- 13 - m. iliopsoas;
- 14 - nodus lymphaticus Rosenmüller-Пурозов.

ТОПОГРАФИЯ БАЗИЛУЛИ
 ТОПОГРАФИЯ ТАЗА
 TOPOGRAPHY OF THE PELVIS



- 1 - *ligamentum inguinale*;
- 2 - *arcus iliopectineus*;
- 3 - *lacuna musculorum*;
- 4 - *lacuna vasorum*;
- 5 - *membrana obturatoria*;
- 6 - *canalis obturatorius*;
- 7 - *m. piriformis*;
- 8 - *foramen suprapiriforme*;
- 9 - *foramen infrapiriforme*;
- 10 - *lig. sacrospinale*;
- 11 - *lig. sacrotuberale*;
- 12 - *canalis pudendalis (Alcock)*.

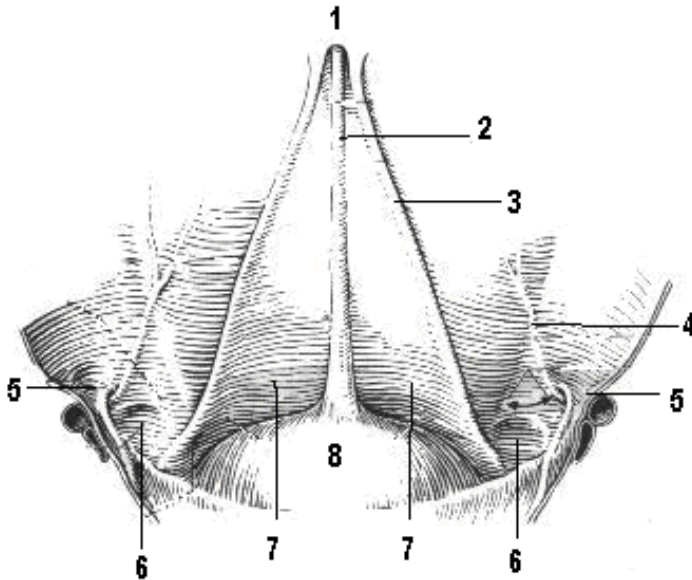
**STRUCTURA LIGAMENTULUI INGHINAL
 ŞI A PERETELUI ANTERIOR AL CANALULUI INGHINAL**
**СТРОЕНИЕ ПАХОВОЙ СВЯЗКИ
 И НАРУЖНОЙ СТЕНКИ ПАХОВОГО КАНАЛА**
**STRUCTURE OF THE INGUINAL LIGAMENT AND OF ANTERIOR
 WALL OF THE INGUINAL CANAL**



1 - linea alba;
 2 - spina iliaca anterior superior;
 3 - lig. inguinale (Poupartii);
 4 - aponeurosis m. obliqui abdominis
 externi;
 5 - lig. lacunare (Gimbernati);
 6 - tuberculum pubicum;
 7 - crus superius;

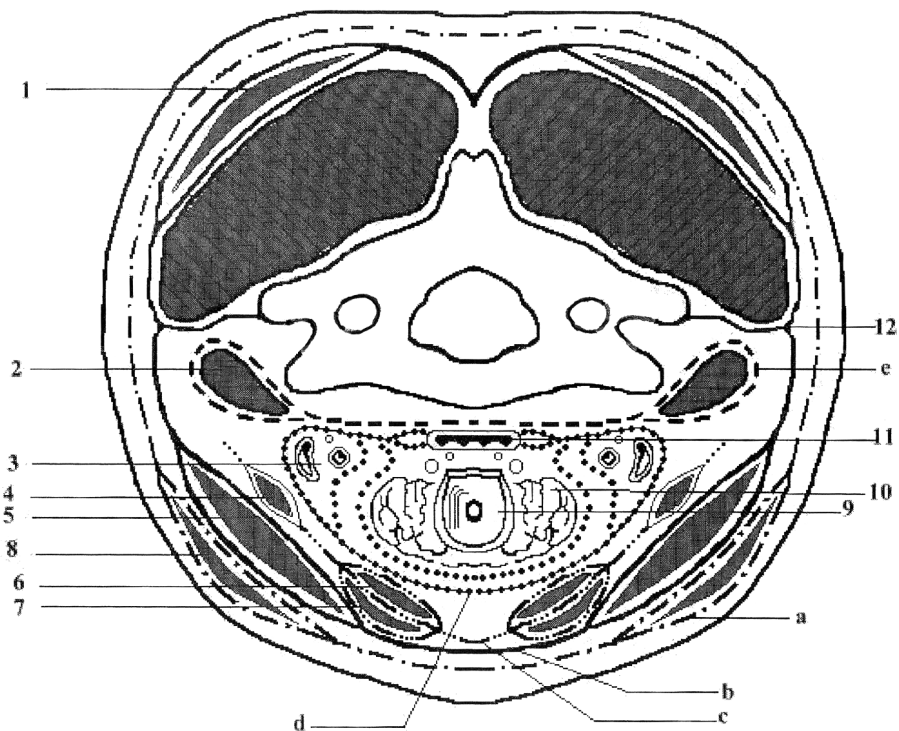
8 - lig. reflexum (Collesi);
 9 - crus inferius;
 10 - fibrae intercrurales;
 11 - lacuna musculorum;
 12 - lacuna vasorum;
 13 - arcus iliopectineus;
 14 - canalis obturatorius;
 15 - annulus inguinalis superficialis.

FAȚA POSTERIOARĂ A PERETELUI ABDOMINAL ANTERIOR
ЗАДНЯЯ ПОВЕРХНОСТЬ ПЕРЕДНЕЙ СТЕНКИ ЖИВОТА
POSTERIOR SURFACE OF THE ANTERIOR ABDOMINAL WALL



- 1 - umbilicus;
- 2 - plica umbilicalis mediana;
- 3 - plica umbilicalis medialis;
- 4 - plica umbilicalis lateralis;
- 5 - fossa inguinalis lateralis;
- 6 - fossa inguinalis medialis;
- 7 - fossa supravesicalis;
- 8 - vesica urinaria.

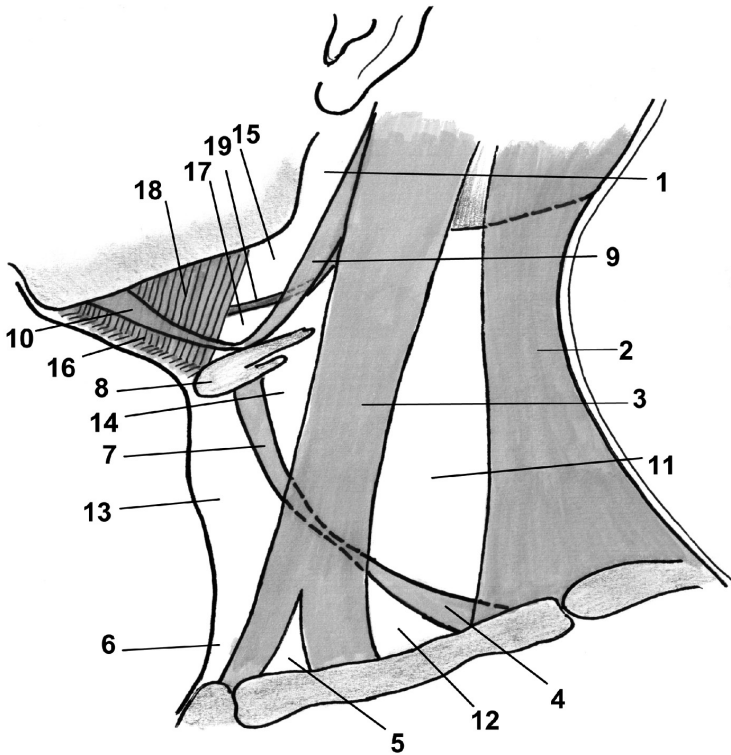
FASCIALE GĂTULUI
 (după V.H. Шевкуненко)
ФАСЦИИ ШЕИ
FASCIAE OF THE NECK



- 1 – *m. trapezius*;
- 2 – *mm. scaleni et mm. prevertebrales*;
- 3 – *fasciculus neurovascularis*;
- 4 – *m. omohyoideus*;
- 5 – *m. sternocleidomastoideus*;
- 6 – *m. thyreoideoideus*;
- 7 – *m. sternohyoideus*;
- 8 – *platysma*;
- 9 – *larynx*;
- 10 – *glandula thyroidea*;
- 11 – *oesophagus*;
- 12 – *septum intermusculare*.

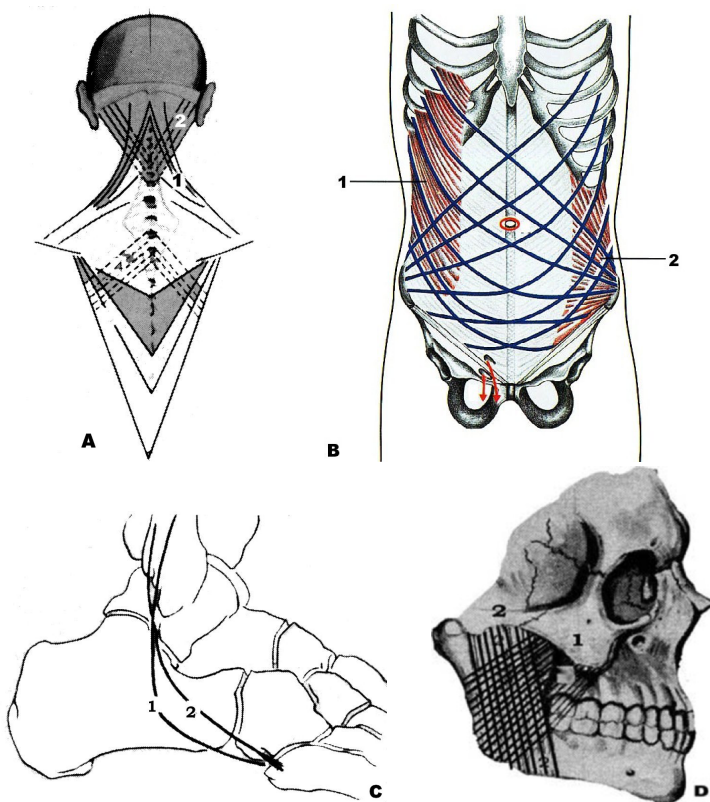
- a* – *fascia colli superficialis (I)*;
- b* – *lamina superficialis fasciae colli propriae (II)*;
- c* – *lamina profunda fasciae colli propriae (III)*;
- d* – *fascia endocervicalis (lamina parietalis et visceralis) (IV)*;
- e* – *fascia prevertebralis (V)*.

TRIUNGHIIURILE GÂTULUI
 ТРЕУГОЛЬНИКИ ШЕИ
 TRIANGLES OF THE NECK



- | | |
|--|---|
| 1 - fossa retromandibularis; | 12 - trigonum omoclaviculare (musculare); |
| 2 - m. trapezius; | 13 - trigonum omotracheale; |
| 3 - m. sternocleidomastoideus; | 14 - trigonum caroticum; |
| 4 - m. omohyoideus (venter inferior); | 15 - trigonum submandibulare; |
| 5 - fossa supraclavicularis minor; | 16 - trigonum submentale; |
| 6 - fossa jugularis; | 17 - trigonum a. lingualis (Пупозов); |
| 7 - m. omohyoideus (venter superior); | 18 - m. mylohyoideus; |
| 8 - os hyoideum; | 19 - n. hypoglossus (XII). |
| 9 - m. digastricus (venter posterior); | |
| 10 - m. digastricus (venter anterior); | |
| 11 - trigonum omotrapezoideum; | |

VARIANTE DE ÎNCRUCIȘĂRI MUSCULARE
 ВАРИАНТЫ ПЕРЕКРЁСТА МЫШЦ
 VARIANTS OF MUSCULAR CROSSINGS

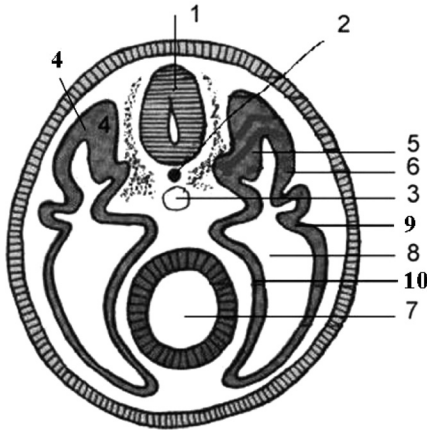


A, B – încrucișările mușchilor situați în diferite straturi ale aceleiași regiuni;
 C – încrucișările sinergiștilor ce merg în aceeași direcție;
 D – încrucișările fasciculelor musculare din componența aceluiași mușchi (m. masseter).

A, B – перекрест мышц расположенных в разных слоях одной области;
 C – перекрест мышц синергистов, имеющих одинаковое направление;
 D – перекрест мышечных пучков в составе той же мышцы (m. masseter).

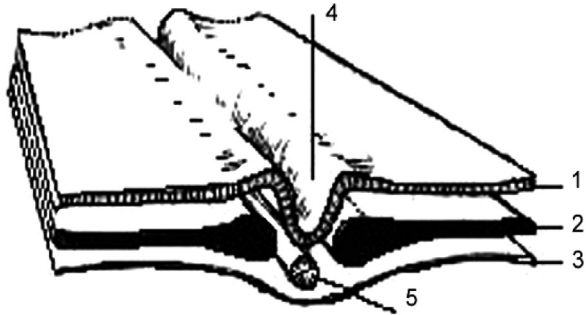
A, B – muscular crossings located at different layers of the same region;
 C – muscular crossing of sinergetic muscles that have the same direction;
 D – crossings of the muscular fascicles within the same muscle.

EMBRION ÎN SECȚIUNE TRANSVERSALĂ
ПОПЕРЕЧНЫЙ РАЗРЕЗ ТУЛОВИЩА ЗАРОДЫША
TRANSVERSE SECTION THROUGH THE EMBRYONIC TRUNK



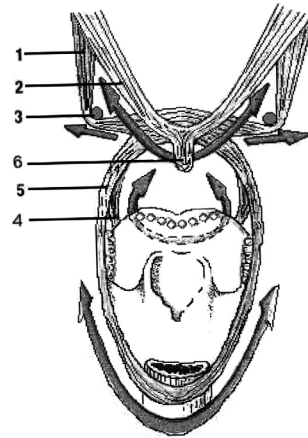
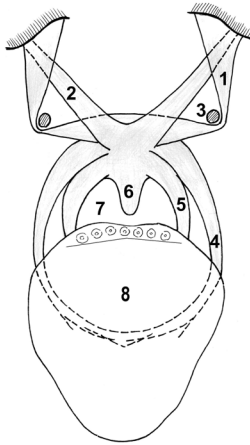
- 1 – *tubulus neuralis;*
- 2 – *chorda dorsalis;*
- 3 – *aorta;*
- 4 – *sclerotom;*
- 5 – *myotom;*
- 6 – *dermatom;*
- 7 – *intestinum primarium;*
- 8 – *coeloma (cavitas corporis);*
- 9 – *somatopleura;*
- 10 – *splanchnopleura.*

FOIȚELE EMBRIONARE ȘI DERIVATELE LOR
ЗАРОДЫШЕВЫЕ (ЭМБРИОНАЛЬНЫЕ) ЛИСТКИ И ИХ ПРОИЗВОДНЫЕ
DERIVATIVES OF THE GERM LAYERS



- 1. *Ectoderma: textus nervosus, tegmina.*
- 2. *Mesoderma: skeleton, musculi striati et non-striati, tunica conjunctiva, systema urinarium, systema genitalia, systema cardiovasculare, glandulae endocrinae (gll. suprarenales, gll. sexuales); tunicae serosae cavittatis trunci (pleura, pericardium, peritoneum, tunica vaginalis testis).*
- 3. *Endoderma: systema digestorium cum glandulis accessoriis, tunica mucosa apparatus respiratorii, glandulae endocrinae (gl. thyroidea, gll. parathyroideae, thymus et pancreas).*
- 4. *Sulcus neuralis.*
- 5. *Chorda dorsalis.*

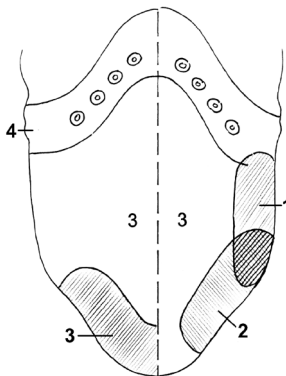
MUȘCHII PALATULUI MOALE. VESTIBULUL FARINGIAN (FAUCES)
МЫШЦЫ МЯГКОГО НЕБА. ПЕРЕШЕЕК ЗЕВА (ЗЕВ)
THE FAUCES OR ISTHMUS FAUCIUM



- 1 – *m. tensor veli palatini*;
- 2 – *m. levator veli palatini*;
- 3 – *hamulus pterygoideus*;
- 4 – *m. palatoglossus*;
- 5 – *m. palatopharyngeus*;
- 6 – *m. uvulae*;
- 7 – *isthmus faucium (fauces)*;
- 8 – *lingua*.

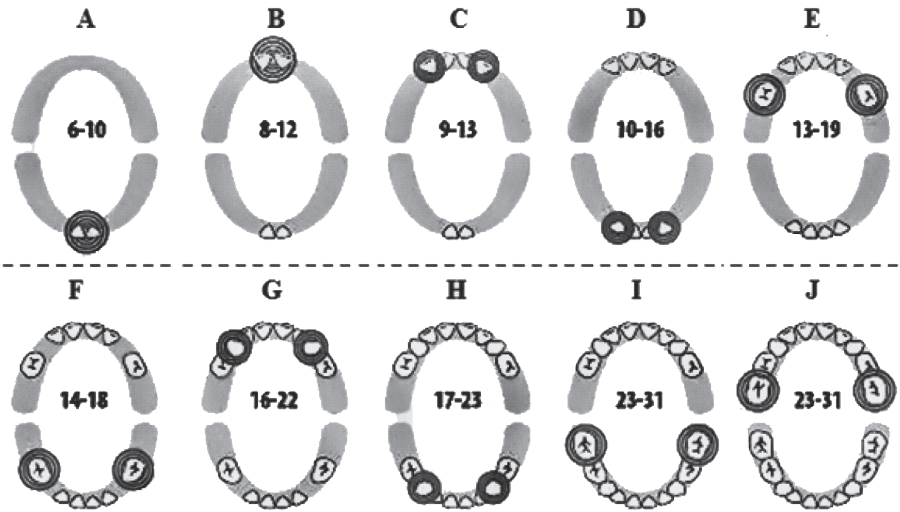
Acțiunea mușchilor din jurul vestibulului
Действие мышц расположенных вокруг зева
Action of the muscles surrounding the fauces

ZONELE DE PERCEPȚIE GUSTATIVĂ ALE LIMBII
ВКУСОВЫЕ ЗОНЫ ЯЗЫКА
GUSTATORY ZONES OF THE TONGUE



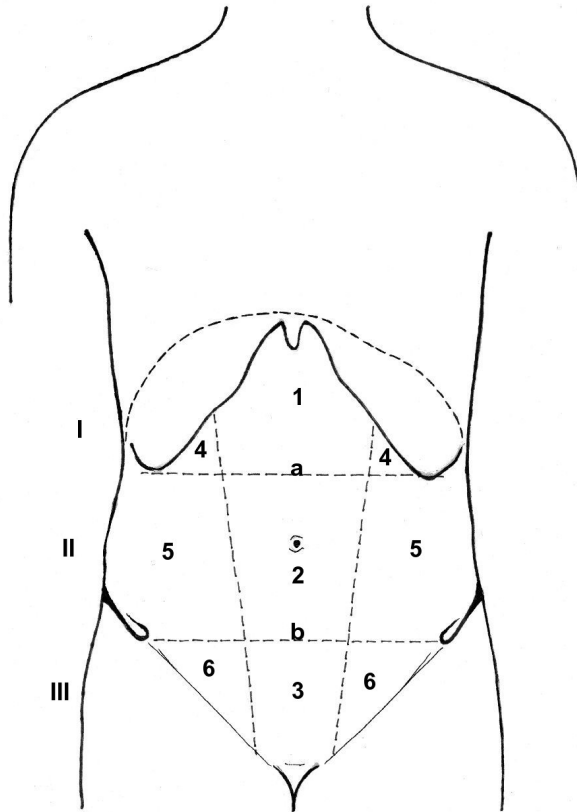
- 1 – *gustus acidus*;
- 2 – *gustus salsus*;
- 3 – *gustus dulcis*;
- 4 – *gustus amarus*.

TERMENELE DE ERUPȚIE A DINȚILOR DECIDUALI ȘI PERMANENȚI
СРОКИ ПРОРЕЗЫВАНИЯ МОЛОЧНЫХ И ПОСТОЯННЫХ ЗУБОВ
TERMS OF ERUPTION OF THE DECIDUOUS AND PERMANENT TEETH



	Dentes	Termeni eruptionis	
		Dentes decidui, menses	Dentes permanentes, anni
A	Dentes incisivi mediales inferiores	6 – 10 / 6 – 8	7 – 8
B	Dentes incisivi mediales superiores	8 – 12 / 7 – 9	7 – 8
C	Dentes incisivi laterales superiores	9 – 13 / 8 – 10	9 – 10
D	Dentes incisivi laterales inferiores	10 – 16 / 7 – 9	9 – 10
E	Dentes molares I superiores	13 – 19 / 16 – 21	7 – 8
F	Dentes molares I inferiores	14 – 18 / 12 – 16	6 – 7
G	Dentes canini superiores	16 – 22/ 15 – 20	11 – 12
H	Dentes canini inferiores	17 – 23	
	Dentes premolares I	–	9 – 10
	Dentes premolares II	–	9 – 11
I, J	Dentes molares II (superiores et inferiores)	23 – 31 / 21 – 30 >33	11 – 12
	Dentes molares III	–	16 – 24

REGIUNILE CLINICO-TOPOGRAFICE ALE PERETELUI
 ANTEROLATERAL AL ABDOMENULUI
 КЛИНИКО-ТОПОГРАФИЧЕСКИЕ ОБЛАСТИ
 ПЕРЕДНЕ-ЛАТЕРАЛЬНОЙ СТЕНКИ ЖИВОТА
 CLINICOTOPOGRAPHICAL REGIONS
 OF THE ANTERO-LATERAL ABDOMINAL WALL

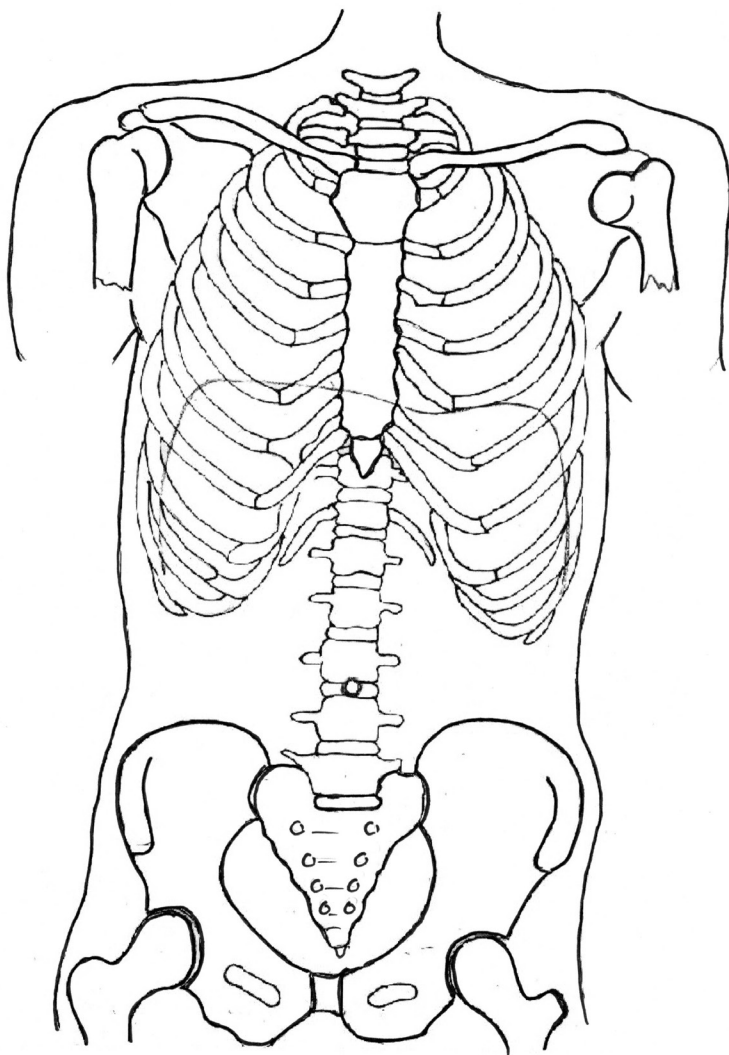


I. epigastrium;
 II. mesogastrium;
 III. hypogastrium.

a - linea bicostarum;
b - linea bispinarum.

1 - regio epigastrica;
 2 - regio umbilicalis;
 3 - regio pubica;
 4 - regiones hypochondriacae dextra et sinistra;
 5 - regiones laterales dextra et sinistra;
 6 - regiones inguinales dextra et sinistra.

**SCHEMĂ-MODEL PENTRU REPREZENTAREA
GRAFICĂ A PROIEȚIEI VISCERELOR
СХЕМА ДЛЯ НАНЕСЕНИЯ ПРОЕКЦИИ ОРГАНОВ
SCHEME FOR GRAPHICAL REPRESENTATION
OF THE PROJECTION OF THE VISCERA**

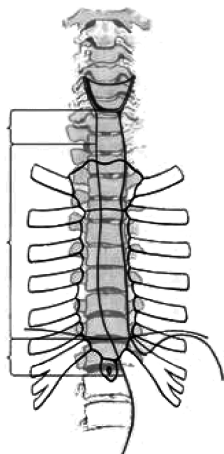


PORȚIUNILE ȘI SCHELETOTOPIA ESOFAGULUI

(diră R.Д. Синельников)

ЧАСТИ И СКЕЛЕТОТОПИЯ ПИЩЕВОДА

PARTS AND SCHELETOTOPY OF THE OESOPHAGUS

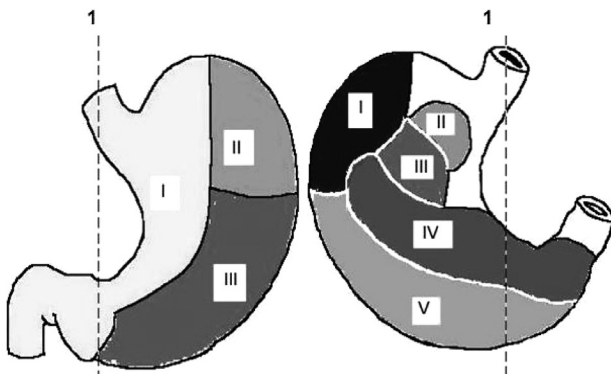


- 1 – *pars cervicalis*;
- 2 – *pars thoracica*;
- 3 – *pars abdominalis*.

ARIILE DE CONTACT ALE STOMACULUI CU ORGANELE ÎNVECINATE

ОБЛАСТИ СОПРИКОСНОВЕНИЯ ЖЕЛУДКА СО СМЕЖНЫМИ ОРГАНАМИ

CONTACT AREAS OF THE STOMACH WITH THE NEIGHBOURING ORGANS



A – paries anterior

B – paries posterior

- I. *Area hepatica*;
- II. *Area diaphragmatica*;
- III. *Area libera*.

- I. *Area lienalis*;
- II. *Area suprarenalis*;
- III. *Area renalis*;
- IV. *Area pancreatica*;
- V. *Area colica*.

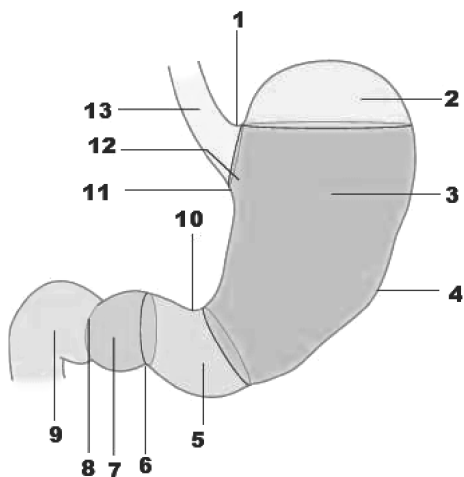
1 – *planum mediosagittale (medianum)*.

PORTIUNILE STOMACULUI

(după Gray, 2005)

ЧАСТИ ЖЕЛУДКА

PARTS OF THE STOMACH



- 1 – incisura cardiaca;
- 2 – fundus gastricus;
- 3 – corpus gastricum;
- 4 – curvatura major;
- 5 – antrum pyloricum;
- 6 – sulcus intermedius;
- 7 – canalis pyloricus;
- 8 – pylorus;
- 9 – duodenum;
- 10 – incisura angularis;
- 11 – curvatura minor;
- 12 – pars cardiaca (cardia);
- 13 – pars abdominalis oesophagi.

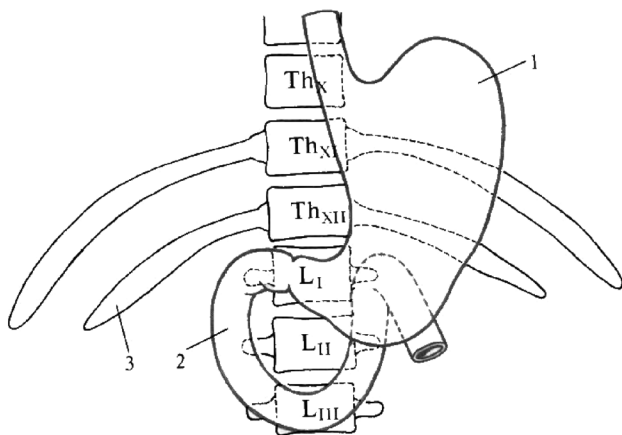
SCHELETOTOPIA STOMACULUI ȘI DUODENULUI

(după P. Д. Синельников, Я.Р. Синельников, 1990)

СКЕЛЕТОТОПИЯ ЖЕЛУДКА И ДВЕНАДЦАТИПЕРСТНОЙ КИШКИ

SKELETOTOPY OF THE STOMACH AND DUODENUM

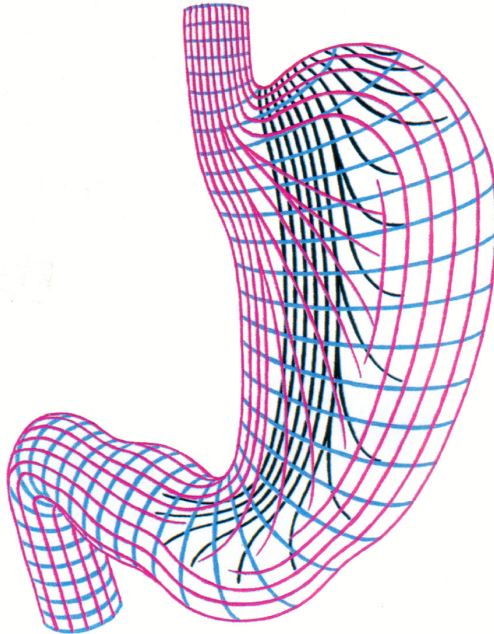
- 1 – gaster;
- 2 – duodenum;
- 3 – costa XII.



**DISPOZIȚIA STRATURILOR MUSCULARE
ÎN PERETELE STOMACULUI**

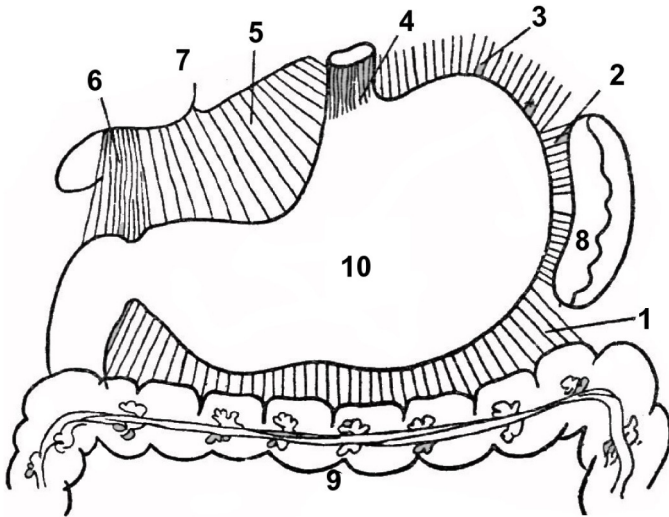
(dipă P. D. Синельников)

**РАСПОЛОЖЕНИЕ МЫШЕЧНЫХ СЛОЁВ СТЕНКИ ЖЕЛУДКА
ARRANGEMENT OF THE MUSCULAR LAYERS
WITHIN THE WALL OF THE STOMACH**



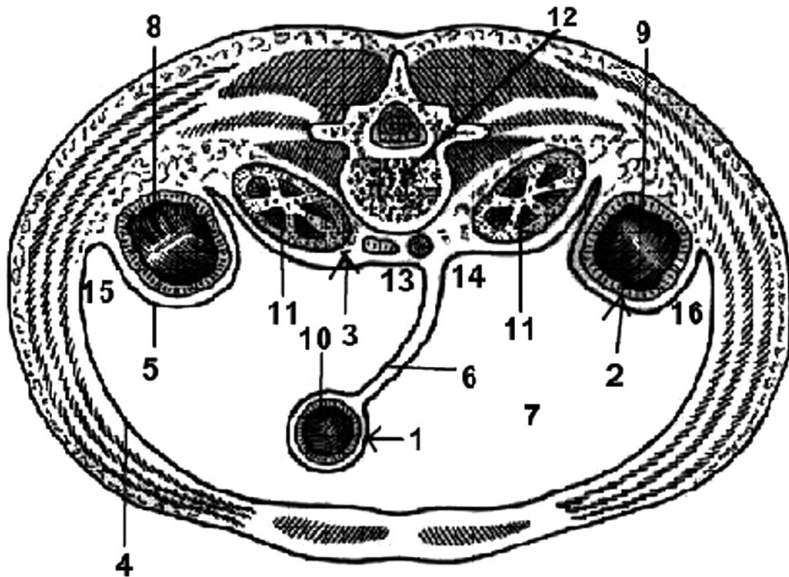
Stratum externum – longitudinale;
stratum medium – circulare;
stratum internum – obliquum.

LIGAMENTELE STOMACULUI
СВЯЗКИ ЖЕЛУДКА
STOMACH LIGAMENTS



- 1 - lig. gastrocolicum;
- 2 - lig. gastrolienale;
- 3 - lig. gastrophrenicum;
- 4 - lig. phrenicoesophageum;
- 5 - lig. hepatogastricum;
- 6 - lig. hepatoduodenale;
- 7 - hepar;
- 8 - lien;
- 9 - colon transversum;
- 10 - gaster.

RAPORTUL ORGANELOR CU PERITONEUL (L_{II-III})
 ВАРИАНТЫ ОТНОШЕНИЯ ОРГАНОВ К БРЮШИНЕ (L_{II-III})
 RELATION OF ORGANS TO THE PERITONEUM (L_{II-III})



1 - *positio intraperitonealis*;
 2 - *positio mesoperitonealis*;
 3 - *positio extraperitonealis*
 (*retroperitonealis*);
 4 - *peritoneum parietale*;
 5 - *peritoneum viscerale*;
 6 - *mesenterium*;
 7 - *cavitas peritonealis*;
 8 - *colon ascendens*;

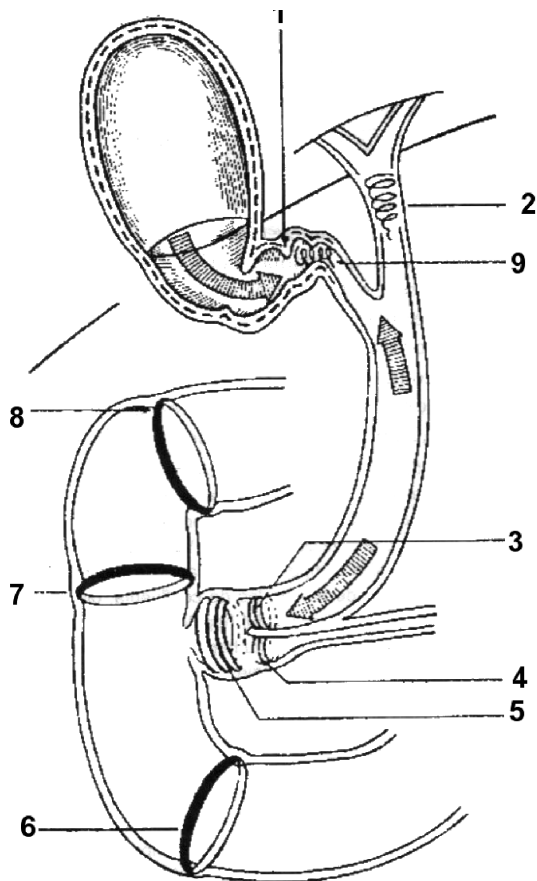
9 - *colon descendens*;
 10 - *intestinum tenue*;
 11 - *ren dexter et sinister*;
 12 - *vertebrae lumbales (L_{II-III})*;
 13 - *sinus mesentericus dexter*;
 14 - *sinus mesentericus sinister*;
 15 - *sulcus paracolicus dexter*;
 16 - *sulcus paracolicus sinister*.

SFINCTERELE BILIDUODENALE

(după V. Papilian, 1998)

ЖЕЛЧНО-ДУОДЕНАЛЬНЫЕ СФИНКТЕРЫ

SPHINCTERS OF THE BILE WAYS AND OF THE DUODENUM



1 – *plica spiralis*;

2 – *m. sphincter ductus biliaris*;

3 – *m. sphincter ductus choledochi*;

4 – *m. sphincter ductus pancreatici*;

5 – *m. sphincter ampullae (Oddi)*;

6 – *m. sphincter duodeni*;

7 – *m. sphincter medioduodeni*;

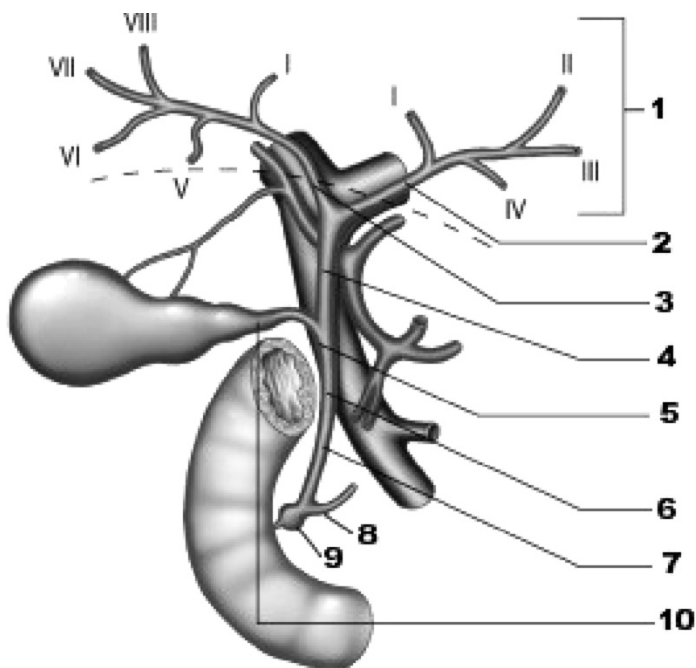
8 – *m. sphincter bulboduodeni*;

9 – *m. sphincter ductus cystici*.

CĂILE BILIARE INTRA- ȘI EXTRAHEPATICE

(după Gray, 2005)

ВНУТРИ-И ВНЕПЕЧЁНОЧНЫЕ ЖЕЛЧЕВЫНОСЯЩИЕ ПУТИ INTRA- AND EXTRAHEPATIC BILE DUCTS



I - VIII - *segmenta hepatis.*

1 - *canales biliaires intrahepatici;*

2 - *ductus hepaticus sinister;*

3 - *ductus hepaticus dexter;*

4 - *ductus hepaticus communis;*

5 - *ductus choledochus (biliaris) -
segmentum supraduodenale;*

6 - *ductus choledochus (biliaris) -
segmentum retroduodenale;*

7 - *ductus choledochus (biliaris) -
segmentum retropancreaticum;*

8 - *ductus pancreaticus principalis;*

9 - *ampulla hepatopancreatica;*

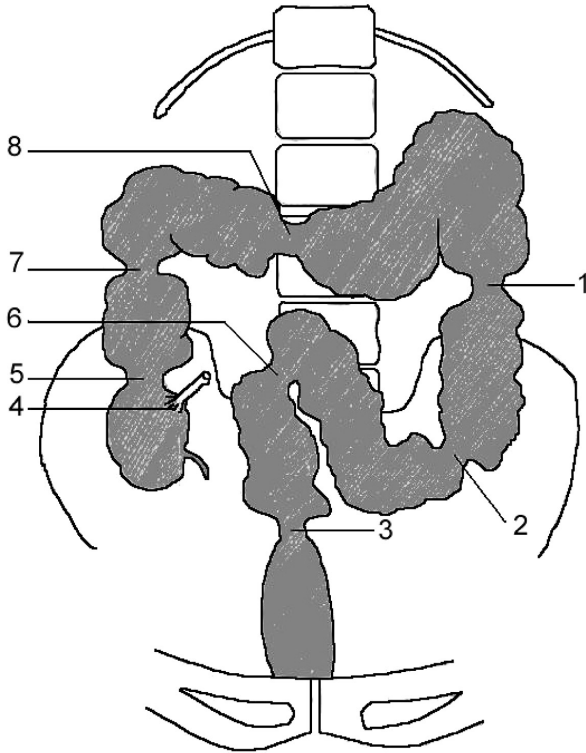
10 - *ductus cysticus.*

SFINCTERELE FUNCȚIONALE ALE INTESTINULUI GROS

(după V. Papilian, 1998)

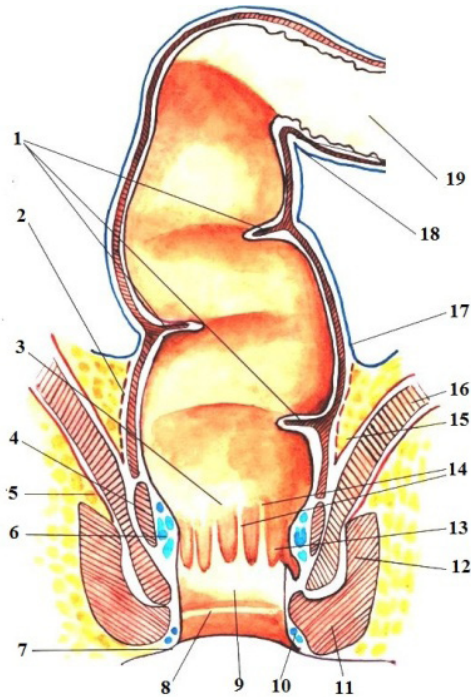
ФУНКЦИОНАЛЬНЫЕ СФИНКТЕРЫ ТОЛСТОЙ КИШКИ

FUNCTIONAL SPHINCTERS OF THE LARGE INTESTINE



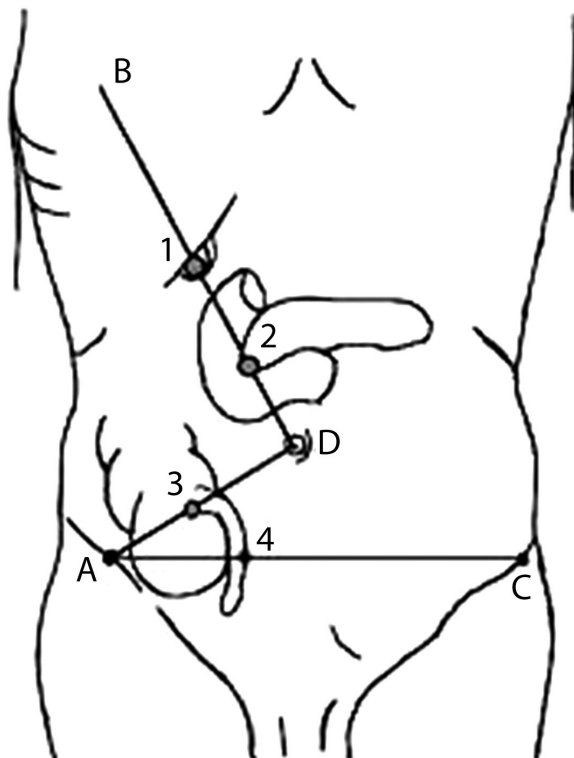
- 1 – *m. sphincter flexurae coli sinistrae (anguli lienalis)* (Payer);
- 2 – *m. sphincter coli sigmoidei* (Balli);
- 3 – *m. sphincter sigmoidorectalis* (Moutier);
- 4 – *m. sphincter (valva) ileocaecalis* (Keith, Varolio);
- 5 – *m. sphincter caecocolicus* (Busi);
- 6 – *m. sphincter accessorius* (Moutier-Rossi);
- 7 – *m. sphincter flexurae coli dextrae (anguli hepatici)* (Hirsch);
- 8 – *m. sphincter coli transversi* (Cannon-Böhm).

CANALUL ANAL
 (dipă A. B. Николаев, 2009)
АНАЛЬНЫЙ КАНАЛ
THE ANAL CANAL



- | | |
|--|---|
| <p>1 – <i>plicae transversae recti</i>;
 2 – <i>fascia visceralis</i>;
 3 – <i>linea pectinata</i>;
 4 – <i>m. sphincter ani internus</i>;
 5 – <i>fascia diaphragmatis pelvis inferior</i>
 6 – <i>plexus venosus rectalis internus</i>;
 7 – <i>zona cutanea ani</i>;
 8 – <i>linea anocutanea</i>;
 9 – <i>pecten analis</i>;
 10 – <i>plexus venosus rectalis externus</i>;
 11 – <i>m. sphincter ani externus, pars subcutanea</i>;</p> | <p>12 – <i>m. sphincter ani externus, pars profunda</i>;
 13 – <i>sinus anales</i>;
 14 – <i>columnae anales</i>;
 15 – <i>fascia diaphragmatis pelvis superior</i>;
 16 – <i>m. levator ani</i>;
 17 – <i>peritoneum</i>;
 18 – <i>transitio intestini sigmoidei in intestino recto (isthmus coli sigmoidei)</i>;
 19 – <i>colon sigmoideum</i>.</p> |
|--|---|

PROIECȚIA CUTANATĂ A SENSIBILITĂȚII UNOR
ORGANE ABDOMINALE
КОЖНАЯ ПРОЕКЦИЯ ЧУВСТВИТЕЛЬНОСТИ НЕКОТОРЫХ
ОРГАНОВ БРЮШНОЙ ПОЛОСТИ
PROJECTION OF THE CUTANEOUS SENSIBILITY OF SOME ORGANS
OF THE ABDOMINAL CAVITY



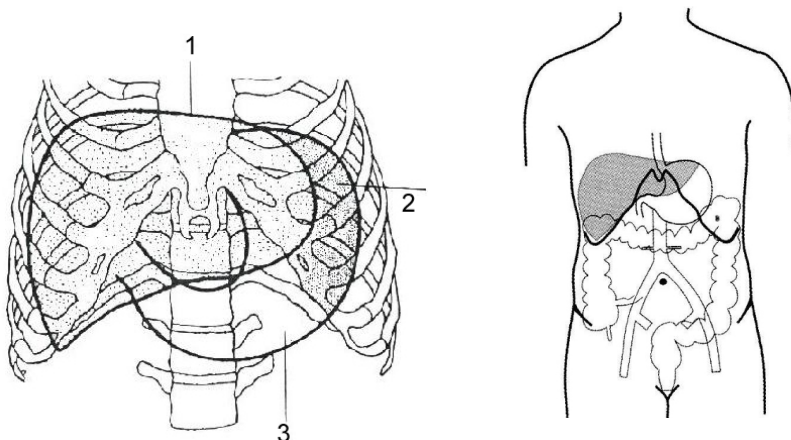
- 1 - *punctum cholecysticum*;
- 2 - *punctum pancreaticum*;
- 3 - *punctum appendiculare* (Mc. Burney);
- 4 - *punctum appendiculare* (Lanz).

AD - *linea umbilicoiliaca*;
BD - *linea umbilicoaxillaris*;
AC - *linea bispinoiliaca*.

**PROIECȚIA STOMACULUI ȘI A FICATULUI PE PERETELE
TORACOABDOMINAL ANTERIOR**

(după V. Papilian, 1998)

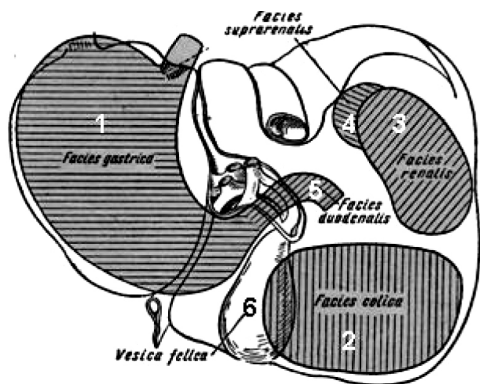
**ПРОЕКЦИЯ ЖЕЛУДКА И ПЕЧЕНИ НА ПЕРЕДНЮЮ СТЕНКУ ТУЛОВИЩА
PROJECTION OF THE STOMACH AND OF THE LIVER
ON THE ANTERIOR WALL OF THE TRUNK**



- 1 – hepar;
2 – gaster (regio hypochondriaca sinistra, spatium semilunare, Traube);
3 – gaster (regio epigastrica, trigonum Labbe).

SINTOPIA FEȚEI VISCERALE A FICATULUI

**СИНТОПИЯ ВИСЦЕРАЛЬНОЙ ПОВЕРХНОСТИ ПЕЧЕНИ
CONTACT AREAS OF THE LIVER WITH THE NEIGHBOURING ORGANS**



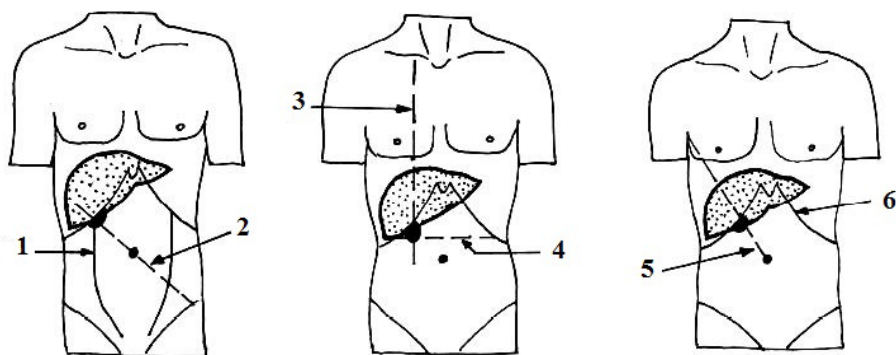
- 1 – impressio gastrica;
2 – impressio colica;
3 – impressio renalis;
4 – impressio suprarenalis;
5 – impressio duodenalis;
6 – vesica fellea.

VARIANTE DE PROIEȚIE A VEZICULEI BILIARE PE PERETELE ABDOMINAL ANTERIOR

(după V.I. Лабзин, А.А. Родионов, 2005)

ВАРИАНТЫ ОПРЕДЕЛЕНИЯ ПРОЕКЦИИ ЖЕЛЧНОГО ПУЗЫРЯ НА ПЕРЕДНЮЮ БРЮШНУЮ СТЕНКУ

VARIANTS OF PROJECTION OF THE GALLBLADDER ON THE ANTERIOR ABDOMINAL WALL



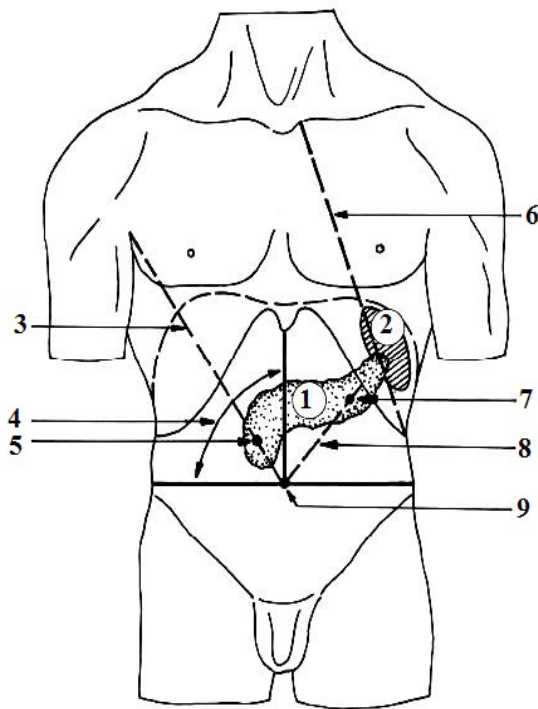
- 1 – *linea pararectomuscularis*;
- 2 – *linea spinoumbilicalis sinistra*;
- 3 – *linea parasternalis*;
- 4 – *linea subcostalis*;
- 5 – *linea Desjardins*;
- 6 – *arcus costalis*;

**PROIECȚIA PANCREASULUI ȘI SPLINEI PE PERETELE
ABDOMINAL ANTERIOR**

(după V.I. Лабзин, А.А. Родионов, 2005)

**ПРОЕКЦИЯ ПОДЖЕЛУДОЧНОЙ ЖЕЛЕЗЫ И СЕЛЕЗЕНКИ НА
ПЕРЕДНЮЮ СТЕНКУ БРЮШНОЙ ПОЛОСТИ**

**PROJECTION OF THE PANCREAS AND SPLEEN ON THE ANTERIOR
ABDOMINAL WALL**



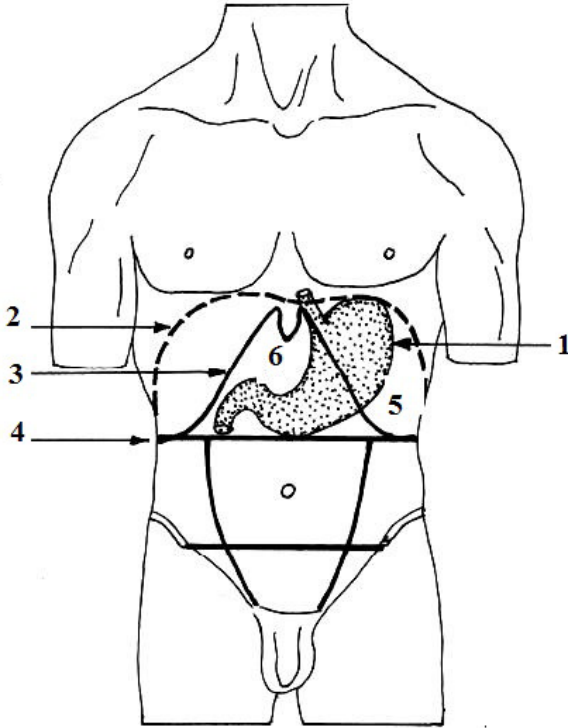
- 1 - pancreas;
- 2 - lien (splen);
- 3 - linea Desjardins;
- 4 - triangulus Chauffarti;
- 5 - punctum Desjardins;
- 6 - linea costoarticularis;
- 7 - punctum Majo- Robsoni;
- 8 - linea bipartiens quadrantem superiorem sinistrum abdominis;
- 9 - umbilicus.

PROIEȚIA STOMACULUI PE PERETELE ABDOMINAL ANTERIOR

(dipă В.И. Лабзин, А.А. Родионов, 2005)

ПРОЕКЦИЯ ЖЕЛУДКА НА ПЕРЕДНЮЮ СТЕНКУ БРЮШНОЙ ПОЛОСТИ

PROJECTION OF THE STOMACH ON THE ANTERIOR ABDOMINAL WALL



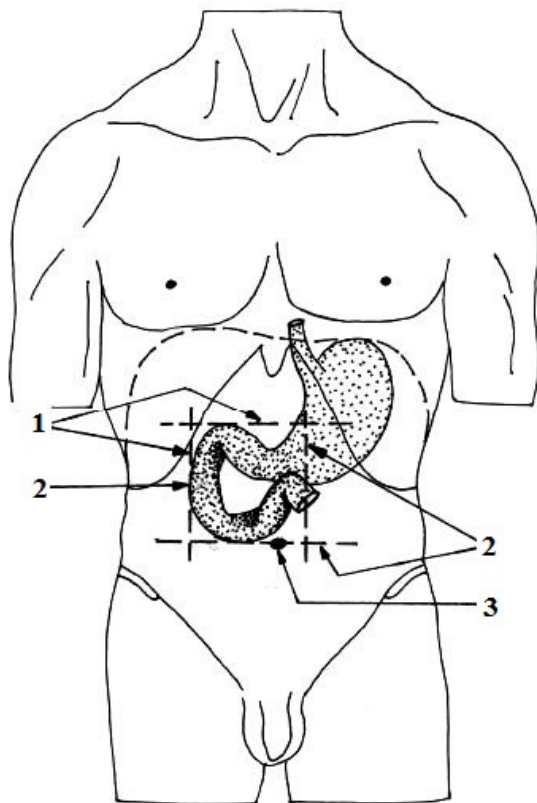
- 1 – gaster;
- 2 – *circumscriptiones diaphragmatis*;
- 3 – *circumscriptiones arcus costalis*;
- 4 – *linea subcostalis*;
- 5 – *regio hypochondriaca sinistra*;
- 6 – *regio epigastrica*.

PROIEȚIA DUODENULUI PE PERETELE ABDOMINAL ANTERIOR

(după В. И. Лабзин, А.А. Родионов, 2005)

ПРОЕКЦИЯ ДВЕНАДЦАТИПЕРСТНОЙ КИШКИ НА ПЕРЕДНЮЮ СТЕНКУ БРЮШНОЙ ПОЛОСТИ

PROJECTION OF THE DUODENUM ON THE ANTERIOR ABDOMINAL WALL

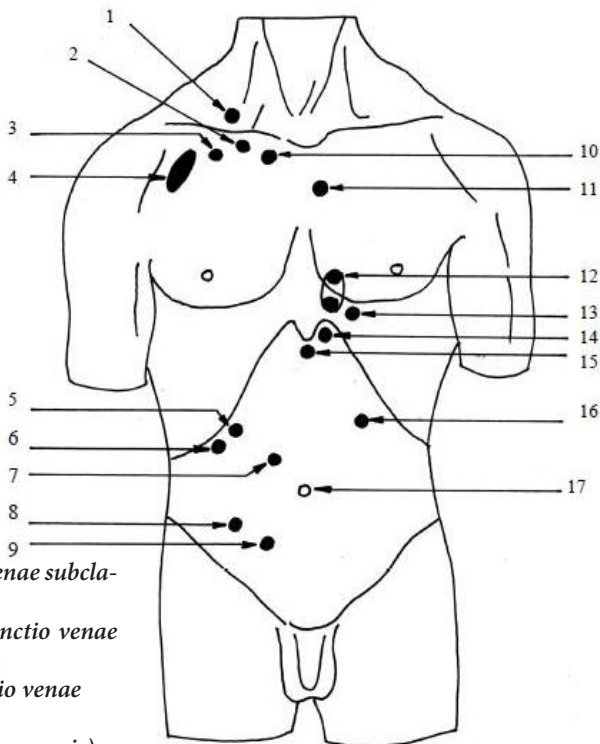


1 - duodenum;

2 - *circumscriptio zonae projectiae duodeni*;

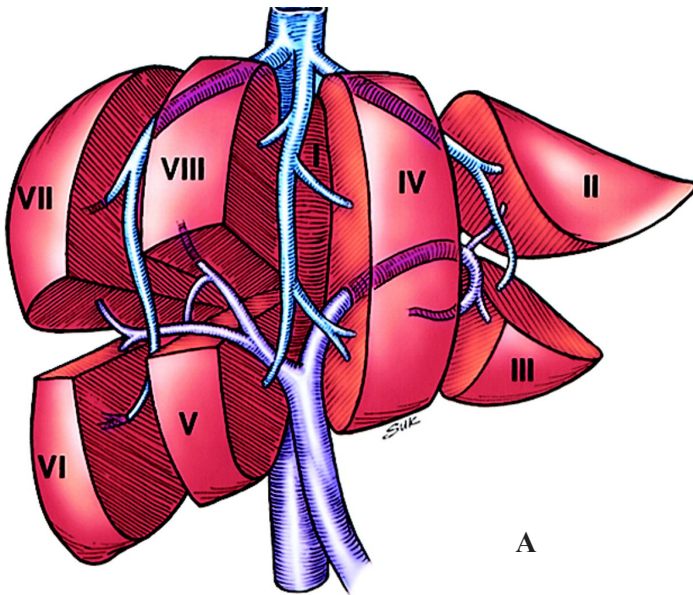
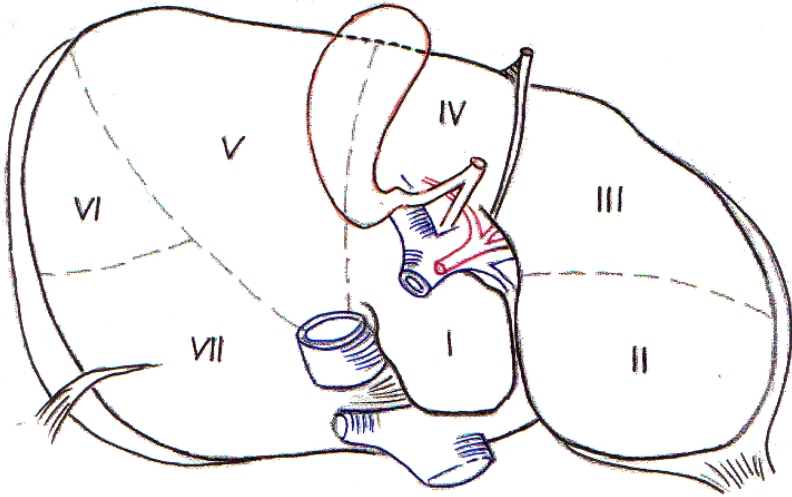
3 - umbilicus.

LOCALIZAREA PUNCTELOR SUPLIMENTARE DE REFERINȚĂ
СХЕМА ЛОКАЛИЗАЦИИ ДОПОЛНИТЕЛЬНЫХ
ОПОЗНАВАТЕЛЬНЫХ ТОЧЕК
LOCATION OF THE ADDITIONAL REFERENCE POINTS

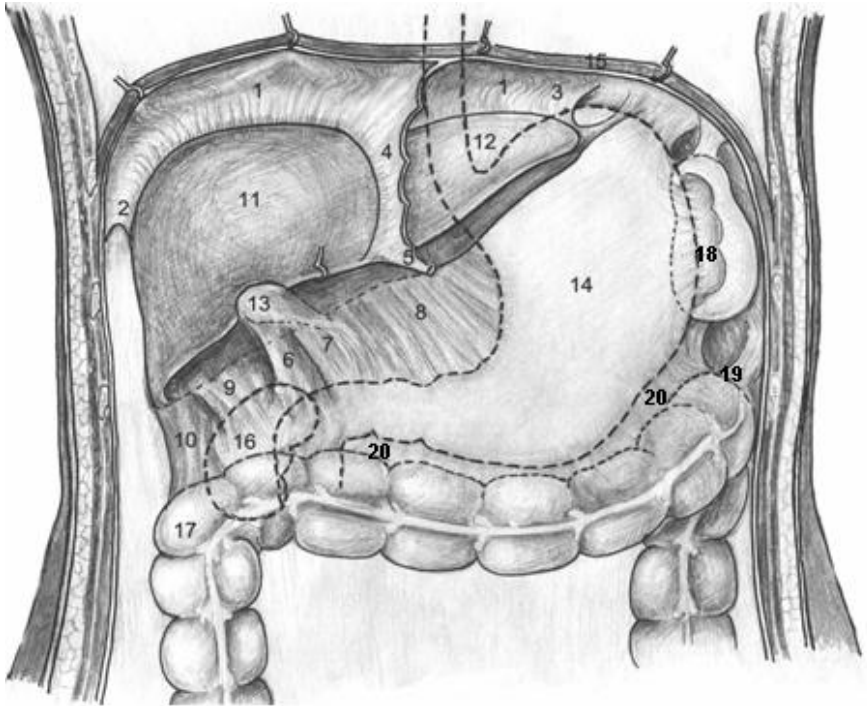


- 1 – punctum Ioffi (punctio venae subclavicularis);
- 2 – punctum Aubaniaci (punctio venae subclavicularis);
- 3 – punctum Wilsoni (punctio venae subclavicularis);
- 4 – fovea Mohrenheimi (tremor vocis);
- 5 – punctum renale anterius;
- 6 – punctum Kehri (fundus vesicae felleae);
- 7 – punctum Desjardins (caput pancreatis);
- 8 – punctum Mc Burney (basis appendicis vermiformis);
- 9 – punctum Lanz (basis appendicis vermiformis);
- 10 – punctum Giles (punctio venae subclavicularis);
- 11 – punctum Боткин- Erbi (auscultatio valvae aortae – punctum supplens);
- 12 – punctum Пурозов- Delormi (punctio pericardii);
- 13 – punctum Curschmanni (punctio pericardii);
- 14 – punctum Larrey (punctio pericardii);
- 15 – punctum Marfani (punctio pericardii);
- 16 – punctum Mayo-Robsoni (cauda pancreatis);
- 17 – umbilicus.

SEGMENTAREA FICATULUI
(A – după C. Couinaud)
СЕМЕНТЫ ПЕЧЕНИ
SEGMENTS OF THE LIVER



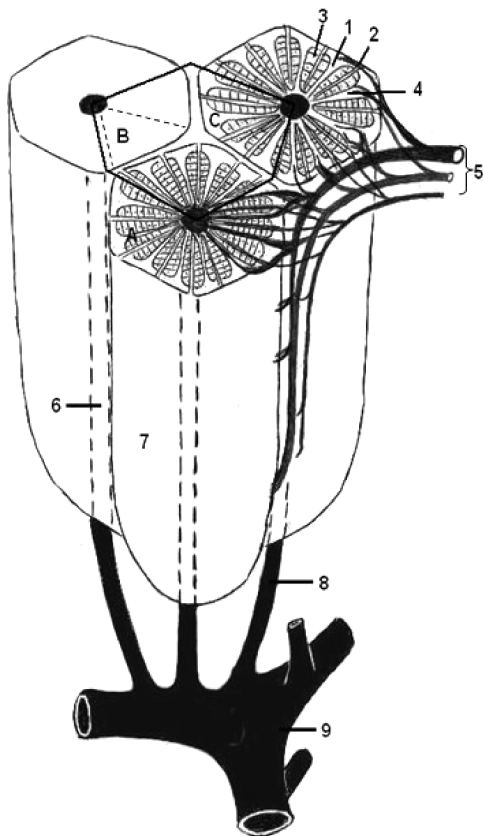
LIGAMENTELE PERITONEALE ALE ETAJULUI SUPRAMEZOCOLIC
СВЯЗКИ ОРГАНОВ ВЕРХНЕГО ЭТАЖА БРЮШНОЙ ПОЛОСТИ
PERITONEAL LIGAMENTS OF THE SUPRAMESOCOLIC STOREY



1 - lig. coronarium;
 2 - lig. triangulare dextrum;
 3 - lig. triangulare sinistrum;
 4 - lig. falciforme hepatis;
 5 - lig. teres hepatis;
 6 - lig. hepatocystoduodenocolicum;
 7 - lig. hepatoduodenale;
 8 - lig. hepatogastricum;
 9 - lig. hepatorenale;
 10 - lig. hepatocolicum;

11-12 - lobi hepatis (dexter et sinister);
 13 - vesica fellea (biliaris);
 14 - gaster;
 15 - diaphragma;
 16 - ren dexter;
 17 - colon;
 18 - lig. gastrolienale (gastrosplenicum);
 19 - lig. phrenicocolicum;
 20 - lig. gastrocolicum.

LOBULUL HEPATIC
(schema modificată după M. Ifrim, 1985)
ПЕЧЕНОЧНАЯ ДОЛЬКА
THE HEPATIC LOBULE



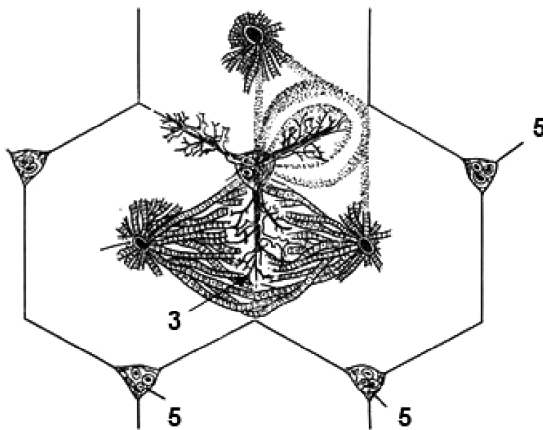
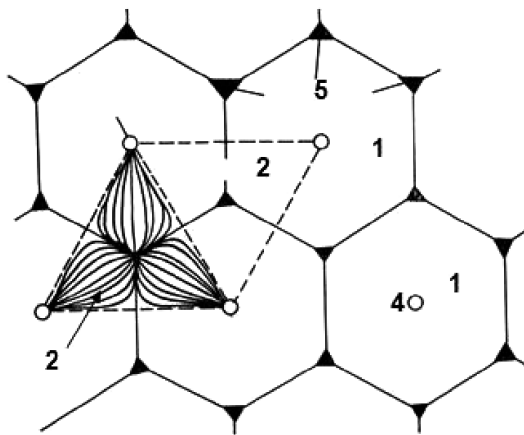
- 1 - canaliculi biliferi;
- 2 - ductuli biliferi;
- 3 - laminae (trabeculae) hepaticae;
- 4 - vasa sinusoidea;
- 5 - trias hepatica [arteria, venula, ductulus interlobularis (Glisson)];
- 6 - v. centralis;
- 7 - lobulus hepaticus;

- 8 - v. sublobularis;
- 9 - v. hepatica.
- A - lobulus hepaticus;
- B - acinus hepaticus;
- C - lobulus portalis.

STRUCTURA LOBULARĂ ȘI ACINARĂ A FICATULUI

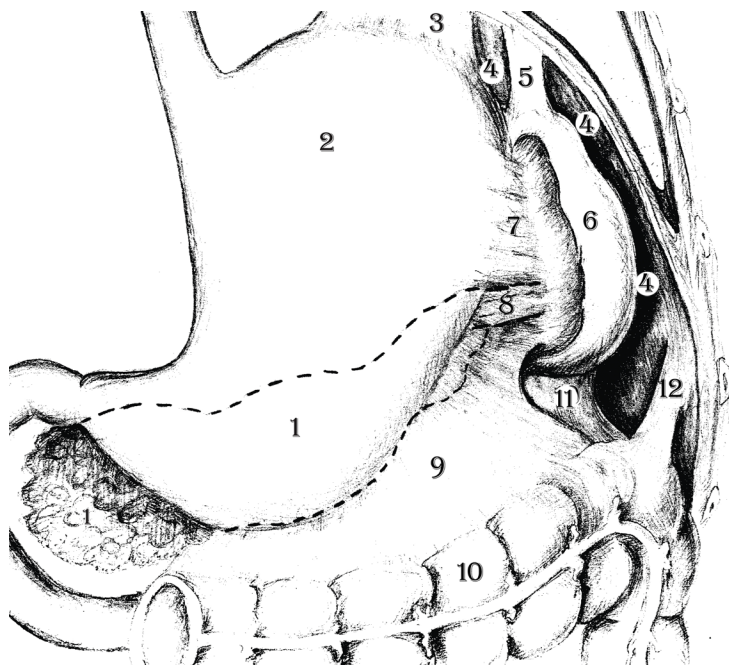
(după Ham A., Korckmark D., 1983)

ДОЛЬКОВОЕ И АЦИНАРНОЕ СТРОЕНИЕ ПЕЧЕНИ LOBULAR AND ACINOUS STRUCTURE OF THE LIVER



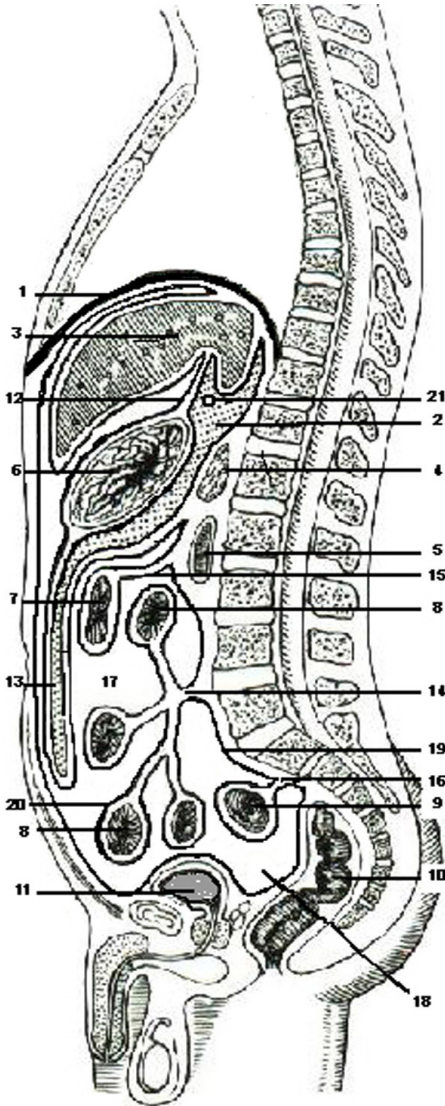
- 1 - lobulus hepaticus classicus;
- 2 - lobulus portalis;
- 3 - acinus hepaticus;
- 4 - venae centrales;
- 5 - spatium Dissé.

LIGAMENTELE SPLINEI
(după O.Belic)
СВЯЗКИ СЕЛЕЗЁНКИ
LIGAMENTS OF THE SPLEEN



- 1 - pancreas;
- 2 - gaster;
- 3 - lig. gastrophrenicum;
- 4 - diaphragma;
- 5 - lig. phrenicolienale;
- 6 - lien;
- 7 - lig. gastrolienale;
- 8 - lig. pancreaticolienale;
- 9 - lig. gastrocolicum;
- 10 - colon transversum;
- 11 - lig. colicolienale;
- 12 - lig. phrenicocolicum.

RAPORTURILE PERITONEULUI LA BĂRBAT (secțiune sagitală)
 ТОПОГРАФИЯ БРЮШИНЫ У МУЖЧИНЫ
 (срединно-сагитальный разрез)
 RELATIONS OF ORGANS TO THE PERITONEUM IN MALE
 (sagital section)



- 1 - diaphragma;
- 2 - bursa omentalis;
- 3 - hepar;
- 4 - pancreas;
- 5 - duodenum;
- 6 - gaster;
- 7 - colon transversum;
- 8 - jejunum/ileum;
- 9 - colon sigmoideum;
- 10 - rectum;
- 11 - vesica urinaria;
- 12 - omentum minus
(lig. hepatogastricum
et lig. hepatoduodenale);
- 13 - omentum majus;
- 14 - radix mesenterii;
- 15 - mesocolon transversum;
- 16 - mesosigmoideum;
- 17 - cavitas peritonealis;
- 18 - excavatio rectovesicalis;
- 19 - peritoneum parietale;
- 20 - peritoneum viscerale;
- 21 - foramen epiploicum (Winslow).

REGIUNEA PERINEALĂ

I – etajul peritoneal; II – etajul subperitoneal; III – etajul perineal

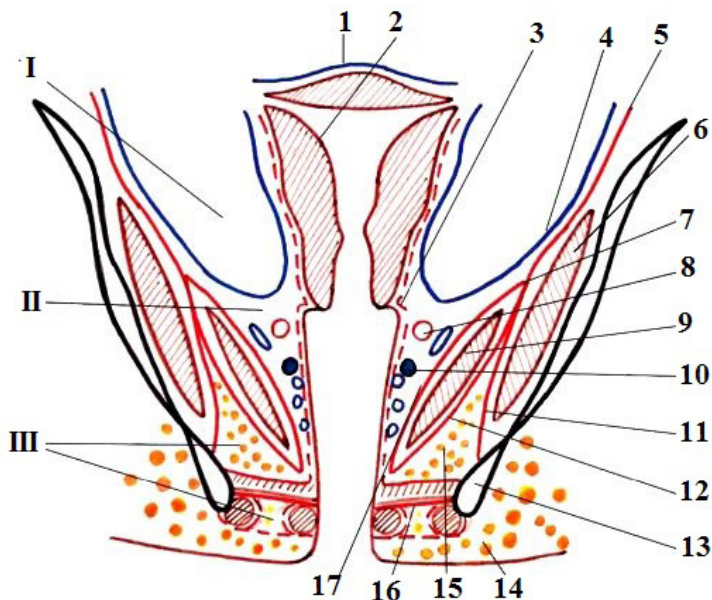
(după A. B. Николаев, 2009)

ОБЛАСТЬ ПРОМЕЖНОСТИ

I – брюшинный этаж; II – подбрюшинный этаж; III – промежностный этаж

THE PERINEAL REGION

I – the peritoneal storey; II – the subperitoneal storey; III – the perineal storey



1 – *peritoneum viscerale*;

2 – *uterus*;

3 – *fascia visceralis*;

4 – *peritoneum parietale*;

5 – *fascia parietalis*;

6 – *m. obturatorius internus*;

7 – *arcus tendineus m. levatoris ani*;

8 – *a. iliaca interna*;

9 – *m. levator ani*;

10 – *ureter*;

11 – *fascia obturatoria*;

12 – *fascia diaphragmatis pelvis inferior*;

13 – *tuber ischiadicum*;

14 – *tela subcutanea*;

15 – *fossa ischioanalis*;

16 – *membrana perinei*;

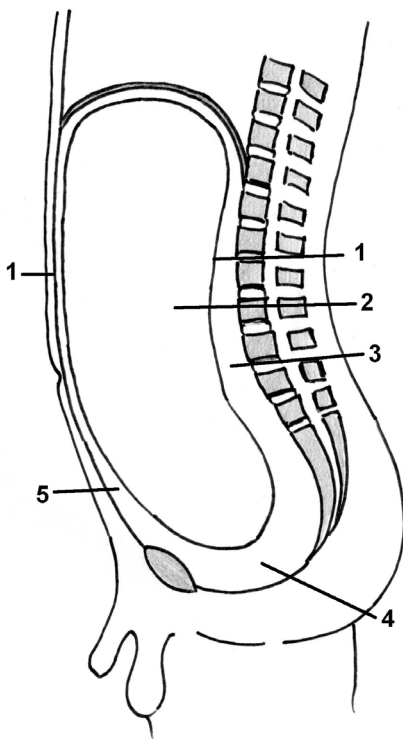
17 – *fascia diaphragmatis pelvis superior*.

CAVITATEA PERITONEALĂ ȘI SPAȚIILE EXTRAPERITONEALE
(secțiune schematică medio-sagitală prin abdomen)

(după V. Papilian, 1998)

ПОЛОСТЬ БРЮШИНЫ И ЭКСТРАПЕРИТОНЕАЛЬНЫЕ
ПРОСТРАНСТВА (срединно – сагитальный разрез)

PERITONEAL CAVITY AND THE EXTRAPERITONEAL SPACES
(mediosagittal section through the abdomen)



1 – *peritoneum parietale*;

2 – *cavitas peritonealis*;

3 – *spatium retroperitoneale*;

4 – *spatium subperitoneale (pelvisubperitoneale)*;

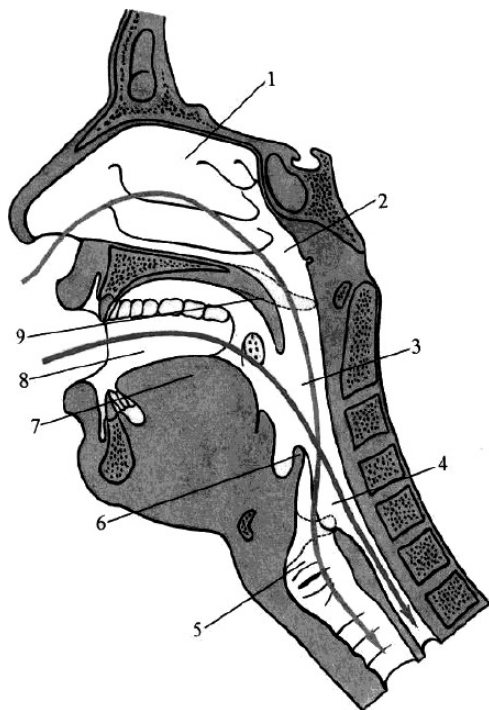
5 – *spatium preperitoneale*.

INTERSECTAREA CĂILOR RESPIRATORII ȘI DIGESTIVE ÎN FARINGE

(după P.Д. Синельников, Я.Р. Синельников, 1990)

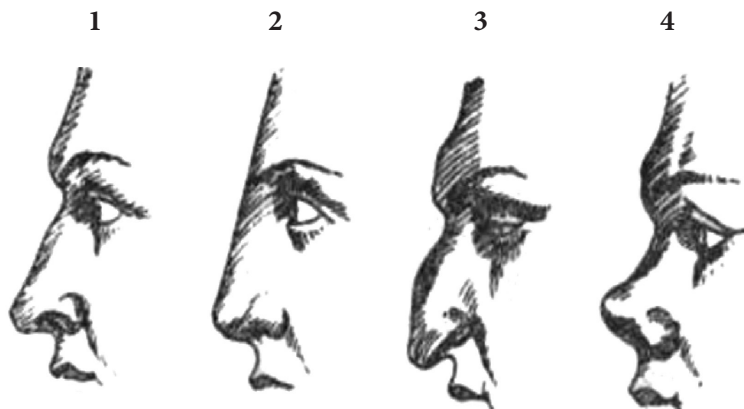
ПЕРЕСЕЧЕНИЕ В ОБЛАСТИ ГЛОТКИ ДЫХАТЕЛЬНОГО И ПИЩЕВАРИТЕЛЬНОГО ПУТЕЙ

INTERSECTION OF THE RESPIRATORY WAYS AND ALIMENTARY TRACT WITHIN THE PHARYNX



- 1 – *cavitas nasi*;
- 2 – *pars nasalis pharyngis*;
- 3 – *pars oralis pharyngis*;
- 4 – *pars laryngea pharyngis*;
- 5 – *cavitas laryngis*;
- 6 – *epiglottis*;
- 7 – *lingua*;
- 8 – *cavitas oris*;
- 9 – *palatum molle*.

PRINCIPALELE TIPURI DE NAS
(după N. Diaconescu, 1979)
ФОРМЫ НАРУЖНОГО НОСА
THE MAIN TYPES OF THE EXTERNAL NOSE

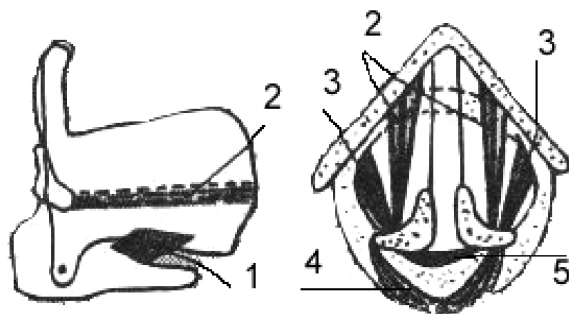


- 1 – *nasus rectus* (Augustus);
2 – *nasus graecus* (Venus de Millo);
3 – *nasus aquilinus* (Dante);
4 – *nasus selliformis* (Socrate).

FORMAȚIUNILE DE FIXARE, ÎNCORDARE
ȘI RELAXARE A COARDELOR VOCALE

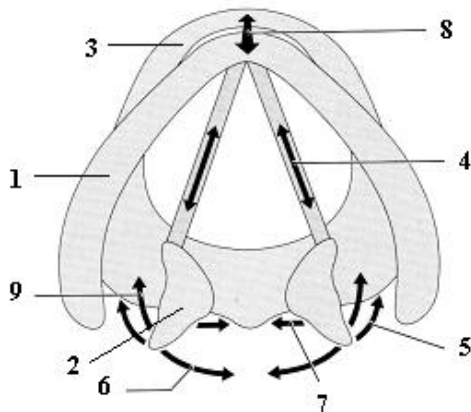
(după Л.В. Путьшев, 1999)

СТРУКТУРЫ ФИКСИРУЮЩИЕ, НАПРЯГАЮЩИЕ И
РАССЛАБЛЯЮЩИЕ ГОЛОСОВЫЕ СВЯЗКИ
ANATOMICAL FORMATIONS FOR THE FIXATION,
STRAINING AND RELAXATION OF THE VOCAL FOLDS



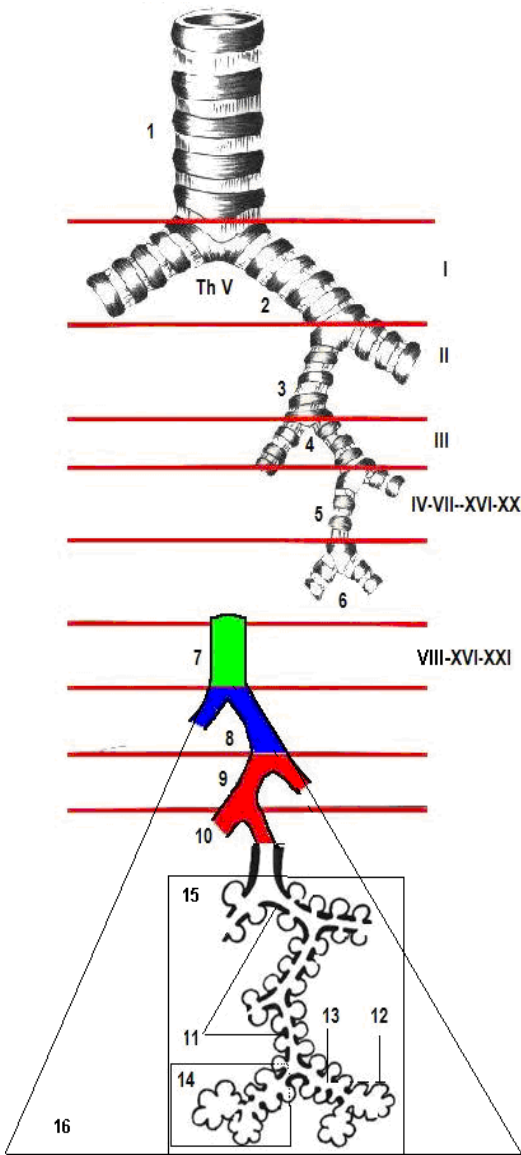
- 1 – *m. cricothyroideus*;
- 2 – *m. thyroarytenoideus*;
- 3 – *m. cricoarytenoideus lateralis*;
- 4 – *m. cricoarytenoideus posterior*;
- 5 – *m. arytenoideus transversus*.

LARINGELE ÎN FONAȚIE
(după M. Schuenke)
ГОРТАНЬ В АКТЕ ЗВУКООБРАЗОВАНИЯ
THE LARYNX IN PHONATION



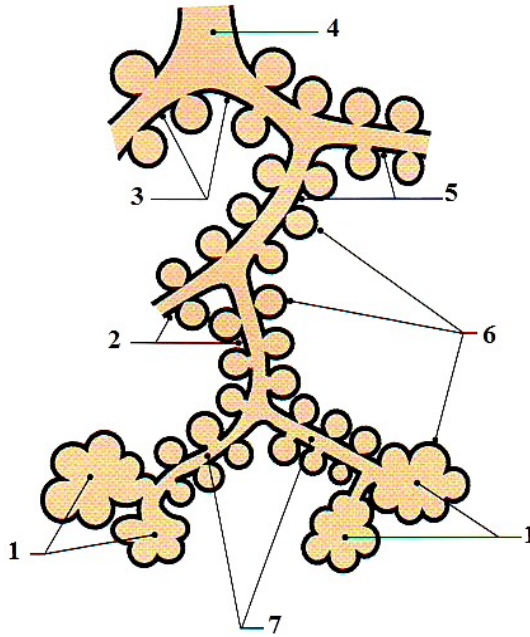
- 1 – *cartilago thyroidea*;
- 2 – *cartilago arytenoidea*;
- 3 – *cartilago cricoidea*;
- 4 – *m. vocalis*;
- 5 – *m. cricoarytenoideus lateralis*;
- 6 – *m. cricoarytenoideus posterior*;
- 7 – *m. arytenoideus transversus*.
- 8 – *m. cricothyroideus*;
- 9 – *m. thyroarytenoideus*.

ARBORELE BRONCHIC
БРОНХИАЛЬНОЕ ДЕРЕВО
BRONCHIAL TREE



- 1 – trachea;
- 2 – bronchi principales dexter et sinister (primarii) (I);
- 3 – bronchi lobares (secundarii) (II);
- 4 – bronchi segmentales (tertii) (III);
- 5, 6 – bronchi subsegmentales et interlobulares (IV-VII – XIV-XXI);
- 7 – bronchi intralobulares (lobulus pulmonis secundarius) (VIII – XV- XXI);
- 8 – bronchioli terminales;
- 9 – bronchioli I;
- 10 – bronchioli II;
- 11 – bronchioli respiratorii (I-IV);
- 12 – sacculus alveolaris et alveoli pulmonis;
- 13 – ductuli alveolares;
- 14 – lobulus pulmonis primarius;
- 15 – acinus pulmonalis;
- 16 – lobulus pulmonis secundarius.

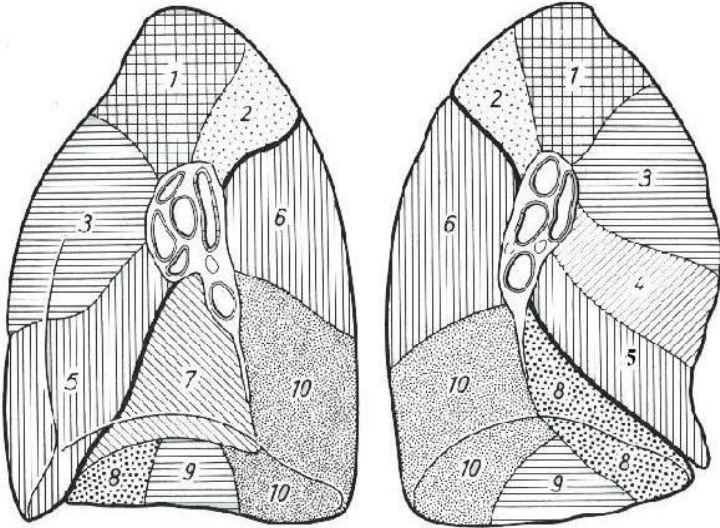
ACINUL
АЦИНУС
ACINUS



- 1 – *sacculi alveolares*;
2, 3, 5, 7 – *bronchioli respiratorii (I-IV)*;
4 – *bronchiolus terminalis*;
6 – *alveoli pulmonis*;

SEGMENTELE PLĂMÂNILOR
БРОНХОЛЕГОЧНЫЕ СЕГМЕНТЫ
SEGMENTS OF THE LUNGS

Fața mediastinală
Медиальная (медиастинальная) поверхность
Medial (mediastinal) surface



Pulmo dexter

Lobus superior

- 1 – segmentum apicale (S_I);
- 2 – segmentum posterius (S_{II});
- 3 – segmentum anterius (S_{III});

Lobus medius

- 4 – segmentum laterale (S_{IV});
- 5 – segmentum mediale (S_V);

Lobus inferior

- 6 – segmentum superius (S_{VI});
- 7 – segmentum basale mediale (cardiacum) (S_{VII});
- 8 – segmentum basale anterius (S_{VIII});
- 9 – segmentum basale laterale (S_{IX});
- 10 – segmentum basale posterius (S_{X}).

Pulmo sinister

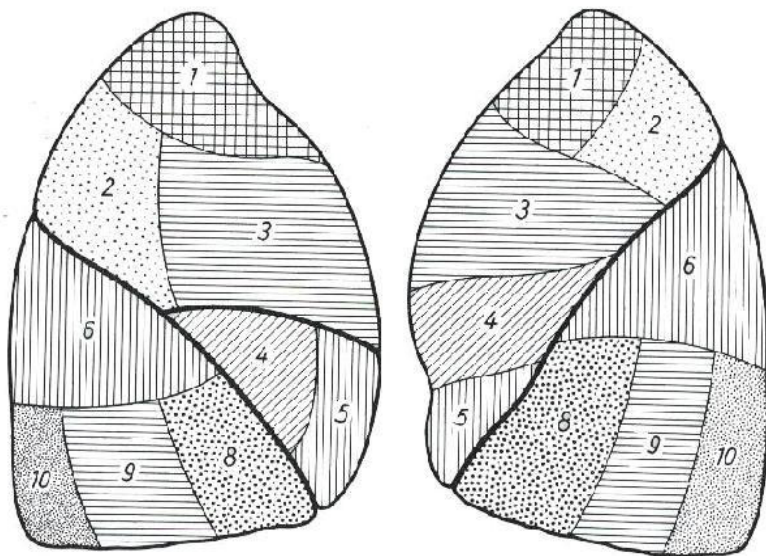
Lobus superior

- 1, 2 – segmentum apicoposterius (S_{I-II});
- 3 – segmentum anterius (S_{III});
- 4 – segmentum lingulare superius (S_{IV});
- 5 – segmentum lingulare inferius (S_V);

Lobus inferior

- 6 – segmentum superius (S_{VI});
- 7 – segmentum basale mediale (cardiacum) (S_{VII});
- 8 – segmentum basale anterius (S_{VIII});
- 9 – segmentum basale laterale (S_{IX});
- 10 – segmentum basale posterius (S_{X}).

Fața costală
Реберная поверхность
Costal surface



Pulmo dexter

Lobus superior

- 1 – *segmentum apicale* (S_I);
- 2 – *segmentum posterius* (S_{II});
- 3 – *segmentum anterius* (S_{III});

Lobus medius

- 4 – *segmentum laterale* (S_{IV});
- 5 – *segmentum mediale* (S_V);

Lobus inferior

- 6 – *segmentum superius* (S_{VI});
- 7 – *segmentum basale mediale*
(*cardiacum*) (S_{VII});
- 8 – *segmentum basale anterius* (S_{VIII});
- 9 – *segmentum basale laterale* (S_{IX});
- 10 – *segmentum basale posterius* (S_X).

Pulmo sinister

Lobus superior

- 1, 2 – *segmentum apicoposterius* (S_{I-II});
- 3 – *segmentum anterius* (S_{III});
- 4 – *segmentum lingulare superius* (S_{IV});
- 5 – *segmentum lingulare inferius* (S_V);

Lobus inferior

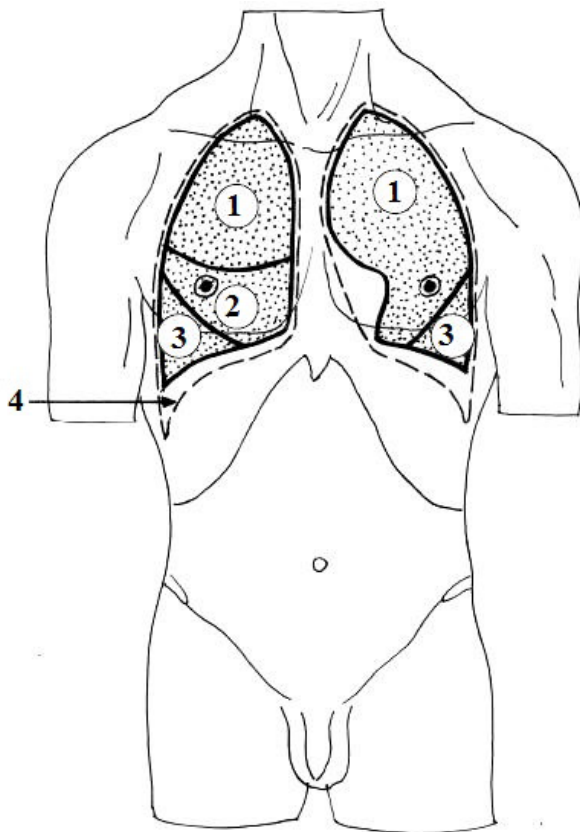
- 6 – *segmentum superius* (S_{VI});
- 7 – *segmentum basale mediale*
(*cardiacum*) (S_{VII});
- 8 – *segmentum basale anterius* (S_{VIII});
- 9 – *segmentum basale laterale* (S_{IX});
- 10 – *segmentum basale posterius* (S_X).

**PROIEȚIA PLĂMÂNILOR (-) ȘI PLEUREI (- - -) PE FAȚA
ANTERIOARĂ A TORACELUI**

(după В.И. Лабзин, А.А. Родионов, 2005)

**ПРОЕКЦИЯ ЛЕГКИХ (-) И ПЛЕВРЫ (- - -) НА ПЕРЕДНЮЮ
ПОВЕРХНОСТЬ ГРУДНОЙ КЛЕТКИ**

**PROJECTION OF THE LUNGS (-) AND PLEURA (-) ON THE ANTERIOR
SURFACE OF THE THORAX**



1 – lobus superior;

2 – lobus medius;

3 – lobus inferior;

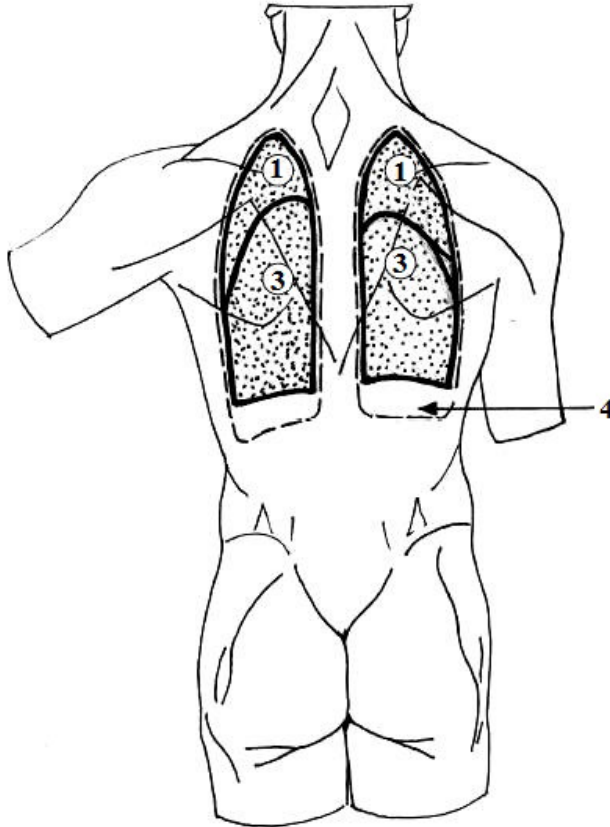
4 – sinus costodiaphragmaticus.

**PROIEȚIA PLĂMÂNILOR (-) ȘI PLEUREI (- - -) PE FAȚA
POSTERIOARĂ A TORACELUI**

(după В.И. Лабзин, А.А. Родионов, 2005)

**ПРОЕКЦИЯ ЛЕГКИХ (-) И ПЛЕВРЫ (- - -) НА ЗАДНЮЮ
ПОВЕРХНОСТЬ ГРУДНОЙ КЛЕТКИ**

**PROJECTION OF THE LUNGS (-) AND PLEURA (- - -) ON THE POSTERIOR
SURFACE OF THE THORAX**



1 – lobus superior;

3 – lobus inferior;

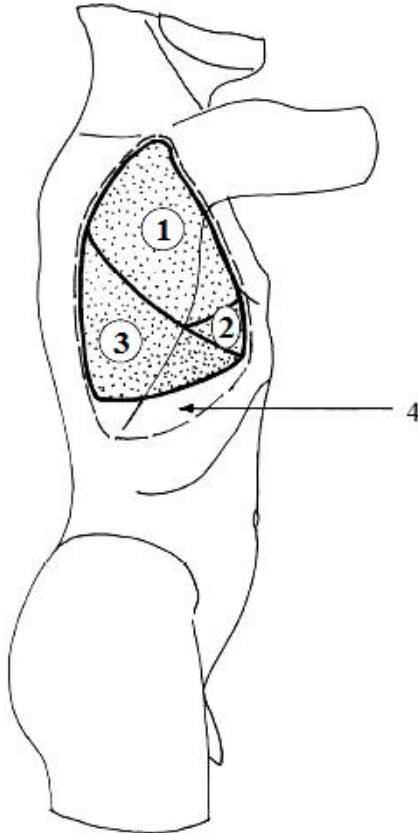
4 – sinus costodiaphragmaticus.

**PROIEȚIA PLĂMÂNILOR (-) ȘI PLEUREI (- - -) PE FAȚA LATERALĂ
A TORACELUI (aspect din dreapta)**

(dipă В.И. Лабзин, А.А. Родионов, 2005)

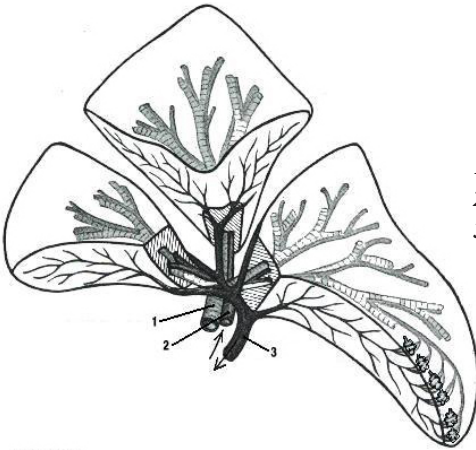
**ПРОЕКЦИЯ ЛЕГКИХ (-) И ПЛЕВРЫ (- - -) НА БОКОВУЮ
ПОВЕРХНОСТЬ ГРУДНОЙ КЛЕТКИ (вид справа)**

**PROJECTION OF THE LUNGS (-) AND PLEURA (-) ON THE LATERAL
SURFACE OF THE THORAX (right aspect)**



- 1 – lobus superior;
- 2 – lobus medius;
- 3 – lobus inferior;
- 4 – sinus costodiaphragmaticus.

SEGMENTUL BRONHOPULMONAR
 БРОНХОЛЕГОЧНОЙ СЕГМЕНТ
 THE BRONCHOPULMONARY SEGMENT



- 1 – bronchus segmentalis (tertius) (III);
 2 – a. pulmonalis (segmentalis);
 3 – v. pulmonalis.

COMPLEXUL STRUCTURAL ALVEOLOCAPILAR

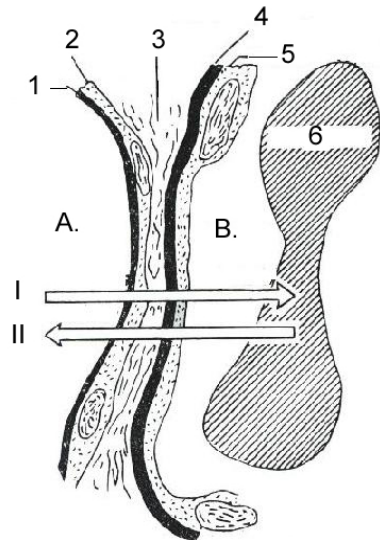
(după I. Haulică, 1998)

АЛЬВЕОЛО-КАПИЛЯРНЫЙ СТРУКТУРНЫЙ КОМПЛЕКС
 THE ALVEOLO-CAPILLARY STRUCTURAL COMPLEX

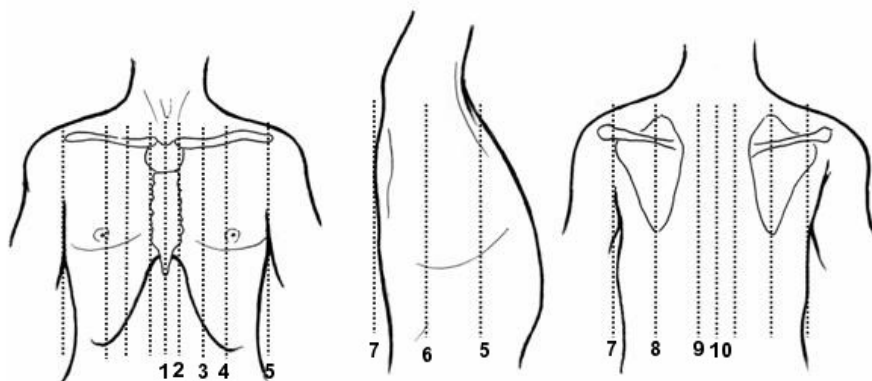
- A. alveolus;
 B. vas capillare.

- I. diffusio O₂;
 II. diffusio CO₂.

- 1 – membranula surfactans;
 2 – epithelium alveolare;
 3 – substantia fundamentalis
 (spatium interstitiale);
 4 – lamina basalis;
 5 – endotheliocytes capillares;
 6 – erythrocytus.

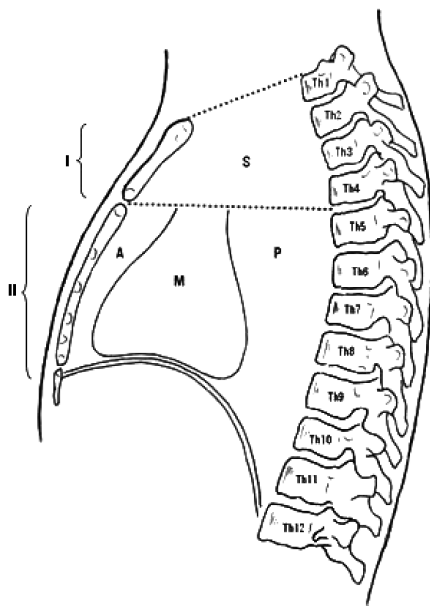


LINIILE TOPOGRAFICE TRASATE PE TORACE
ТОПОГРАФИЧЕСКИЕ ЛИНИИ
НА ПОВЕРХНОСТИ ГРУДНОЙ КЛЕТКИ
TOPOGRAPHICAL LINES TRACED ON THE THORAX



- 1 – *linea mediana anterior;*
- 2 – *linea sternalis;*
- 3 – *linea parasternalis;*
- 4 – *linea medioclavicularis;*
- 5 – *linea axillaris anterior;*
- 6 – *linea axillaris media;*
- 7 – *linea axillaris posterior;*
- 8 – *linea scapularis;*
- 9 – *linea paravertebralis;*
- 10 – *linea mediana posterior.*

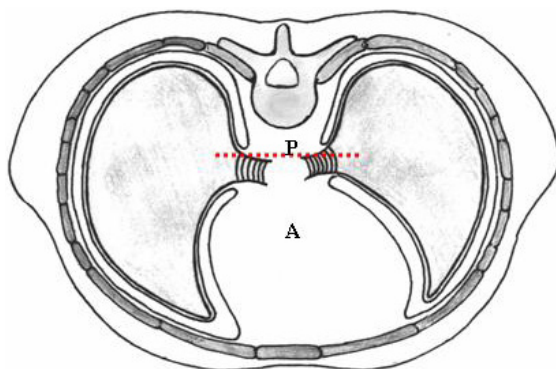
SECȚIUNE MEDIOSAGITALĂ PRIN MEDIASTIN (PNA)
 СРЕДИННЫЙ СРЕЗ ЧЕРЕЗ СРЕДОСТЕНИЕ
 MEDIOSAGITTAL CROSS SECTION THROUGH THE MEDIASTINUM



I – mediastinum superius (S);
II – mediastinum inferius;

A – antierius;
M – medius;
P – posterius.

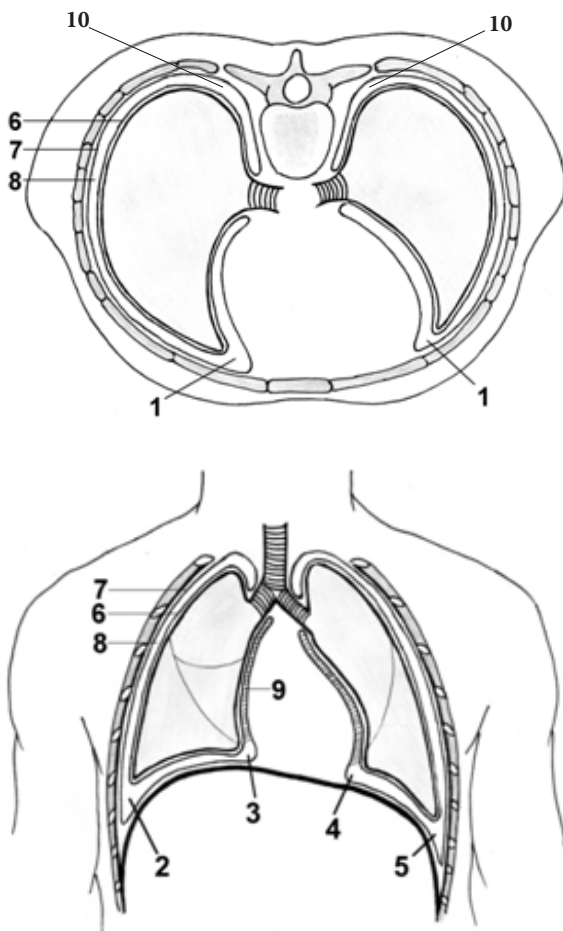
SECȚIUNE ORIZONTALĂ PRIN MEDIASTIN (BNA)
 ПОПЕРЕЧНЫЙ СРЕЗ ЧЕРЕЗ СРЕДОСТЕНИЕ
 HORIZONTAL CROSS SECTION THROUGH THE MEDIASTINUM



A – mediastinum antierius;

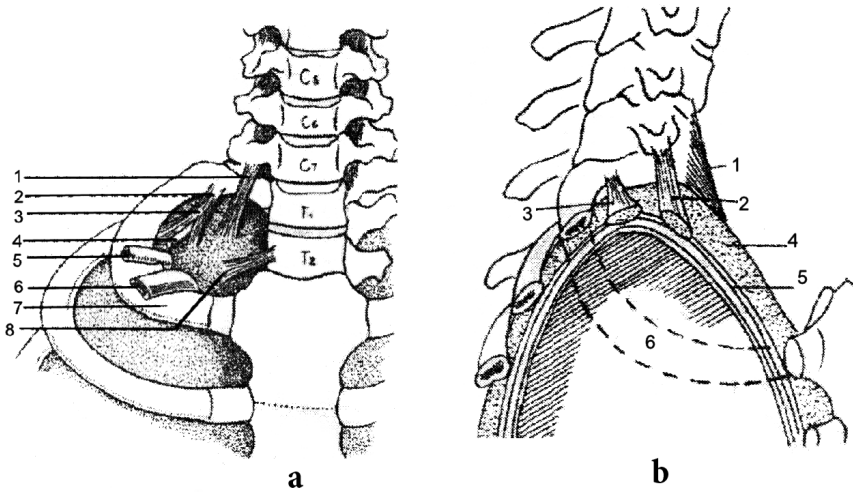
P – mediastinum posterius.

CAVITĂȚILE PLEURALE
 ПЛЕВРАЛЬНЫЕ ПОЛОСТИ
 PLEURAL CAVITIES



- 1 – recessus costomediastinales (dexter et sinister);
 2, 5 – recessus costodiaphragmatici (dexter et sinister);
 3, 4 – recessus phrenicomediastinales (dexter et sinister);
 6 – pleura visceralis;
 7 – pleura parietalis (pars costalis, pars diaphragmatica, pars mediastinalis);
 8 – cavitas pleuralis;
 9 – lig. pulmonale;
 10 – recessus vertebromediastinalis.

APARATUL SUSPENSOR AL CUPOLEI PLEURALE
(după V. Papilian)
ПОДВЕШИВАЮЩИЙ АППАРАТ СВОДА ПЛЕВРЫ
SUSPENSORY APPARATUS OF THE PLEURAL CUPOLA



a – facies anterior

- 1 – *ligamentum transversopleurale;*
- 2 – *ligamentum costopleurale;*
- 3 – *fascia endothoracica (segmentum superius);*
- 4 – *ramus ventralis nervi spinalis Th₁;*
- 5 – *arteria subclavia;*
- 6 – *vena subclavia;*
- 7 – *costa I;*
- 8 – *ligamentum vertebropleurale.*

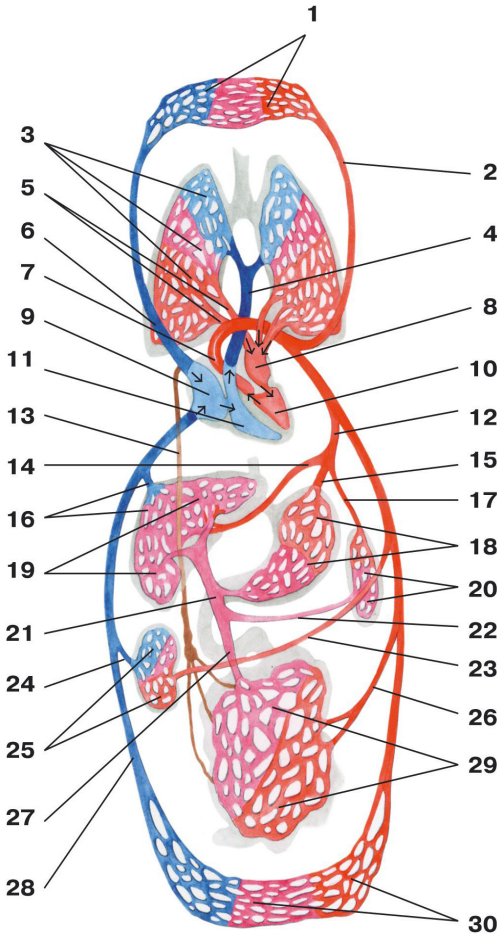
b – facies lateralis

- 1 – *ligamentum vertebropleurale;*
- 2 – *ligamentum transversopleurale;*
- 3 – *ligamentum costopleurale;*
- 4 – *fascia endothoracica;*
- 5 – *cupula pleurae;*
- 6 – *costa I.*

CIRCULAȚIA CORPORALĂ (SISTEMICĂ) ȘI PULMONARĂ

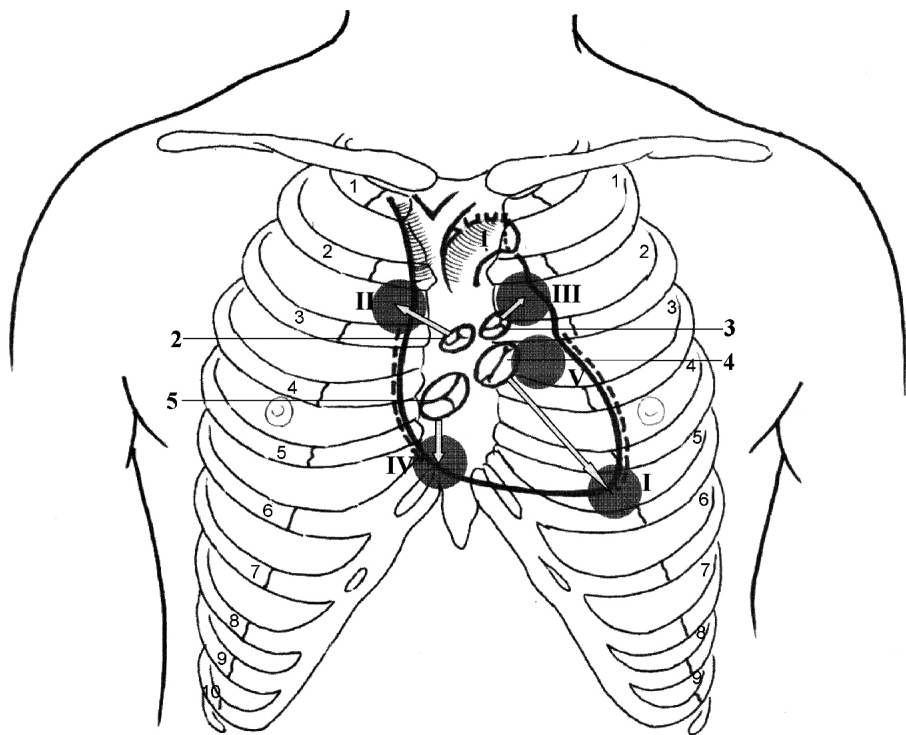
(după P.Д. Синельников)

БОЛЬШОЙ И МАЛЫЙ КРУГИ КРОВООБРАЩЕНИЯ SYSTEMIC AND PULMONARY CIRCULATION



- 1 – vasa capillaria capitis, colli, partium trunci superiorum et membrorum superiorum;
 2 – a. carotis communis;
 3 – vasa capillaria pulmonis;
 4 – truncus pulmonalis;
 5 – vv. pulmonales dextrae;
 6 – v. cava superior;
 7 – aorta;
 8 – atrium sinistrum;
 9 – atrium dextrum;
 10 – ventriculus sinister;
 11 – ventriculus dexter;
 12 – truncus coeliacus;
 13 – ductus thoracicus;
 14 – a. hepatica communis;
 15 – aa. gastricae;
 16 – vv. hepaticae;
 17 – a. splenica (lienalis);
 18 – vasa capillaria gastris;
 19 – vasa capillaria hepatis;
 20 – vasa capillaria lienis;
 21 – v. portae;
 22 – v. splenica (lienalis);
 23 – a. renalis;
 24 – v. renalis;
 25 – vasa capillaria renis;
 26 – aa. mesentericae;
 27 – vv. mesentericae;
 28 – v. cava inferior;
 29 – vasa capillaria intestini;
 30 – vasa capillaria partium trunci inferiorum et membrorum inferiorum.

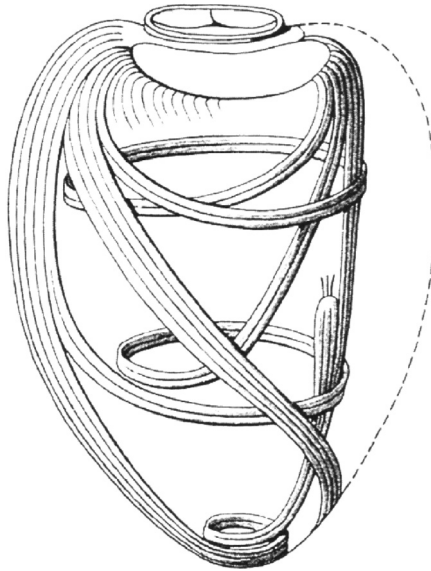
PROIECȚIA LINIILOR LIMITROFE ALE INIMII, A VALVELOR ȘI
 FOCARELE DE AUSCULTAȚIE A ZGOMOTELOR CARDIACE
 ПРОЕКЦИЯ ГРАНИЦ, КЛАПАНОВ И МЕСТА НАИЛУЧШЕГО
 ВЫСЛУШИВАНИЯ ТОНОВ СЕРДЦА
 PROJECTION ON THE CHEST OF THE BORDERS, VALVES
 AND OF THE POINTS OF AUSCULTATION OF THE HEART



- 1 - *arcus aortae*;
 2 - *valva aortae*;
 3 - *valva trunci pulmonalis*;
 4 - *valva bicuspidalis (mitralis)*;
 5 - *valva tricuspidalis*.

- I. punctum valvae atrioventricularis
 sinistrae (valva bicuspidalis sive
 mitralis);
 II. punctum valvae aortae;
 III. punctum valvae trunci pulmonalis;
 IV. punctum valvae atrioventricularis
 dextrae (valva tricuspidalis);
 V. punctum valvae aortae auxiliare
 (accessorium) Erb - Боткин.

ORIENTAREA FASCICULELOR MUSCULARE ÎN PERETELE
VENTRICULULUI STÂNG AL INIMII
НАПРАВЛЕНИЕ МЫШЕЧНЫХ ПУЧКОВ СТЕНКИ ЛЕВОГО
ЖЕЛУДОЧКА СЕРДЦА
DIRECTION OF THE MUSCLE FASCICLES (BUNDLES) WITHIN
THE WALL OF THE LEFT VENTRICLE OF THE HEART

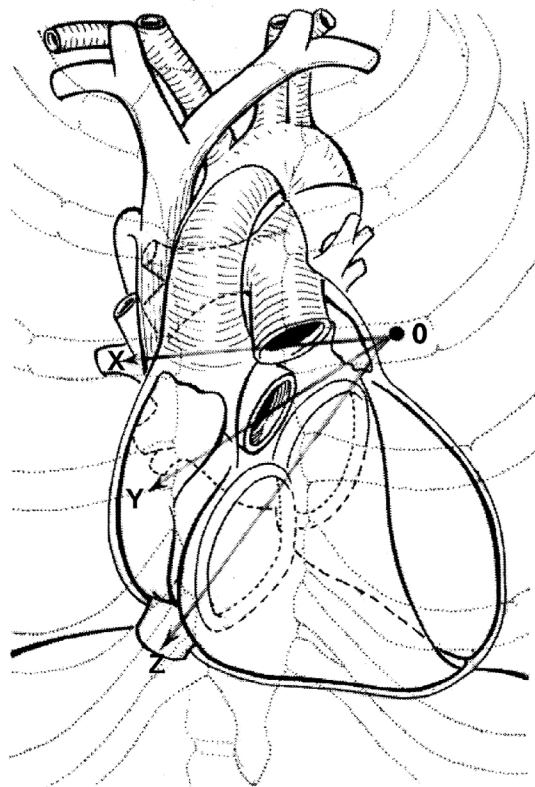


*Stratum externum – obliquum (commune ad ventriculos dextrum et sinistrum);
stratum medium –circulare (ad ventriculum quodque);
stratum internum – longitudinale (commune ad ventriculos dextrum et sinistrum).*

PROIECȚIA ORIFICIILOR INIMII PE PERETELE
TORACIC ANTERIOR

(după Merkel)

ПРОЕКЦИЯ ОТВЕРСТИЙ СЕРДЦА
НА ПЕРЕДНЮЮ СТЕНКУ ГРУДНОЙ КЛЕТКИ
PROJECTION OF THE ORIFICES
OF THE HEART ON THE THORACIC WALL



OX - linea ostii trunci pulmonalis;

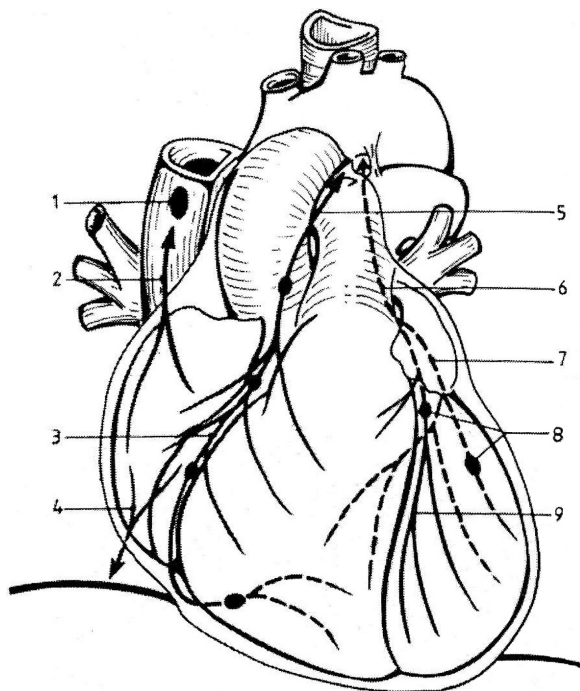
OY - linea ostii aortae;

OZ - linea ostii atrioventricularium dextrum et sinistrum.

LIMFATICELE INIMII ȘI PERICARDULUI

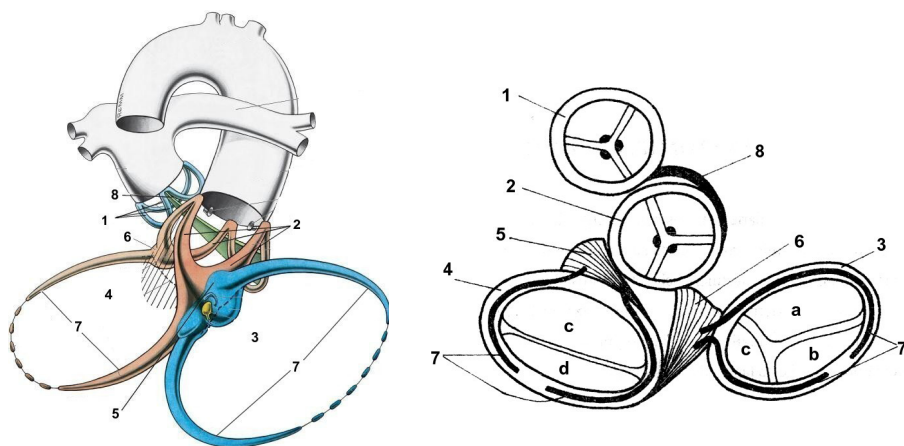
(după L. Bejan, 1999)

ЛИМФАТИЧЕСКИЕ ОБРАЗОВАНИЯ СЕРДЦА И ПЕРИКАРДА LYMPH STRUCTURES OF THE HEART AND OF THE PERICARDIUM



- 1 – *nodulus lymphaticus Beartes*;
- 2 – *truncus lymphaticus arterialis ascendens*;
- 3 – *truncus lymphaticus ventriculi dextri*;
- 4 – *truncus lymphaticus arterialis descendens*;
- 5 – *truncus collectus lymphaticus dexter*;
- 6 – *truncus collectus lymphaticus sinister*;
- 7 – *afluentia lymphatica posterior*;
- 8 – *noduli lymphatici Rainer*;
- 9 – *afluentia lymphatica anterior*.

SCHELETUL FIBROS AL INIMII
(după Gray, 2005)
ФИБРОЗНЫЙ СКЕЛЕТ СЕРДЦА
THE FIBROUS SKELETON OF THE HEART



- 1 – anulus fibrosus trunci pulmonalis;**
- 2 – anulus fibrosus aorticus;**
- 3 – anulus fibrosus dexter;**
- 4 – anulus fibrosus sinister;**
- 5 – trigonum fibrosum sinistrum;**
- 6 – trigonum fibrosum dextrum;**
- 7 – fila coronaria;**
- 8 – tendo conii pulmonalis.**

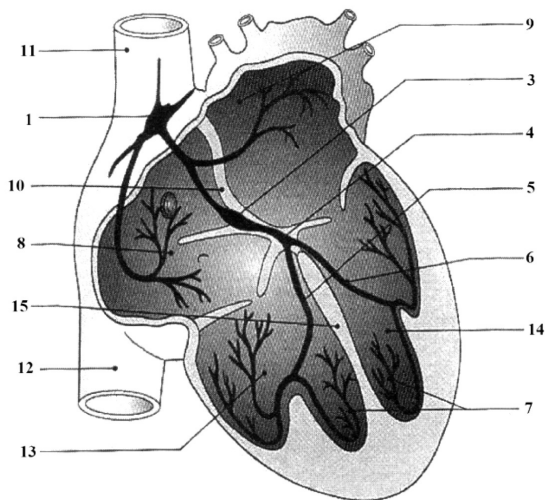
Valva tricuspidalis:

- a – cuspid anterior;**
- b – cuspid posterior;**
- c – cuspid septalis;**

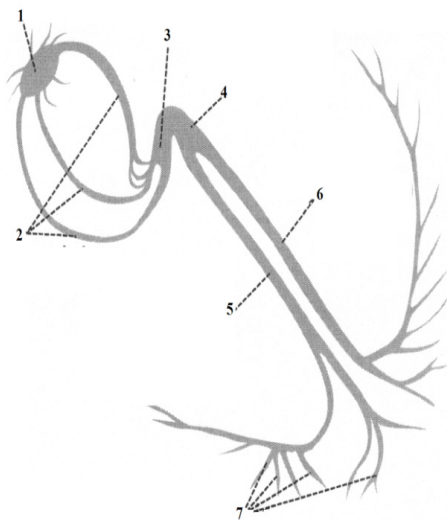
Valva bicuspidalis:

- c – cuspid anterior;**
- d – cuspid posterior.**

SISTEMUL CONDUCTIL AL CORDULUI
ПРОВОДЯЩАЯ СИСТЕМА СЕРДЦА
CONDUCTING SYSTEM OF THE HEART



- 1 – nodus sinuatrialis (Keith-Flack);**
- 2 – conexiones internodales;**
- 3 – nodus atrioventricularis (Aschoff-Tawara);**
- 4 – fasciculus atrioventricularis (His);**
- 5 – fasciculus atrioventricularis, crus dextrum;**
- 6 – fasciculus atrioventricularis, crus sinistrum;**
- 7 – rr. suendocardiales (fibrae Purkinje);**
- 8 – atrium dextrum;**
- 9 – atrium sinistrum;**
- 10 – septum interatriale;**
- 11 – vena cava superior;**
- 12 – vena cava inferior;**
- 13 – ventriculus dexter;**
- 14 – ventriculus sinister;**
- 15 – septum interventriculare.**

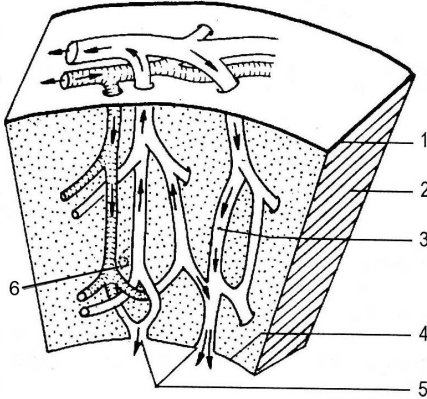


VENELE THEBESIIUS

(după L. Bejan, 1999)

ВЕНЫ THEBESIIUS

THEBESIIUS VEINS

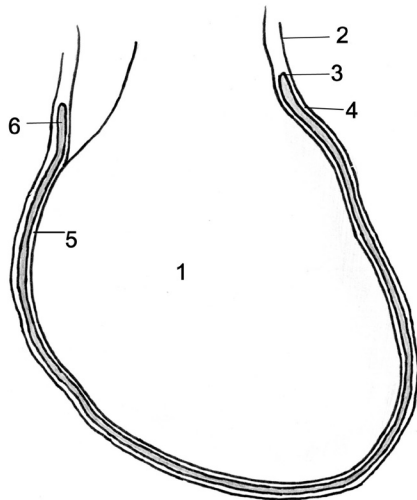


- 1 - epicardium;
- 2 - myocardium;
- 3 - canalis Thebesii;
- 4 - endocardium;
- 5 - foramina venarum minimarum (Lannelongue);
- 6 - rete capillare.

STRUCTURA PERICARDULUI

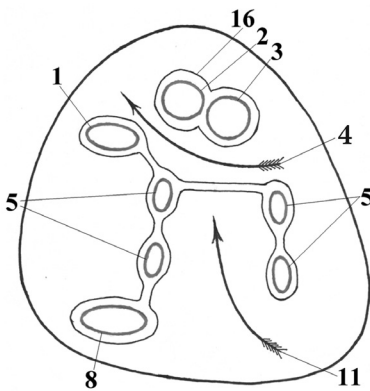
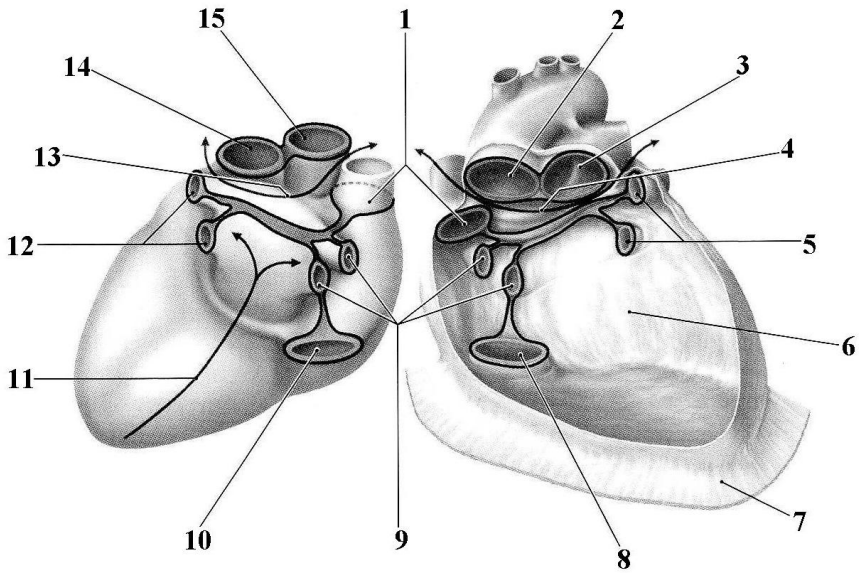
СТРОЕНИЕ ПЕРИКАРДА

STRUCTURE OF THE PERICARDIUM



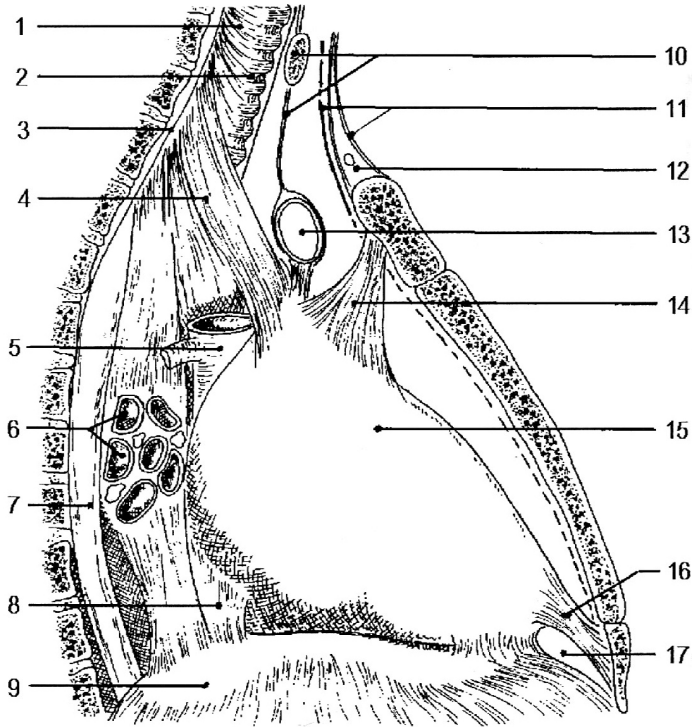
- 1 - cor;
- 2 - pericardium fibrosum;
- 3 - pericardium serosum;
- 4 - lamina parietalis;
- 5 - lamina visceralis (epicardium);
- 6 - cavitas pericardiaca.

SINUSURILE PERICARDULUI
СИНУСЫ ПЕРИКАРДА
SINUSES OF THE PERICARDIUM



- 1 – ostium venae cavae superioris;
- 2, 15 – ostium aortae ascendantis;
- 3, 14 – ostium trunci pulmonalis;
- 4, 13 – sinus transversus pericardii;
- 5, 9, 12 – ostia venarum pulmonalium (sinsitra et dextra);
- 6 – cavitas pericardiaca;
- 7 – adhaesio pericardii fibrosi ad fasciam diaphragmaticam;
- 8, 10 – ostium venae cavae inferioris;
- 11 – sinus obliquus pericardii;
- 16 – pericardium.

LIGAMENTELE PERICARDULUI
(după L. Bejan, 1999)
СВЯЗКИ ПЕРИКАРДА
LIGAMENTS OF THE PERICARDIUM



- 1 - *lig. vertebroviscerale;*
- 2 - *trachea;*
- 3 - *lamina (fascia) prevertebralis;*
- 4 - *lig. vertebropericardiacum sinistrum (Beraud);*
- 5 - *vena cava superior;*
- 6 - *bronchus lobaris et bronchus intermedius dexter;*
- 7 - *oesophagus;*
- 8 - *ligg. phrenicopericardiaca;*

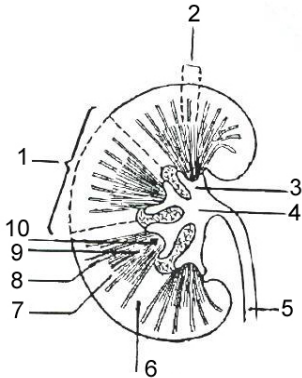
- 9 - *diaphragma;*
- 10 - *isthmus gl. thyroideae et lig. thyroaortopericardiacum;*
- 11 - *fascia cervicalis et fascia omoclavicularis;*
- 12 - *spatium suprasternale;*
- 13 - *v. brachiocephalica sinistra;*
- 14 - *lig. sternopericardiacum;*
- 15 - *pericardium fibrosum;*
- 16 - *lig. sternopericardiacum inferius;*
- 17 - *spatium Barbieri.*

STRUCTURA INTERNĂ A RINICHIULUI

(după V. Papilian, 1995)

ВНУТРЕННЕЕ СТРОЕНИЕ ПОЧКИ

INTERNAL STRUCTURE OF THE KIDNEY



- 1 – lobus renalis;
- 2 – lobulus corticalis;
- 3 – calyx renalis;
- 4 – pelvis renalis;
- 5 – ureter;
- 6 – columnae renales (Bertini);
- 7 – pars convoluta;
- 8 – pars radiata;
- 9 – pyramides renales (Malpighi);
- 10 – papillae renales.

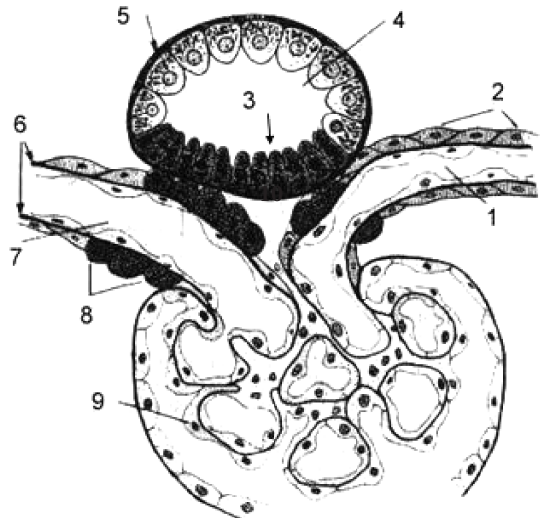
STRUCTURA COMPLEXULUI JUXTAGLOMERULAR

(după A. Guyton, 1997)

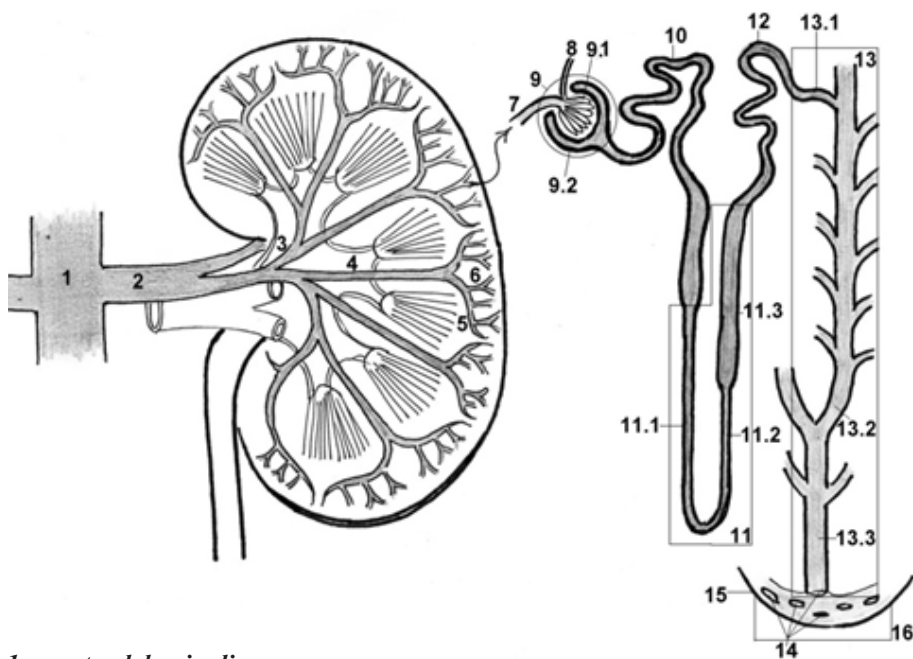
СТРУКТУРА ЮКСТАГЛОМЕРУЛЯРНОГО КОМПЛЕКСА

STRUCTURE OF THE JUXTAGLOMERULAR COMPLEX

- 1 – arteriola glomerularis efferens (vas efferens);
- 2 – tunica media arteriolar glomerularis;
- 3 – macula densa (epitheliocytes maculae densae);
- 4 – tubulus contortus distalis;
- 5 – membrana basalis;
- 6 – lamina elastica interna;
- 7 – arteriola glomerularis afferens (vas afferens);
- 8 – endocrinocytes myoidei (juxtaglomerulocytes);
- 9 – glomerulus (rete capillare glomerulare, vasa capillaria glomerularia);
- 10 – insula perivascularis mesangii (mesangiocytes).



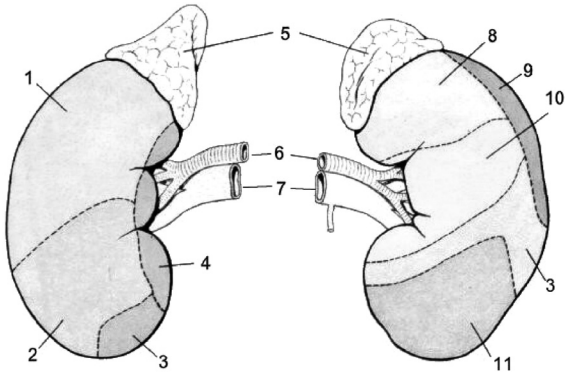
SCHEMA NEFRONULUI
 СХЕМА НЕФРОНА
 SCHEME OF THE NEPHRON



- 1 – aorta abdominalis;
- 2 – a. renalis;
- 3 – a. segmenti anterioris superioris;
- 4 – a. interlobaris;
- 5 – a. arcuata;
- 6 – a. interlobularis;
- 7 – arteriola glomerularis afferens
(vas afferens);
- 8 – arteriola glomerularis efferens
(vas efferens);
- 9 – corpusculum renale
(Malpighi – Шумлянскій);
- 9.1 – glomerulus (rete capillare
glomerulare, vasa capillaria
glomerularia);
- 9.2 – capsula glomeruli
(Шумлянскій – Bowman);

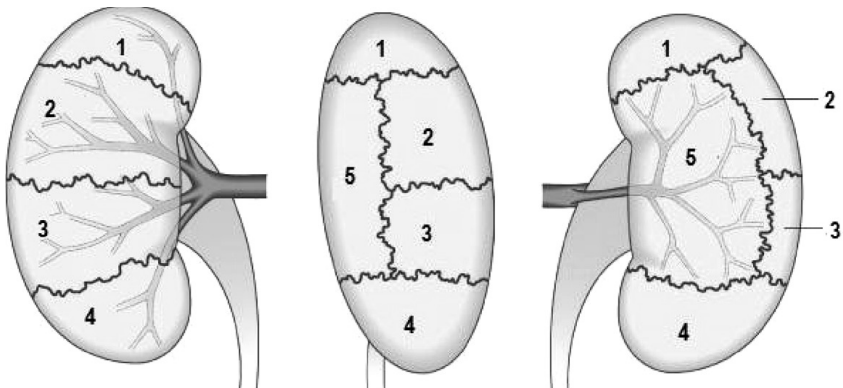
- 10 – tubulus contortus proximalis;
- 11 – ansa nephroni (Henle);
- 11.1 – pars descendens tubuli
attenuati;
- 11.2 – pars ascendens tubuli
attenuati;
- 11.3 – tubulus rectus distalis;
- 12 – tubulus contortus distalis;
- 13 – tubulus renalis colligans;
- 13.1 – tubulus renalis arcuatus;
- 13.2 – tubulus colligans rectus;
- 13.3 – ductus papillaris;
- 14 – foramina papillaria;
- 15 – papilla renalis;
- 16 – area cribrosa.

SINTOPIA RINICHIOR
СИНТОПИЯ ПОЧЕК
SYNTOPY OF THE KIDNEYS



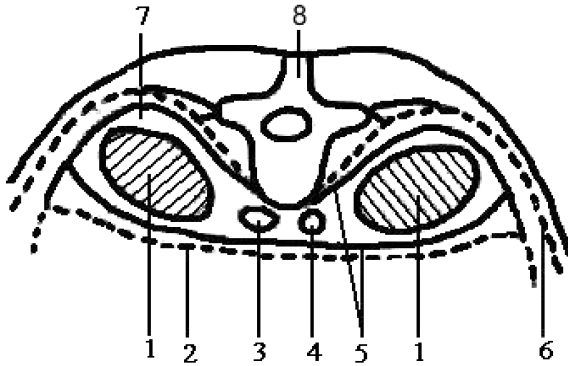
- 1 – *area hepatica*;
- 2 – *area colica*;
- 3 – *area jejunalis*;
- 4 – *area duodenalis*;
- 5 – *glandulae suprarenales*;
- 6 – *aa. renales*;
- 7 – *vv. renales*;
- 8 – *area gastrica*;
- 9 – *area lienalis*;
- 10 – *area pancreatica*;
- 11 – *area colica*.

SEGMENTELE RENALE
СЕГМЕНТЫ ПОЧЕК
SEGMENTS OF THE KIDNEYS



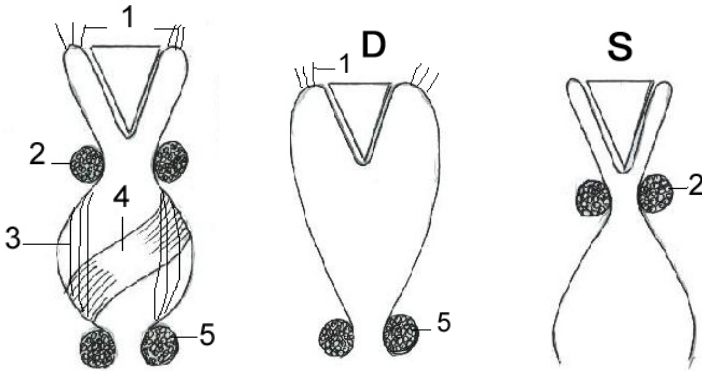
- 1 – *segmentum superius*;
- 2 – *segmentum anterius superius*;
- 3 – *segmentum anterius inferius*;
- 4 – *segmentum inferius*;
- 5 – *segmentum posterius*.

SCHEMA ÎNVELIȘURILOR RINICHIULUI
 (după H.B. Крылов, А.И. Искренко, 1986)
СХЕМА ОБОЛОЧЕК ПОЧЕК
SCHEME OF THE COATS OF THE KIDNEYS



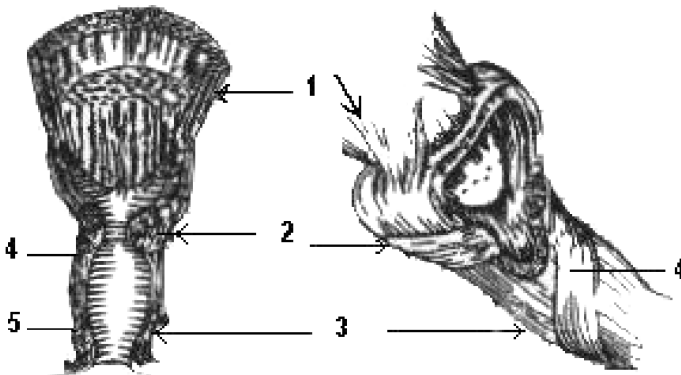
- 1 – *ren et capsula fibrosa*;
 2 – *peritoneum parietale*;
 3 – *v. cava inferior*;
 4 – *aorta*;
 5 – *fascia renalis (lamina pre- et retrorenalis)*;
 6 – *fascia transversalis*
 (*extroperitonealis, endoabdominalis*);
 7 – *capsula adiposa (Gerota)*;
 8 – *vertebra lumbalis*.

APARATUL FORNICAL AL RINICHIULUI
 ФОРНИКАЛЬНЫЙ АППАРАТ ПОЧКИ
 FORNICAL APPARATUS OF THE KIDNEY (calyces)



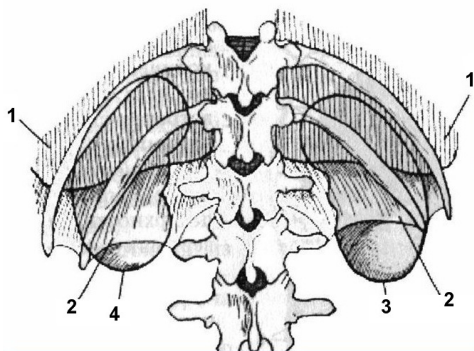
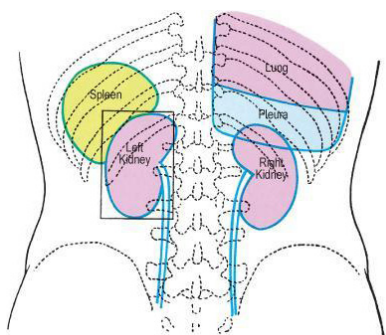
S – systole;
 D – diastole;

1 – *m. levator fornycis*;
 2 – *m. sphincter fornycis*;
 3 – *m. longitudinalis calycis*;
 4 – *m. spiralis calycis*;
 5 – *m. sphincter calycis*.



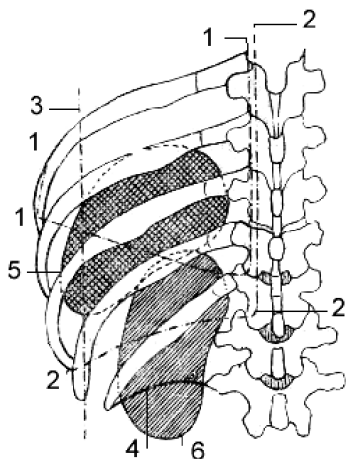
1 – *m. levator fornycis*;
 2 – *m. sphincter fornycis*;
 3 – *m. longitudinalis calycis*;
 4 – *m. spiralis calycis*;
 5 – *m. sphincter calycis*.

SCHELETOTOPIA RINICHILOR (aspect posterior)
СКЕЛЕТОТОПИЯ ПОЧЕК (вид сзади)
THE SKELETOTOPY OF THE KIDNEYS (posterior view)



- 1 – pleura parietalis;**
2 – diaphragma;
3 – ren dexter;
4 – ren sinister.

PROIECȚIA SPLINEI ȘI A RINICHIULUI STÂNG (aspect posterior)
(după V. Papilian, 1998)
ПРОЕКЦИЯ СЕЛЕЗЕНКИ И ЛЕВОЙ ПОЧКИ (вид сзади)
PROJECTION OF THE SPLEEN AND OF THE LEFT KIDNEY (posterior view)



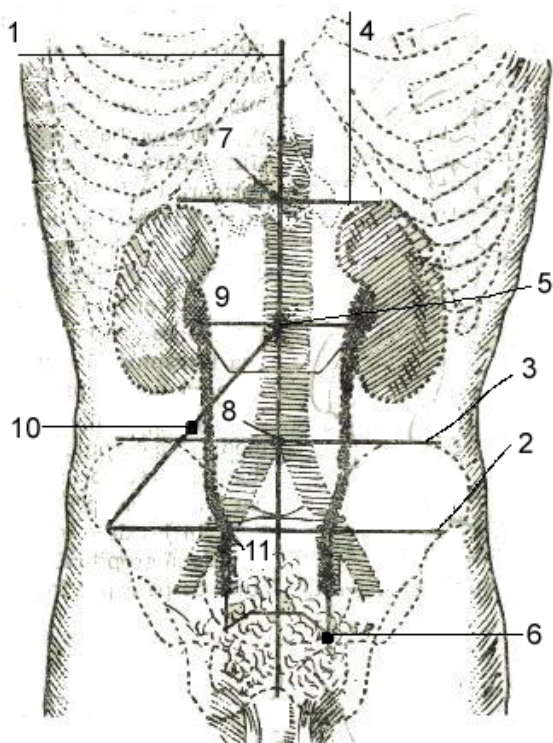
- 1 – margines pulmonis sinistri;**
2 – proectio sinuum costomediastinalis posterioris et costodiaphragmatici sinistrorum;
3 – linea axillaris posterior;
4 – arcus lumbocostalis sinister;
5 – lien;
6 – ren sinister.

REPERE TOPOGRAFICE PENTRU PROIEȚIA RINICHILOR ȘI URETERELOR

(după V. Papilian, 1998)

ТОПОГРАФИЧЕСКИЕ ОРИЕНТИРЫ ПРОЕКЦИИ ПОЧЕК И МОЧЕТОЧНИКОВ

TOPOGRAPHICAL REFERENCE POINTS FOR THE PROJECTION OF THE KIDNEYS AND URETERS



1 - *linea mediana;*

2 - *distantia spinarum;*

3 - *distantia cristarum;*

4 - *linea bicostarum*
(*costae IX*);

5 - *umbilicus;*

6 - *tuberculum pubicum;*

7 - *punctum coeliacum;*

8 - *punctum aorticum;*

9 - *punctum uretericum*
superius (Bazy);

10 - *punctum appendiculare*
(*Mc Burney*);

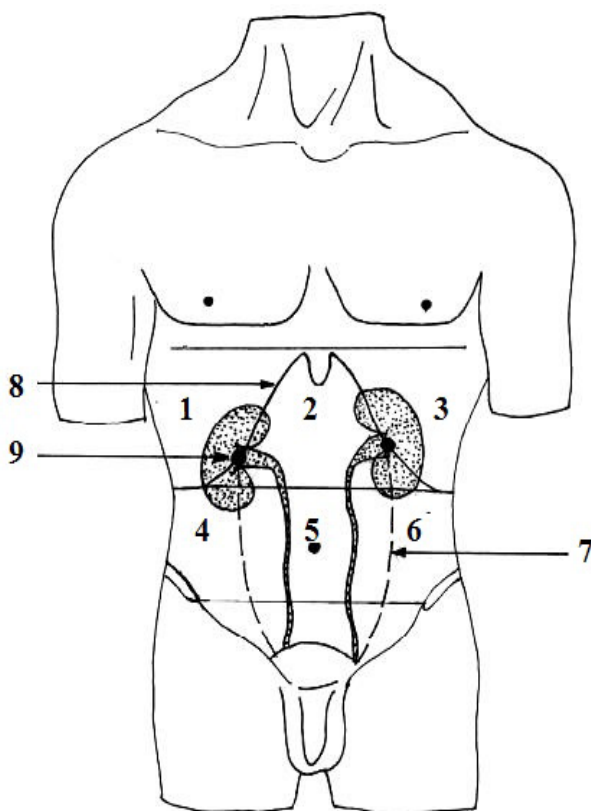
11 - *punctum uretericum*
medium.

**PROIECȚIA RINICHILOR ȘI HILULUI RENAL PE PERETELE
ABDOMINAL ANTERIOR**

(după V.I. Лабзин, А.А. Родионов, 2005)

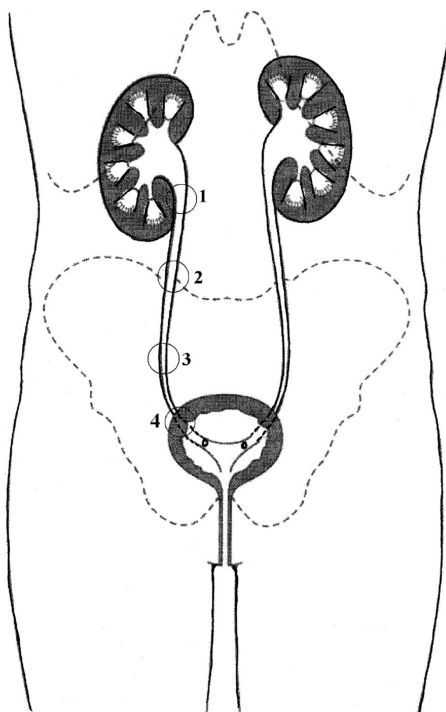
**ПРОЕКЦИЯ ПОЧЕК И ПОЧЕЧНЫХ ВОРОТ НА ПЕРЕДНЮЮ СТЕНКУ
БРЮШНОЙ ПОЛОСТИ**

**PROJECTION OF THE KIDNEYS AND OF THE RENAL HILUM
ON THE ANTERIOR ABDOMINAL WALL**



- 1, 3 – *regiones hypochondriacae dextra et sinistra;*
2 – *regio epigastrica;*
4, 6 – *regiones laterales abdominis dextra et sinistra;*
5 – *regio umbilicalis;*
7 – *linea pararectomuscularis;*
8 – *circumscriptio arcus costalis;*
9 – *punctum renale anterius.*

ÎNGUSTĂRILE URETERULUI
СУЖЕНИЯ МОЧЕТОЧНИКА
CONSTRICTIONS THE URETER

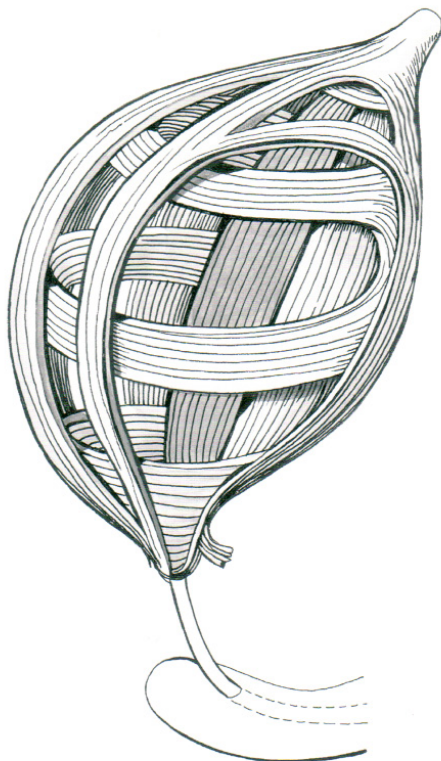


- 1 - la trecerea bazinetului în ureter;
- 2 - la întretăierea cu vasele testiculare/ovariene (inconstant);
- 3 - la trecerea părții abdominale în cea pelviană;
- 4 - la intrarea în vezica urinară.

- 1 - у перехода лоханки в мочеточник;
- 2 - при пересечении с яичковыми /яичниковыми сосудами (не постоянный);
- 3 - у перехода брюшной части мочеточника в тазовую;
- 4 - у входа в мочевой пузырь.

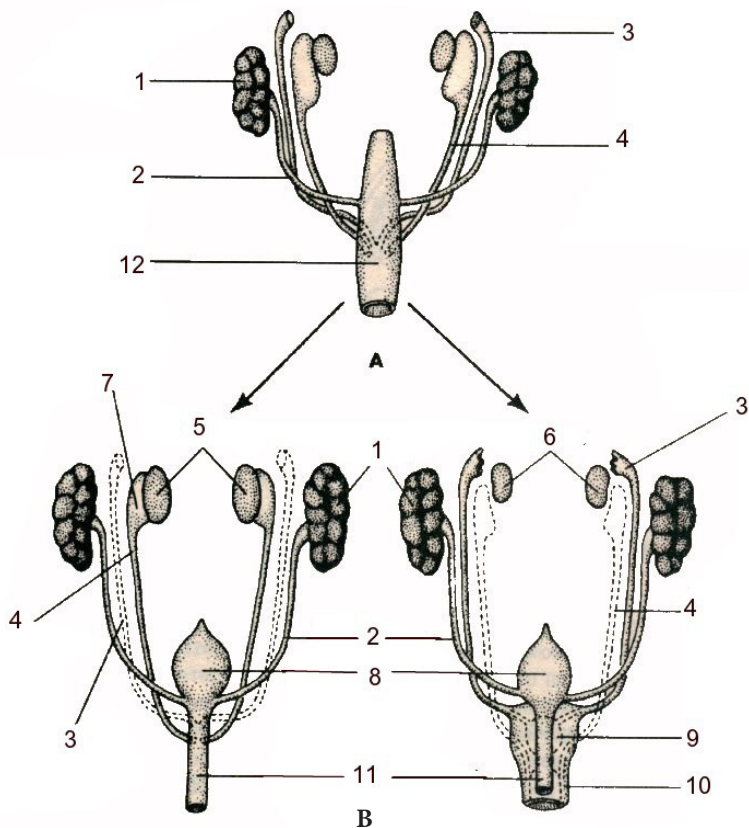
- 1 - at the level where the renal pelvis continues with the ureter;
- 2 - at the level where the ureter is crossed by the testicular / ovarian vessels (it is inconstant);
- 3 - at the level where the abdominal part of the ureter continues with the pelvic one;
- 4 - at the level where the ureter penetrates the urinary bladder.

ARANJAREA STRATURILOR MUSCULARE
ÎN PERETELE VEZICII URINARE
РАСПОЛОЖЕНИЕ МЫШЕЧНЫХ СЛОЁВ
СТЕНКИ МОЧЕВОГО ПУЗЫРЯ
ARRANGEMENT OF THE MUSCULAR LAYERS
WITHIN THE WALL OF THE URINARY BLADDER



- 1 – stratum externum – longitudinale;*
2 – stratum medium – circulare;
3 – stratum internum – longitudinale.

DIFERENȚIEREA GONADELOR
 (diră Э.Г. Улумбеков, Ю.А. Чельшев, 1997)
ПОЛОВАЯ ДИФФЕРЕНЦИРОВКА ГОНАД
DIFFERENTIATION OF THE GONADS



A – stadiul indiferent/индифферентный период/indifferent stage

B – stadiul de diferențiere/период дифференциаций/stage of differentiation

1 – renes;

2 – ureter;

3 – ductus paramesonephricus (Müller);

4 – ductus mesonephricus (Wolff);

5 – testes;

6 – ovaria;

7 – epididymis;

8 – vesica urinaria;

9 – uterus;

10 – pars superior vaginae;

11 – urethra;

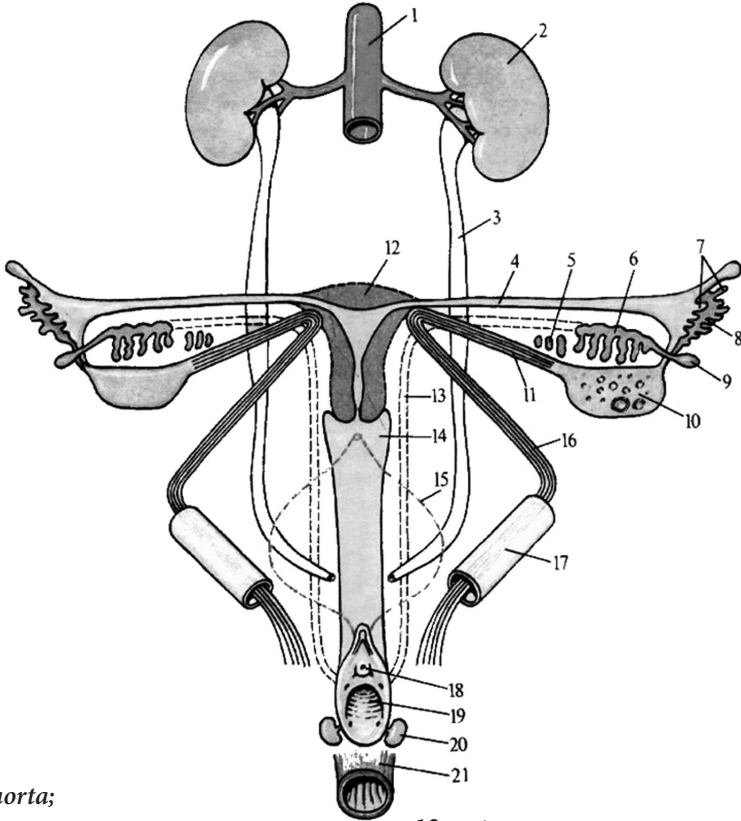
12 – cloaca.

SCHEMA DEZVOLTĂRII ORGANELOR GENITALE FEMININE

(după P.Д. Синельников, Я.Р. Синельников, 1990)

СХЕМА РАЗВИТИЯ ВНУТРЕННИХ ЖЕНСКИХ ПОЛОВЫХ ОРГАНОВ

SCHEME OF THE DEVELOPMENT OF THE INTERNAL FEMALE GENITAL ORGANS



1 - aorta;

2 - ren;

3 - ureter;

4 - tuba uterina;

5 - paroophoron;

6 - epoophoron;

7 - fimbriae tubae uterinae;

8 - ostium abdominale tubae uterinae;

9 - appendix vesiculosa;

10 - ovarium;

11 - lig. ovarii proprium;

12 - uterus;

13 - ductus mesonephricus (Wolff);

14 - vagina;

15 - vesica urinaria;

16 - lig. teres uteri;

17 - canalis inguinalis;

18 - ostium urethrae externum;

19 - ostium vaginae;

20 - glandula vestibularis major;

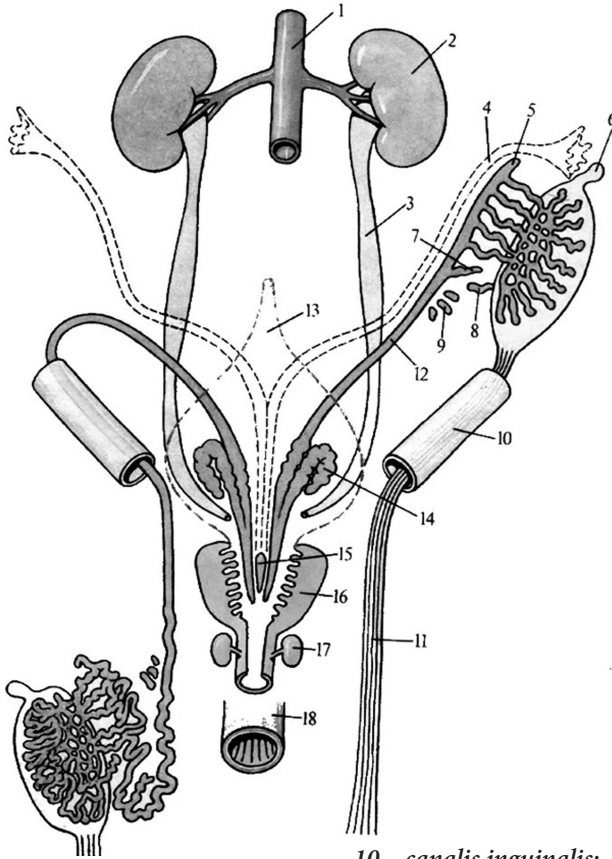
21 - rectum.

SCHEMA DEZVOLTĂRII ORGANELOR GENITALE MASCULINE

(diră P.Д. Синельников, Я.Р. Синельников, 1990)

СХЕМА РАЗВИТИЯ ВНУТРЕННИХ МУЖСКИХ ПОЛОВЫХ ОРГАНОВ

SCHEME OF THE DEVELOPMENT OF THE INTERNAL MALE GENITAL ORGANS



1 - aorta;

2 - ren;

3 - ureter;

4 - ductus paramesonephricus (Müller);

5 - appendix epididymidis;

6 - appendix testis;

7 - ductus aberrans inferior;

8 - ductus aberrans superior;

9 - paradydimis;

10 - canalis inguinalis;

11 - gubernaculum testis (BNA);

12 - ductus mesonephricus;

13 - vesica urinaria;

14 - vesicula seminalis;

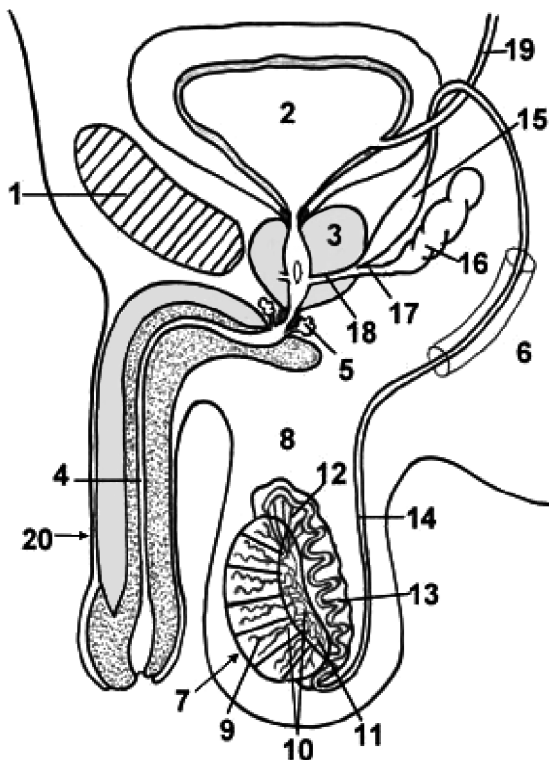
15 - utriculus prostaticus;

16 - prostata;

17 - glandula bulbourethralis;

18 - rectum.

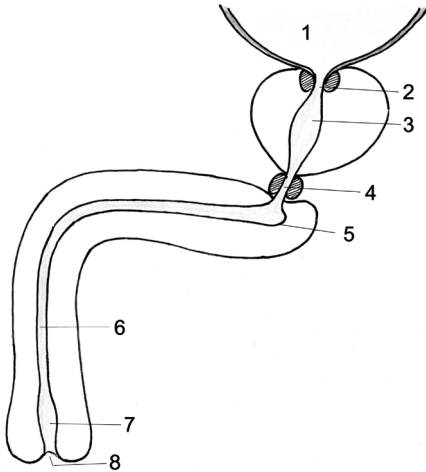
**ORGANELE GENITALE MASCULINE.
CĂILE DE EVACUARE A SPERMEI
МУЖСКИЕ ПОЛОВЫЕ ОРГАНЫ. СЕМЯВЫНОСЯЩИЕ ПУТИ
MALE GENITAL ORGANS. SPERM-CONVEYING DUCTS**



1 – *symphysis pubica*;
2 – *vesica urinaria*;
3 – *prostata*;
4 – *urethra masculina*;
5 – *glandulae bulbourethrales*
(*Cowperi*);
6 – *canalis inguinalis*;
7 – *testis*;
8 – *epididymis*;
9 – *tubuli seminiferi contorti*;
10 – *tubuli seminiferi recti*;

11 – *rete testis*;
12 – *ductuli efferentes testis*;
13 – *ductus epididymidis*;
14 – *ductus deferens*;
15 – *ampulla ductus deferentis*;
16 – *vesicula seminalis*;
17 – *ductus excretorius*;
18 – *ductus ejaculatorius*;
19 – *ureter*;
20 – *penis*.

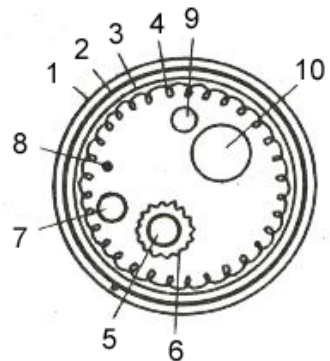
CURBURILE, STRICTURILE ȘI DILATĂRILE URETREI MASCULINE
ИЗГИБЫ, СУЖЕНИЯ И РАСШИРЕНИЯ МУЖСКОГО
МОЧЕИСПУСКАТЕЛЬНОГО КАНАЛА
CURVATURES, NARROWINGS AND DILATATIONS OF THE MALE
URETHRA



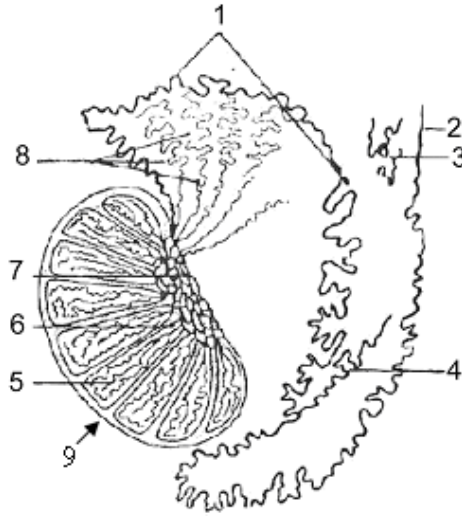
- 1 – vesica urinaria;
- 2 – ostium urethrae internum;
- 3 – dilatatio partis prostatica urethrae;
- 4 – strictura partis membranaceae urethrae;
- 5 – bulbus penis;
- 6 – pars spongiosa;
- 7 – fossa navicularis urethrae;
- 8 – ostium urethrae externum.

ELEMENETELE COMPONENTE ALE FUNICULULUI SPERMATIC
(secțiune transversală)
СОСТАВНЫЕ ЭЛЕМЕНТЫ СЕМЕННОГО КАНАТИКА
(поперечный разрез)
COMPONENT ELEMENTS OF THE SPERMATIC CORD
(transverse section)

- 1 – fascia cremasterica;
- 2 – m. cremaster;
- 3 – fascia spermatica interna;
- 4 – plexus pampiniformis;
- 5 – a. testicularis;
- 6 – plexus testicularis;
- 7 – a. cremasterica;
- 8 – ramus genitalis n. genitofemoralis;
- 9 – a. ductus deferentis;
- 10 – ductus deferens.

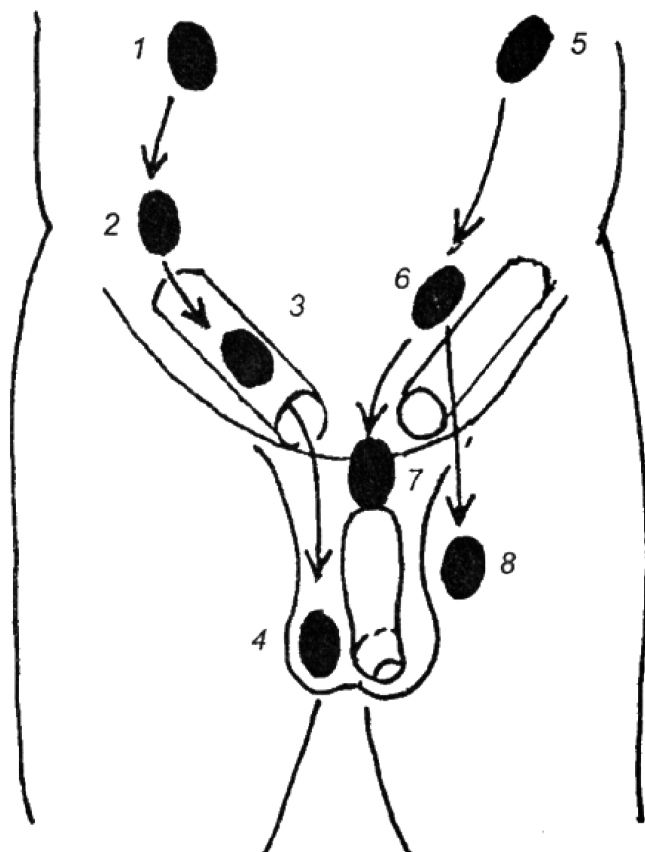


**CANALICULELE SECRETORII ȘI EXCRETORII
ALE TESTICULULUI ȘI EPIDIDIMULUI
ВЫДЕЛЯЮЩИЕ И ВЫНОСЯЩИЕ КАНАЛЬЦЫ ЯИЧКА
И ЕГО ПРИДАТКА
SECRETORY AND EXCRETORY CANALICLES
OF THE TESTIS AND OF THE EPIDIDYMIS**



- 1 - ductus epididymidis;
- 2 - ductus deferens;
- 3 - paradidymis;
- 4 - ductuli aberrantes;
- 5 - tunica albuginea;
- 6 - rete testis;
- 7 - tubuli seminiferi recti;
- 8 - ductuli efferentes testis;
- 9 - ductuli aberrantes.

DESCINDEREA TESTICULELOR
 ОПУСКАНИЕ ЯИЧЕК
 DESCENT OF THE TESTIS



Descensus testis (*pars sinistra*):

- 1 - testis in cavitate abdominis;
- 2 - testis ad lineam anuli interni canalis inguinalis;
- 3 - testis in canale inguinali;
- 4 - testis in scroto.

Retentio et ectopia testis (*pars dextra*):

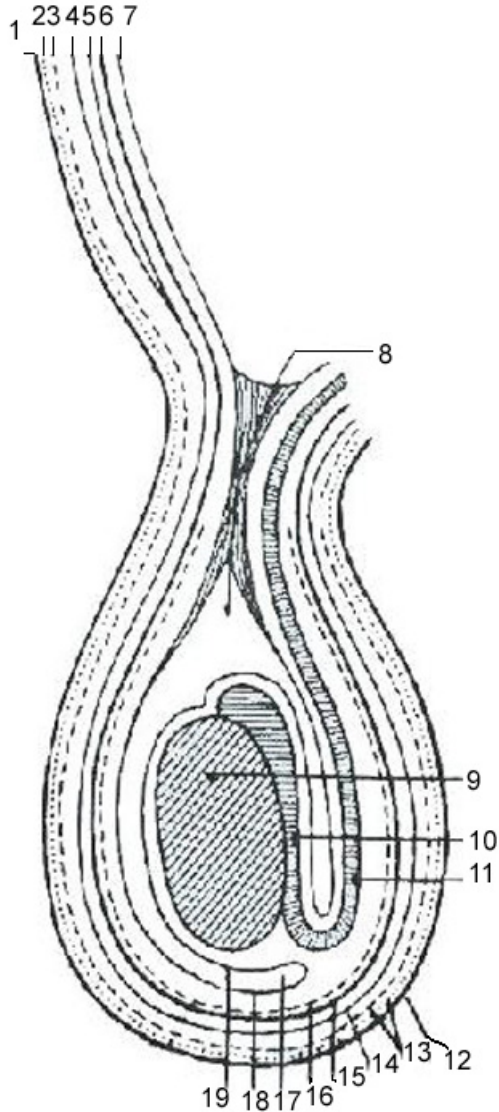
- 5 - retentio abdominalis;
- 6 - ectopia pelvica;
- 7 - ectopia pubica;
- 8 - ectopia femoralis.

ÎNVELIȘURILE TESTICULULUI ȘI ALE FUNICULULUI SPERMATIC

(după Kiss-Szentágothai)

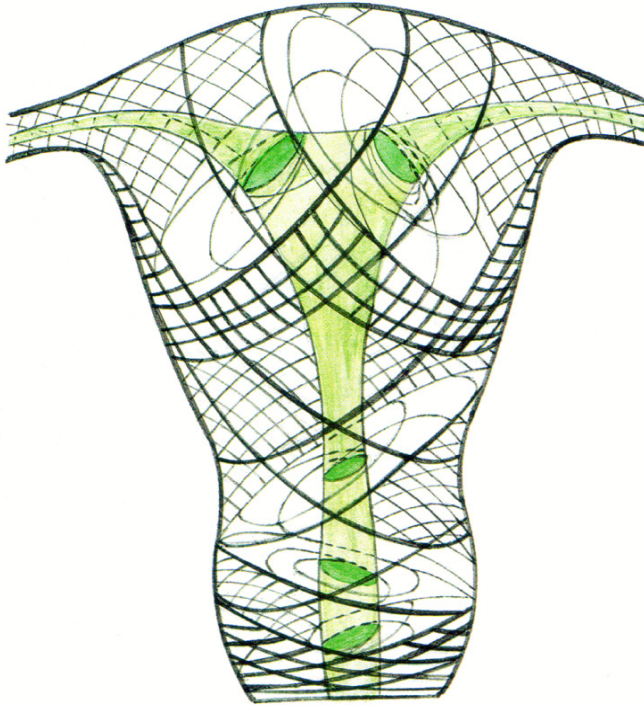
ОБОЛОЧКИ ЯИЧКА И СЕМЕНОГО КАНАТИКА

COATS OF THE TESTIS AND OF THE SPERMATIC CORD



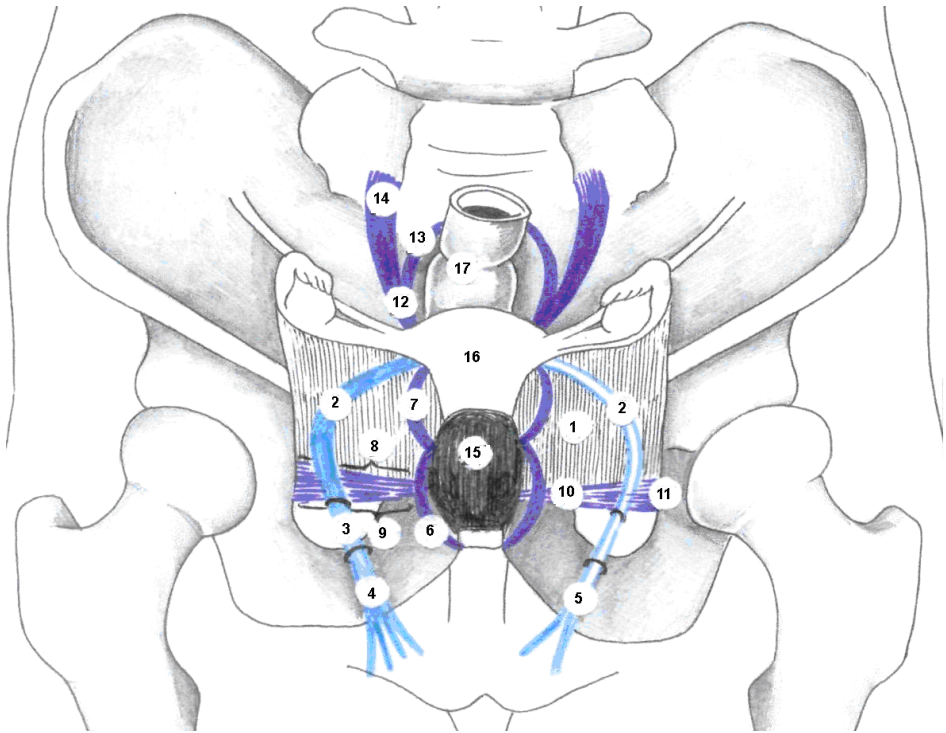
- 1 - *cutis abdominis*;
- 2 - *tela subcutanea*;
- 3 - *m. obliquus externus abdominis*;
- 4 - *m. obliquus internus abdominis*;
- 5 - *m. transversus abdominis*;
- 6 - *fascia transversalis*;
- 7 - *peritoneum parietale*;
- 8 - *fossa inguinalis lateralis et recessus vaginalis*;
- 9 - *testis*;
- 10 - *epididymis*;
- 11 - *ductus deferens*;
- 12 - *cutis scroti*;
- 13 - *tunica dartos*;
- 14 - *fascia spermatica externa*;
- 15 - *fascia cremasterica et m. cremaster*;
- 16 - *fascia spermatica interna*;
- 17 - *tunica vaginalis testis (cavum vaginale)*;
- 18 - *lamina parietalis tunicae vaginalis testis*;
- 19 - *lamina visceralis tunicae vaginalis testis*.

STRATURILE MIOMETRULUI
СЛОИ МИОМЕТРИЯ
LAYERS OF THE MYOMETRIUM



Stratum submucosum – fibrae longitudinales et obliquae;
stratum vasculosum – fibrae longitudinales;
stratum supravasculosum – fibrae circulares;
stratum subserosum – fibrae longitudinales.

APARATUL LIGAMENTAR AL UTERULUI
(după O. Belic)
СВЯЗОЧНЫЙ АППАРАТ МАТКИ
LIGAMENTARY APPARATUS OF THE UTERUS



1 - lig. latum uteri;
 2, 3, 4, 5 - lig. teres uteri:
 2 - segmentum pelvinum;
 3 - segmentum inguinale;
 4, 5 - segmentum
 postinguinale;
 6 - lig. pubovesicale;
 7 - lig. vesicouterinum;
 8, 9, 10, 11 - lig. cardinale:
 8 - pars superior;
 9 - pars inferior;

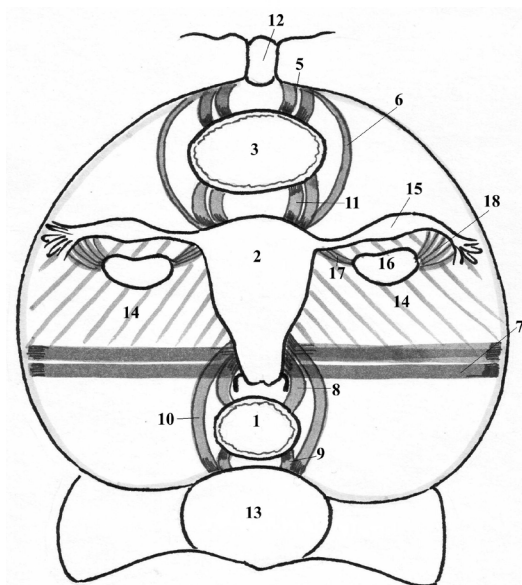
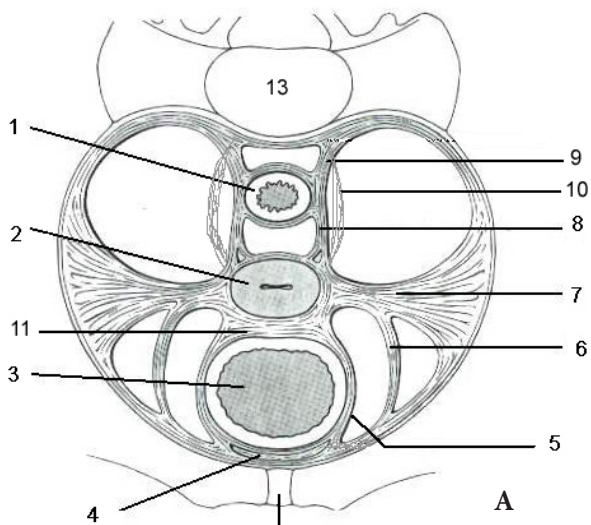
10 - pars medialis;
 11 - pars lateralis;
 12, 13, 14 - lig. sacrouterinum:
 12 - pars uterina;
 13 - pars rectalis;
 14 - pars sacralis;
 15 - vesica urinaria;
 16 - uterus;
 17 - rectum.

ELEMENTELE DE FIXARE ALE ORGANELOR PELVIENE

(A - după R.M.H.McMinn, R.T.Hutchings, 1977)

ФИКСИРУЮЩИЙ АППАРАТ ОРГАНОВ ТАЗА

FIXATION APPARATUS OF THE PELVIC ORGANS



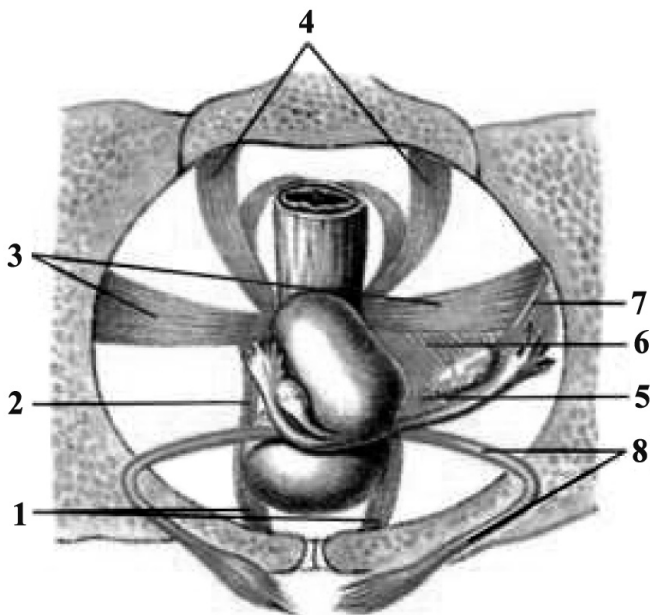
- 1 – *rectum*;
- 2 – *uterus*;
- 3 – *vesica urinaria*;
- 4 – *spatium retropubicum*;
- 5 – *lig. pubovesicale*;
- 6 – *lig. teres uteri*;
- 7 – *lig. cardinale (lig. transversum cervicis)*;
- 8 – *lig. rectouterinum*;
- 9 – *lig. sacrorectale*;
- 10 – *lig. sacrouterinum*;
- 11 – *lig. vesicouterinum*;
- 12 – *symphysis pubica*;
- 13 – *os sacrum*;
- 14 – *lig. latum uteri*;
- 15 – *tuba uterina (salpinx)*;
- 16 – *ovarium*;
- 17 – *lig. ovarii proprium*;
- 18 – *lig. suspensorium ovarii*.

APARATUL DE FIXARE ȘI SUSȚINERE A UTERULUI
(secțiune transversală)

(după A. B. Николаев, 2009)

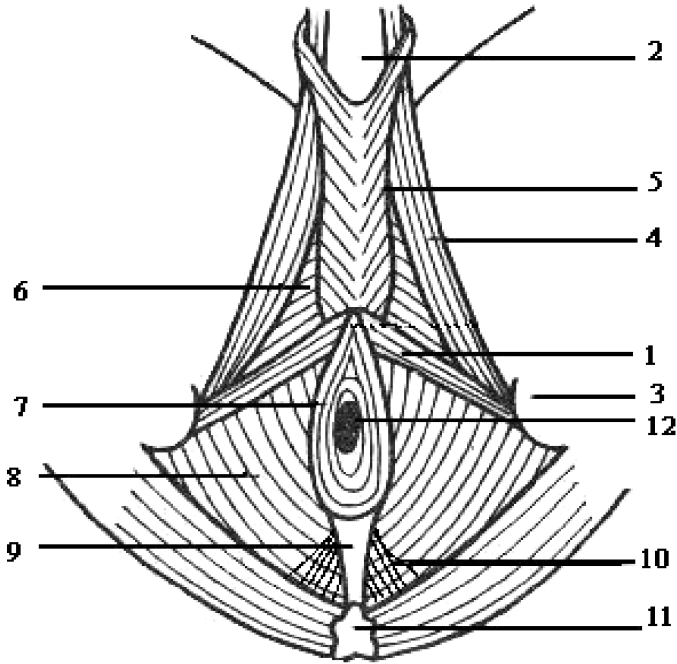
ФИКСИРУЮЩИЙ И ПОДДЕРЖИВАЮЩИЙ АППАРАТ МАТКИ
НА ПОПЕРЕЧНОМ СРЕЗЕ (схема)

THE FIXATION AND SUSTAINING APPARATUS OF THE UTERUS
(transverse section)



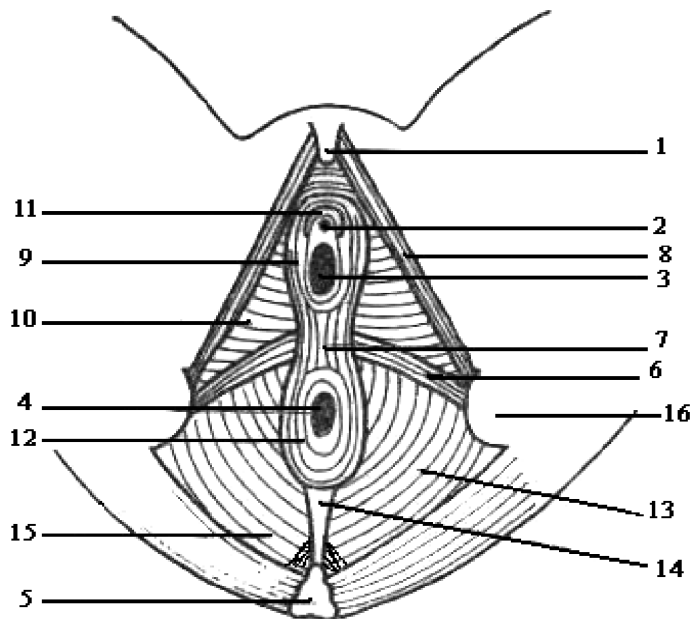
- 1 - *ligg. pubovesicale*;
- 2 - *lig. pubovaginalis / pubouterinus*;
- 3 - *ligg. cardinalia*;
- 4 - *lig. sacrouterinum*;
- 5 - *lig. ovarii proprium*;
- 6 - *m. levator ani*,
- 7 - *lig. suspensorium ovarii*;
- 8 - *lig. teres uteri*.

MUȘCHII PERINEULUI LA BĂRBAT
 (după H.V. Крылов, 1986)
МЫШЦЫ МУЖСКОЙ ПРОМЕЖНОСТИ
MUSCLES OF THE MALE PERINEUM



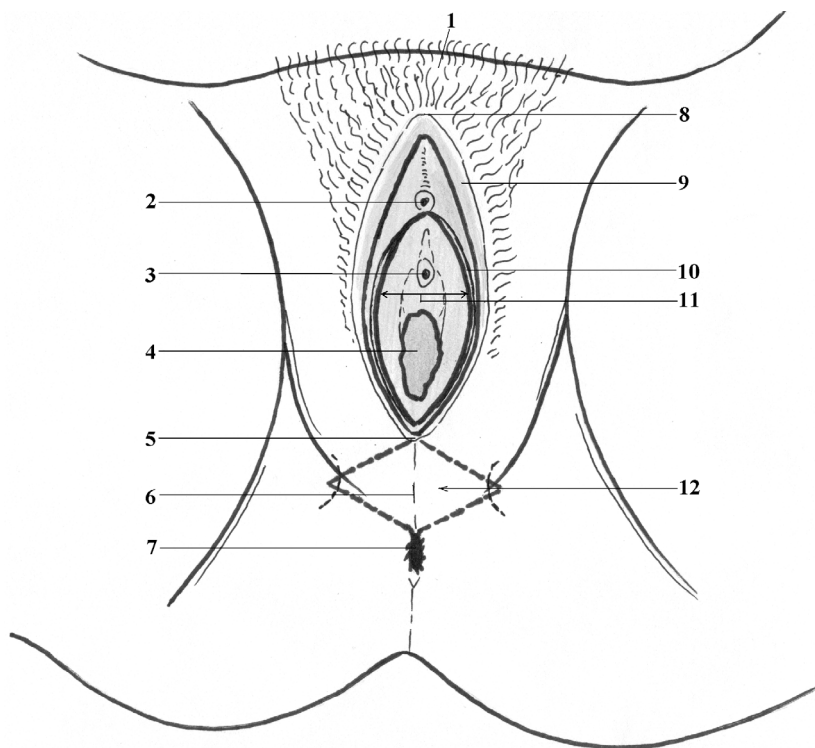
- 1 - *m. transversus perinei superficialis*;
 2 - *symphysis pubica*;
 3 - *tuber ischiadicum*;
 4 - *m. ischiocavernosus*;
 5 - *m. bulbospongiosus*;
 6 - *m. transversus perinei profundus*;
 7 - *m. sphincter ani externus*;
 8 - *m. levator ani*;
 9 - *lig. anococcygeum*;
 10 - *m. coccygeus*;
 11 - *os coccygis*;
 12 - *anus*.

MUȘCHII PERINEULUI LA FEMEIE
(după H.V. Крылов, 1986)
МЫШЦЫ ЖЕНСКОЙ ПРОМЕЖНОСТИ
MUSCLES OF THE FEMALE PERINEUM



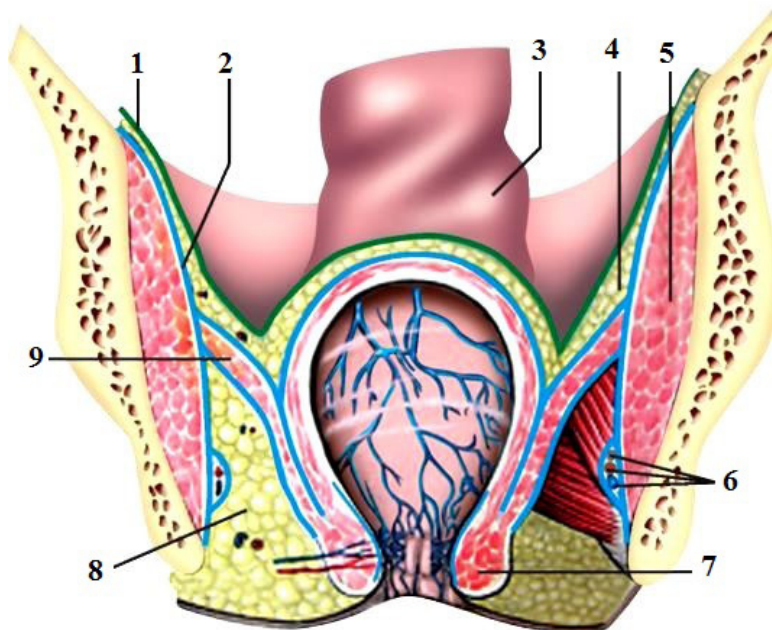
- | | |
|---|--|
| 1 - <i>glans clitoridis</i> ; | 9 - <i>m. bulbospongiosus</i> ; |
| 2 - <i>ostium urethrae externum</i> ; | 10 - <i>m. transversus perinei profundus</i> ; |
| 3 - <i>ostium vaginae</i> ; | 11 - <i>m. sphincter urethrae externus</i> ; |
| 4 - <i>anus</i> ; | 12 - <i>m. sphincter ani externus</i> ; |
| 5 - <i>os coccygis</i> ; | 13 - <i>m. levator ani</i> ; |
| 6 - <i>m. transversus perinei superficialis</i> ; | 14 - <i>lig. anococcygeum</i> ; |
| 7 - <i>centrum perinei</i> ; | 15 - <i>m. coccygeus</i> ; |
| 8 - <i>m. ischiocavernosus</i> ; | 16 - <i>tuber ischiadicum</i> . |

**PERINEUL OBSTETRICAL
АКУШЕРСКАЯ ПРОМЕЖНОСТЬ
OBSTETRICAL PERINEUM**



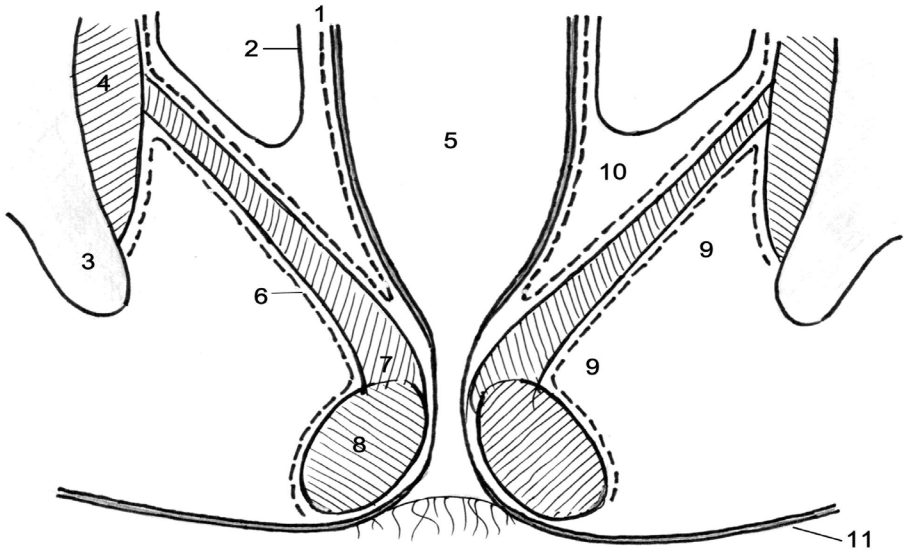
- 1 – mons pubis;*
- 2 – glans clitoridis;*
- 3 – ostium urethrae externum;*
- 4 – ostium vaginae;*
- 5 – commissura labiorum posterior;*
- 6 – raphe perinei;*
- 7 – anus;*
- 8 – commissura labiorum anterior;*
- 9 – labium majus pudendi;*
- 10 – labium minus pudendi;*
- 11 – vestibulum vaginae;*
- 12 – perineum obstetricum.*

SECȚIUNE FRONTALĂ PRIN BAZINUL MIC.
 FOSELE ISCHIORECTALE
 (după A. B. Николаев, 2009)
 ФРОНТАЛЬНЫЙ СРЕЗ МАЛОГО ТАЗА.
 СЕДАЛИЩНО-АНАЛЬНЫЕ ЯМКИ
 FRONTAL SECTION THROUGH THE LESSER PELVIS. THE
 ISCHIORECTAL FOSSAE



- 1 – peritoneum;
 2 – fascia obturatoria;
 3 – rectum;
 4 – cavum pelvis subperitoneale;
 5 – m. obturatorius internus;
 6 – canalis pudendalis (Alcock), a., v. pudenda interna, n. pudendus;
 7 – m. sphincter ani externus;
 8 – fossa ischioanalis;
 9 – m. levator ani.

FASCIILE ȘI SPAȚIILE CELULOADIPOASE ALE PELVISULUI
 ФАСЦИИ И КЛЕТЧАТОЧНЫЕ ПРОСТРАНСТВА ТАЗА
 FASCIAE AND ADIPOSE SPACES OF THE PELVIS



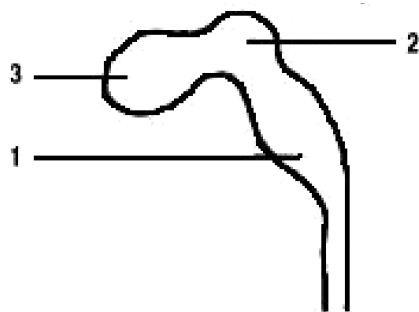
- 1 - fascia diaphragmatis pelvis superior;
- 2 - peritoneum;
- 3 - os coxae;
- 4 - m. obturatorius internus;
- 5 - ampulla recti;
- 6 - fascia diaphragmatis pelvis inferior;
- 7 - m. levator ani;
- 8 - m. sphincter ani externus;
- 9 - fossa ischioanalis;
- 10 - spatium pelvisubperitoneale;
- 11 - cutis.

MODIFICĂRILE EXTREMITĂȚII CEFALICE A TUBULUI NEURAL

(după H.V. Крылова, И.А. Искренко, 1986)

ИЗМЕНЕНИЯ ГОЛОВНОГО ОТДЕЛА МОЗГОВОЙ ТРУБКИ

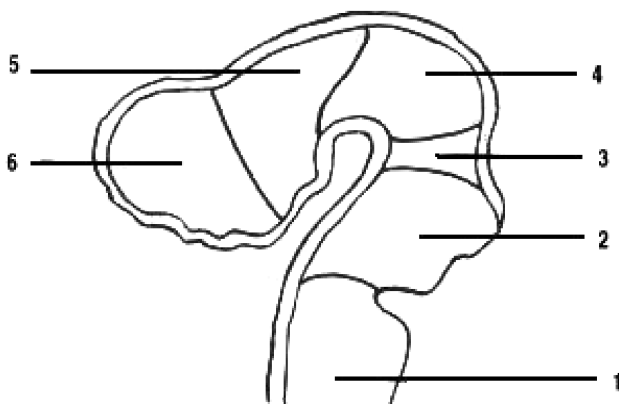
MODIFICATIONS OF THE CERHALIC END OF THE NEURAL TUBE



1 - rhombencephalon;

2 - mesencephalon;

3 - prosencephalon.



1 - myelencephalon;

2 - metencephalon (pons et cerebellum);

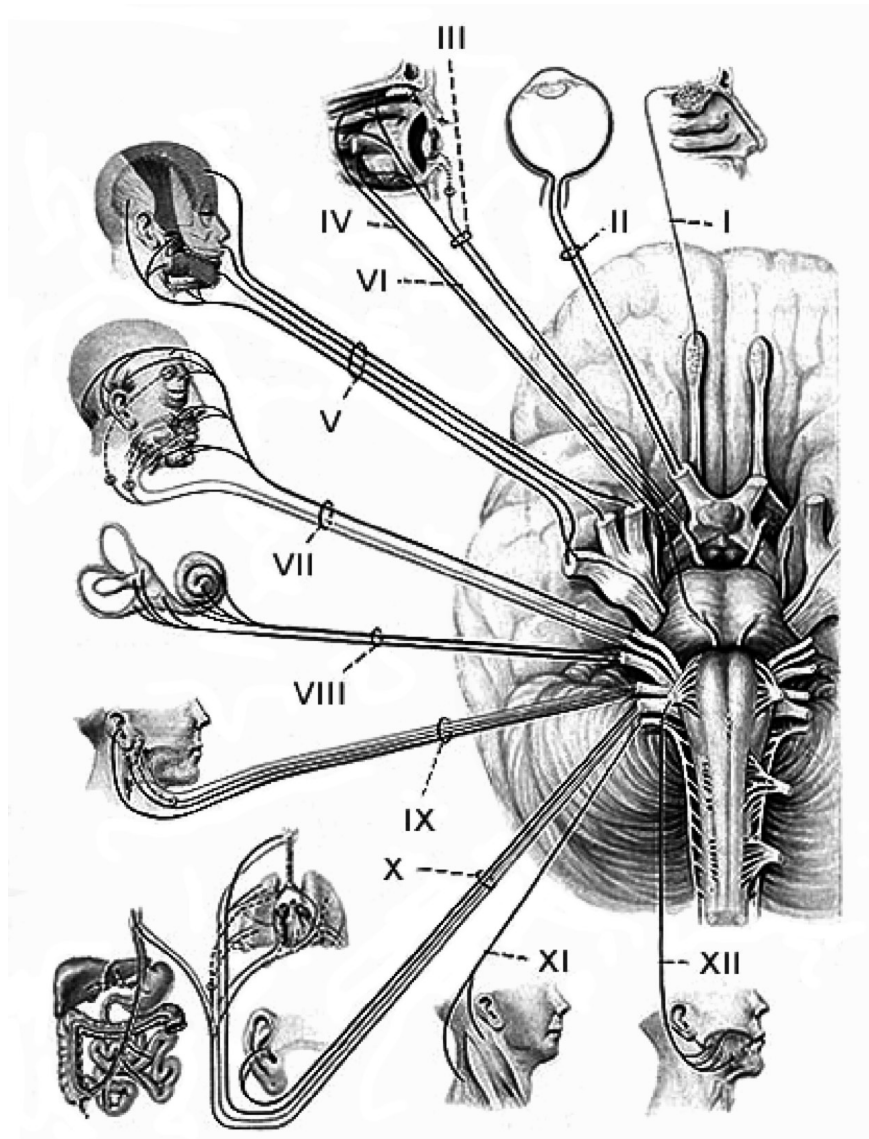
3 - isthmus rhombencephali;

4 - mesencephalon;

5 - diencephalon;

6 - telencephalon.

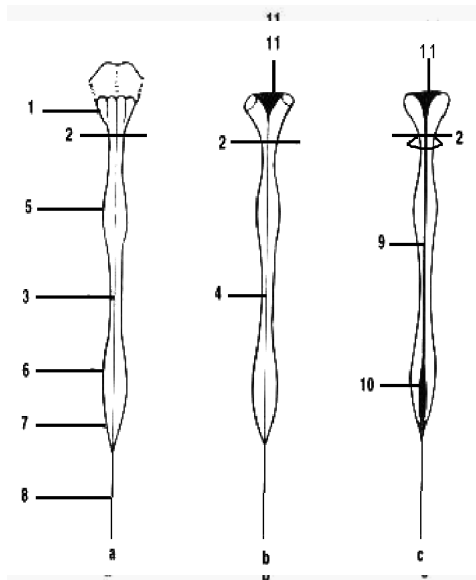
NERVII CRANIENI. DISTRIBUȚIE PERIFERICĂ
ЧЕРЕПНО-МОЗГОВЫЕ НЕРВЫ.
ПЕРИФЕРИЧЕСКОЕ РАСПРЕДЕЛЕНИЕ
PERIPHERAL DISTRIBUTION OF THE CRANIAL NERVES



NERVII CRANIENI.
APARIȚIA DIN ENCEFAL ȘI DIN CAVITATEA CRANIULUI
ЧЕРЕПНО-МОЗГОВЫЕ НЕРВЫ.
ВЫХОД ИЗ МОЗГА И ИЗ ПОЛОСТИ ЧЕРЕПА
CRANIAL NERVES. APPEARANCE FROM THE BRAIN
AND OUTLET OF THE SKULL

	<i>NN. CRANIALES</i>	<i>ENCEPHALON</i>	<i>CRANIUM</i>
I.	<i>N. olfactorius</i> (<i>fila olfactoria</i>)	Bulbus olfactorius	Foramina cribrosa ossis ethmoidalis
II.	<i>N. opticus</i>	Chiasma opticum	Canalis opticus
III.	<i>N. oculomotorius</i>	Fossa interpeduncularis (sulcus nervi oculomotorii)	Fissura orbitalis superior
IV.	<i>N. trochlearis</i>	Velum medullare superius (pars dorsalis trunci cerebri)	Fissura orbitalis superior
V.	<i>N. trigeminus</i>	Pars lateroanterior pontis	<i>N. ophthalmicus</i> – fissura orbitalis sup. <i>N. maxillaris</i> – foramen rotundum <i>N. mandibularis</i> – foramen ovale
VI.	<i>N. abducens</i>	Sulcus bulbopontinus (basis pyramidis bulbi)	Fissura orbitalis superior
VII.	<i>N. facialis</i>	Pars lateroposterior pontis	Canalis n. facialis (Fallopil)
VIII.	<i>N. vestibulocochlearis</i>	Sulcus bulbopontinus	Porus acusticus internus
IX.	<i>N. glossopharyngeus</i>	Sulcus posterolateralis/ retroolivaris (medullae oblongatae)	Foramen jugulare
X.	<i>N. vagus</i>	Sulcus posterolateralis/ retroolivaris (medullae oblongatae)	Foramen jugulare
XI.	<i>N. accessorius</i>	Sulcus posterolateralis/ retroolivaris (medullae oblongatae)	Foramen jugulare
XII.	<i>N. hypoglossus</i>	Sulcus anterolateralis/ preolivaris (medullae oblongatae)	Canalis nervi hypoglossi

CONFORMAȚIA EXTERNĂ A MĂDUVEI SPINĂRII
 НАРУЖНОЕ СТРОЕНИЕ СПИННОГО МОЗГА
 EXTERNAL STRUCTURE OF THE SPINAL CORD



a – facies anterior;
 b – facies posterior;
 c – sectio frontalis.

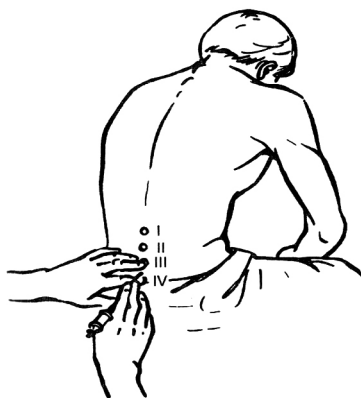- 1 – medulla oblongata (myelencephalon, bulbus);
- 2 – foramen magnum;
- 3 – fissura mediana anterior;
- 4 – sulcus medianus posterior;
- 5 – intumescencia cervicalis (C2 – Th2);
- 6 – intumescencia lumbosacralis (Th10 – conus medullaris);
- 7 – conus medullaris;
- 8 – filum terminale (pars spinalis);
- 9 – canalis centralis;
- 10 – ventriculus terminalis;
- 11 – ventriculus quartus (IV).

STABILIREA PUNCTULUI PENTRU PUNCȚIA LOMBARĂ

(după B.K. Гостинцев, 2003)

ОПРЕДЕЛЕНИЕ МЕСТА СПИННОМОЗГОВОЙ ПУНКЦИИ

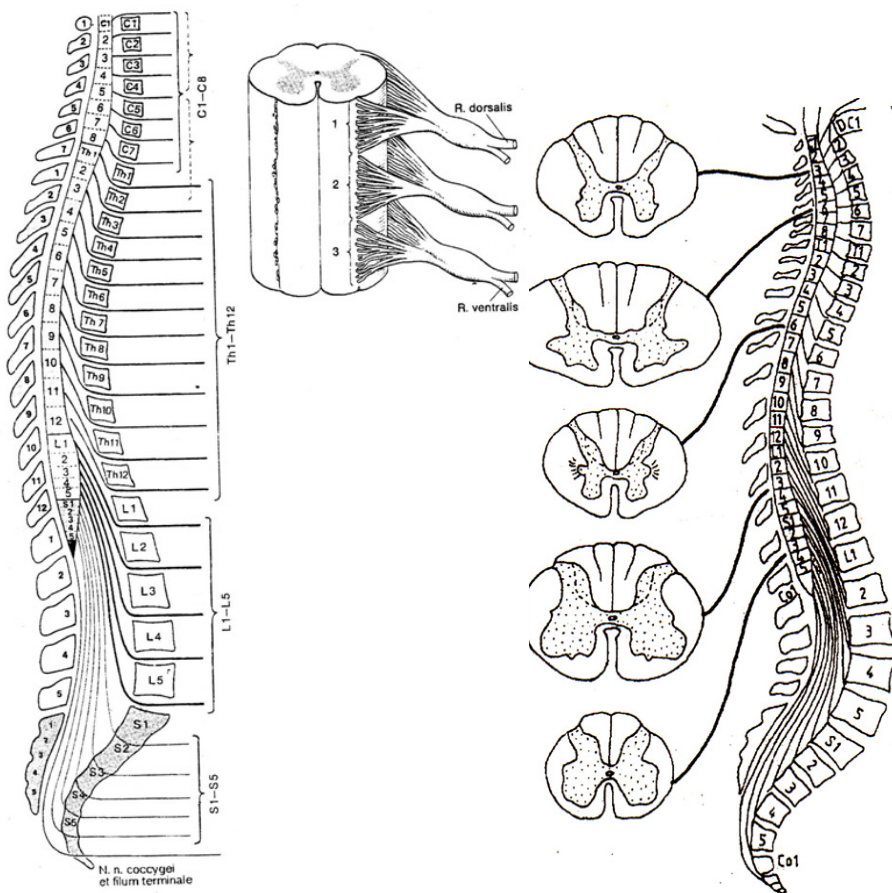
DETERMINATION OF SPINAL CANAL PUNCTURE



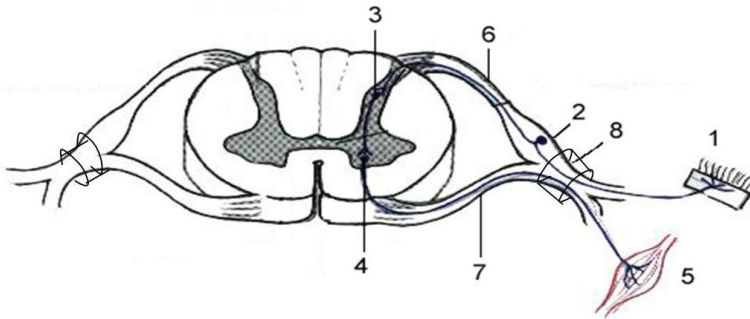
**RAPORTURILE SEGMENTELOR MĂDUVEI SPINĂRII CU
RĂDĂCINILE NERVILOR SPINALI ȘI CORPURILE VERTEBRELOR.
VARIAȚII REGIONALE ALE SUBSTANȚEI CENUȘII ȘI ALBE DE-A
LUNGUL MĂDUVEI SPINĂRII**

**СООТНОШЕНИЕ СЕГМЕНТОВ СПИННОГО МОЗГА С ВЫХОДЯЩИМИ
ИЗ НИХ КОРЕШКАМИ И ТЕЛАМИ ПОЗВОНКОВ. РЕГИОНАЛЬНЫЕ
ВЗАИМООТНОШЕНИЯ МЕЖДУ БЕЛЫМ И СЕРЫМ ВЕЩЕСТВОМ НА
ПРОТЯЖЕНИИ СПИННОГО МОЗГА**

**CORRELATIONS BETWEEN THE SEGMENTS OF THE SPINAL CORD
WITH THE ROOTS OF THE SPINAL NERVES AND THE BODIES OF THE
VERTEBRAE. REGIONAL INTERRELATIONS BETWEEN THE WHITE
AND GREY MATER OF THE SPINAL CORD**

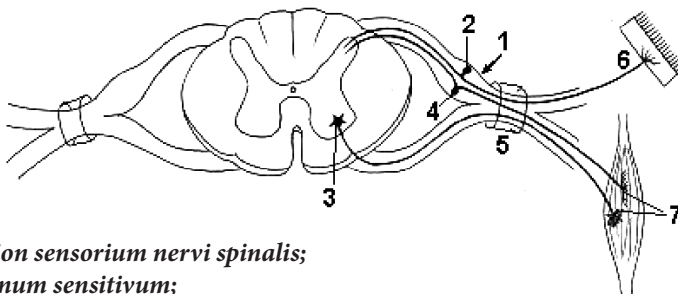


**ARCUL REFLEX SIMPLU ȘI FORMAREA NERVULUI SPINAL
 ПРОСТАЯ (ТРЕХНЕЙРОННАЯ) РЕФЛЕКТОРНАЯ ДУГА
 И ОБРАЗОВАНИЕ СПИНОМОЗГОВОГО НЕРВА
 SIMPLE REFLEX ARC AND FORMATION OF THE SPINAL NERVE**



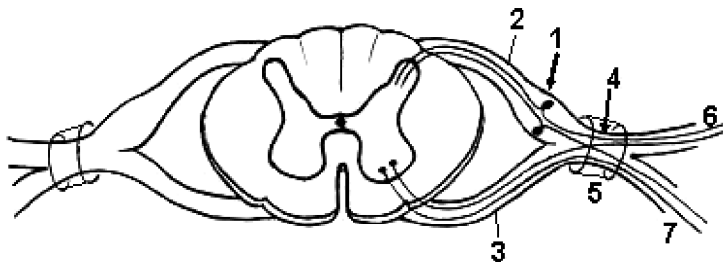
- 1 – receptor cutis;
- 2 – ganglion sensorium nervi spinalis (neuronum pseudounipolare) (neuronum I);
- 3 – neuronum sensitivum, associationis (cornu posterius) (neuronum II);
- 4 – neuronum motorium (cornu anterius) (neuronum III);
- 5 – musculus striatus;
- 6 – radix posterior (radix sensoria);
- 7 – radix anterior (radix motoria);
- 8 – truncus nervis spinalis.

**SCHEMA ARCULUI REFLEX SIMPLU CU LEGĂTURĂ INVERSĂ
 СХЕМА ПРОСТОЙ РЕФЛЕКТОРНОЙ ДУГИ С ОБРАТНОЙ СВЯЗЬЮ
 THE SCHEME OF THE SIMPLE REFLEX ARC WITH FEEDBACK LOOP**



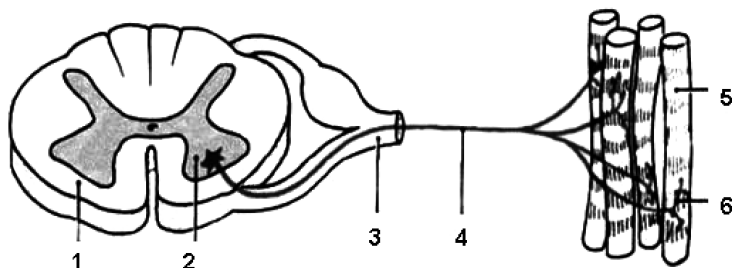
- 1 – ganglion sensorium nervi spinalis;
- 2 – neuronum sensitivum;
- 3 – neuronum motorium;
- 4 – neuronum cum conexione praepostera (feedback);
- 5 – foramen intervertebrale;
- 6 – receptor cutis;
- 7 – receptor et effector musculorum.

SCHEMA FORMĂRII NERVULUI SPINAL
СХЕМА ФОРМИРОВАНИЯ СПИНОМОЗГОВОГО НЕРВА
THE SCHEME OF THE FORMATION OF THE SPINAL NERVE



- 1 - *ganglion sensorium nervi spinalis*;
- 2 - *radix posterior*;
- 3 - *radix anterior*;
- 4 - *truncus nervi spinalis*;
- 5 - *foramen intervertebrale*;
- 6 - *ramus posterior*;
- 7 - *ramus anterior*.

SCHEMA UNITĂȚII NEUROMOTORII (MIONULUI)
СХЕМА НЕРВНОДВИГАТЕЛЬНОЙ ЕДИНИЦЫ (МИОНА)
DIAGRAM OF THE NEUROMOTOR UNIT (MION)



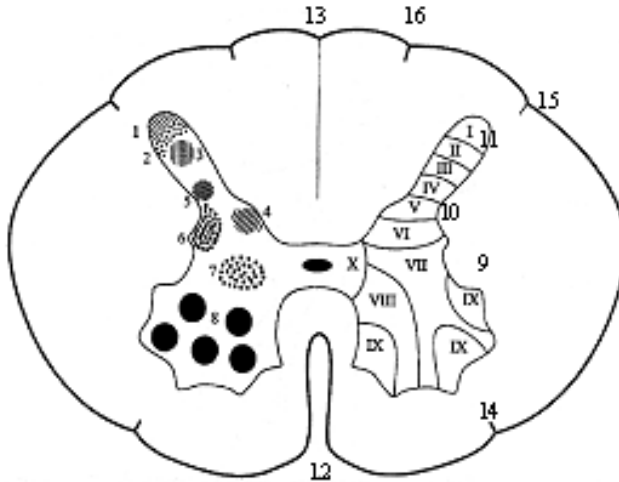
- 1 - *funiculus anterior*;
- 2 - *nuclei motorii (corpus neuroni, pericaryon)*;
- 3 - *nervus spinalis*;
- 4 - *neurofibrae motoricae*;
- 5 - *fibrae musculares*;
- 6 - *terminationes nervorum*.

NUCLEELE ȘI STRUCTURA LAMINARĂ A SUBSTANȚEI CENUȘII
A MĂDUVEI SPINĂRII

(după F. G. Sido, 2004)

ЯДРА И ПЛАСТИНЧАТАЯ СТРУКТУРА СЕРОГО ВЕЩЕСТВА
СПИННОГО МОЗГА

NUCLEI OF THE GREY MATTER OF THE SPINAL CORD



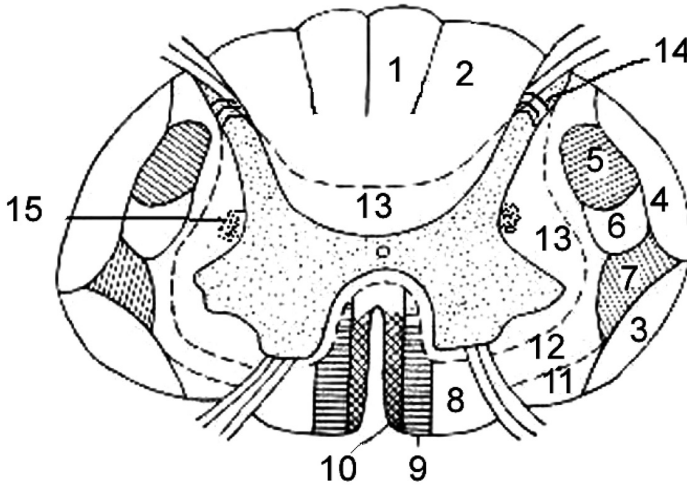
- 1 – nucleus marginalis;
 2 – substantia gelatinosa (Rolando);
 3 – nucleus proprius;
 4 – nucleus thoracicus (T_1 - L_3) (Clarke-Stilling);
 5 – nucleus lateralis (Бехмев);
 6 – nucleus intermediolateralis (C_8 , T_{1-12} , L_{1-3}) (Бехмев);
 7 – substantia intermedia centralis;
 8 – nuclei motorii;
 9 – cornu anterius;
 10 – cornu laterale (C_8 , T_{1-12} , L_{1-3});
 11 – cornu posterius;
 12 – fissura mediana anterior;
 13 – sulcus medianus posterior;
 14 – sulcus anterolateralis;
 15 – sulcus posterolateralis;
 16 – sulcus intermedius posterior.
 I-X – laminae spiniales.

CĂILE DE CONDUCERE ALE MĂDUVEI SPINĂRII

(după H.V. Крылова, И.А. Искренко, 1986)

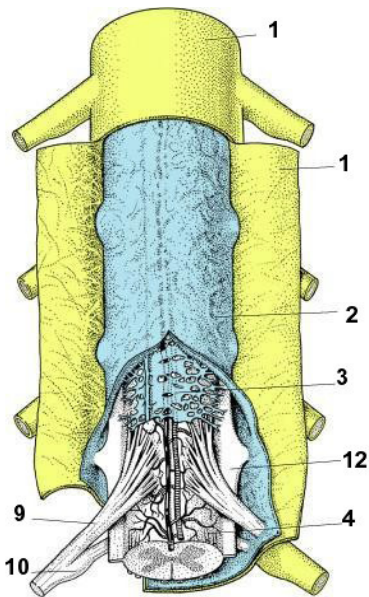
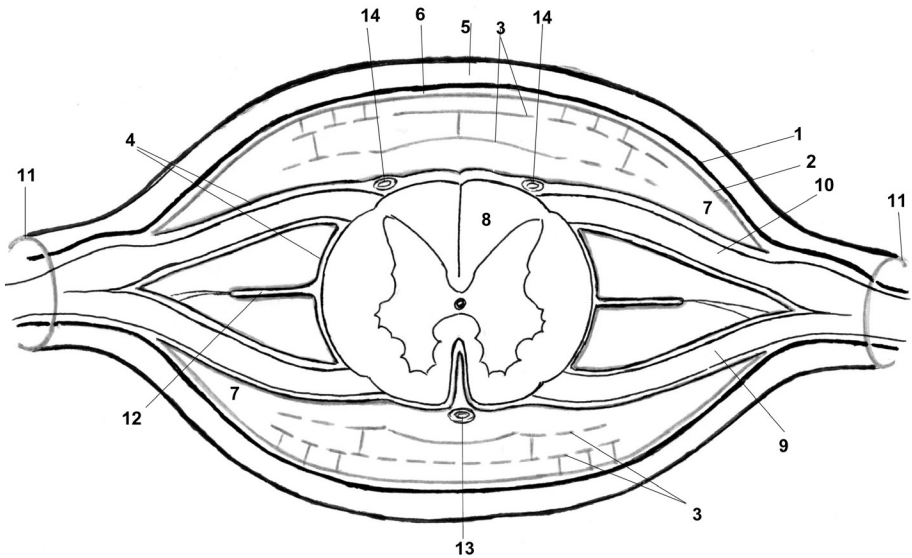
ПРОВОДЯЩИЕ ПУТИ СПИННОГО МОЗГА

PATHWAYS OF THE SPINAL CORD



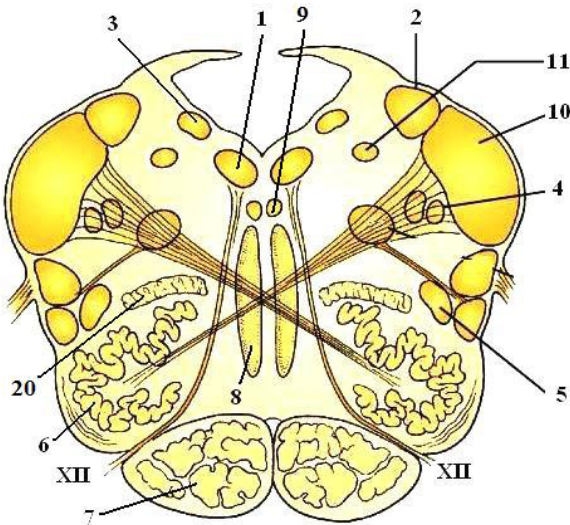
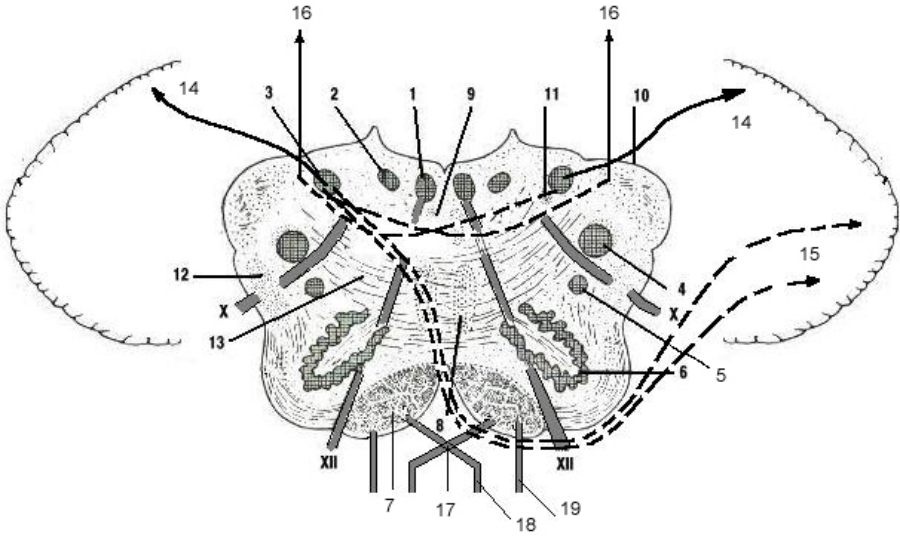
- 1 - *fasciculus gracilis* (Goll);
- 2 - *fasciculus cuneatus* (Burdach);
- 3 - *tractus spinocerebellaris anterior* (Gowers);
- 4 - *tractus spinocerebellaris posterior* (Flechsig);
- 5 - *tractus corticospinalis lateralis*;
- 6 - *tractus rubrospinalis* (Monakow);
- 7 - *tractus spinothalamicus lateralis*;
- 8 - *tractus spinothalamicus anterior*;
- 9 - *tractus corticospinalis anterior*;
- 10 - *tractus tectospinalis*;
- 11 - *tractus vestibulospinalis*;
- 12 - *fibrae reticulospinales*;
- 13 - *fasciculi proprii*;
- 14 - *substantia gelatinosa* (Rolando);
- 15 - *formatio reticularis*.

MENINGELE RAHIDIAN
ОБОЛОЧКИ СПИННОГО МОЗГА
MENINGES OF SPINAL CORD



- 1 - *dura mater spinalis*;
- 2 - *arachnoidea mater spinalis*;
- 3 - *lamellae intermediae arachnoideae*;
- 4 - *pia mater spinalis*;
- 5 - *spatium epidurale (extradurale)*;
- 6 - *spatium subdurale*;
- 7 - *spatium subarachnoideum*;
- 8 - *medulla spinalis*;
- 9 - *radix anterior*;
- 10 - *radix posterior*;
- 11 - *foramen intervertebrale*;
- 12 - *ligamentum denticulatum*;
- 13 - *a. spinalis anterior*;
- 14 - *aa. spinales posteriores*.

**SCHEMA UNEI SECȚIUNI TRANSVERSALE
PRIN BULBUL RAHIDIAN
СХЕМА ПОПЕРЕЧНОГО СЕЧЕНИЯ ПРОДОЛГОВАТОГО МОЗГА
DIAGRAM OF THE TRANSVERSAL SECTION THROUGH
THE MEDULLA OBLONGATA**

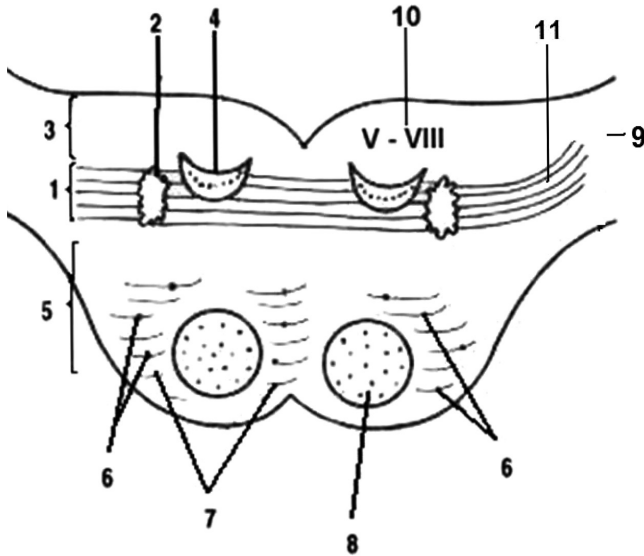


- 1 – *nucleus nervi hypoglossi (XII)*;
- 2 – *nucleus posterior (dorsalis) nervi vagi (X)*;
- 3 – *nucleus cuneatus*;
- 4 – *nucleus spinalis n. trigemini (V)*;
- 5 – *nucleus ambiguus (IX, X, XI)*;
- 6 – *nuclei olivares inferiores (complexus olivaris inferior)*;
- 7 – *tractus pyramidalis*;
- 8 – *decussatio lemnisci medialis et lemniscus medialis*;
- 9 – *fasciculus longitudinalis medialis*;
- 10 – *pedunculus cerebellaris inferior*;
- 11 – *tractus solitarius*;
- 12 – *tractus rubrospinalis, tectospinalis et spinocerebellaris anterior*;
- 13 – *fibrae arcuatae internae*;
- 14 – *fibrae arcuatae externae posteriores*;
- 15 – *fibrae arcuatae externae anteriores*;
- 16 – *fibrae bulbothalamicae*;
- 17 – *decussatio pyramidum*;
- 18 – *tractus corticospinalis lateralis*;
- 19 – *tractus corticospinalis anterior*;
- 20 – *nucleus olivaris accessorius posterior*.

X – *n. vagus*;

XII – *n. hypoglossus*.

STRUCTURA INTERNĂ A PUNȚII (SECȚIUNE FRONTALĂ)
ВНУТРЕННЕЕ СТРОЕНИЕ МОСТА НА ФРОНТАЛЬНОМ РАЗРЕЗЕ
INTERNAL STRUCTURE OF THE PONS (FRONTAL SECTION)



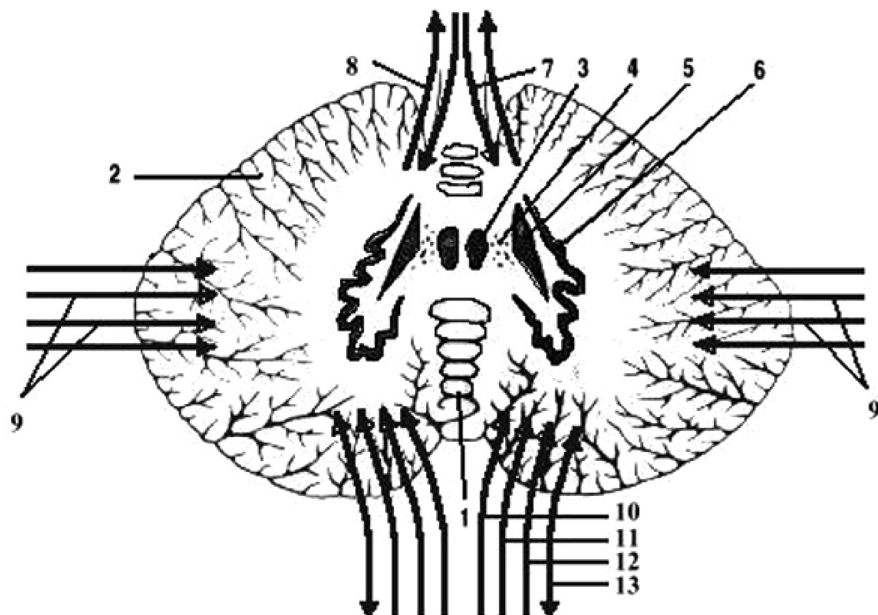
- 1 – *corpus trapezoideum*;
- 2 – *nucleus olivarius superior*;
- 3 – *tegmentum pontis*;
- 4 – *lemniscus medialis*;
- 5 – *pars basilaris pontis*;
- 6 – *nuclei pontis*;
- 7 – *fibrae pontis transversae*;
- 8 – *tractus pyramidalis*;
- 9 – *pedunculus cerebellaris medius*;
- 10 – *nuclei nn. V – VIII*;
- 11 – *lemniscus lateralis*.

NUCLEELE CEREBELULUI ȘI COMPONENTELE
PEDUNCULILOR CEREBELOȘI

(modificată după Н.В. Крылова, И.А. Искренко, 1986)

ЯДРА МОЗЖЕЧКА И ПРОВОДЯЩИЕ ПУТИ МОЗЖЕЧКОВЫХ НОЖЕК

NUCLEI OF THE CEREBELLUM AND PATHWAYS
OF THE CEREBELLAR PEDUNCLES



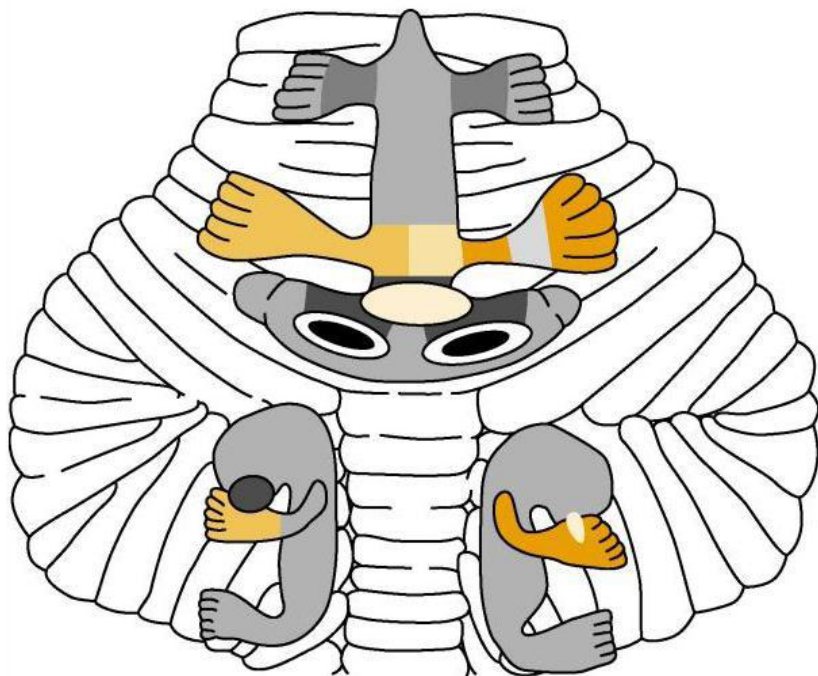
- 1 - vermis cerebelli;
- 2 - hemispherium cerebelli;
- 3 - nucleus fastigii (nucleus medialis cerebelli);
- 4 - nucleus globosus;
- 5 - nucleus emboliformis;
- 6 - nucleus dentatus (nucleus lateralis cerebelli);
- 7 - tractus spinocerebellaris anterior (Gowers);
- 8 - tr. cerebellotegmentalis;
- 9 - tractus pontocerebellaris;
- 10 - tractus spinocerebellaris posterior (Flechsig);
- 11 - fibrae arcuatae externae;
- 12 - tractus olivocerebellaris;
- 13 - tr. vestibulocerebellaris/cerebellovestibularis.

**LOCALIZAREA SOMATOTOPICĂ ÎN CORTEXUL CEREBELAR.
HOMUNCULUSUL CEREBELAR**

(dupa Grodd et al., 2001)

**СОМАТОТОПИЧЕСКАЯ ЛОКАЛИЗАЦИЯ В КОРЕ МОЗЖЕЧКА.
МОЗЖЕЧКОВЫЙ ГОМУНКУЛУС**

**SOMATOTOPIC LOCALIZATION OF THE CEREBELLAR CORTEX.
THE CEREBELLAR HOMUNCULUS**

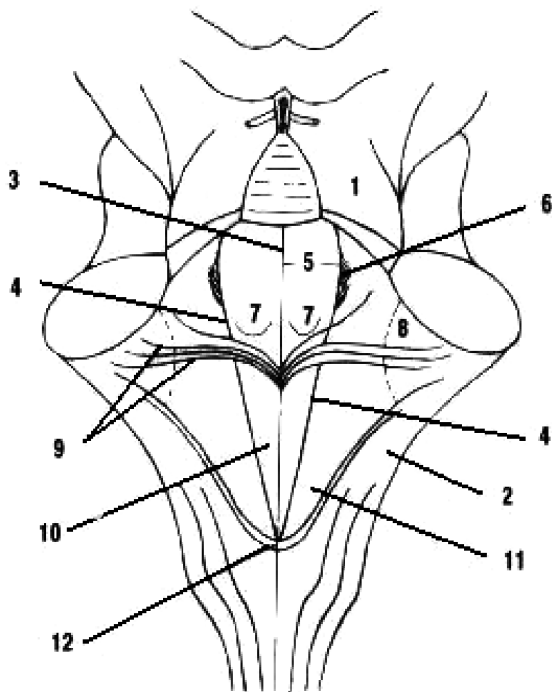


RELIEFUL FOSEI ROMBOIDE

(dură H.V. Крылова, И.А. Искренко, 1986)

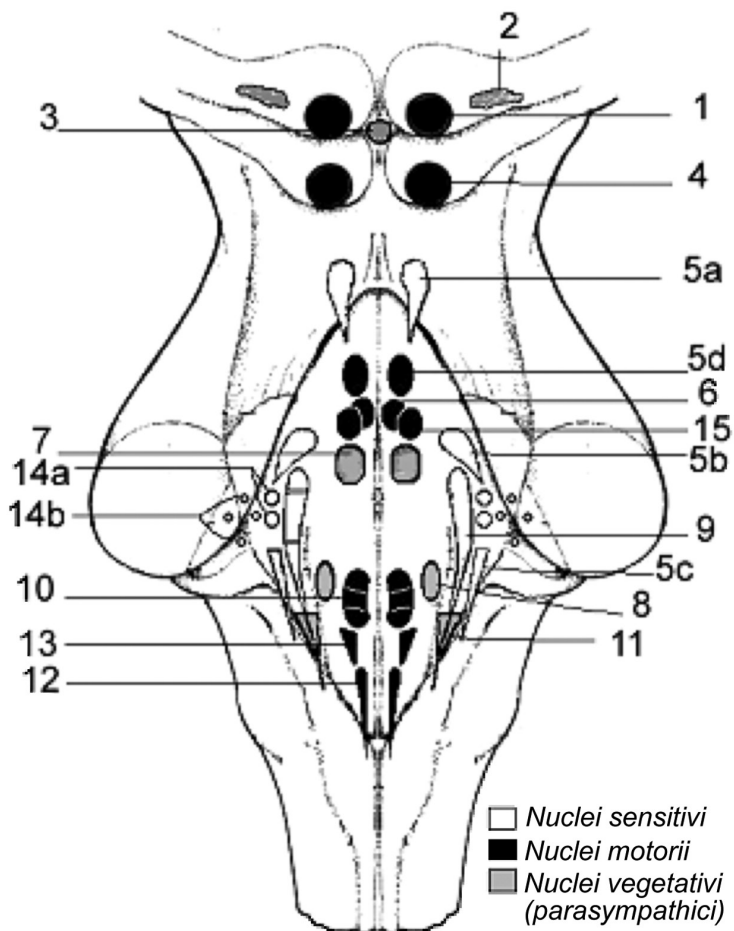
РЕЛЬЕФ РОМБОВИДНОЙ ЯМКИ

RELIEF OF THE RHOMBOID FOSSA



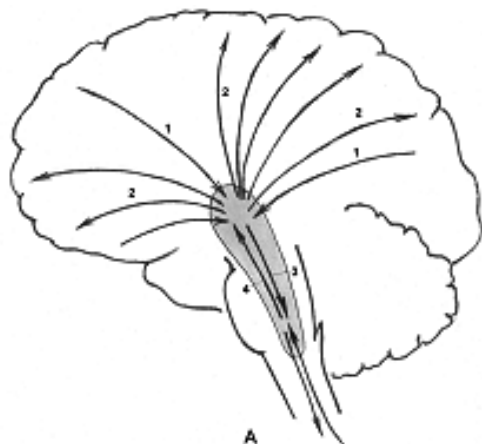
- 1 – *pedunculus cerebellaris superior*;
- 2 – *pedunculus cerebellaris inferior*;
- 3 – *sulcus medianus*;
- 4 – *sulcus limitans*;
- 5 – *eminentia medialis*;
- 6 – *locus coeruleus*;
- 7 – *colliculus facialis*;
- 8 – *area vestibularis*;
- 9 – *striae medullares ventriculi quarti*;
- 10 – *trigonum nervi hypoglossi*;
- 11 – *trigonum nervi vagi (trigonum vagale)*;
- 12 – *obex*.

PROIEȚIA NUCLEELOR NERVILOR CRANIENI PE FAȚA
 DORSALĂ A TRUNCHIULUI CEREBRAL (FOSA ROMBOIDĂ)
 ПРОЕКЦИЯ ЯДЕР ЧЕРЕПНЫХ НЕРВОВ НА ДОРСАЛЬНУЮ
 ПОВЕРХНОСТЬ СТВОЛА МОЗГА (РОМБОВИДНАЯ ЯМКА)
 PROJECTION OF THE NUCLEI OF THE CRANIAL NERVES ON THE
 DORSAL SURFACE OF THE BRAIN STEM (THE ROMBOID FOSSA)

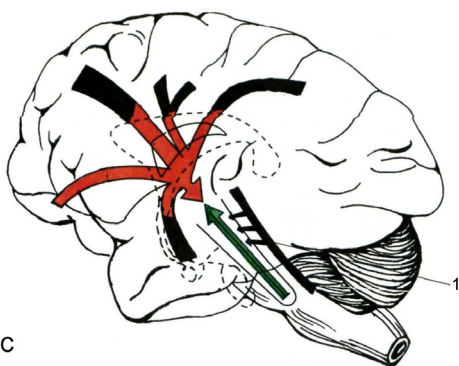


- 1 – *nucl. n. oculomotorii* (III);
- 2 – *nucll. accessorii nervi oculomotorii* (Якубович- Westphal-Edinger) (III);
- 3 – *nucl. anteromedialis (impar)* (Perl) (III) – *somatovegetativus*;
- 4 – *nucl. n. trochlearis* (IV);
- 5a – *nucl. mesencephalicus n. trigemini* (V);
- 5b – *nucl. pontinus (nucl. principalis n. trigemini)*;
- 5c – *nucl. spinalis n. trigemini*;
- 5d – *nucl. motorius n. trigemini*;
- 6 – *nucl. n. abducentis* (VI);
- 7 – *nucl. salivatorius superior* (VII);
- 8 – *nucl. salivatorius inferior* (IX);
- 9 – *nucll. tractus solitarii* (VII,IX,X);
- 10 – *nucl. ambiguus* [IX, X, XI (*pars cranialis*)];
- 11 – *nucl. posterior (dorsalis) n. vagi* (X);
- 12 – *nucl. n. accessorii* (XI);
- 13 – *nucl. n. hypoglossi* (XII);
- 14 a – *nervus cochlearis* (VIII)
(*nucll. cochleares posterior et anterior*);
- 14 b – *nervus vestibularis* (VIII)
[*nucll. vestibulares: superior* (Бехмевес), *inferior* (Roller),
lateralis (Deiters), *medialis* (Schwalbe)];
- 15 – *nucl. n. facialis* (VII).

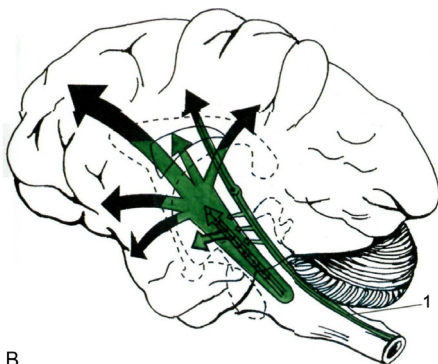
CONEXIUNILE FORMAȚIUNII RETICULARE
 СВЯЗИ РЕТИКУЛЯРНОЙ ФОРМАЦИИ
 CONNECTIONS OF THE RETICULAR FORMATION



A



C



B

A

1 - tr. corticoreticulares;

2 - tr. reticulocorticales;

3 - tr. reticulospinales;

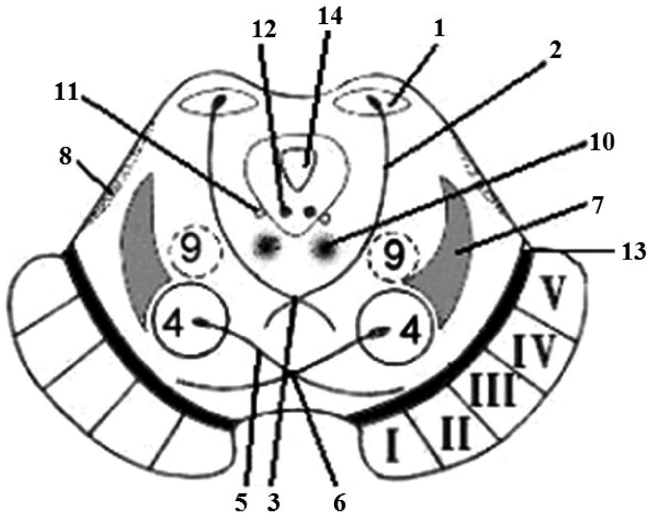
4 - tr. spinoreticulares.

B - tr. reticulocorticales (apud Г. Мэзун);

C - tr. corticoreticulares (apud Г. Мэзун);

1 - conexiones tractuum afferentium cum formatione reticulari.

STRUCTURA INTERNĂ A MEZENCEFALULUI
 ВНУТРЕННЕЕ СТРОЕНИЕ СРЕДНЕГО МОЗГА
 INTERNAL STRUCTURE OF THE MIDBRAIN



- 1 - *nuclei colliculi inferioris*;
 2 - *tractus tectospinalis*;
 3 - *decussatio tegmentalis posterior*
 (Meynert);
 4 - *nucleus ruber*;
 5 - *tractus rubrospinalis* (Monakow);
 6 - *decussatio tegmentalis anterior*
 (Forel);
 7 - *lemniscus medialis*;
 8 - *lemniscus lateralis*;
 9 - *formatio reticularis*;
 10 - *fasciculus longitudinalis medialis*;
 11 - *nucleus mesencephalicus nervi*
trigemini (V);
 12 - *nucleus nervi trochlearis* (IV);
 13 - *substantia nigra* (Söemmering);
 14 - *aqueductus mesencephali* (cerebri)
 (Sylvius).

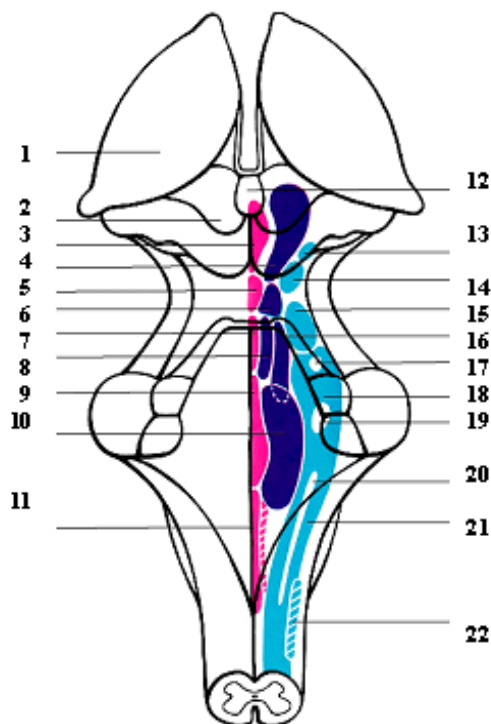
- I - *tractus corticopontinus*
 (*fibrae frontopontinae*);
 II - *tractus pyramidalis*
 (*fibrae corticonucleares*);
 III - *tractus pyramidalis*
 (*fibrae corticospinales laterales*);
 IV - *tractus pyramidalis*
 (*fibrae corticospinales anteriores*);
 V - *tractus corticopontinus*
 (*fibrae occipitotemporopontinae*).

NUCLEELE FORMAȚIUNII RETICULARE

(după Gray)

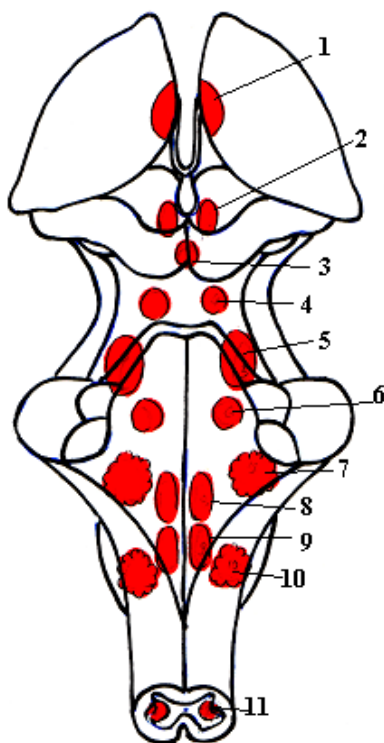
ЯДРА РЕТИКУЛЯРНОЙ ФОРМАЦИИ

NUCLEI OF THE RETICULAR FORMATION



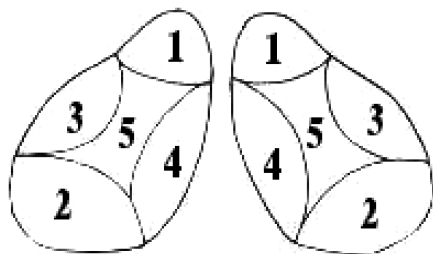
- | | |
|---|---|
| 1 – thalamus; | 13 – nucleus tegmentalis pedunculo-pontinus; |
| 2 – colliculus superior; | 14 – nucleus parabrachialis lateralis; |
| 3 – nucleus raphes posterior; | 15 – nucleus parabrachialis medialis; |
| 4 – nuclei cuneiformis et subcuneiformis; | 16 – nucleus reticularis pontis caudalis; |
| 5 – nucleus centralis superior; | 17 – nucleus motorius nervi trigemini; |
| 6 – nucleus reticularis pontis; | 18 – nucleus pontinus centralis; |
| 7 – raphe (pontis); | 19 – nucleus n. facialis; |
| 8 – nucleus reticularis tegmenti pontis (Бехмецев); | 20 – nucleus ambiguus; |
| 9 – nucleus raphes magnus; | 21 – nucleus reticularis centralis (medullae oblongatae); |
| 10 – nucleus gigantocellularis; | 22 – nucleus reticularis lateralis (medullae oblongatae). |
| 11 – nucleus raphes obscurus et pallidus; | |

NUCLEELE FORMAȚIUNII RETICULARE
 ЯДРА РЕТИКУЛЯРНОЙ ФОРМАЦИИ
 NUCLEI OF THE RETICULAR FORMATION



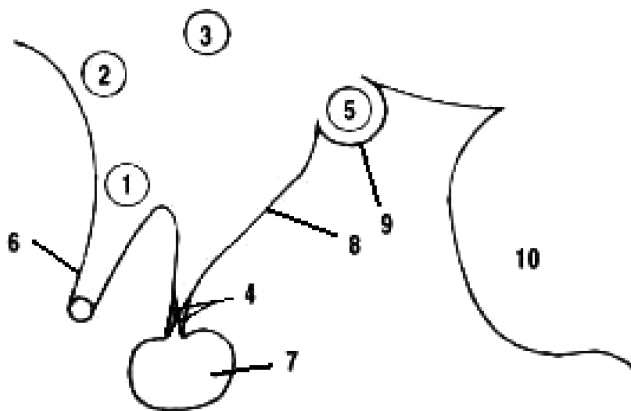
- 1 – *nucleus reticularis thalami* (Бурденко);
 2 – *substantia grisea centralis*;
 3 – *nucleus reticularis impar mesencephali*;
 4 – *nucleus reticularis pontis rostralis*;
 5 – *nucleus reticularis tegmenti pontis*;
 6 – *nucleus reticularis pontis caudalis*;
 7 – *nucleus gigantocellularis*;
 8 – *nucleus reticularis centralis (pars ventralis)*;
 9 – *nucleus reticularis centralis (pars dorsalis)*;
 10 – *nucleus reticularis parvocellularis*;
 11 – *formatio reticularis spinalis*.

ТОПОГРАФИЯ НУКЛЕЕЛОР ТАЛАМУСУЛUI
ТОПОГРАФИЯ ЯДЕР ЗРИТЕЛЬНОГО БУТРА
TOPOGRAPHY OF THE THALAMIC NUCLEI



- 1 - *nuclei anteriores thalami (olfactorii)*;
- 2 - *nuclei dorsales thalami (optici)*;
- 3 - *nuclei laterales thalami (sensus generalis)*;
- 4 - *nuclei mediales thalami (systema extrapyramidale)*;
- 5 - *nuclei intralaminares thalami (formatio reticularis)*.

NUCLEELE NEUROSECRETORARE ALE HIPOTALAMUSULUI
НЕЙРОСЕКРЕТОРНЫЕ ЯДРА ПОДБУГОРНОЙ
(ПОДТАЛАМИЧЕСКОЙ) ОБЛАСТИ
NEUROSECRETORY NUCLEI OF THE HYPOTHALAMUS

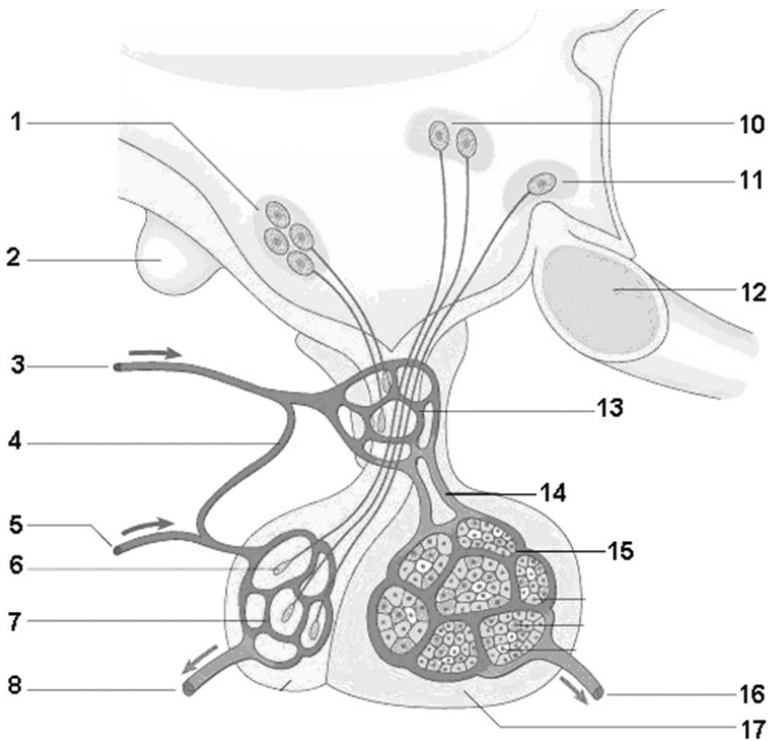


- 1 - *nucleus supraopticus*;
- 2 - *nucleus preopticus*;
- 3 - *nucleus paraventricularis hypothalami*;
- 4 - *nucleus infundibularis*;
- 5 - *nuclei corporis mammillaris*;
- 6 - *chiasma opticum*;
- 7 - *hypophysis (glandula pituitaria)*;
- 8 - *tuber cinereum*;
- 9 - *corpus mammillare*;
- 10 - *pons (Varolio)*.

SISTEMUL PORTAL HIPOTALAMOHIPOFIZAR

(după Gray)

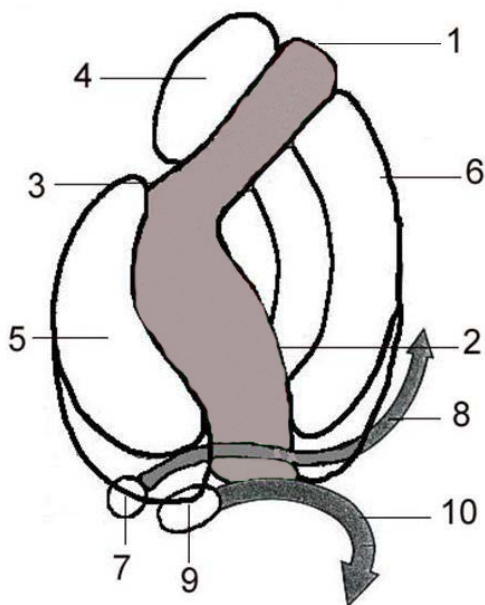
ГИПОТАЛАМОГИПОФИЗАРНАЯ ПОРТАЛЬНАЯ СИСТЕМА HYPOTHALAMOHYPOPHYSEAL PORTAL SYSTEM



- 1 - *nuclei hypothalami;*
- 2 - *corpus mammillare;*
- 3 - *arteria hypophysialis superior;*
- 4 - *arteria trabecularis;*
- 5 - *arteria hypophysialis inferior;*
- 6 - *terminatio axonis;*
- 7 - *plexus capillares lobi posterioris;*
- 8 - *vena hypophysialis;*
- 9 - *lobus neuralis seu posterior;*

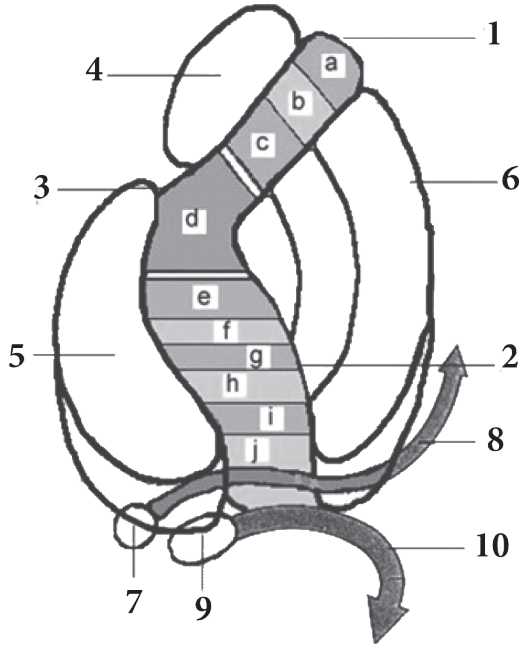
- 10 - *nucleus paraventricularis;*
- 11 - *nucleus supraopticus;*
- 12 - *chiasma opticum;*
- 13 - *systema hypothalamohypophysiale
(plexus capillaris primarius);*
- 14 - *vv. portales hypophysiales;*
- 15 - *plexus capillaris secundarius;*
- 16 - *vena hypophysialis;*
- 17 - *lobus anterior.*

PORTIUNILE CAPSULEI INTERNE
(după Gray, 2008)
ЧАСТИ ВНУТРЕННЕЙ КАПСУЛЫ
COMPONENTS OF THE INTERNAL CAPSULE



- 1 - crus anterior;**
- 2 - crus posterior;**
- 3 - genu capsulae internaе;**
- 4 - caput nuclei caudati;**
- 5 - thalamus;**
- 6 - nucleus lentiformis;**
- 7 - corpus geniculatum mediale;**
- 8 - radiatio acustica;**
- 9 - corpus geniculatum laterale;**
- 10 - radiatio optica (Gratiolet).**

COMPONENTELE CAPSULEI INTERNE
 (modificat după Williams P.L., Warwick R., 1989)
КОМПОНЕНТЫ ВНУТРЕННЕЙ КАПСУЛЫ
COMPONENTS (PATHWAYS) OF THE INTERNAL CAPSULE



a – tractus frontothalamicus;
b – tractus frontorubralis;
c – tractus frontopontinus;
d – tractus corticonuclearis;
e – tractus corticospinalis;
f – tractus bulbothalamicus et spinothalamicus;
g – tractus corticothalamicus;
h – tractus parietooccipitopontinus et occipitotemporopontinus;
i – radiatio acustica;
j – radiatio optica (tractus occipitohalamicus, Gratiolet).

1 – crus anterior capsulae internaе;
2 – crus posterior capsulae internaе;
3 – genu capsulae internaе;
4 – caput nuclei caudati;
5 – thalamus;
6 – nucleus lentiformis;
7 – corpus geniculatum mediale;
8 – radiatio acustica;
9 – corpus geniculatum laterale;
10 – radiatio optica.

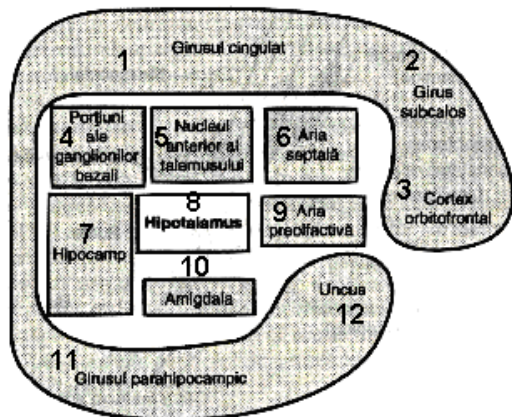
SISTEMUL LIMBIC

(după A. Guyton, 1997)

(neomologat de TA)

ЛИМБИЧЕСКАЯ СИСТЕМА

THE LIMBIC SYSTEM

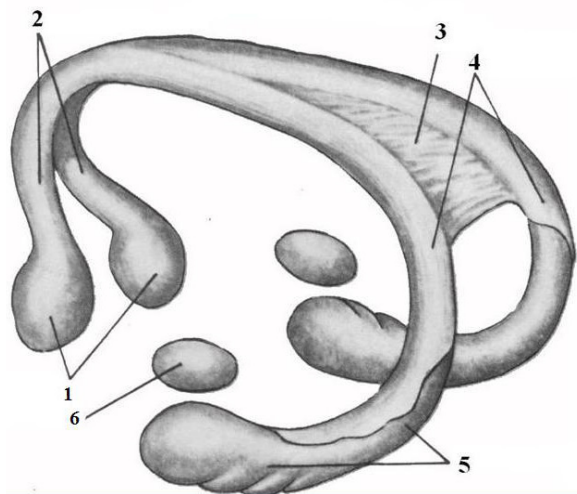


- 1 – gyrus cinguli;
- 2 – area subcallosa;
- 3 – cortex orbitofrontalis;
- 4 – nuclei basales;
- 5 – nucleus anterior thalami;
- 6 – septum pellucidum;
- 7 – hippocampus;
- 8 – hypothalamus;
- 9 – area paraolfactoria;
- 10 – corpus amygdaloideum;
- 11 – gyrus parahippocampalis;
- 12 – uncus.

FORNIXUL

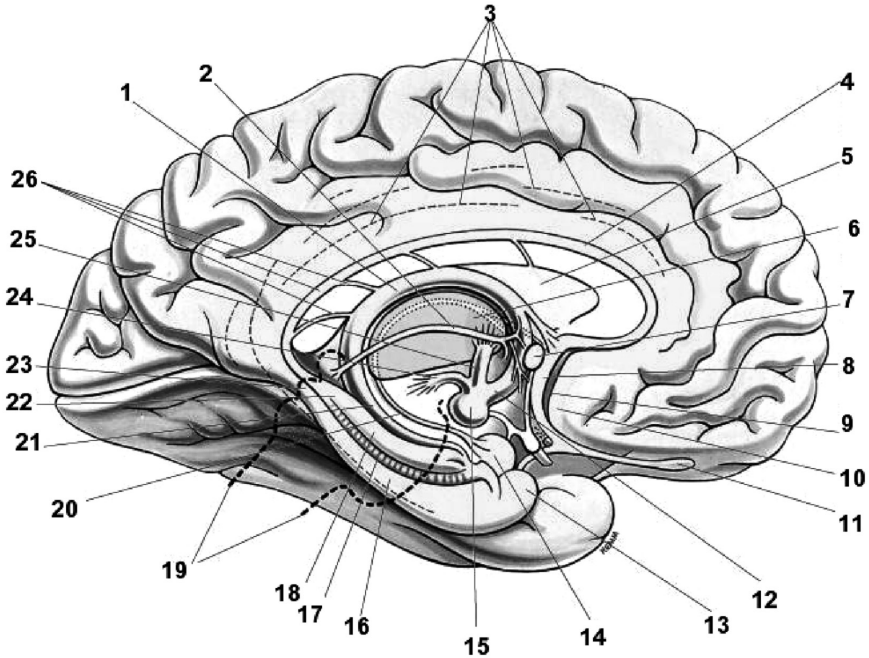
СВОД

THE FORNIX



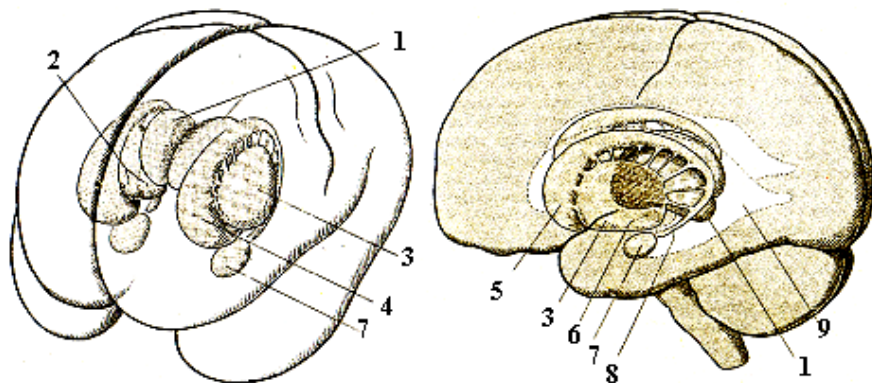
- 1 – corpora mamillaria;
- 2 – columnae fornix;
- 3 – commissura hippocampi seu commissura fornix (lyra Davidi);
- 4 – crura fornix;
- 5 – hippocampus;
- 6 – corpus amygdaloideum.

**LOBUL LIMBIC: PARTEA VIZIBILĂ PE FAȚA MEDIANĂ
A EMISFEREI CEREBRALE**
**ЛИМБИЧЕСКАЯ ДОЛЯ: ВИДИМАЯ ЧАСТЬ НА МЕДИАЛЬНОЙ
ПОВЕРХНОСТИ ПОЛУШАРИЯ**
**THE LIMBIC LOBE: COMPONENTS OF THE LIMBIC SYSTEM
THAT CAN BE DISTINGUISHED ON THE MEDIAL SURFACE
OF THE BRAIN HEMISPHERE**



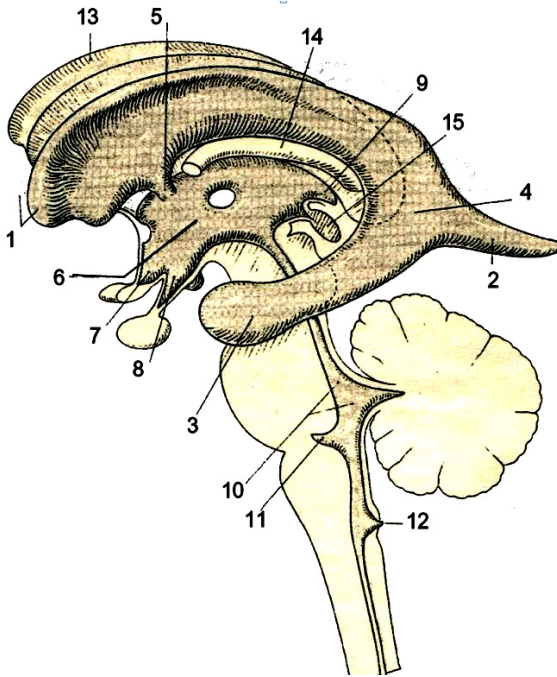
- | | |
|--|--------------------------------------|
| 1 - corpus fornicis; | 14 - corpus amygdaloideum; |
| 2 - stria medullaris thalami; | 15 - corpora mammillaria; |
| 3 - gyrus cinguli; | 16 - gyrus parahippocampalis; |
| 4 - indusium griseum et striae longitudinales (medialis et lateralis); | 17 - gyrus dentatus; |
| 5 - septum pellucidum; | 18 - hippocampus; |
| 6 - nuclei anteriores thalami; | 19 - truncus encephali; |
| 7 - commissura anterior; | 20 - stria terminalis; |
| 8 - gyrus paraterminalis; | 21 - fimbria hippocampi; |
| 9 - rudimentum prehippocampale; | 22 - gyrus fasciolaris; |
| 10 - area paraolfactoria; | 23 - isthmus gyri cinguli; |
| 11 - bulbus olfactorius; | 24 - fasciculus mammillotegmentalis; |
| 12 - columnae fornicis; | 25 - fasciculus mammillothalamicus; |
| 13 - uncus; | 26 - corpus callosum. |

**INTERRELAȚIILE NUCLEILOR BAZALI
 CU SISTEMUL VENTRICULAR**
**ВЗАИМООТНОШЕНИЯ БАЗАЛЬНЫХ ЯДЕР
 С ЖЕЛУДОЧКОВОЙ СИСТЕМОЙ**
**INTERRELATIONS BETWEEN BASAL NUCLEI
 AND VENTRICULAR SYSTEM**



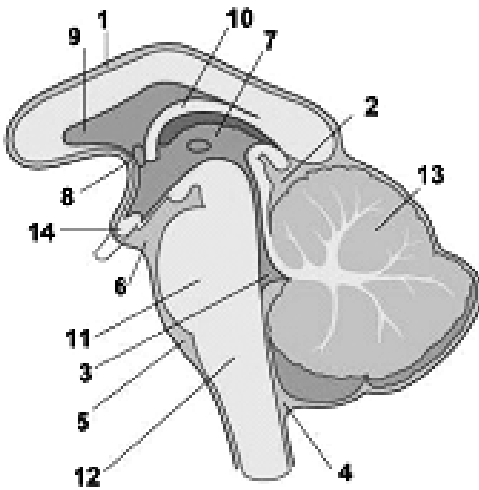
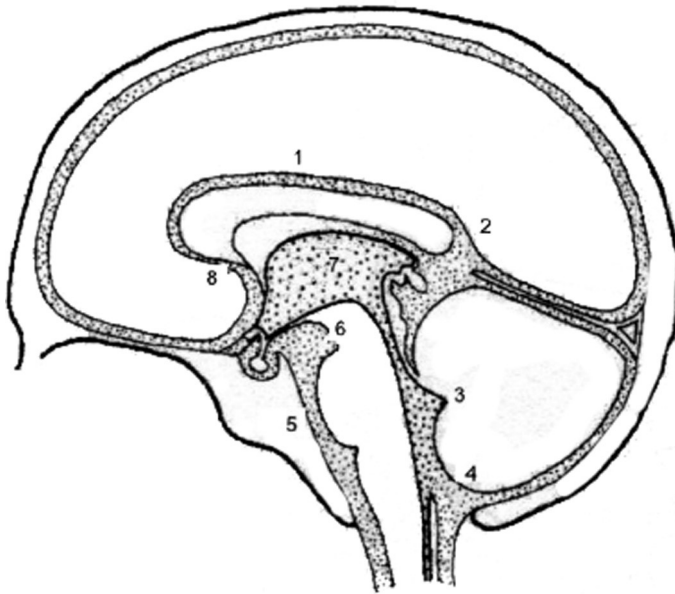
- 1 - thalamus;*
- 2 - globus pallidus;*
- 3 - putamen;*
- 4 - nucleus caudatus;*
- 5 - caput nuclei caudati;*
- 6 - nucleus subthalamicus;*
- 7 - corpus amygdaloideum;*
- 8 - cauda nuclei caudati;*
- 9 - ventriculus lateralis.*

SISTEMUL VENTRICULAR
СИСТЕМА ЖЕЛУДОЧКОВ ГОЛОВНОГО МОЗГА
VENTRICULAR SYSTEM



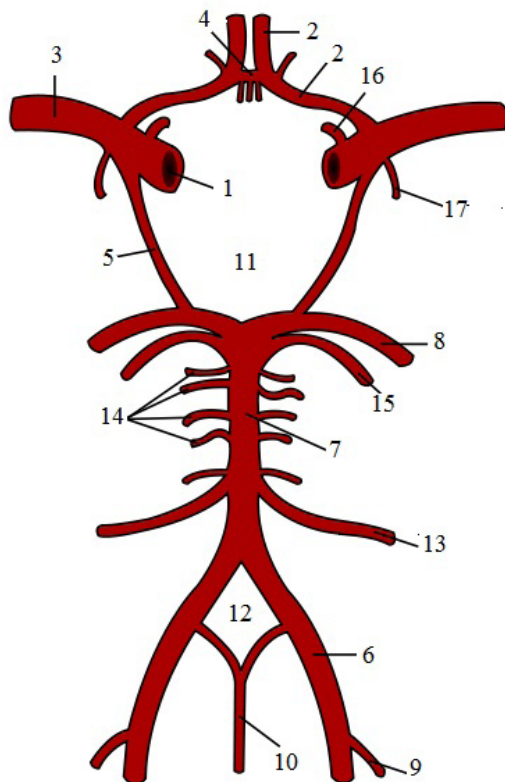
- 1 – cornu frontale/anterius (ventriculi lateralis);
- 2 – cornu occipitale/posterius (ventriculi lateralis);
- 3 – cornu temporale/inferius (ventriculi lateralis);
- 4 – trigonum collaterale;
- 5 – foramen interventriculare (Monro);
- 6 – ventriculus tertius;
- 7 – recessus supraopticus;
- 8 – recessus infundibuli;
- 9 – recessus suprapinealis;
- 10 – aquaeductus cerebri et ventriculus quartus;
- 11 – recessus lateralis et apertura lateralis ventriculi quarti (Luschka);
- 12 – apertura mediana ventriculi quarti (Magendie);
- 13 – corpus callosum;
- 14 – fornix;
- 15 – glandula pinealis.

CISTERNELE SUBARAHNOIDIENE
ПОДПАУТИНОВЫЕ ЦИСТЕРНЫ
THE SUBARACHNOID CISTERNAE



- 1 - *cisterna pericallosa*;
- 2 - *cisterna ambiens*;
- 3 - *ventriculus IV (quartus)*;
- 4 - *cisterna cerebellomedullaris posterior (cisterna magna)*;
- 5 - *cisterna pontocerebellaris*;
- 6 - *cisterna interpeduncularis*;
- 7 - *ventriculus III (tertius)*;
- 8 - *cisterna laminae terminalis*;
- 9 - *septum pellucidum*;
- 10 - *fornix*;
- 11 - *pons*;
- 12 - *medulla oblongata*;
- 13 - *cerebellum*;
- 14 - *chiasma opticum*.

POLIGONUL ARTERIAL AL ENCEFALULUI (Th. Willis)
АРТЕРИАЛЬНОЕ КОЛЬЦО ОСНОВАНИЯ МОЗГА (Th. Willis)
CEREBRAL ARTERIAL CIRCLE (WILLIS' CIRCLE)



- 1 – arteria carotis interna;
- 2 – arteria cerebri anterior;
- 3 – arteria cerebri media;
- 4 – arteria communicans anterior;
- 5 – arteria communicans posterior;
- 6 – arteria vertebralis;
- 7 – arteria basilaris;
- 8 – arteria cerebri posterior;
- 9 – arteria inferior posterior cerebelli;
- 10 – arteria spinalis anterior;

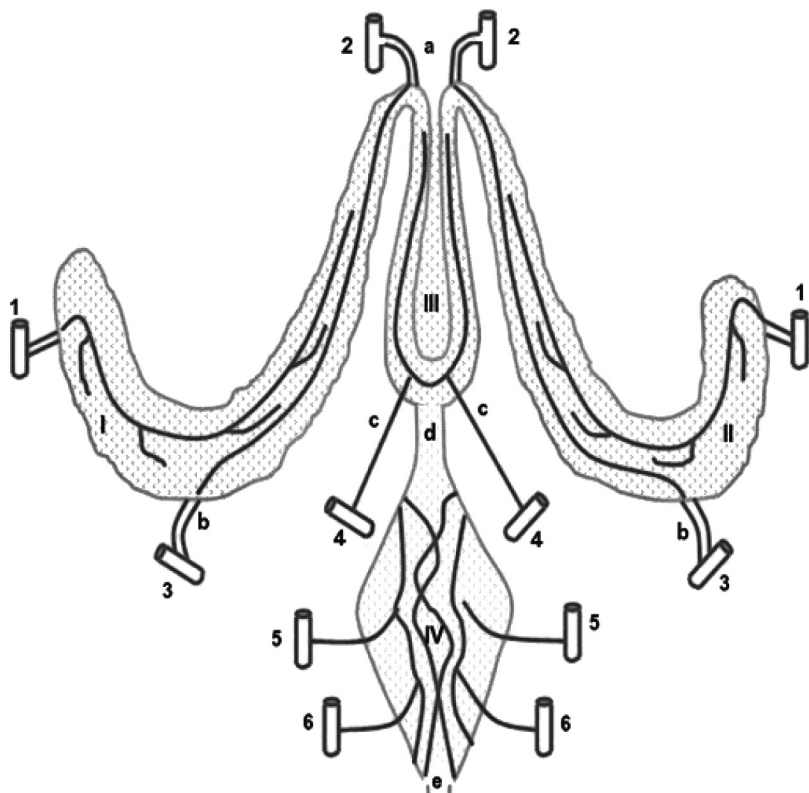
- 11 – circulus arteriosus cerebri (major) (Willis);
- 12 – circulus arteriosus (minor) (Захарченко);
- 13 – arteria inferior anterior cerebelli;
- 14 – arteriae pontis;
- 15 – arteria cereberallis superior;
- 16 – arteria ophthalmica;
- 17 – arteria choroidea anterior.

PLEXURILE COROIDE ALE VENTRICULELOR ENCEFALULUI

(după A. Darii);

СОСУДИСТЫЕ СПЛЕТЕНИЯ ГОЛОВНОГО МОЗГА

THE CHOROID PLEXUSES OF THE VENTRICLES OF THE BRAIN



I, II – plexus choroideus ventriculorum lateraliu;

III – plexus choroideus ventriculi tertii;

IV – plexus choroideus ventriculi quarti.

1 – arteria carotis interna;

2 – arteria cerebri anterior;

3 – arteria cerebri posterior;

4 – arteria cerebelli superior;

5 – arteria cerebelli inferior posterior;

6 – arteria cerebelli inferior anterior;

a – arteria anterior plexus choroidei;

b – arteria media plexus choroidei;

c – arteria posterior plexus choroidei;

d – aquaeductus cerebri (Sylvius);

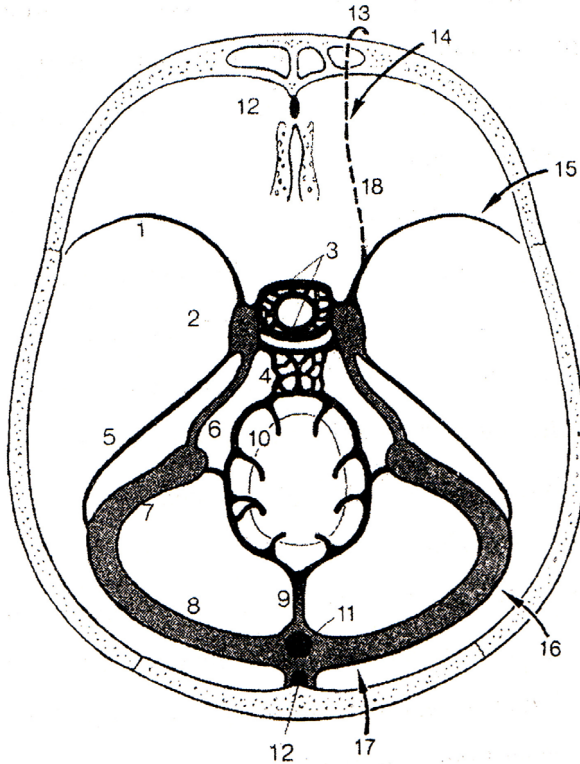
e – canalis medullaris.

SINUSURILE VENOASE ALE PĂRIMENINGELUI

(după F. G. Sido, 2004)

ВЕНОЗНЫЕ СИНОСЫ ТВЕРДОЙ ОБОЛОЧКИ ГОЛОВНОГО МОЗГА

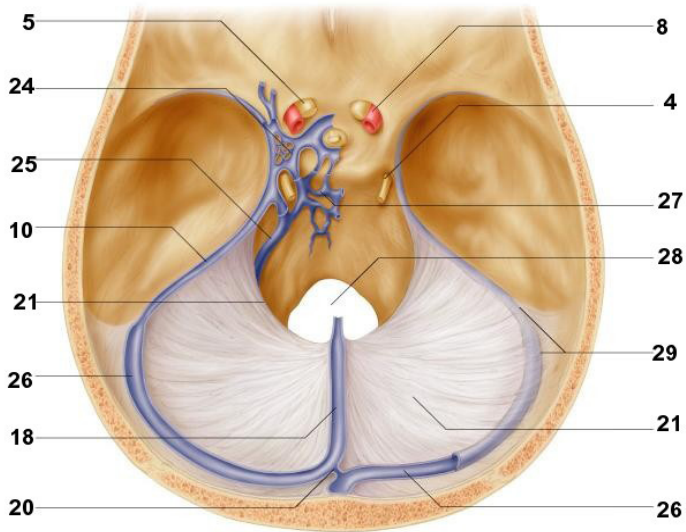
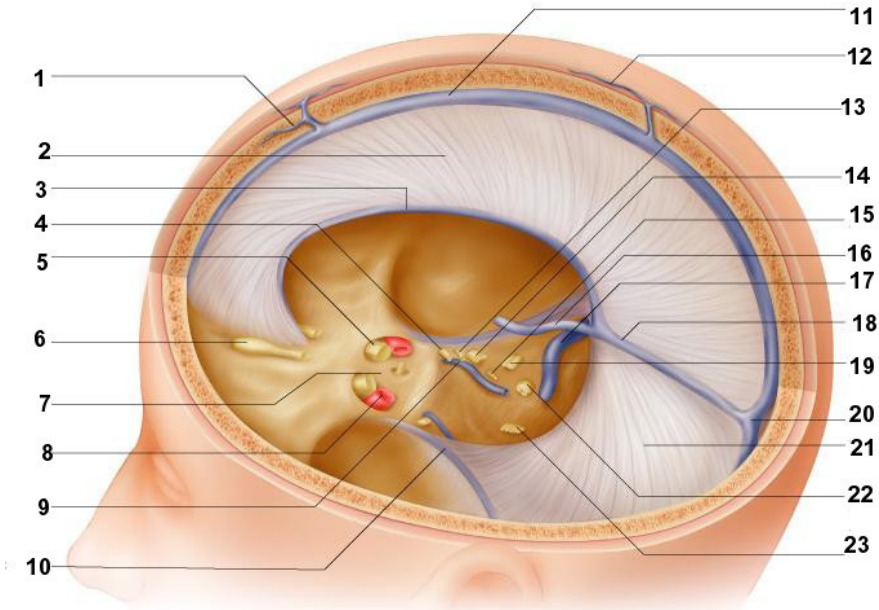
VENOUS SINUSES OF CRANIAL DURA MATER



- 1 – sinus sphenoparietalis;
- 2 – sinus cavernosus;
- 3 – sinus intercavernosus anterior et posterior;
- 4 – plexus venosus basilaris;
- 5 – sinus petrosus superior;
- 6 – sinus petrosus inferior;
- 7 – sinus sigmoideus;
- 8 – sinus transversus;
- 9 – sinus occipitalis;
- 10 – plexus venosus vertebralis internus;

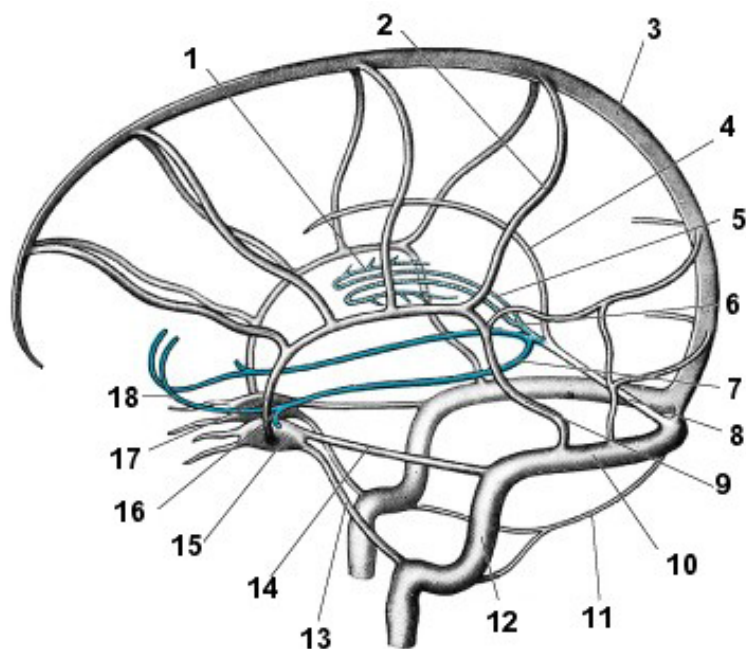
- 11 – sinus rectus;
- 12 – sinus sagittalis superior (sectio horizontalis);
- 13 – vena angularis;
- 14 – vena diploica frontalis;
- 15 – vena diploica temporalis anterior;
- 16 – vena diploica temporalis posterior;
- 17 – vena diploica occipitalis;
- 18 – vena ophthalmica superior.

DERIVATELE PAHIMENINGELUI (dura mater encephali)
ПРОИЗВОДНЫЕ ТВЁРДОЙ ОБОЛОЧКИ ГОЛОВНОГО МОЗГА
DERIVATIVES OF THE DURA MATER OF THE BRAIN



- 1 – vv. *diploicae*;
- 2 – *falx cerebri*;
- 3 – *sinus sagittalis inferior*;
- 4 – n. *oculomotorius*;
- 5 – n. *opticus*;
- 6 – *bulbus olfactorius*;
- 7 – *diaphragma sellae*;
- 8 – a. *carotis interna*;
- 9, 25 – *sinus petrosus inferior*;
- 10 – *sinus petrosus superior*;
- 11 – *sinus sagittalis superior*;
- 12 – vv. *emissariae*;
- 13 – n. *trochlearis*;
- 14 – n. *trigeminus*;
- 15 – n. *abducens*;
- 16 – v. *magna cerebri (Galeni)*;
- 17 – *sinus sigmoideus*;
- 18 – *sinus rectus*;
- 19 – nn. *facialis et vestibulocochlearis*;
- 20 – *confluens sinuum (Herophili)*;
- 21 – *tentorium cerebelli*;
- 22 – nn. *glossopharyngeus, vagus et accessorius (Willisii)*;
- 23 – n. *hypoglossus*;
- 24 – *sinus cavernosus*;
- 26 – *sinus transversus*.

SISTEMUL VENOS INTRACRANIAN
ВНУТРИЧЕРЕПНАЯ ВЕНОЗНАЯ СИСТЕМА
THE INTRACRANIAL VENOUS SYSTEM



*1 – venae thalamostriatae
 (superior et inferiores)
 et choroideae (superior et inferior);*

2 – vena anastomotica superior;

3 – sinus sagittalis superior;

4 – sinus sagittalis inferior;

5 – vena cerebri interna;

6 – vena cerebri magna;

7 – vena basalis;

8 – sinus rectus;

9 – vena anastomotica inferior;

10 – sinus transversus;

11 – sinus occipitalis;

12 – sinus sigmoideus;

13 – sinus petrosus inferior;

14 – sinus petrosus superior;

15 – sinus cavernosus;

16 – vena media profunda cerebri;

17 – vena media superficialis cerebri;

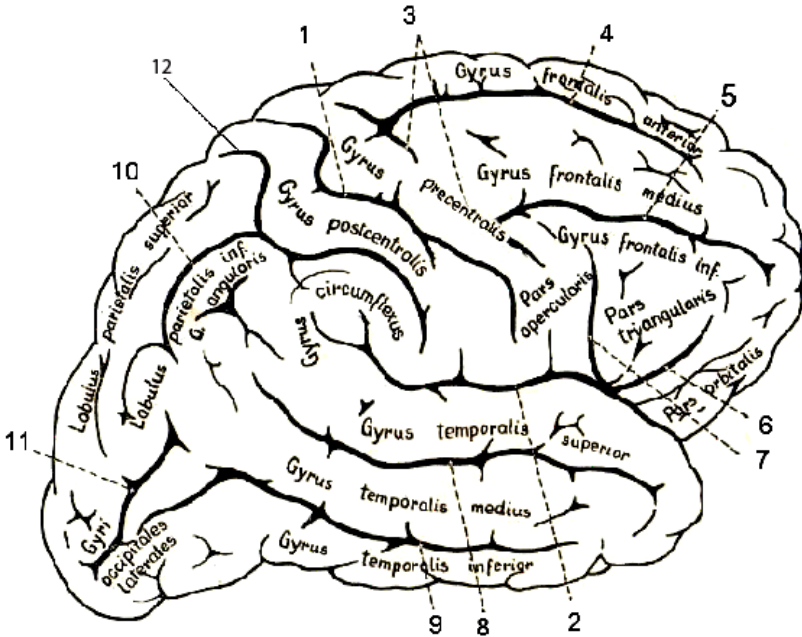
18 – venae anteriores cerebri.

RELIEFUL FEȚEI DORSOLATERALE A EMISFEREI
CEREBRALE DREPTE

(după F. Kiss, J. Szentagothai)

БОРОЗДЫ И ИЗВИЛИНЫ ВЕРХНЕЛАТЕРАЛЬНОЙ ПОВЕРХНОСТИ
ПРАВОГО ПОЛУШАРИЯ МОЗГА

THE RELIEF OF THE DORSOLATERAL SURFACE
OF THE RIGHT CEREBRAL HEMISPHERE



- 1 – sulcus centralis (Rolandi);
- 2 – sulcus lateralis (Sylvii);
- 3 – sulcus precentralis;
- 4 – sulcus frontalis superior;
- 5 – sulcus frontalis inferior;
- 6 – ramus anterior;
- 7 – ramus ascendens;
- 8 – sulcus temporalis superior;
- 9 – sulcus temporalis inferior;
- 10 – sulcus intraparietalis;
- 11 – sulcus occipitalis lateralis (neomologat de TA);
- 12 – sulcus postcentralis.

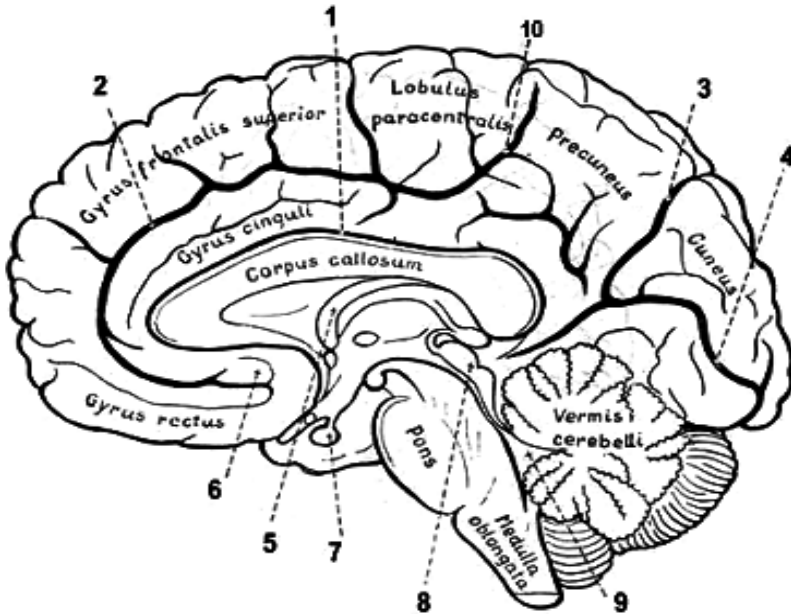
RELIEFUL FEȚEI MEDIALE A EMISFEREI CEREBRALE DREPTE

(după F. Kiss, J. Szentagothai)

БОРОЗДЫ И ИЗВИЛИНЫ МЕДИАЛЬНОЙ ПОВЕРХНОСТИ

ПРАВОГО ПОЛУШАРИЯ МОЗГА

THE RELIEF OF THE MEDIAL SURFACE OF THE RIGHT CEREBRAL HEMISPHERE



1 – sulcus corporis callosi;

2 – sulcus cinguli;

3 – sulcus parietooccipitalis;

4 – sulcus calcarinus;

5 – fornix;

6 – area paraolfactoria;

7 – hypophysis (glandula pituitaria);

8 – lamina quadrigemina (lamina tecti);

9 – ventriculus quartus (IV);

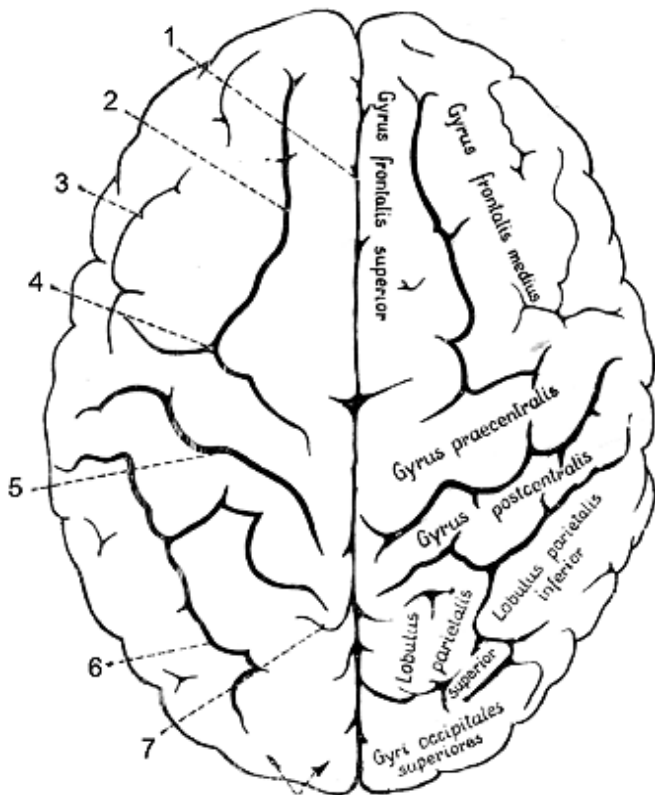
10 – ramus marginalis sulci cinguli (sulcus marginalis).

RELIEFUL FEȚEI SUPERIOARE A EMISFERELOR CEREBRALE

(după F. Kiss, J. Szentagothai)

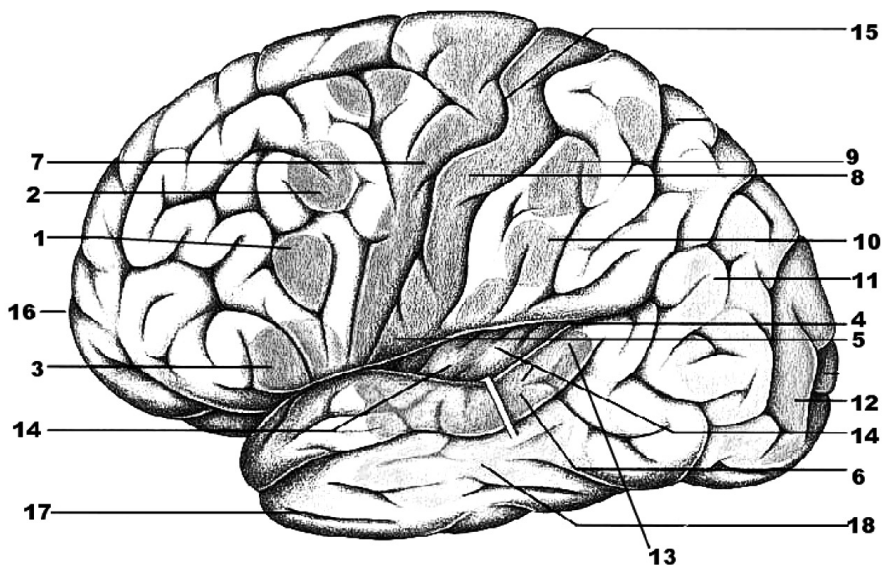
БОРОЗДЫ И ИЗВИЛИНЫ ВЕРХНЕЙ ПОВЕРХНОСТИ ПОЛУШАРИЙ МОЗГА

THE RELIEF OF THE UPPER SURFACE OF THE CEREBRAL HEMISPHERES



- 1 - *fissura longitudinalis cerebri*;
- 2 - *sulcus frontalis superior*;
- 3 - *sulcus frontalis inferior*;
- 4 - *sulcus precentralis*;
- 5 - *sulcus centralis (Rolandi)*;
- 6 - *sulcus intraparietalis*;
- 7 - *ramus marginalis sulci cinguli*;
- 8 - *polus occipitalis*.

LOCALIZAREA FUNCȚIILOR ÎN SCOARȚA EMISFERELOR MARI
 (fața dorsolaterală)
 ЛОКАЛИЗАЦИЯ ФУНКЦИЙ В КОРЕ ПОЛУШАРИЙ МОЗГА
 (верхнелатеральная поверхность)
 LOCALIZATION OF FUNCTIONS IN THE CEREBRAL CORTEX
 (superolateral surface)



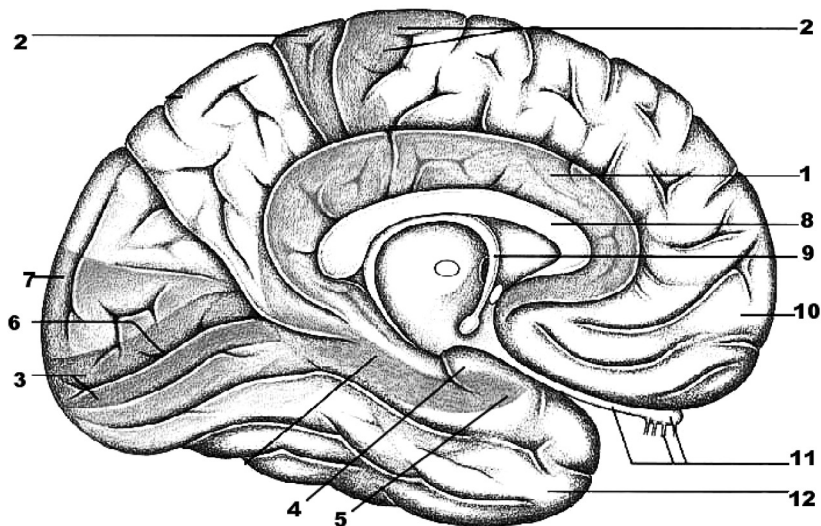
1. Analizatorul motor al limbajului scris (*gyrus frontalis medius, pars premotoria*).
2. Nucleul analizatorului ce asigură mișcarea concomitentă a capului și ochilor în sens opus (*gyrus frontalis medius, pars centralis*).
3. Nucleul analizatorului motor al vorbirii articulate (*pars opercularis, gyrus Broca*).
4. *Pars inferior gyri postcentralis*.
5. Nucleul analizatorului impulsurilor de la viscere și vase (*pars inferior gyri pre-et postcentralis*).
6. Nucleul analizatorului auditiv (*pars centralis gyri temporalis superioris / gyri temporales transversi Heschl*).
7. Nucleul analizatorului motor – coordonarea mișcărilor (*gyrus precentralis*).
8. Nucleul analizatorului cortical al sensibilității generale (*gyrus postcentralis*).
9. Nucleul analizatorului stereognoziei (*lobulus parietalis superior*).

10. Nucleul praxiei (*gyrus supramarginalis*).
11. Nucleul analizatorului optic al limbajului scris (*gyrus angularis*).
12. Lobul optic (*lobus occipitalis*).
13. Nucleul analizatorului acustic al vorbirii orale (*pars posterior gyri temporalis superioris, centrul Wernicke*).
14. Nucleul analizatorului gustativ (*cortex insulae Reili et operculum fronto-parietalis*).
15. *Sulcus centralis (Rolandi)*.
16. *Lobus frontalis*.
17. *Lobus temporalis*.
18. *Gyrus temporalis medius*.

1. Ядро двигательного анализатора письменной речи (*gyrus frontalis medius, pars premotoria*).
2. Ядро двигательного анализатора сочетанного поворота головы и глаз в противоположную сторону (*gyrus frontalis medius*).
3. Ядро двигательного анализатора артикуляции речи (*pars opercularis, gyrus Broca*).
4. *Pars inferior gyri postcentralis*.
5. Ядро анализатора импульсов от внутренностей и сосудов (*pars inferior gyri pre- et postcentralis*).
6. Ядро слухового анализатора (*pars centralis gyri temporalis superioris / gyri temporales transversi Heschl*).
7. Ядро двигательного анализатора (*координация движений*) (*gyrus precentralis*).
8. Ядро анализатора общей чувствительности (*кожного анализатора*) (*gyrus postcentralis*).
9. Ядро анализатора стереогнозии (*lobulus parietalis superior*).
10. Ядро/центр праксии (*целенаправленных движений*) (*gyrus supramarginalis*).
11. Ядро зрительного анализатора письменной речи (*gyrus angularis*).
12. Ядро зрительного анализатора (*lobus occipitalis*).
13. Ядро слухового анализатора устной речи, *центр Wernicke* (*pars posterior gyri temporalis superioris*).
14. Ядро вкусового анализатора (*cortex insulae Reili et operculum fronto-parietalis*).
15. *Sulcus centralis (Rolandi)*.
16. *Lobus frontalis*.
17. *Lobus temporalis*.
18. *Gyrus temporalis medius*.

1. Nucleus of the motor analyser of the written speech (*gyrus frontalis medius, pars premotoria*).
2. Nucleus of the motor analyser concerned with concord turning of the head and eyes in the opposite direction (*gyrus frontalis medius, pars premotoria*).
3. Nucleus of the motor analyser of speech articulation (*Broca's speech area (pars opercularis, gyrus Broca)*).
4. *Pars inferior gyri postcentralis*.
5. Nucleus of the analyser of impulses passing from the viscera and vessels (*pars inferior gyri pre- et postcentralis*).
6. Nucleus of the auditory analyser (*pars centralis gyri temporalis superioris / gyri temporales transversi Heschl*).
7. Nucleus of the motor analyser (*gyrus precentralis*).
8. The nucleus of the skin analyser (*the sense of touch, pain, and temperature (gyrus postcentralis)*).
9. Nucleus of the stereognosis (*lobulus parietalis superior*).
10. Nucleus of the motor analyser (*by means of which habitual purposeful combined movements are synthesized (gyrus supramarginalis)*).
11. Nucleus of the visual analyser of the written speech (*gyrus angularis*).
12. Nucleus of the visual analyser (*lobus occipitalis*).
13. Nucleus of the auditory analyser of spoken speech (*Wernicke's center (pars posterior gyri temporalis superioris)*).
14. Nucleus of the taste analyser (*cortex insulae Reili et operculum fronto-parietalis*).
15. *Sulcus centralis (Rolandi)*.
16. *Lobus frontalis*.
17. *Lobus temporalis*.
18. *Gyrus temporalis medius*.

LOCALIZAREA FUNCȚIILOR ÎN SCOARȚA EMISFERELOR MARI
 (fața medială și inferioară)
 ЛОКАЛИЗАЦИЯ ФУНКЦИЙ В КОРЕ ПОЛУШАРИЙ МОЗГА
 (медиаьная и нижняя поверхности)
 LOCALIZATION OF FUNCTIONS IN THE CEREBRAL CORTEX
 (medial and inferior surfaces)



1. Centrul sistemului limbic, suprem vegetativ, emotiv și motivațional (*gyrus fornicatus*).
2. Nucleul analizatorului motor (*lobulus paracentralis, Betz*).
3. Nucleul analizatorului optic (*lobus occipitalis, zona din prejma sulcus calcarinus*).
4. Nucleul analizatorului olfactiv (*pars distalis gyrus parahippocampalis, uncus et polus temporalis*).
5. *Uncus*.
6. *Sulcus calcarinus*.
7. *Lobus occipitalis*.
8. *Corpus callosum*.
9. *Fornix*.
10. *Lobus frontalis*.
11. *Tractus et bulbus olfactorius*.
12. *Lobus temporalis*.

1. Центр лимбической системы, высший вегетативный центр эмоций и мотиваций (*gyrus fornicatus*).
2. Ядро двигательного анализатора (*lobulus paracentralis Betz*).
3. Ядро зрительного анализатора (*lobus occipitalis*).
4. Ядро обонятельного анализатора (*pars distalis gyri parahippocampalis, uncus et polus temporalis*).
5. *Uncus*.
6. *Sulcus calcarinus*.
7. *Lobus occipitalis*.
8. *Corpus callosum*.
9. *Fornix*.
10. *Lobus frontalis*.
11. *Tractus et bulbus olfactorius*.
12. *Lobus temporalis*.

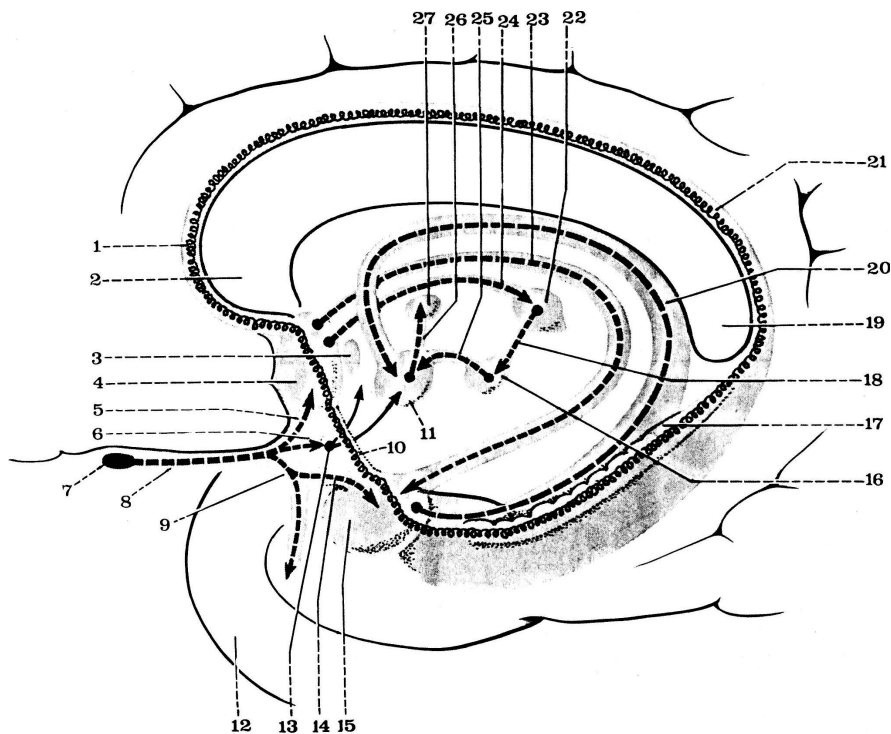
1. Cortical center of the limbic system, the superior vegetative center of emotions and motivations (*the gyrus fornicatus*).
2. Nucleus of the motor analyser (*the paracentral lobule Beitz*).
3. Nucleus of the visual analyser (*occipital lobe*).
4. Nucleus of the olfactory analyser (*pars distalis gyri parahippocampalis, uncus et polus temporalis*).
5. *Uncus*.
6. *Sulcus calcarinus*.
7. *Lobus occipitalis*.
8. *Corpus callosum*.
9. *Fornix*.
10. *Lobus frontalis*.
11. *Tractus et bulbus olfactorius*.
12. *Lobus temporalis*.

COMPONENTELE RINENCEFALULUI

(după C. Cabrol, 1999) - neomologat de TA

КОМПОНЕНТЫ/ ЧАСТИ ОБОНЯТЕЛЬНОГО МОЗГА

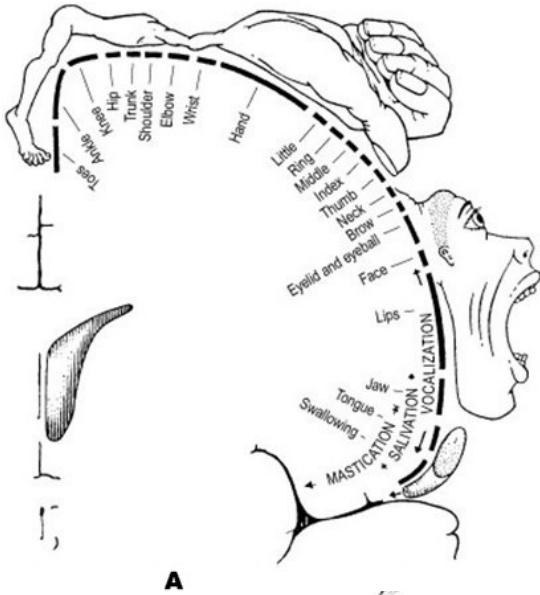
COMPONENTS OF THE RHINENCEPHALON



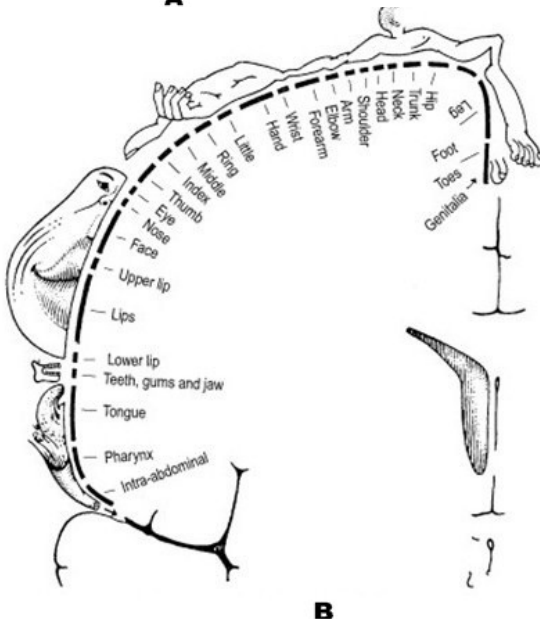
- 1 - genu corporis callosi;
- 2 - rostrum corporis callosi;
- 3 - commissura anterior;
- 4 - nuclei septales (septum pellucidum);
- 5 - stria olfactoria medialis;
- 6 - stria olfactoria intermedia;
- 7 - bulbus olfactorius;
- 8 - tractus olfactorius;
- 9 - stria olfactoria lateralis;
- 10 - stria diagonalis (Broca);
- 11 - corpus mammillare;
- 12 - hippocampus;
- 13 - substantia perforata anterior/rostralis;
- 14 - ramus profundus radices externae;
- 15 - corpus amygdaloideum;

- 16 - nucleus interpeduncularis;
- 17 - gyrus dentatus;
- 18 - fasciculus retroflexus (tractus habenulointerpeduncularis), Meynert;
- 19 - splenium corporis callosi;
- 20 - fimbria hippocampi;
- 21 - indusium griseum;
- 22 - nuclei habenulares lateralis et medialis;
- 23 - stria semicircularis;
- 24 - habenula;
- 25 - fasciculus interpedunculomammillaris (neomologat de TA);
- 26 - fasciculus mammillothalamicus (Vicq d'Azyr);
- 27 - nuclei anteriores thalami.

HOMUNCULUSUL SENZITIV ȘI CEL MOTOR
ЧУВСТВИТЕЛЬНЫЙ И ДВИГАТЕЛЬНЫЙ ГОМУНКУЛУСЫ
THE SENSORY AND MOTOR HOMUNCULUSES

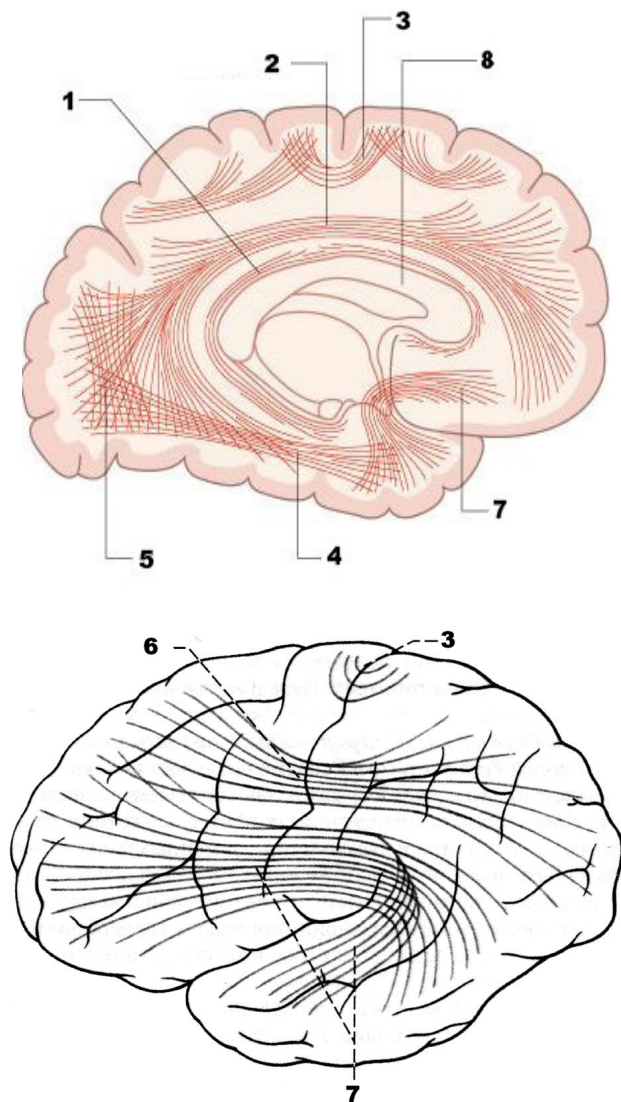


A – gyrus postcentralis;



B – gyrus precentralis.

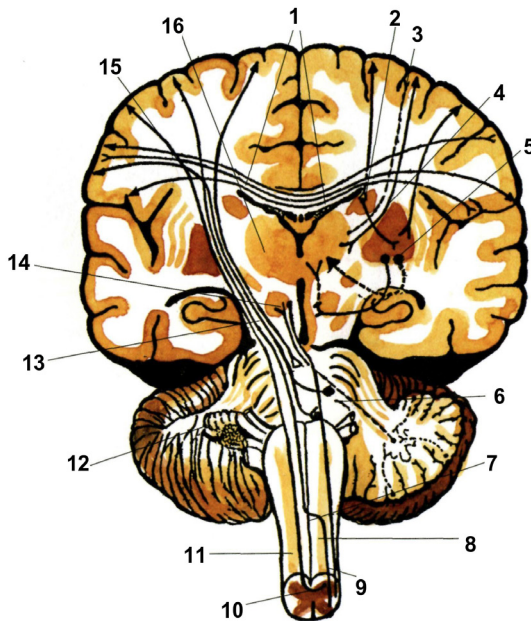
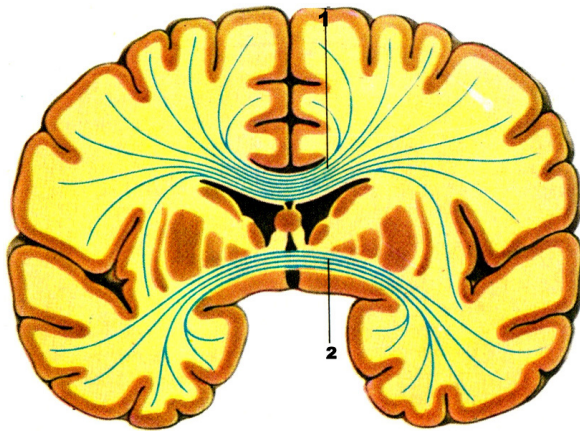
FASCICULELE DE FIBRE ASOCIATIVE DIN SUBSTANȚA
ALBĂ A EMISFERELOR
ПУЧКИ АССОЦИАТИВНЫХ ВОЛОКОН
БЕЛОГО ВЕЩЕСТВА ПОЛУШАРИЙ
THE FASCICLES OF ASSOCIATIVE FIBERS OF THE WHITE
MATER OF THE CEREBRAL HEMISPHERES



A – facies medialis;
B – facies superolateralis.

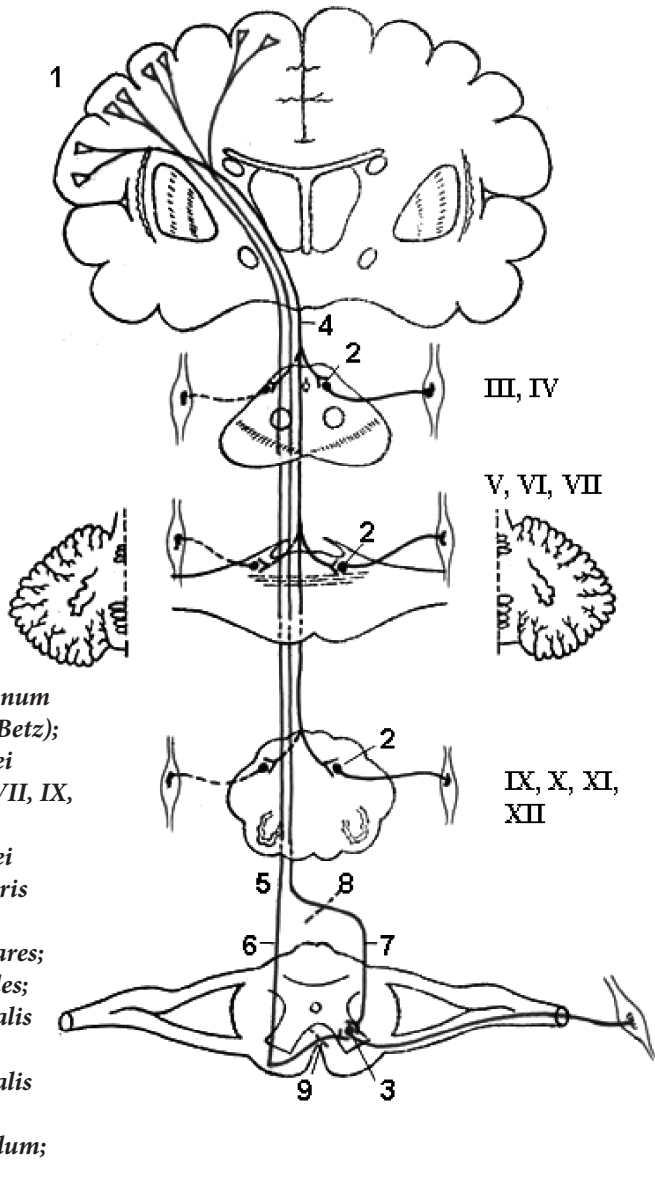
1 – cingulum;
2 – fasciculus longitudinalis superior (arcuatus);
3 – fibrae arcuatae cerebri;
4 – fasciculus longitudinalis inferior;
5 – fasciculi occipitales verticales (Wernike);
6 – fasciculus longitudinalis superior (arcuatus);
7 – fasciculus uncinatus;
8 – corpus callosum.

**FIBRELE COMISURALE ȘI DE PROIECȚIE
 DIN SUBSTANȚA ALBĂ A EMISFERELOR**
**КОМИССУРАЛЬНЫЕ И ПРОЕКЦИОННЫЕ ВОЛОКНА
 БЕЛОГО ВЕЩЕСТВА ПОЛУШАРИЙ**
**COMISSURAL AND PROJECTION FIBERS
 OF THE WHITE MATTER OF THE BRAIN**

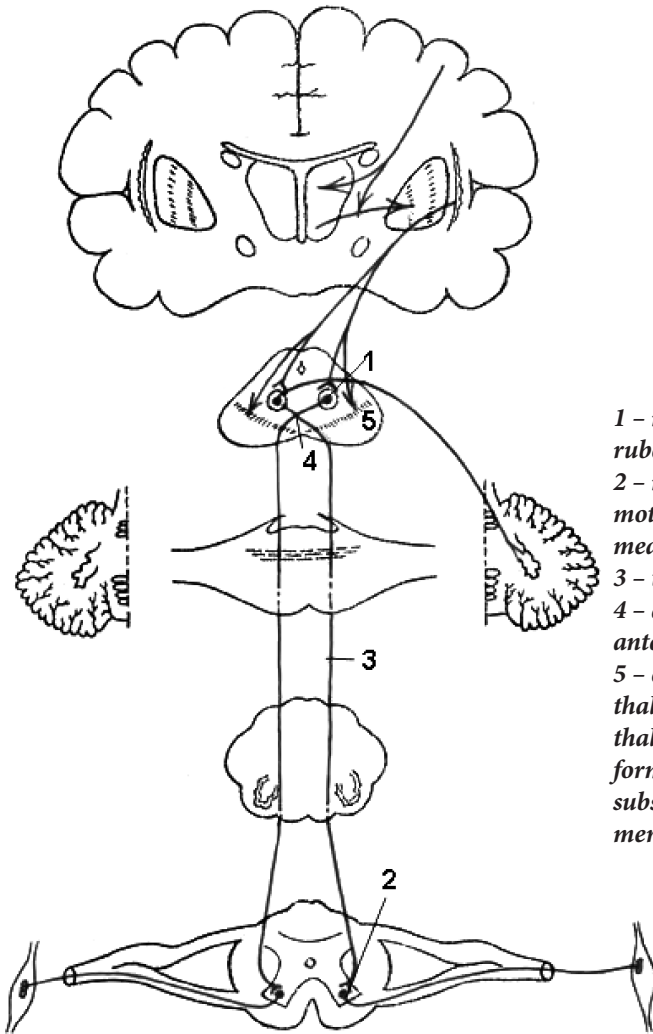


- 1 – *fibrae corporis callosi*;
- 2 – *commissura anterior*;
- 3 – *radiatio thalami*;
- 4 – *capsula interna*;
- 5 – *nucleus lentiformis*;
- 6 – *fibrae pedunculi cerebellaris superioris*;
- 7 – *decussatio pyramidum (motoria)*;
- 8 – *tractus corticospinalis lateralis*;
- 9 – *tractus rubrospinalis*;
- 10 – *commissura alba*;
- 11 – *tractus corticospinalis anterior*;
- 12 – *fibrae pontis transversae*;
- 13 – *tractus corticopontinus*;
- 14 – *nucleus ruber*;
- 15 – *fibrae corticonucleares*;
- 16 – *thalamus*.

SISTEMUL PIRAMIDAL (principala cale motoare)
ПИРАМИДНАЯ СИСТЕМА (главный двигательный путь)
PYRAMIDAL SYSTEM (the main motor tract)



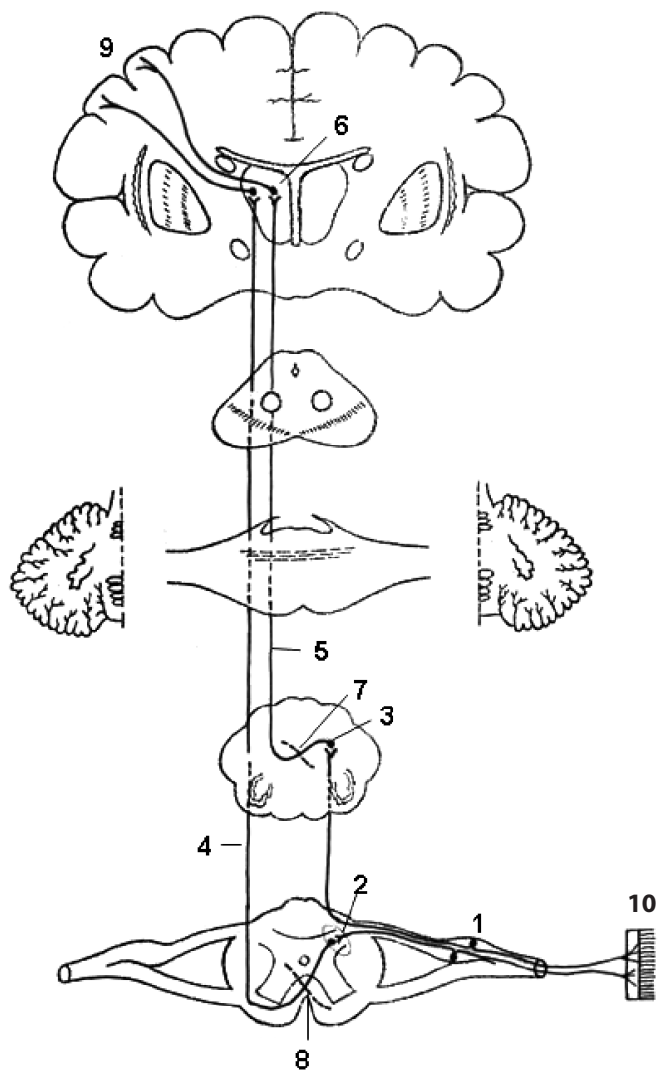
PRINCIPALA CALE A SISTEMULUI EXTRAPIRAMIDAL
 (tractul rubrospinal) (fasciculul von Monakow)
 ГЛАВНЫЙ ПУТЬ ЭКСТРАПИРАМИДНОЙ (СТРИОПАЛЛИДАРНОЙ)
 СИСТЕМЫ (красноядерно-спинномозговой путь) (von Monakow)
 THE MAIN EXTRAPYRAMIDAL (STRIOPALLIDAL) SYSTEM TRACT
 (rubrospinal tract) (Monakow's bundle)



- 1 – neuronum I (nucleus ruber);
- 2 – neuronum II (nuclei motorii cornus anterioris medullae spinalis);
- 3 – tractus rubrospinalis;
- 4 – decussatio tegmentalis anterior (Forel);
- 5 – corpus striatum, thalamus, nucleus sub-thalamicus Luysii, nuclei formationis reticularis, substantia nigra (Soemmerring) etc.

**CĂILE CONȘTIENTE ALE SENSIBILITĂȚII
TACTILE ȘI DE PRESIUNE**

ПУТЬ СОЗНАТЕЛЬНОЙ ТАКТИЛЬНОЙ ЧУВСТВИТЕЛЬНОСТИ
(чувство осязания, прикосновения, давления)
THE CONDUCTING TRACTS OF THE SKIN TACTILE SENSE
(sense of touch and pressure)

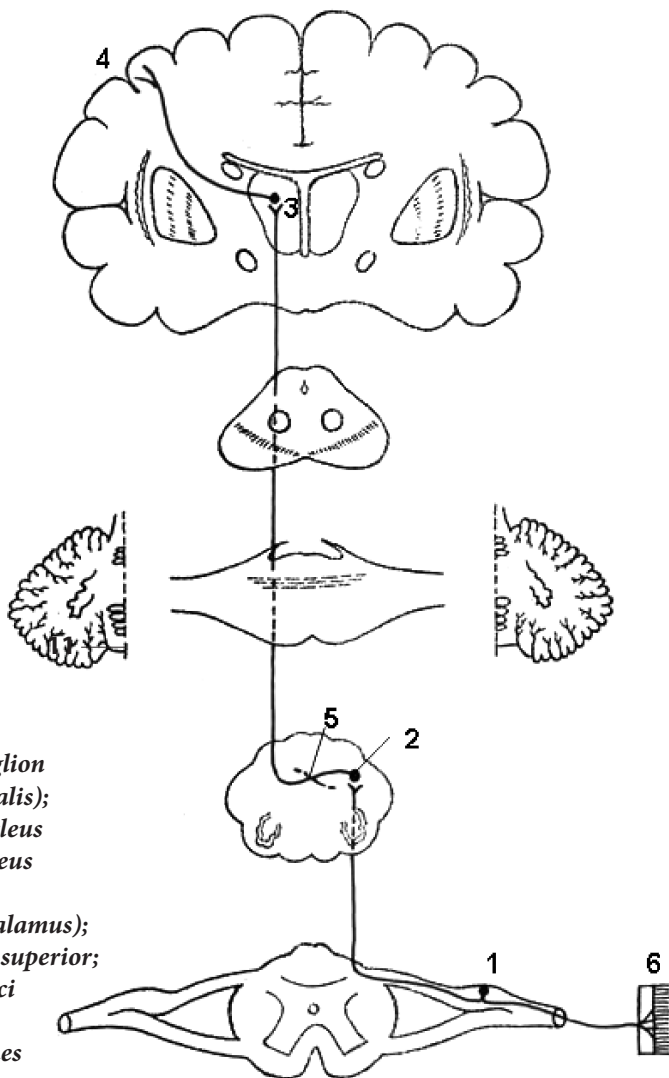


- 1 – neuronum I (ganglion sensorium nervi spinalis);*
- 2 – neuronum II (substantia gelatinosa, Rolandi);*
- 3 – neuronum II [nucleus gracilis (Goll) et nucleus cuneatus (Burdach)];*
- 4 – tractus spinothalamicus anterior;*
- 5 – lemniscus medialis;*
- 6 – neuronum III (thalamus);*
- 7 – decussatio lemnisci medialis;*
- 8 – commissura alba anterior medullae spinalis;*
- 9 – gyrus postcentralis;*
- 10 – cutis, terminationes nervorum.*

CALEA DE CONDUCERE A STEREOGNOZIEI

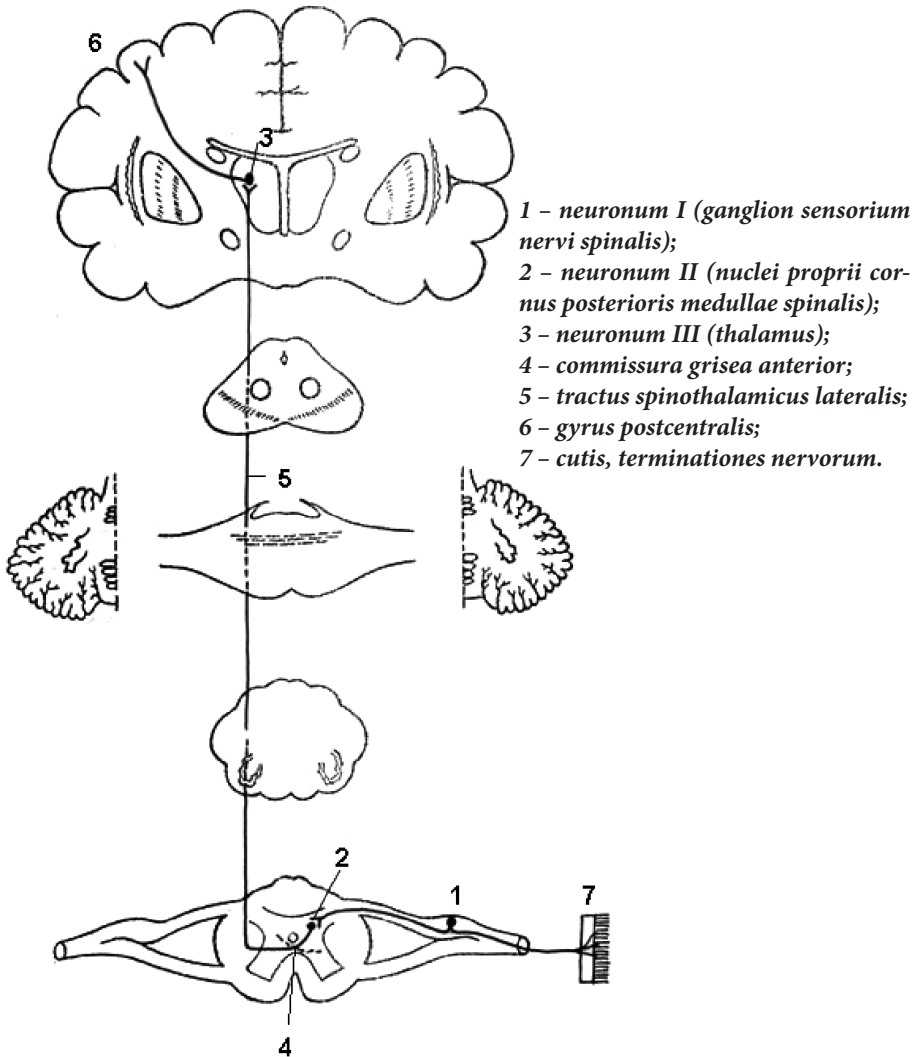
(sensibilitatea cutanată spațială)

ПУТЬ ПРОСТРАНСТВЕННОЙ КОЖНОЙ ЧУВСТВИТЕЛЬНОСТИ
THE CONDUCTING TRACTS OF THREE-DIMENSIONAL SKIN SENSE

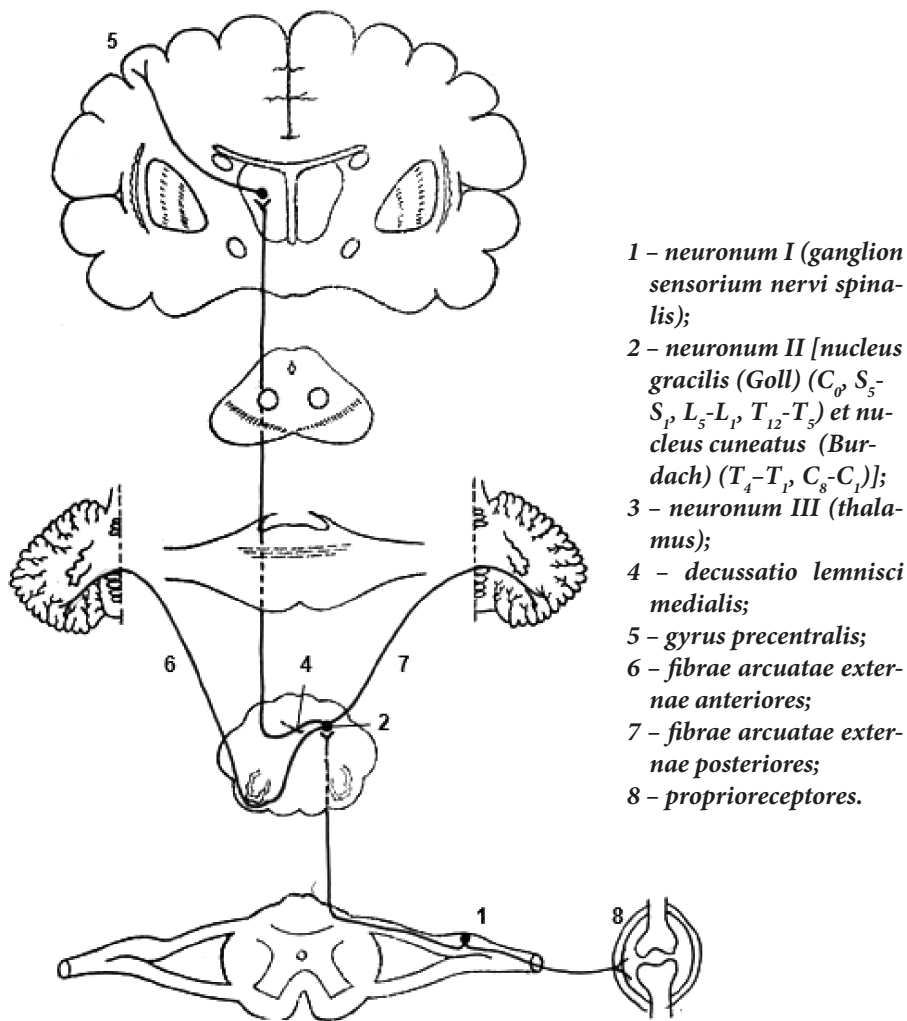


- 1 - neuronum I (ganglion sensorium nervi spinalis);
2 - neuronum II [nucleus gracilis (Goll) et nucleus cuneatus (Burdach)];
3 - neuronum III (thalamus);
4 - lobulus parietalis superior;
5 - decussatio lemnisci medialis;
6 - cutis, terminationes nervorum.

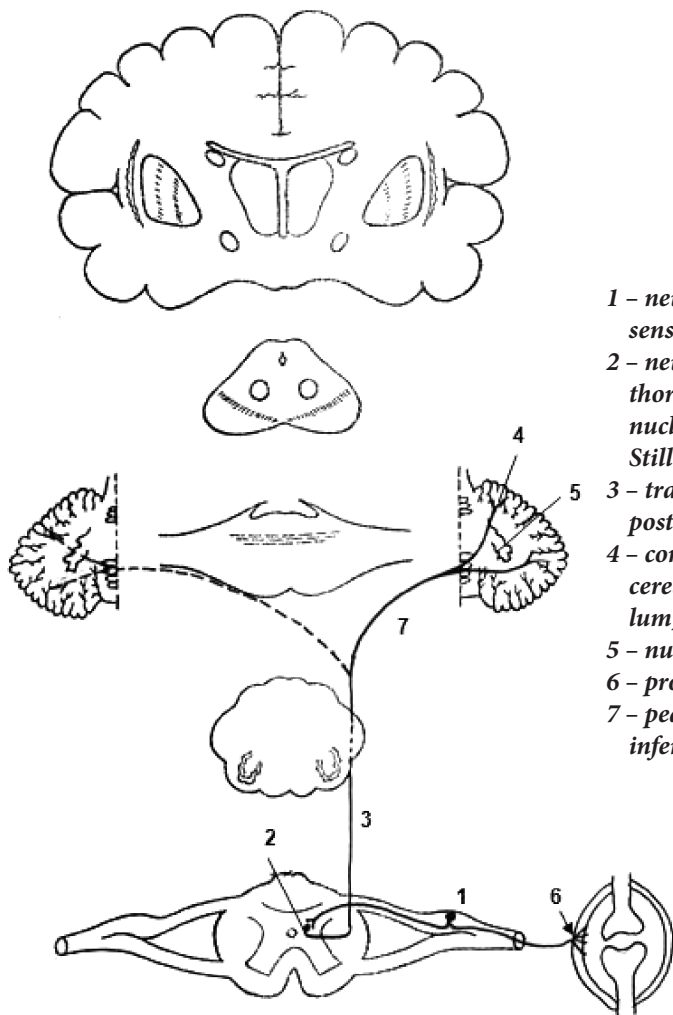
**CALEA CONDUCTOARE A SENSIBILITĂȚII
DOLOROASE ȘI TERMICE**
**ПРОВОДЯЩИЙ ПУТЬ ТЕМПЕРАТУРНОЙ
И БОЛЕВОЙ ЧУВСТВИТЕЛЬНОСТИ**
THE CONDUCTING TRACTS OF PAIN AND TEMPERATURE SENSE



CALEA SENSIBILITĂȚII PROPRIOCEPTIVE DE DIRECȚIE
 CORTICALĂ (sensibilitatea proprioceptivă conștientizată)
 ПРОПРИОЦЕПТИВНЫЙ СОЗНАТЕЛЬНЫЙ ПУТЬ КОРКОВОГО
 НАПРАВЛЕНИЯ (мышечно-суставное чувство)
 THE PROPRIOCEPTIVE TRACT TO THE CEREBRAL CORTEX

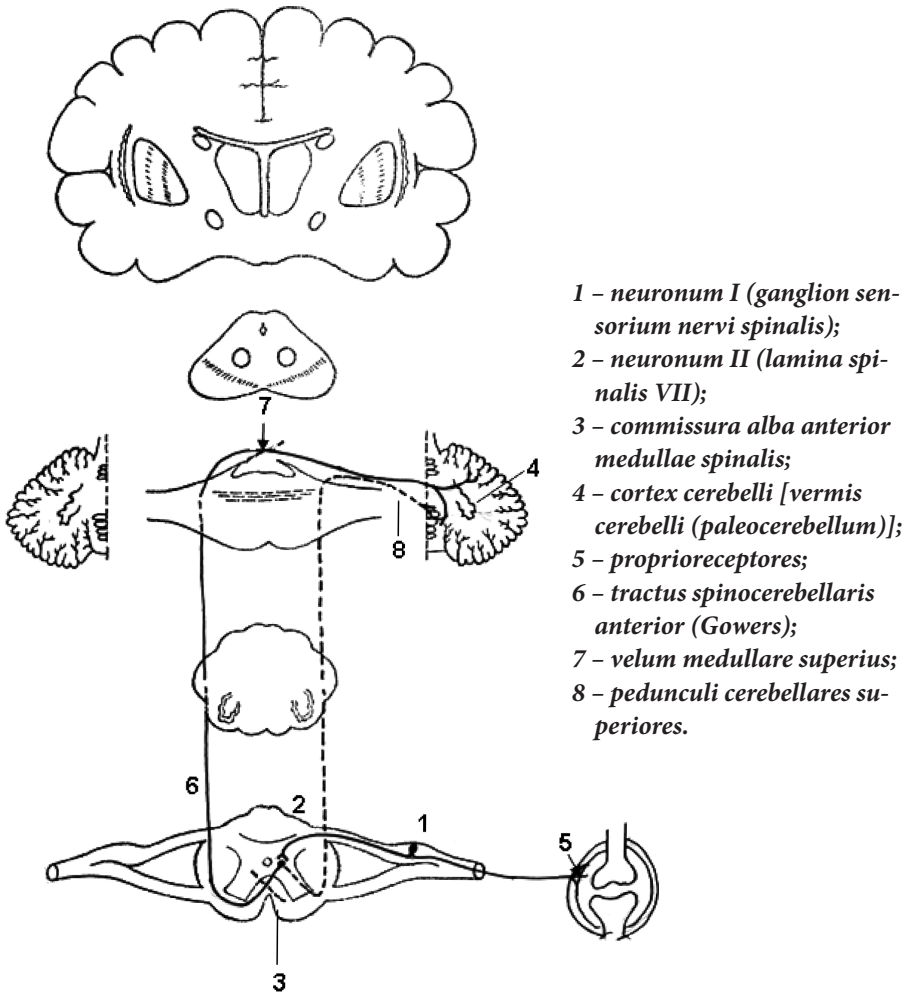


CALEA SENSIBILITĂȚII PROPRIOCEPTIVE INCONȘTIENTE
 (DIRECTĂ) DE DIRECȚIE CEREBELOASĂ
 (tractul spinocerebelos posterior, Flechsig)
 ПРОПРИОЦЕПТИВНЫЙ ПУТЬ МОЗЖЕЧКОВОГО НАПРАВЛЕНИЯ
 (ПРЯМОЙ, НЕПЕРЕКРЕЩЕННЫЙ)
 (задний спинномозжечковый путь, Flechsig)
 THE PROPRIOCEPTIVE SUBCONSCIOUS TRACT TO THE
 CEREBELLUM (posterior spinocerebellar tract, Flechsig's)



- 1 - neuronum I (ganglion sensorium nervi spinalis);
- 2 - neuronum II [nucleus thoracicus posterior, nucleus dorsalis, Clarke-Stilling (C_8-L_3)];
- 3 - tractus spinocerebellaris posterior, Flechsig;
- 4 - cortex cerebelli [vermis cerebelli (paleocerebellum)];
- 5 - nucleus dentatus;
- 6 - proprioceptores;
- 7 - pedunculi cerebellares inferiores.

**CALEA PROPRIOCEPTIVĂ INCONȘTIENTĂ
DE DIRECȚIE CEREBELOASĂ
(indirectă) (tractul spinocerebelos anterior) (Gowers)
ПРОПРИОЦЕПТИВНЫЙ, БЕЗСОЗНАТЕЛЬНЫЙ ПУТЬ
МОЗЖЕЧКОВОГО НАПРАВЛЕНИЯ (непрямой)
(передний спинномозжечковый путь, Gowers)
THE PROPRIOCEPTIVE SUBCONSCIOUS TRACT TO THE
CEREBELLUM (anterior spinocerebellar tract, Gowers)**

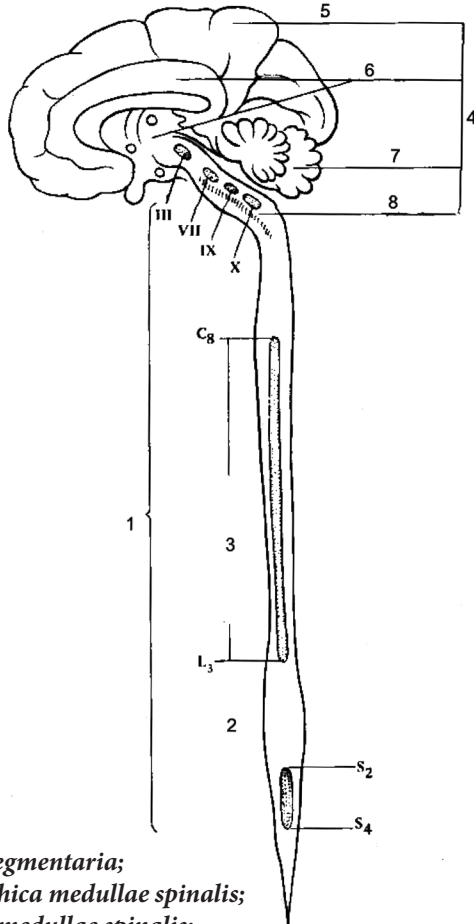


SCHEMA TOPOGRAFIEI CENTRILOR VEGETATIVI SEGMENTARI

(după П.И. Лобко и др., 1988)

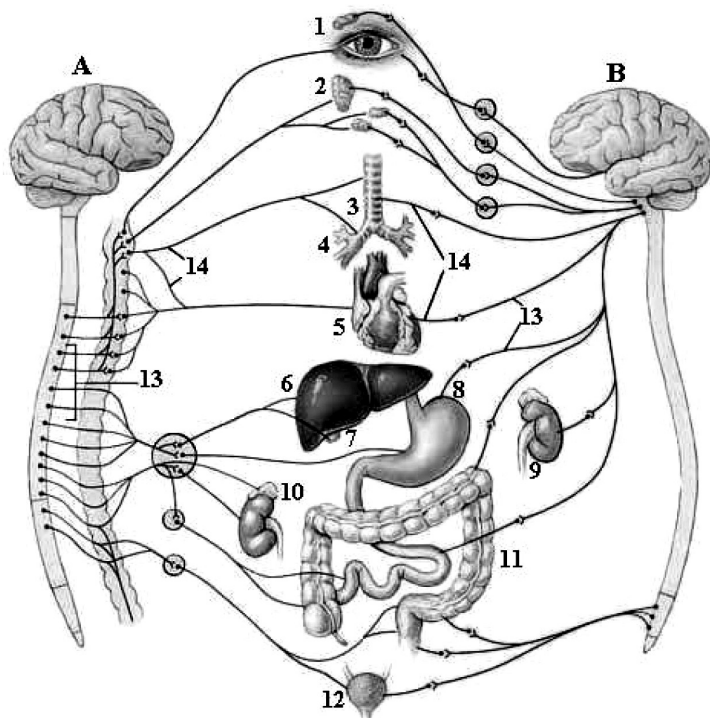
СХЕМА ТОПОГРАФИИ СЕГМЕНТАРНЫХ ВЕГЕТАТИВНЫХ ЦЕНТРОВ

THE SCHEME OF TOPOGRAPHY OF THE SEGMENTARY VEGETATIVE CENTERS



- 1 - *centra vegetativa segmentaria*;
- 2 - *centra parasympathica medullae spinalis*;
- 3 - *centra sympathica medullae spinalis*;
- 4 - *centra vegetativa suprasedgmentaria*;
- 5 - *cortex*;
- 6 - *lobus limbicus*;
- 7 - *cerebellum*;
- 8 - *formatio reticularis*.

**DISTRIBUIREA PĂRȚILOR SIMPATICĂ
ȘI PARASIMPATICĂ ÎN FORMAȚIUNILE ANATOMICE**
**РАСПРЕДЕЛЕНИЕ СИМПАТИЧЕСКОЙ И ПАРАСИМПАТИЧЕСКОЙ
ЧАСТЕЙ НЕРВНОЙ СИСТЕМЫ В АНАТОМИЧЕСКИХ
ОБРАЗОВАНИЯХ**
**DISTRIBUTION OF THE SYMPATHETIC AND PARASYMPHETIC
NERVOUS SYSTEM WITHIN ANATOMICAL FORMATIONS**

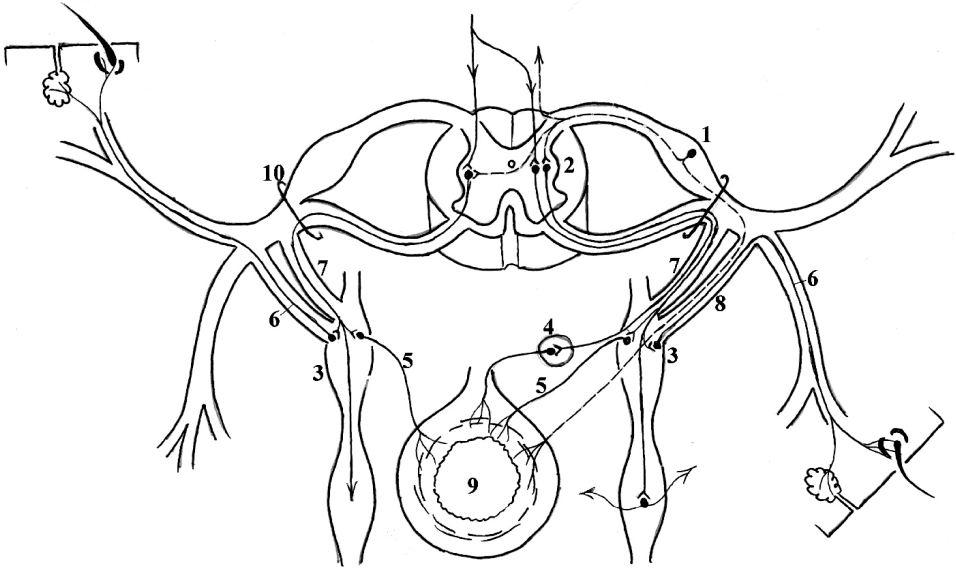


A – pars sympathica;
B – pars parasymphatica.

1 – oculus;
2 – gl. salivariae;
3 – trachea;
4 – bronchi;
5 – cor;
6 – hepar;

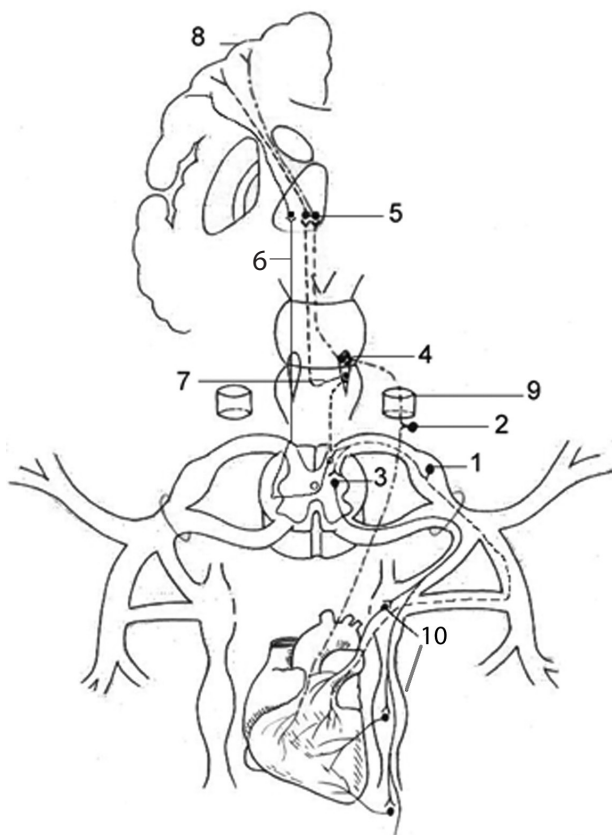
7 – vesica fellea;
8 – gaster;
9 – ren;
10 – gl. suprarenalis;
11 – tractus digestorius;
12 – vesica urinaria;
13 – neurofibra preganglionica;
14 – neurofibra postganglionica.

**ARCUL REFLEX AL DIVIZIUNII AUTONOMICE A SISTEMULUI
NERVOS (PARTEA SIMPATICĂ)
РЕФЛЕКТОРНАЯ ДУГА ВЕГЕТАТИВНОЙ (СИМПАТИЧЕСКОЙ)
НЕРВНОЙ СИСТЕМЫ
VEGETATIVE (SYMPATHETIC) REFLEX ARC**



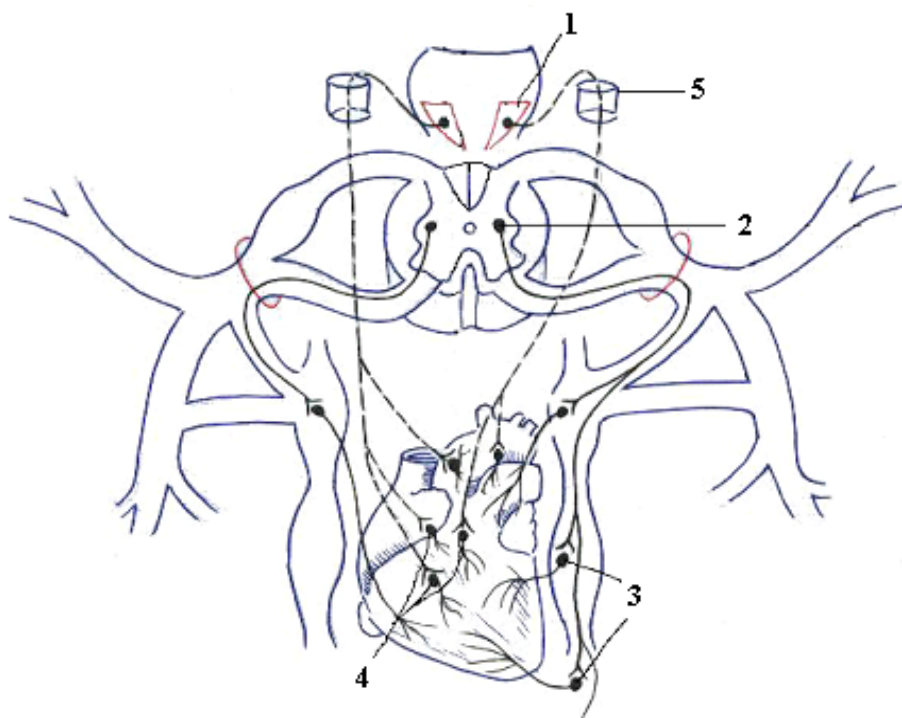
- 1 – ganglion sensorium nervi spinalis (neuronum I);
- 2 – cornu laterale, nucleus intermediolateralis (C_8, T_{1-12}, L_{1-3}) (neuronum II);
- 3 – ganglion trunci sympathici (neuronum III);
- 4 – ganglion prevertebrale (neuronum III);
- 5 – pars visceralis;
- 6 – pars somatica;
- 7 – ramus communicans albus;
- 8 – ramus communicans griseus;
- 9 – viscerus (organum internum);
- 10 – foramen intervertebrale.

INERVAȚIA AFERENTĂ A INIMII
АФФЕРЕНТНАЯ ИННЕРВАЦИЯ СЕРДЦА
AFFERENT INNERVATION OF THE HEART



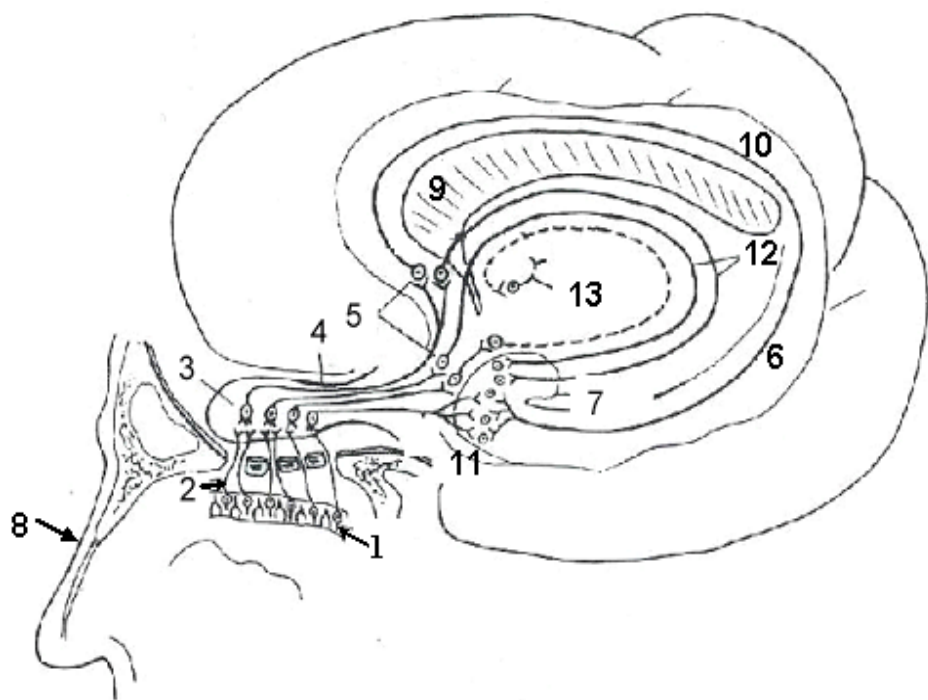
- 1 – neuronum I (ganglion sensorium nervi spinalis);*
- 2 – neuronum I [(ganglion inferius n. vagi (X));*
- 3 – neuronum II (nucleus intermediolateralis medullae spinalis);*
- 4 – neuronum II (nuclei tractus solitarii);*
- 5 – neuronum III (thalamus);*
- 6 – tractus spinothalamicus lateralis;*
- 7 – tractus ganglio-bulbo-thalamo-corticalis (neomologat de TA);*
- 8 – gyrus postcentralis;*
- 9 – foramen jugulare;*
- 10 – ganglia trunci sympathici.*

INERVAȚIA EFERENTĂ VEGETATIVĂ A INIMII
ЭФФЕРЕНТНАЯ ИННЕРВАЦИЯ СЕРДЦА
EFFERENT INNERVATION OF THE HEART



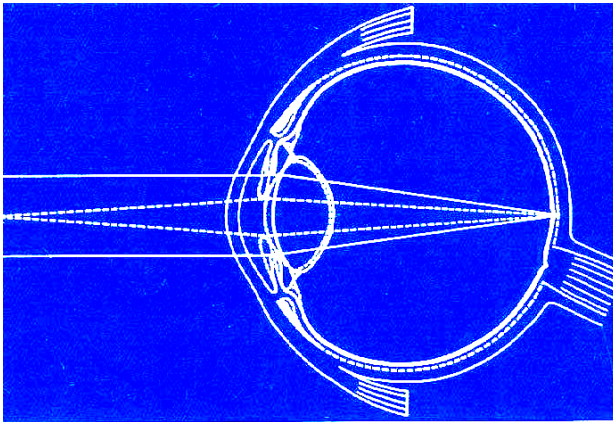
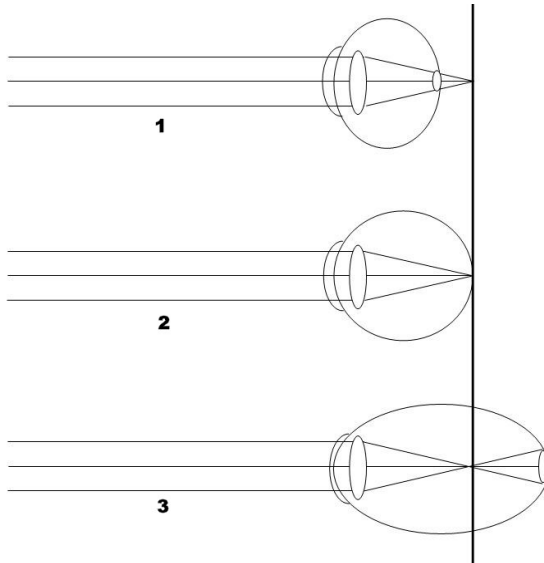
- 1 – *nucleus dorsalis n. vagi (X) (parasympathicus)*;
2 – *nucleus intermediolateralis (sympathicus)*;
3 – *ganglia trunci sympathici*;
4 – *ganglia cardiaca*;
5 – *foramen jugulare*.

CALEA CONDUCTOARE OLFACTIVĂ
ПРОВОДЯЩИЙ ПУТЬ ОБОНЯНИЯ
OLFACTORY PATHWAYS



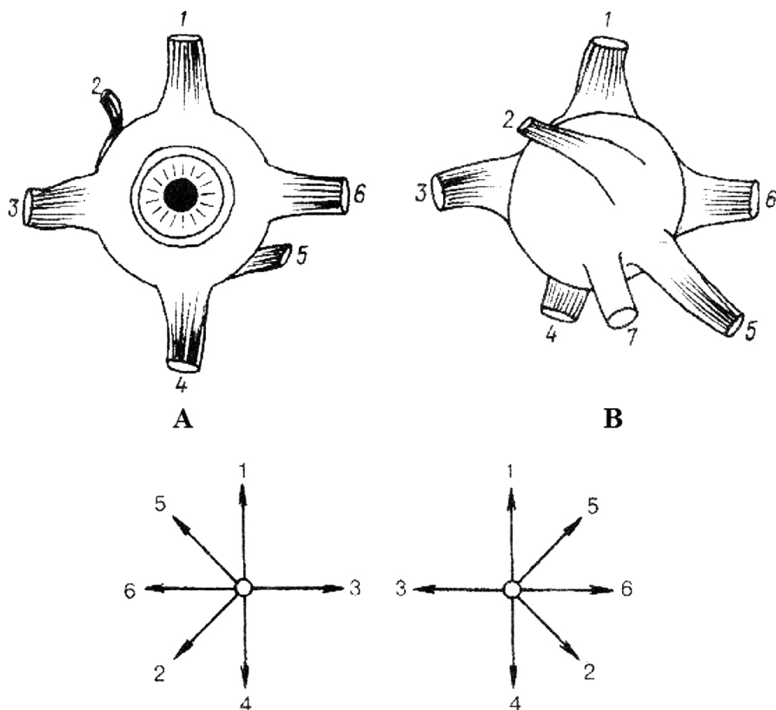
- 1 – *neuronum I (epitheliocytus neurosensorius olfactorius);*
- 2 – *fila olfactoria;*
- 3 – *neuronum II (neuron mitrale et neuron plumosum bulbi olfactorii);*
- 4 – *tractus olfactorius;*
- 5 – *neuronum III (trigonum olfactorium, substantia perforata anterior, septum pellucidum);*
- 6 – *gyrus parahippocampalis;*
- 7 – *uncus, corpus amygdaloideum et area subcallosa;*
- 8 – *nasus externus;*
- 9 – *corpus callosum;*
- 10 – *gyrus cinguli;*
- 11 – *gyrus dentatus;*
- 12 – *fornix;*
- 13 – *thalamus.*

REFRAȚIA RAZELOR DE LUMINĂ ÎN ANOMALII OCULARE
ПРЕЛОМЛЕНИЕ ЛУЧЕЙ СВЕТА ПРИ АНОМАЛИЯХ
ГЛАЗНОГО ЯБЛОКА
REFRACTION OF THE LIGHT IN ABNORMALITIES OF THE EYEBALL



- 1 - ochi hipermetrop/dальнозоркость/ hypermetropia / oculus hypermetropicus (hyperopia, hypermetropia).
- 2 - ochi emetrop/нормальное преломление/ emmetropia / oculus emmetropicus (emmetropia, refractio normalis oculi);
- 3 - ochi miop / близорукость / myopia / oculus myopicus;

MUȘCHII GLOBULUI OCULAR
МЫШЦЫ ГЛАЗНОГО ЯБЛОКА
EXTRA-OCULAR MUSCLES



A – facies anterior

B – facies posterior

1 – m. rectus superior;

2 – m. obliquus superior;

3 – m. rectus medialis;

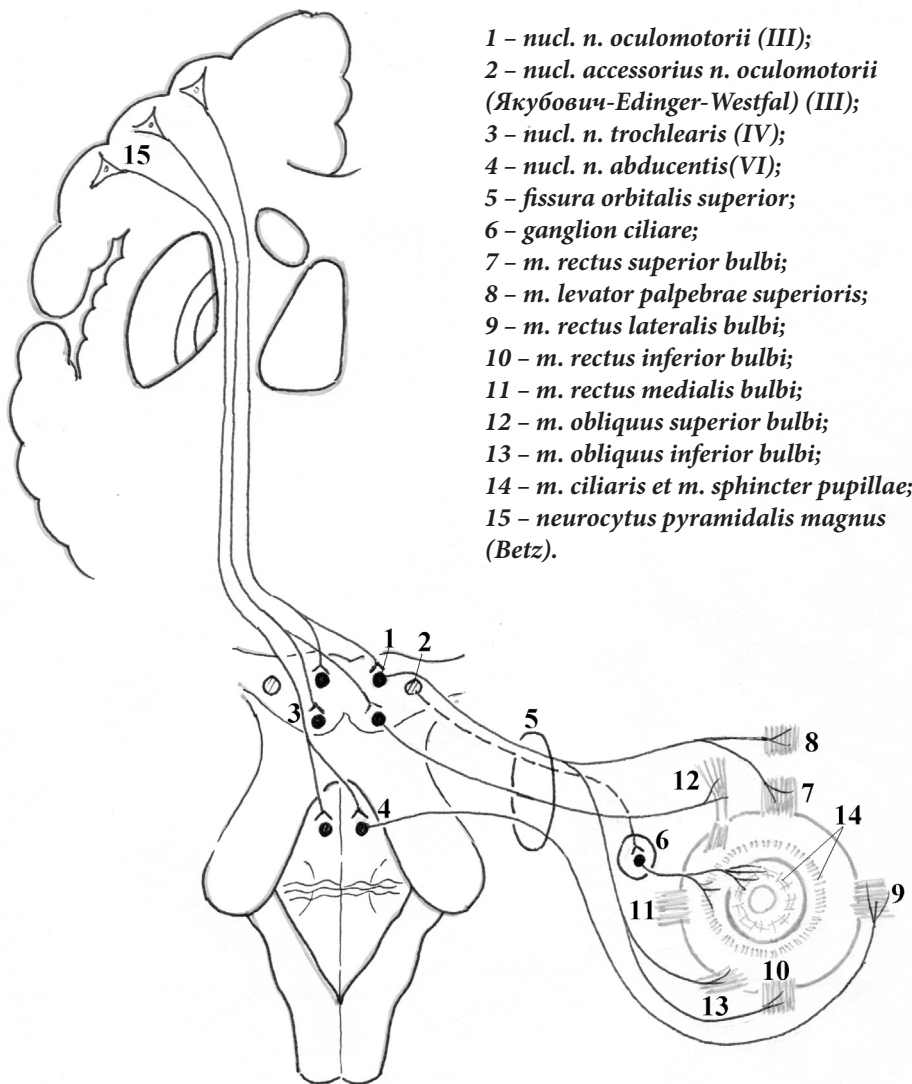
4 – m. rectus inferior;

5 – m. obliquus inferior;

6 – m. rectus lateralis.

- 1 – *epitheliocyti (neurosensorii) coniferi et bacilliferi;*
- 2 – *neuronum I (neuronum bipolare);*
- 3 – *neuronum II (neuronum ganglionare multipolare);*
- 4 – *neuronum III:*
- 4a – *pulvinar thalami;*
- 4b – *corpus geniculatum laterale;*
- 4c – *colliculi superiores;*
- 5 – *radiatio optica (Gratiolet);*
- 6 – *regio sulci calcarini;*
- 7 – *nervus opticus;*
- 8 – *chiasma opticum;*
- 9 – *tractus opticus;*
- 10 – *nuclei colliculorum superiorum;*
- 11 – *tractus tectospinalis;*
- 12 – *tractus tectobulbaris;*
- 13 – *decussatio tegmentalis posterior (Meynert);*
- 14 – *ganglion ciliare;*
- 15 – *medulla spinalis;*
- 16 – *colliculi inferiores;*
- 17 – *ganglion cervicale superius trunci sympathici;*
- 18 – *ramus communicans albus;*
- 19 – *plexus caroticus internus;*
- 20 – *centrum ciliospinale (C₈-Th₁) (neomologat de TA).*

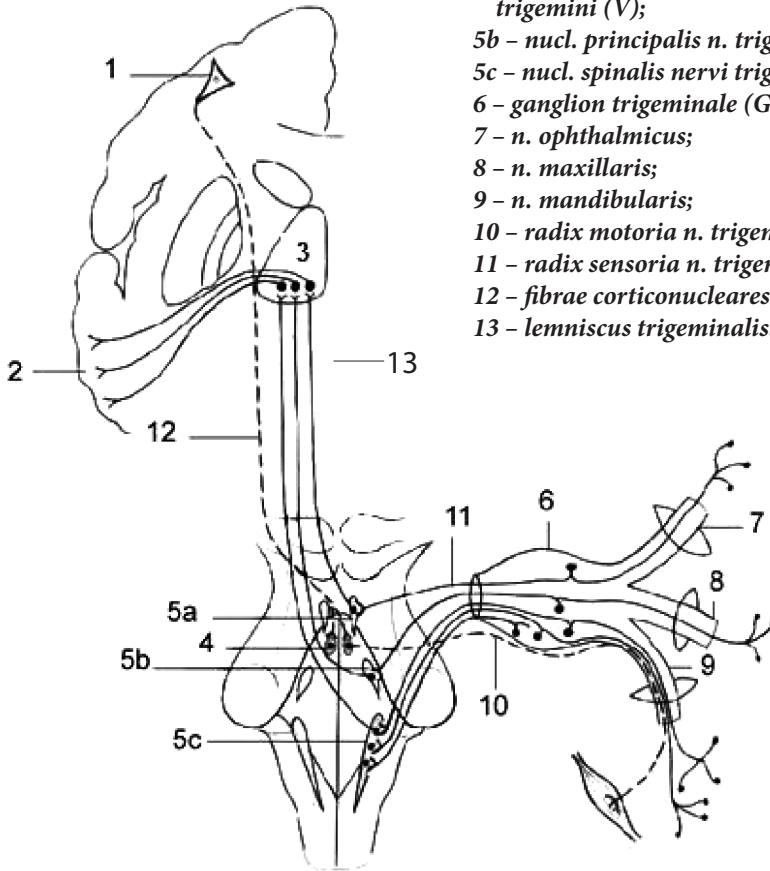
CAILE CONDUCTOARE ALE NERVILOR CRANIENI III, IV, VI
 ПРОВОДЯЩИЕ ПУТИ III, IV, VI ПАР ЧЕРЕПНЫХ НЕРВОВ
 CONDUCTING PATHWAYS OF THE III, IV
 AND VI PAIRS OF CRANIAL NERVES



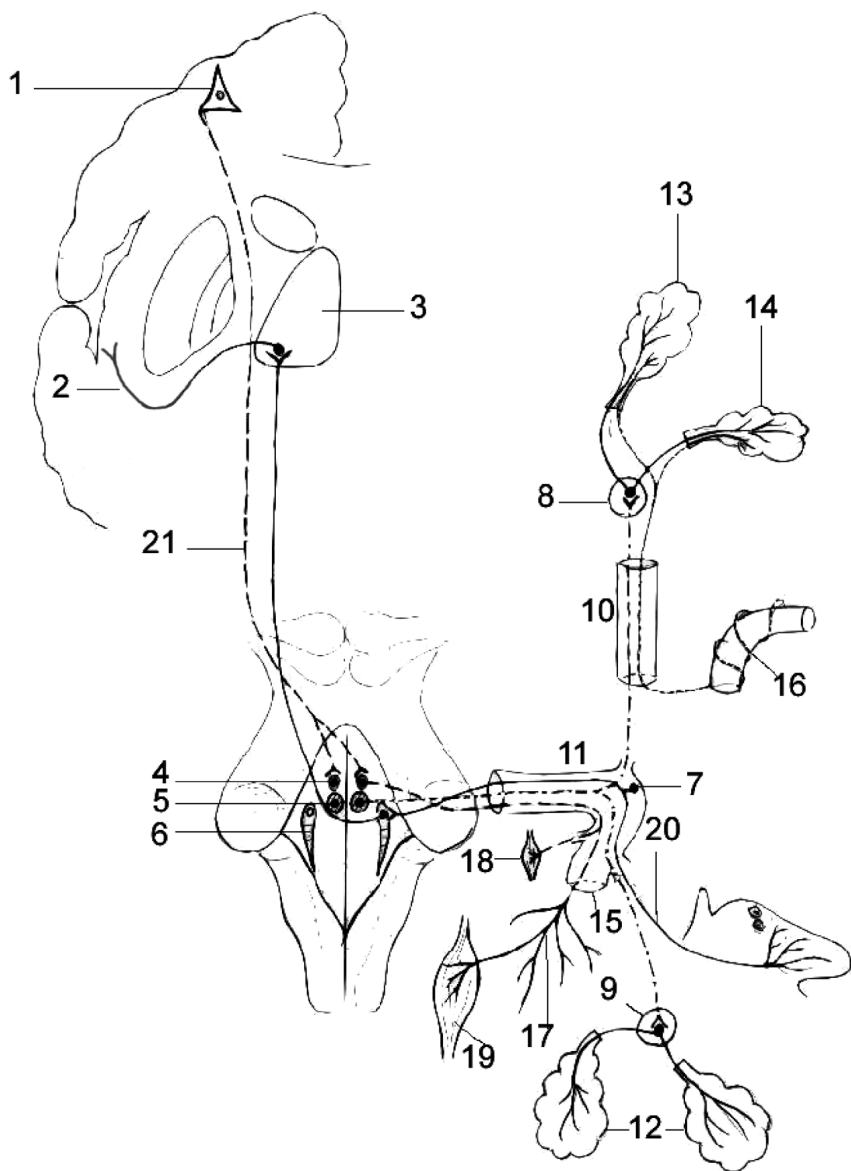
- 1 – *nucl. n. oculomotorii (III)*;
- 2 – *nucl. accessorius n. oculomotorii (Якубович-Edinger-Westfal) (III)*;
- 3 – *nucl. n. trochlearis (IV)*;
- 4 – *nucl. n. abducentis (VI)*;
- 5 – *fissura orbitalis superior*;
- 6 – *ganglion ciliare*;
- 7 – *m. rectus superior bulbi*;
- 8 – *m. levator palpebrae superioris*;
- 9 – *m. rectus lateralis bulbi*;
- 10 – *m. rectus inferior bulbi*;
- 11 – *m. rectus medialis bulbi*;
- 12 – *m. obliquus superior bulbi*;
- 13 – *m. obliquus inferior bulbi*;
- 14 – *m. ciliaris et m. sphincter pupillae*;
- 15 – *neurocytus pyramidalis magnus (Betz)*.

CALEA CONDUCTOARE A NERVULUI TRIGEMEN (V)
 ПРОВОДЯЩИЙ ПУТЬ ТРОЙНИЧНОГО НЕРВА (V)
 CONDUCTING PATHWAYS
 OF THE TRIGEMINAL NERVE (V)

- 1 – neuronum I (neurocytus pyramidalis magnus, Betz) (gyrus precentralis);
- 2 – gyrus postcentralis;
- 3 – neuronum III (thalamus opticus);
- 4 – nucl. motorius n. trigemini (V);
- 5 – nuclei sensoriales n. trigemini (V);
- 5a – nucl. mesencephalicus n. trigemini (V);
- 5b – nucl. principalis n. trigemini (V);
- 5c – nucl. spinalis nervi trigemini (V);
- 6 – ganglion trigeminale (Gasser);
- 7 – n. ophthalmicus;
- 8 – n. maxillaris;
- 9 – n. mandibularis;
- 10 – radix motoria n. trigemini;
- 11 – radix sensoria n. trigemini;
- 12 – fibrae corticonucleares pontis;
- 13 – lemniscus trigeminalis.

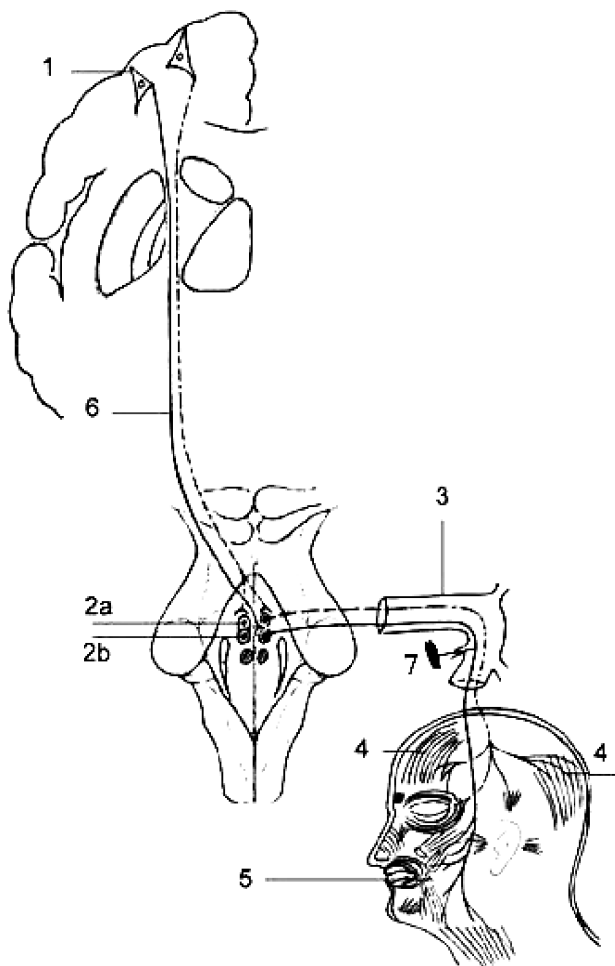


CALEA CONDUCTOARE A NERVULUI FACIAL (VII)
 ПРОВОДЯЩИЙ ПУТЬ ЛИЦЕВОГО НЕРВА (VII)
 CONDUCTING PATHWAYS OF THE FACIAL NERVE (VII)



- 1 – *neuronum I (neurocytus pyramidalis magnus, Betz) (gyrus precentralis);*
- 2 – *cortex insulae et operculum frontoparietalis;*
- 3 – *thalamus;*
- 4 – *nucl. n. facialis (motorius) (neuronum II) (VII);*
- 5 – *nucl. salivatorius superior (VII);*
- 6 – *nucl. tractus solitarii (VII);*
- 7 – *ganglion geniculi;*
- 8 – *ganglion pterygopalatinum;*
- 9 – *ganglion submandibulare et ganglion sublinguale;*
- 10 – *canalis pterygoideus;*
- 11 – *canalis n. facialis (Fallopianus);*
- 12 – *glandulae sublingualis et submandibularis;*
- 13 – *glandula lacrimalis;*
- 14 – *glandulae nasales;*
- 15 – *foramen stylomastoideum;*
- 16 – *plexus caroticus internus;*
- 17 – *plexus parotideus;*
- 18 – *m. stapedius;*
- 19 – *mm. faciei;*
- 20 – *chorda tympani;*
- 21 – *fibrae corticonucleares pontis.*

NERVUL FACIAL (VII). CALEA EFERENTĂ, SOMATOMOTORIE
ЭФФЕРЕНТНЫЙ, ДВИГАТЕЛЬНЫЙ ПУТЬ ЛИЦЕВОГО НЕРВА
EFFERENT, MOTOR PATHWAYS OF THE FACIAL NERVE (VII)



1 - neuronum I (neurocytus pyramidalis magnus, Betz) (gyrus precentralis);

2 - neuronum II (nucl. n. facialis, motorius) (VII);

2a - pars superior;

2b - pars inferior;

3 - canalis n. facialis;

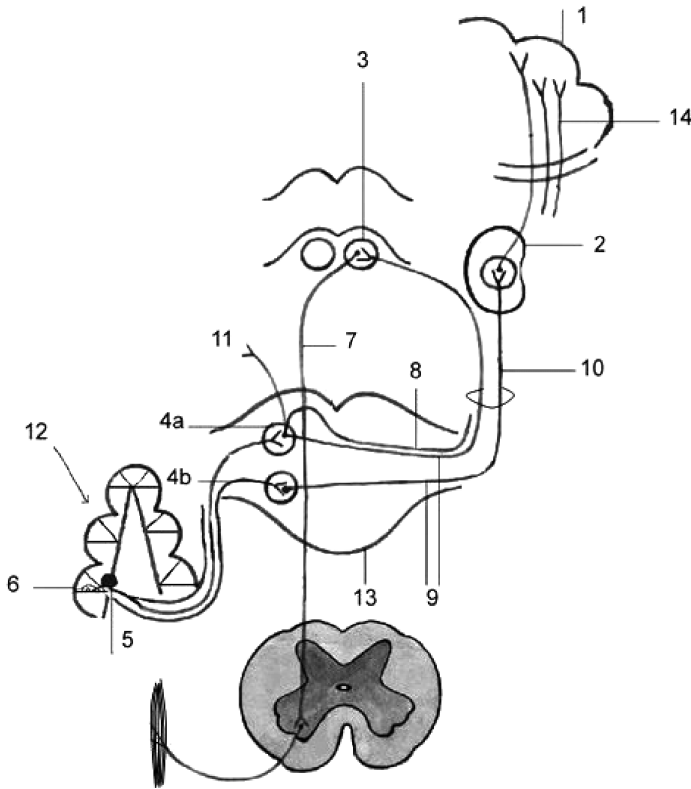
4 - mm. faciei superiores;

5 - mm. faciei inferiores;

6 - fibrae corticonucleares pontis;

7 - m. stapedius.

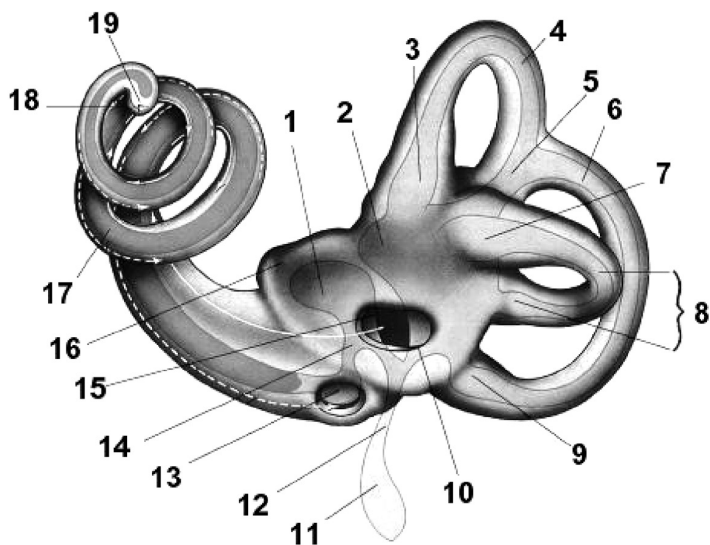
CALEA AUDITIVĂ
 СЛУХОВОЙ ПУТЬ
 AUDITORY PATHWAYS



1 - gyri temporales transversi (Heschl)
 (gyrus temporalis superior);
 2 - neuronum III (corpus geniculatum
 mediale);
 3 - neuronum III (colliculus inferior
 tecti mesencephali);
 4 - neuronum II (nuclei partis
 cochlearis n. vestibulocochlearis):
 4a - nucleus cochlearis posterior;
 4b - nucleus cochlearis anterior;
 5 - neuronum I [ganglion spirale cochleae
 (Corti)];

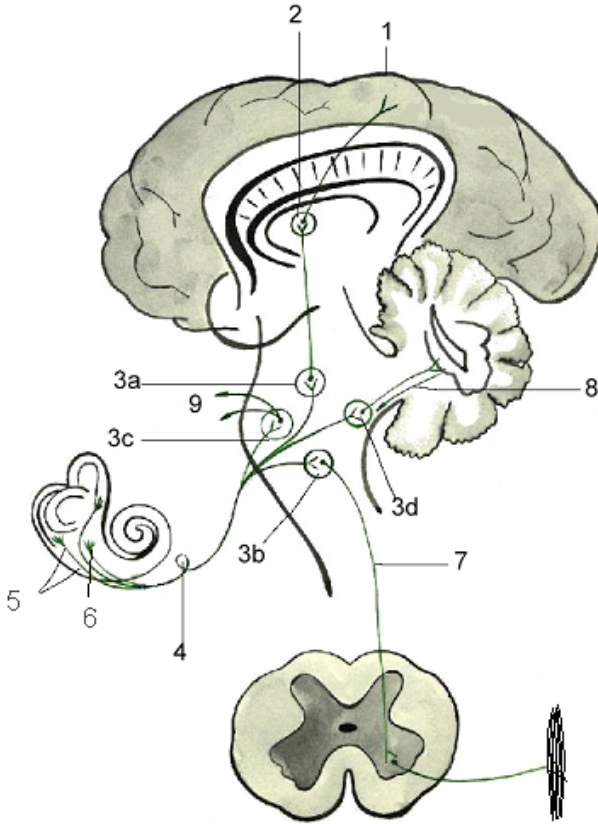
6 - organum spirale Corti
 (epitheliocytus neurosensorius);
 7 - tractus tectospinalis;
 8 - striae medullares ventriculi quarti;
 9 - corpus trapezoideum;
 10 - lemniscus lateralis;
 11 - conexiones ad nervos III, IV, VI;
 12 - cochlea (labyrinthus osseus);
 13 - pons Varolio;
 14 - radiatio acustica.

LABIRINTUL OSOS ȘI MEMBRANOS
 КОСТНЫЙ И ПЕРЕПОНЧАТЫЙ ЛАБИРИНТ
 THE BONY AND MEMBRANOUS LABIRYNTH



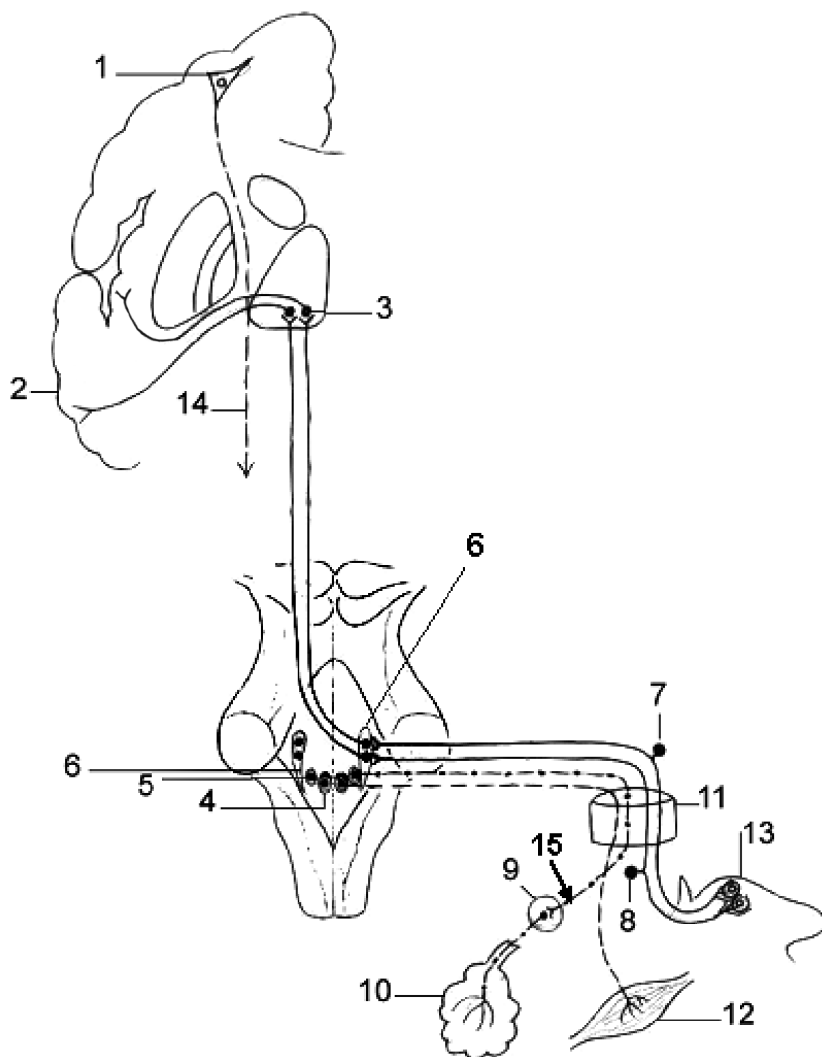
- 1 – *sacculus*;
 2 – *utricle*;
 3 – *ampulla membranacea anterior (ampulla ductus semicircularis anterioris)*;
 4 – *ductus semicircularis anterior*;
 5 – *crus osseum commune*;
 6 – *ductus semicircularis posterior*;
 7 – *ampulla membranacea lateralis (ampulla ductus semicircularis lateralis)*;
 8 – *ductus semicircularis lateralis*;
 9 – *ampulla membranacea posterior (ampulla ductus semicircularis posterioris)*;
 10 – *ductus utriculosaccularis*;
 11 – *saccus endolymphaticus*;
 12 – *ductus endolymphaticus*;
 13 – *fenestra cochleae*;
 14 – *ductus reuniens*;
 15 – *fenestra vestibuli*;
 16 – *vestibulum*;
 17 – *ductus cochlearis*;
 18 – *spatium perilymphaticum*;
 19 – *helicotrema*.

CALEA VESTIBULARĂ
 ВЕСТИБУЛЯРНЫЙ ПУТЬ
 VESTIBULAR PATHWAYS



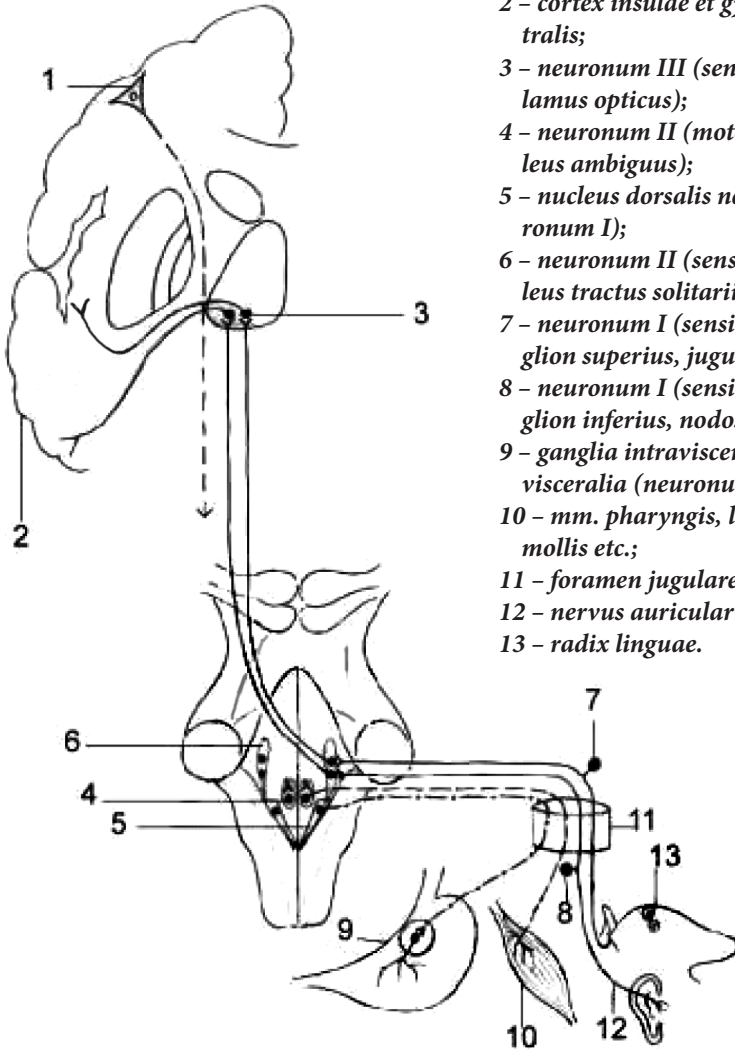
- 1 - lobus parietalis, lobus temporalis;
 2 - neuronum III (thalamus);
 3 - neuronum II - nuclei vestibulares:
 a - superior (Бехмецев); b - inferior (Roller);
 c - lateralis (Deiters); d - medialis (Schwalbe);
 4 - ganglion vestibulare (Scarpa) (neuronum I);
 5 - cristae ampullares;
 6 - macula utriculi et macula sacculi;
 7 - tractus vestibulospinalis;
 8 - fasciculus vestibulocerebellaris et fasciculus cerebellovestibularis;
 9 - conexiones ad nervos craniales IX, X et III, IV, VI.

CALEA CONDUCTOARE A NERVULUI GLOsofarINGIAN (IX)
 ПРОВОДЯЩИЙ ПУТЬ ЯЗЫКОГЛОТочНОГО НЕРВА (IX)
 CONDUCTING PATHWAYS OF THE GLOSSOPHARYNGEAL NERVE (IX)



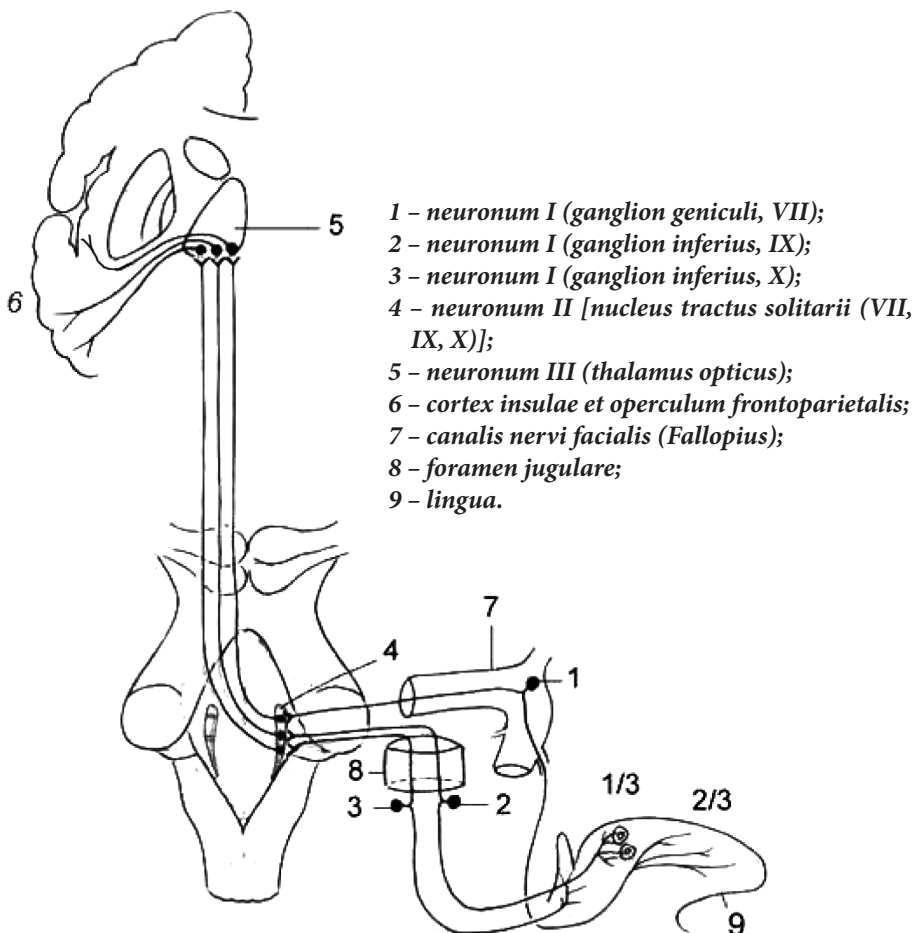
- 1 – neuronum I, motorium (gyrus precentralis, neurocytus pyramidalis magnus, Betz);
- 2 – insula et gyrus postcentralis;
- 3 – neuronum III (thalamus);
- 4 – neuronum II, motorium (nucleus ambiguus);
- 5 – nucleus salivatorius inferior (neuronum I);
- 6 – neuronum II, sensitivum (nucleus tractus solitarii);
- 7 – neuronum I, sensitivum (ganglion superius);
- 8 – neuronum I, sensitivum (ganglion inferius);
- 9 – ganglion oticum;
- 10 – glandula parotidea;
- 11 – foramen jugulare;
- 12 – ramus musculi stylopharyngei;
- 13 – 1/3 pars posterior linguae (papillae valatae);
- 14 – fibrae corticonucleares;
- 15 – nervus tympanicus (n. petrosus minor).

CALEA CONDUCTOARE A NERVULUI VAG (X)
ПРОВОДЯЩИЙ ПУТЬ БЛУЖДАЮЩЕГО НЕРВА (X)
CONDUCTING PATHWAYS OF THE VAGUS NERVE (X)

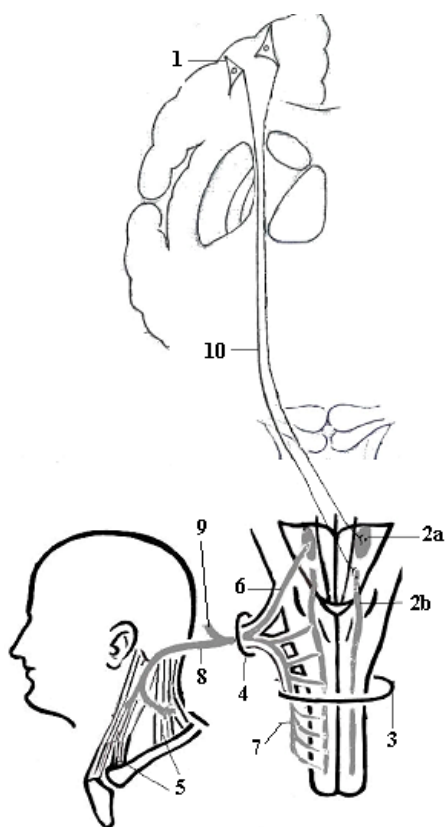


- 1 - neuronum I (motorium) (gyrus precentralis, neurocytus pyramidalis magnus, Betz);
- 2 - cortex insulae et gyrus postcentralis;
- 3 - neuronum III (sensitivum) (thalamus opticus);
- 4 - neuronum II (motorium) (nucleus ambiguus);
- 5 - nucleus dorsalis nervi vagi (neuronum I);
- 6 - neuronum II (sensitivum) (nucleus tractus solitarii);
- 7 - neuronum I (sensitivum) (ganglion superius, jugulare);
- 8 - neuronum I (sensitivum) (ganglion inferius, nodosum);
- 9 - ganglia intravisceralia et paravisceralia (neuronum II);
- 10 - mm. pharyngis, laryngis, palati mollii etc.;
- 11 - foramen jugulare;
- 12 - nervus auricularis posterior;
- 13 - radix linguae.

CALEA CONDUCTOARE A ANALIZATORULUI GUSTATIV
 ПРОВОДЯЩИЙ ПУТЬ ВКУСА
 PATHWAYS OF THE TASTE ANALYSER



CALEA CONDUCTOARE A NERVULUI ACESOR (XI)
ПРОВОДЯЩИЙ ПУТЬ ДОБАВОЧНОГО НЕРВА (XI)
CONDUCTING PATHWAYS OF THE ACCESSORY NERVE (XI)



1 - neuronum I (gyrus precentralis, neurocytus pyramidalis magnus, Betz);

2 - neuronum II (nuclei motorii):
 a - nucleus ambiguus (IX, X, XI);
 b - nucleus nervi accessorii (XI);

3 - foramen magnum;

4 - foramen jugulare;

5 - mm. sternocleidomastoideus et trapezius;

6 - radices craniales nervi accessorii;

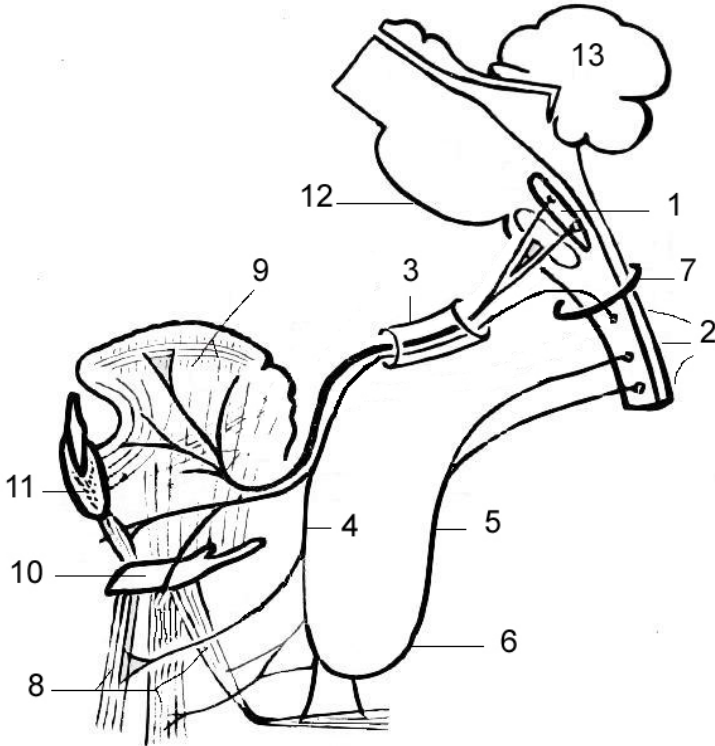
7 - radices spinales nervi accessorii;

8 - ramus externus;

9 - ramus internus;

10 - fibrae corticonucleares.

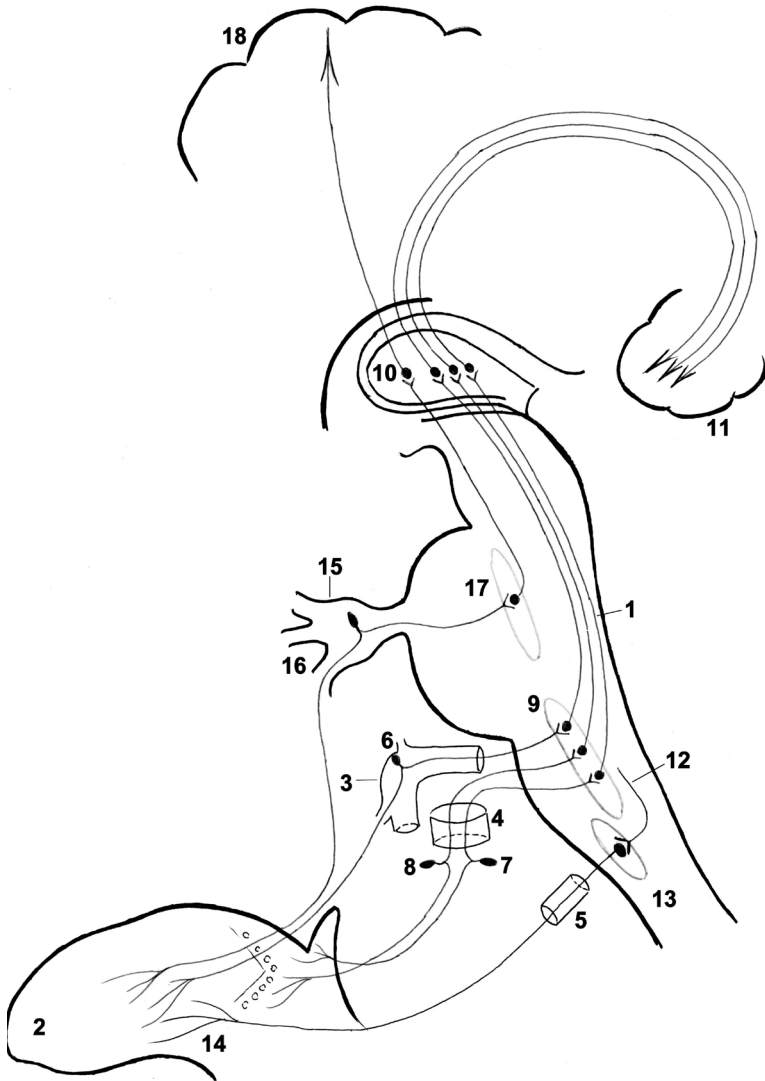
CALEA CONDUCTOARE A NERVULUI HIPOGLOS (XII)
 ПРОВОДЯЩИЙ ПУТЬ ПОДЪЯЗЫЧНОГО НЕРВА (XII)
 CONDUCTING PATHWAYS OF THE HYPOGLOSSAL NERVE (XII)



- 1 - nucleus nervi hypoglossi;
 2 - medulla spinalis (C₁, C₂, C₃);
 3 - canalis nervi hypoglossi;
 4 - radix superior ansae cervicalis;
 5 - radix inferior ansae cervicalis;
 6 - ansa cervicalis;
 7 - foramen magnum;

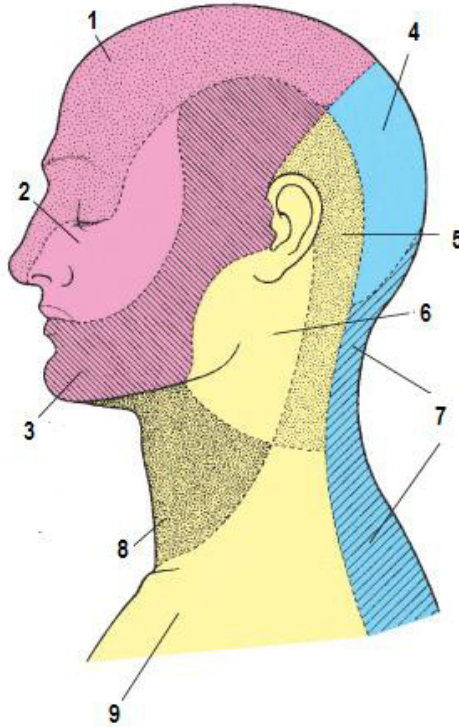
- 8 - mm. infrahyoidei;
 9 - rami linguales (musculi linguae);
 10 - os hyoideum;
 11 - mandibula;
 12 - truncus cerebri;
 13 - cerebellum.

INERVAȚIA LIMBII
ИННЕРВАЦИЯ ЯЗЫКА
INNERVATION OF THE TONGUE



- 1 – *truncus cerebri*;
- 2 – *lingua*;
- 3 – *canalis nervi facialis (Falloppio)*;
- 4 – *foramen jugulare*;
- 5 – *canalis n. hypoglossi*;
- 6 – *neuronum I (ganglion geniculi, VII)*;
- 7 – *neuronum (ganglion inferius, IX)*;
- 8 – *neuronum I (ganglion inferius, X)*;
- 9 – *neuronum II [nucl. tractus solitarii (VII, IX, X)]*;
- 10 – *neuronum III (thalamus)*;
- 11 – *cortex insulae et operculum frontoparietalis*;
- 12 – *fibrae corticonucleares*;
- 13 – *nucl. n. hypoglossi (XII)*;
- 14 – *rami linguales (musculi linguae)*;
- 15 – *neuronum I (ganglion trigeminale, Gasser)*;
- 16 – *n. mandibularis*;
- 17 – *neuronum II – nuclei sensoriales n. trigemini (V) (nucll. mesencephalicus, principalis, spinalis)*;
- 18 – *gyrus postcentralis*.

ZONELE DE INERVAȚIE A PIELII CAPULUI ȘI GÂTULUI
ИННЕРВАЦИЯ КОЖИ ЛИЦА И ШЕИ
INNERVATION OF THE SKIN OF THE FACE AND NECK



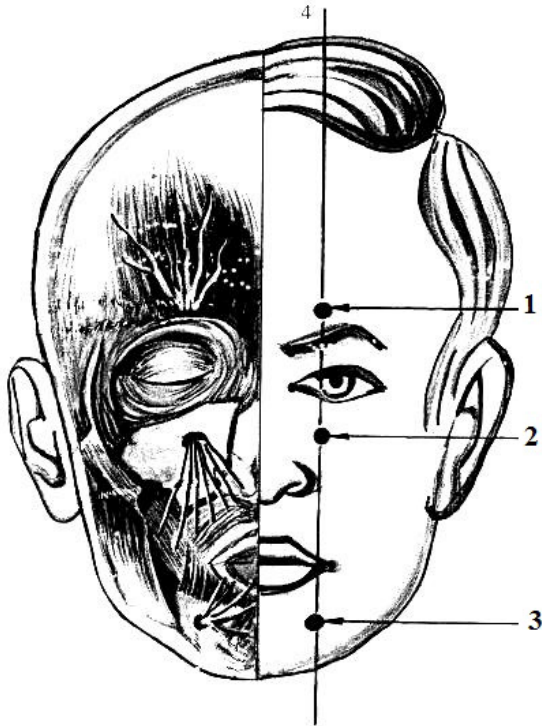
- 1 – *n. ophthalmicus (n. trigeminus, V)*;
- 2 – *n. maxillaris (n. trigeminus, V)*;
- 3 – *n. mandibularis (n. trigeminus, V)*;
- 4 – *n. occipitalis major (rami dorsales nervorum spinalium C₂-C₃)*;
- 5 – *n. occipitalis minor (plexus cervicalis)*;
- 6 – *n. auricularis magnus (plexus cervicalis)*;
- 7 – *rami dorsales nervorum spinalium (C₃-C₅)*;
- 8 – *n. transversus colli (plexus cervicalis)*;
- 9 – *nn. supraclaviculares (plexus cervicalis)*.

LINEA DE IEȘIRE A RAMURILOR NERVULUI TRIGEMEN (4)

(după В.И. Лабзин, А.А. Родионов, 2005)

ЛИНИЯ ВЫХОДА ВЕТВЕЙ ТРОЙНИЧНОГО НЕРВА (4)

THE OUTLET LINE OF THE TRIGEMINAL NERVE (4)

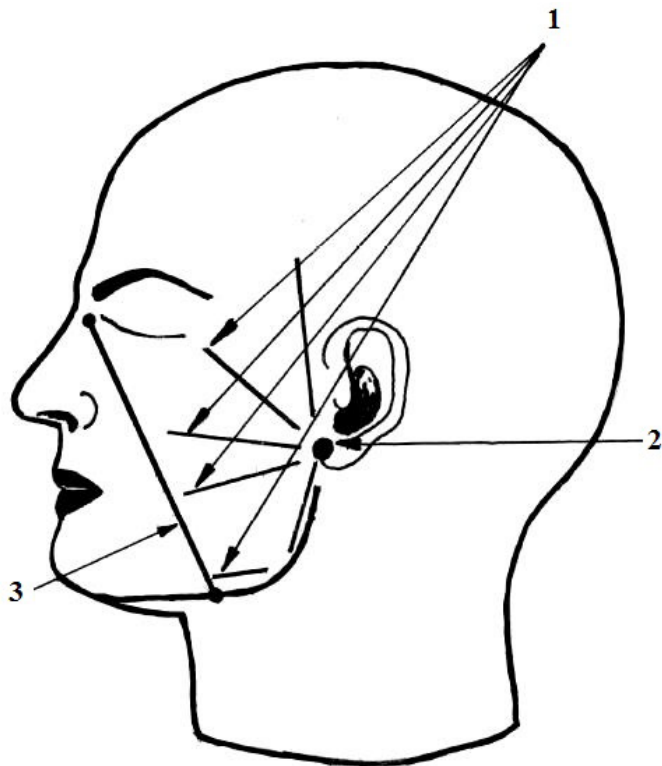


1 – punctum nervi supraorbitalis;

2 – punctum nervi infraorbitalis;

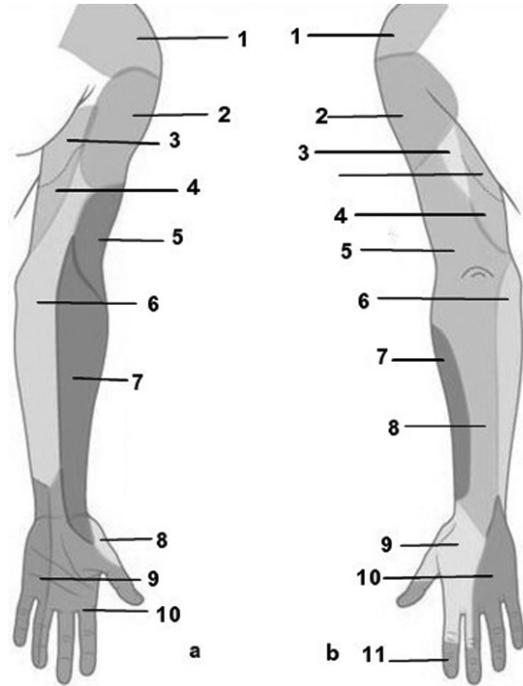
3 – punctum nervi mentalis.

LINII DE PROIECȚIE ȘI PUNCTE DE REFERINȚĂ PE FAȚĂ
(după В.И. Лабзин, А.А. Родионов, 2005)
ПРОЕКЦИОННЫЕ ЛИНИИ И ТОЧКИ НА ЛИЦЕ
THE PROJECTION LINES AND REFERENCE POINTS ON THE FACE



- 1 - *punctum trunci basalis nervi facialis;*
2 - *lineae prolectiae ramorum terminalium nervi facialis;*
3 - *linea prolectiae arteriae facialis.*

ZONELE DE INERVAȚIE A PIELII MEMBRULUI SUPERIOR
ИННЕРВАЦИЯ КОЖИ ВЕРХНЕЙ КОНЕЧНОСТИ
INNERVATION OF THE SKIN OF THE UPPER LIMB



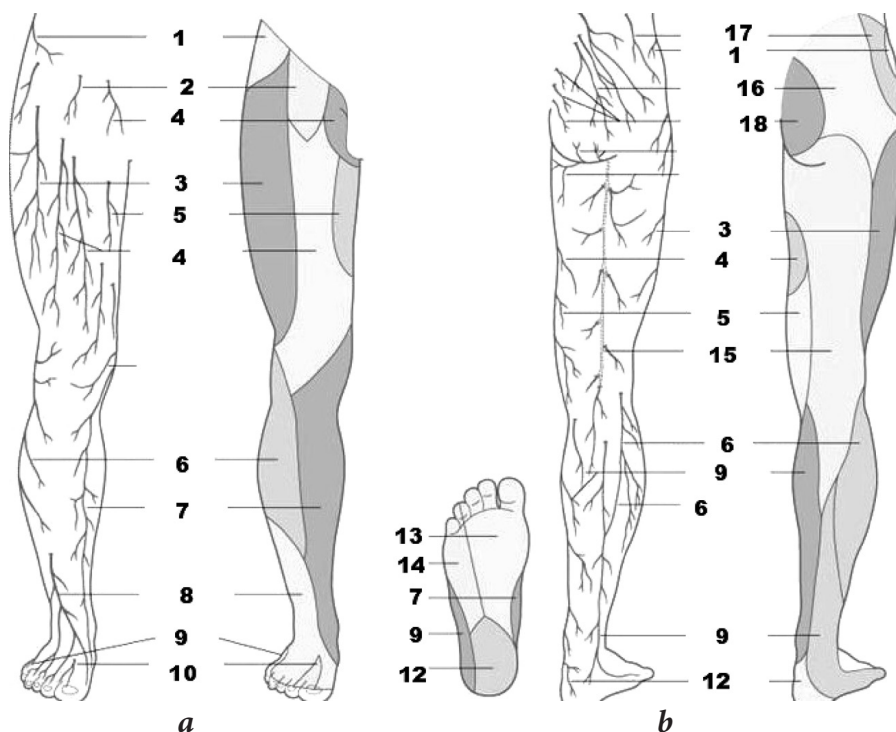
a – facies anterior:

- 1 – *nn. supraclaviculares;*
- 2 – *n. cutaneus brachii lateralis superior (n. axillaris);*
- 3 – *rami cutanei laterales (nn. intercostobrachiales);*
- 4 – *n. cutaneus brachii medialis;*
- 5 – *n. cutaneus brachii posterior (n. radialis);*
- 6 – *n. cutaneus antebrachii medialis;*
- 7 – *n. cutaneus antebrachii lateralis;*
- 8 – *ramus superficialis (n. radialis);*
- 9 – *ramus palmaris (n. ulnaris);*
- 10 – *n. medianus;*

b – facies posterior:

- 1 – *nn. supraclaviculares;*
- 2 – *n. cutaneus brachii lateralis superior (n. axillaris);*
- 3 – *rami cutanei laterales (nn. intercostobrachiales);*
- 4 – *n. cutaneus brachii medialis;*
- 5 – *n. cutaneus antebrachii posterior (n. radialis);*
- 6 – *n. cutaneus antebrachii medialis;*
- 7 – *n. cutaneus antebrachii lateralis (n. musculocutaneus);*
- 8 – *n. cutaneus antebrachii posterior (n. radialis);*
- 9 – *r. superficialis (n. radialis);*
- 10 – *r. dorsalis (n. ulnaris);*
- 11 – *n. medianus.*

INERVAȚIA PIELII MEMBRULUI INFERIOR
ИННЕРВАЦИЯ КОЖИ НИЖНЕЙ КОНЕЧНОСТИ
INNERVATION OF THE SKIN OF THE LOWER LIMB

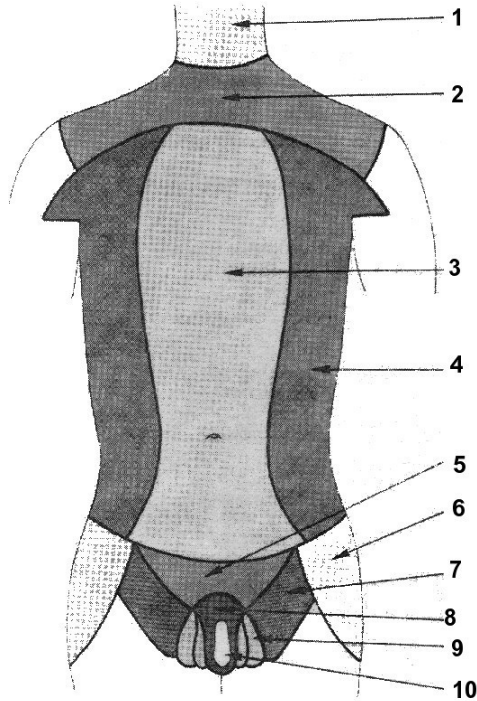


a – facies anterior;
b – facies posterior.

- 1 – *r. cutaneus lateralis*
(*n. iliohypogastricus*);
- 2 – *r. femoralis n. genitofemoralis*;
- 3 – *n. cutaneus femoris lateralis*;
- 4 – *rr. cutanei anteriores*
(*n. femoralis*);
- 5 – *r. cutaneus (n. obturatorius)*;
- 6 – *n. cutaneus surae lateralis*
(*n. peroneus communis*);
- 7 – *n. saphenus (n. femoralis)*;
- 8 – *n. peroneus superficialis*;

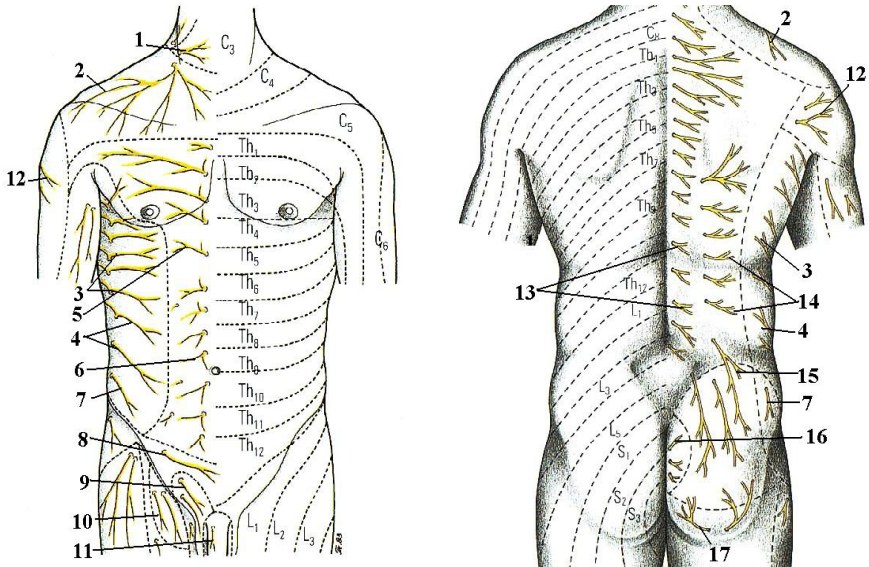
- 9 – *n. suralis*;
- 10 – *n. peroneus profundus*;
- 11 – *n. cutaneus surae medialis*;
- 12 – *n. tibialis*;
- 13 – *n. plantaris medialis*;
- 14 – *n. plantaris lateralis*;
- 15 – *n. cutaneus femoris posterior*;
- 16 – *nn. clunium inferiores*;
- 17 – *nn. clunium superiores*;
- 18 – *nn. clunium medii*.

**ZONELE DE INERVAȚIE CUTANATĂ
A FEȚEI ANTERIOARE A TRUNCHIULUI
ЗОНЫ КОЖНОЙ ИННЕРВАЦИИ
ПЕРЕДНЕЙ ПОВЕРХНОСТИ ТУЛОВИЩА
CUTANEOUS NERVES OF THE TRUNK**



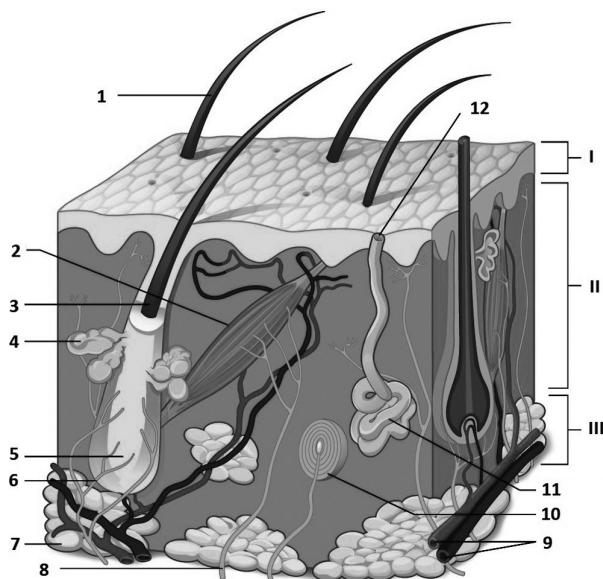
- 1 – *n. transversus colli (plexus cervicalis)*;
- 2 – *nn. supraclaviculares*;
- 3 – *rr. cutanei anteriores*;
- 4 – *rr. cutanei laterales (nn. intercostobrachiales)*;
- 5 – *r. cutaneus anterior (n. iliohypogastricus)*;
- 6 – *r. cutaneus lateralis (n. iliohypogastricus)*;
- 7 – *r. femoralis (n. genitofemoralis)*;
- 8 – *n. ilioinguinalis*;
- 9 – *r. genitalis (n. genitofemoralis)*;
- 10 – *rr. scrotales anteriores (n. ilioinguinalis)*.

**NERVII CUTANAȚI AI TRUNCHIULUI
ȘI REGIUNILE LOR DE DISTRIBUIRE**
ОБЛАСТИ РАСПРОСТРАНЕНИЯ КОЖНЫХ НЕРВОВ ТУЛОВИЩА
**REGIONS OF DISTRIBUTION OF THE CUTANEOUS
NERVES OF THE TRUNK**



- 1 – n. transversus colli (plexus cervicalis);
- 2 – nn. supraclaviculares (plexus cervicalis);
- 3 – rr. cutanei laterales pectorales nn. intercostalium;
- 4 – rr. cutanei laterales abdominales nn. intercostalium;
- 5 – rr. cutanei anteriores pectorales nn. intercostalium;
- 6 – rr. cutanei anteriores abdominales nn. intercostalium;
- 7 – r. cutaneus lateralis n. iliohypogastrici (plexus lumbalis);
- 8 – r. cutaneus anterior n. iliohypogastrici (plexus lumbalis);
- 9 – n. ilioinguinalis (plexus lumbalis);
- 10 – r. femoralis n. genitofemoralis (plexus lumbalis);
- 11 – n. dorsalis penis (n. pudendus, plexus sacralis);
- 12 – n. cutaneus brachii lateralis superior (n. axillaris, plexus brachialis);
- 13 – rr. cutanei mediales (rr. posteriores nn. thoracicorum);
- 14 – rr. cutanei laterales (rr. posteriores nn. thoracicorum);
- 15 – nn. clunium superiores (rr. posteriores nn. lumbalium);
- 16 – nn. clunium medii (rr. posteriores nn. sacralium);
- 17 – nn. clunium inferiores (n. cutaneus femoris posterior, plexus sacralis).

SRUCTURA PIELII
СТРОЕНИЕ КОЖИ
THE STRUCTURE OF THE SKIN



I - epidermis;
II - dermis;
III - hypodermis.

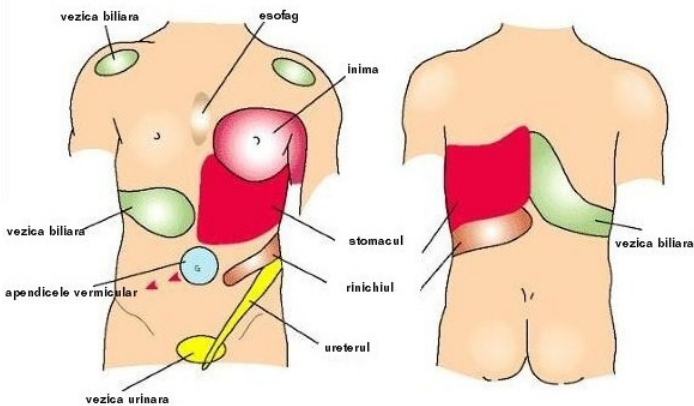
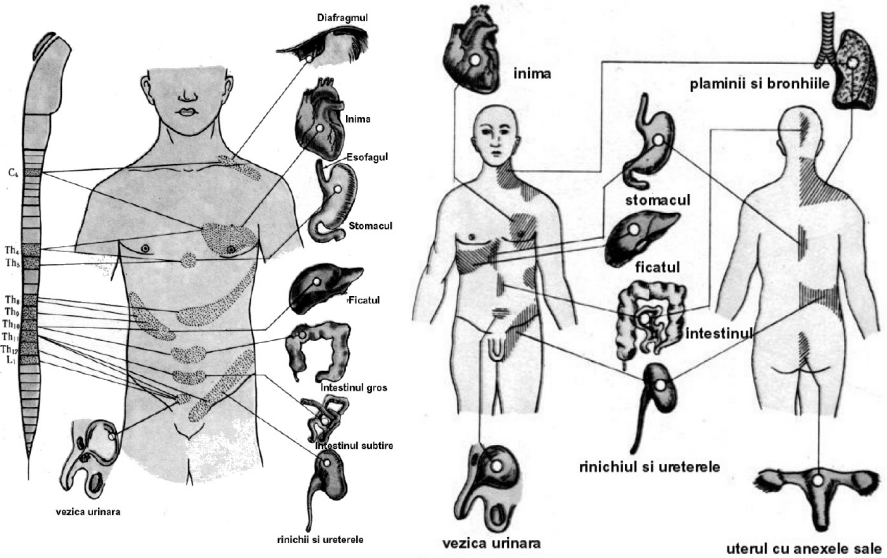
1 - pilus;
2 - m. errector pili;
3 - folliculus pili;
4 - glandula sebacea;
5 - radix;
6 - terminationes nervorum;
7 - textus (tela) adiposus;
8 - fibra nervosa sensitiva;
9 - vasa sanguinea;
10 - corpusculus Vater-Pacini;
11 - glandula sudorifera;
12 - porus glandulae sudoriferae;

ZONELE ZAHARIN-HEAD – ARIILE CUTANATE DE DURERE REFERITĂ ÎN AFECȚIUNILE VISCERELOR. LEGĂTURA LOR CU SEGMENTELE MĂDUVEI SPINĂRII

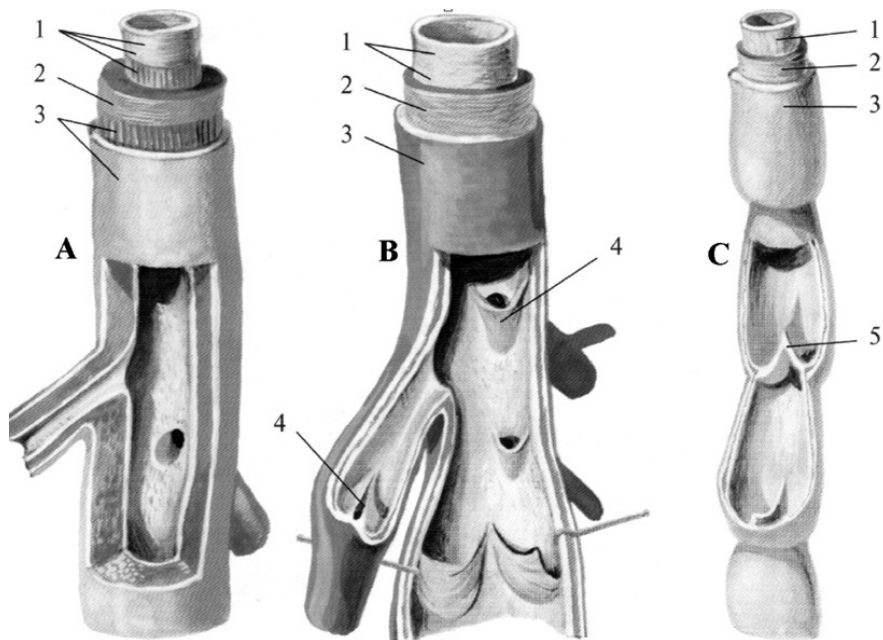
ЗОНЫ ZAHARIN-HEAD – УЧАСТКИ КОЖНОЙ БОЛЕВОЙ ЧУВСТВИТЕЛЬНОСТИ ПРИ ПОРАЖЕНИИ ВНУТРЕННИХ ОРГАНОВ.

ИХ СВЯЗЬ С СЕГМЕНТАМИ СПИННОГО МОЗГА

THE ZAHARIN-HEAD ZONES – THE CUTANEOUS AREAS OF REFLECTED PAIN IN VISCERAL DISEASES AND THEIR RELATIONSHIPS WITH THE SPINAL CORD SEGMENTS

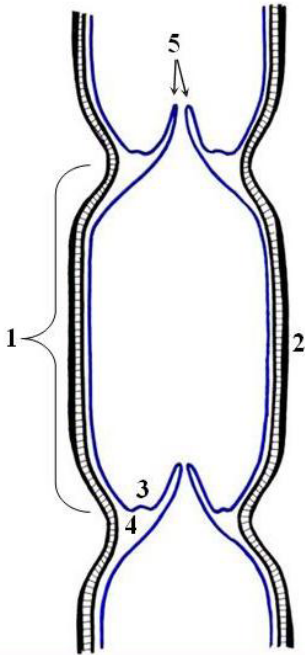


**STRUCTURA PERETELUI ARTEREI (A), VENEI (B)
 ȘI VASULUI LIMFATIC (C)
 СТРОЕНИЕ СТЕНКИ АРТЕРИИ (А), ВЕНЫ (В)
 И ЛИМФАТИЧЕСКОГО СОСУДА (С)
 STRUCTURE OF THE WALLS OF THE ARTERY (A), OF THE VEIN (B)
 AND OF THE LYMPH VESSEL (C)**



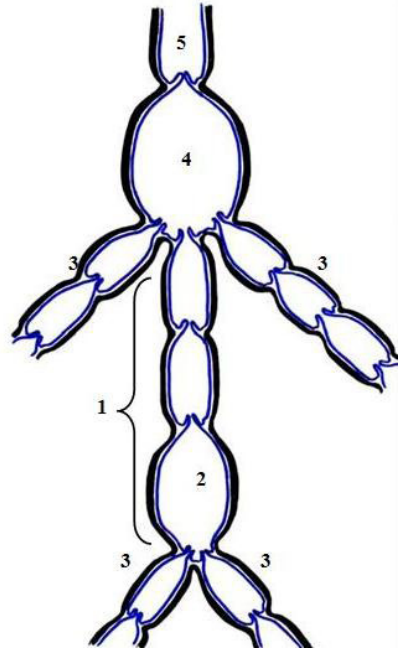
- 1 - tunica intima;
- 2 - tunica media;
- 3 - tunica externa;
- 4 - valvula venosa;
- 5 - valvula lymphatica.

STRUCTURA MICROSEGMENTULUI (LIMFANGIONULUI)
 ŞI MACROMICROSEGMENTULUI VASULUI LIMFATIC
 СТРОЕНИЕ МИКРОСЕКМЕНТА (ЛИМФАНГИОНА) И
 МАКРОМИКРОСЕКМЕНТА ЛИМФАТИЧЕСКОГО СОСУДА
 STRUCTURE OF THE MICROSEGMENT (LYMPHANGION) AND OF THE
 MACROMICROSEGMENT OF THE LYMPH VESSEL



A

- A
 1 - *lymphangion*;
 2 - *vagina muscularis*;
 3 - *sinus valvularis*;
 4 - *labrium*;
 5 - *valvulae*.



B

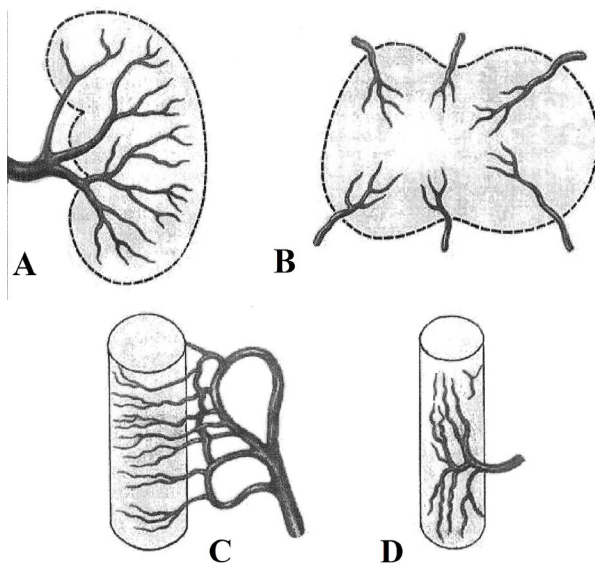
- B
 1 - *macromicrosegmentum lymphaticum*;
 2 - *cisterna caudalis*;
 3 - *vasa afferentia*;
 4 - *cisterna cranialis*;
 5 - *vas efferens*.

TIPURI DE RAMIFICARE A ARTERELOR ÎN DIFERITE ORGANE

(după M.R. Sapin)

ТИПЫ ВЕТВЛЕНИЯ АРТЕРИЙ В РАЗЛИЧНЫХ ОРГАНАХ

TYPES OF ARTERIAL BRANCHING WITHIN DIFFERENT ORGANS



A – de la hilul organului spre periferie (rinichi, ficat);

B – orientare radiară, de la periferie spre centrul organului (epifizele oaselor, măduva spinării);

C – orientare transversală (circulară) a arterelor (intestine);

D – orientare longitudinală a arterelor (mușchi, ureter).

A – по направлению от ворот органа к его периферии (почки, печень);

B – радиарное направление артериальных ветвей в органе (эпифизы костей, спинной мозг);

C – поперечное (круговое) направление артериальных ветвей (кишечник);

D – продольное направление артериальных ветвей (мышцы, мочеточник).

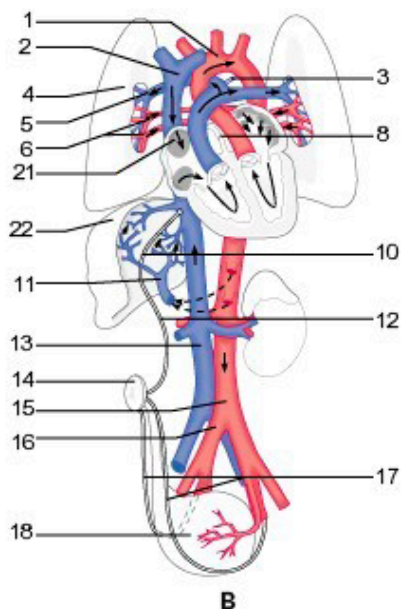
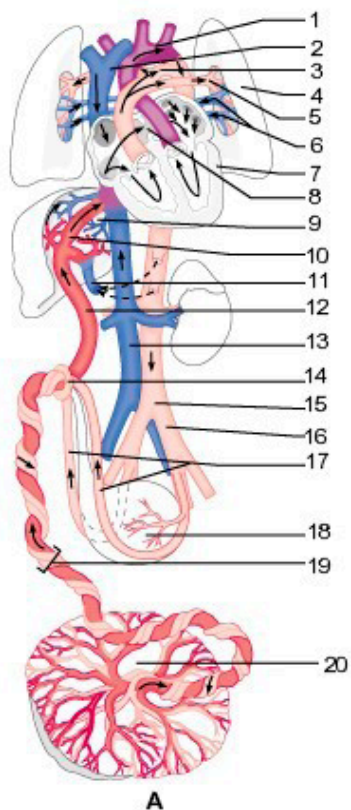
A – from the hilum of the organ toward the periphery (kidney, liver);

B – radial orientation of the arterial branches from the periphery toward the center of the organ (bony epiphyses, spinal cord);

C – transversal orientation (circular) of the arteries (intestine);

D – longitudinal orientation of the arteries (muscles, ureter).

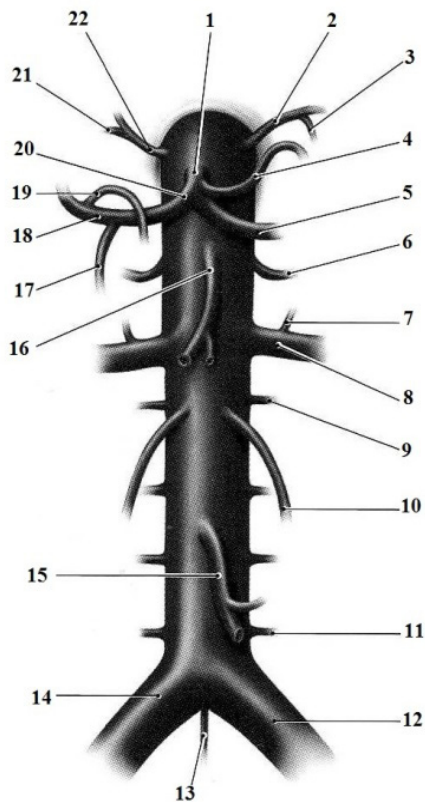
CIRCULAȚIA FETOPLACENTARĂ (A) ȘI CEA POSTNATALĂ (B)
СХЕМЫ КРОВООБРАЩЕНИЯ ПЛОДА (А) И ПОСЛЕ РОЖДЕНИЯ (В)
BLOOD CIRCULATION IN FOETUS (A)
AND POSTNATAL CIRCULATION (B)



- 1 - arcus aortae;
- 2 - v. cava superior;
- 3 - ductus arteriosus / lig. arteriosum;
- 4 - pulmo;
- 5 - a. pulmonalis;
- 6 - vv. pulmonales;
- 7 - cor;
- 8 - foramen ovale / fossa ovalis;
- 9, 22 - hepar;

- 10 - ductus venosus (Aranzi)/
lig. venosum;
- 11 - v. portae;
- 12 - v. umbilicalis;
- 13 - v. cava inferior;
- 14 - umbilicus;
- 15 - aorta abdominalis;
- 16 - a. iliaca communis;
- 17 - aa. umbilicales / ligg. umbilicalia
media;
- 18 - vesica urinaria;
- 19 - funiculus umbilicalis;
- 20 - placenta;
- 21 - ostium v. cavae superioris.

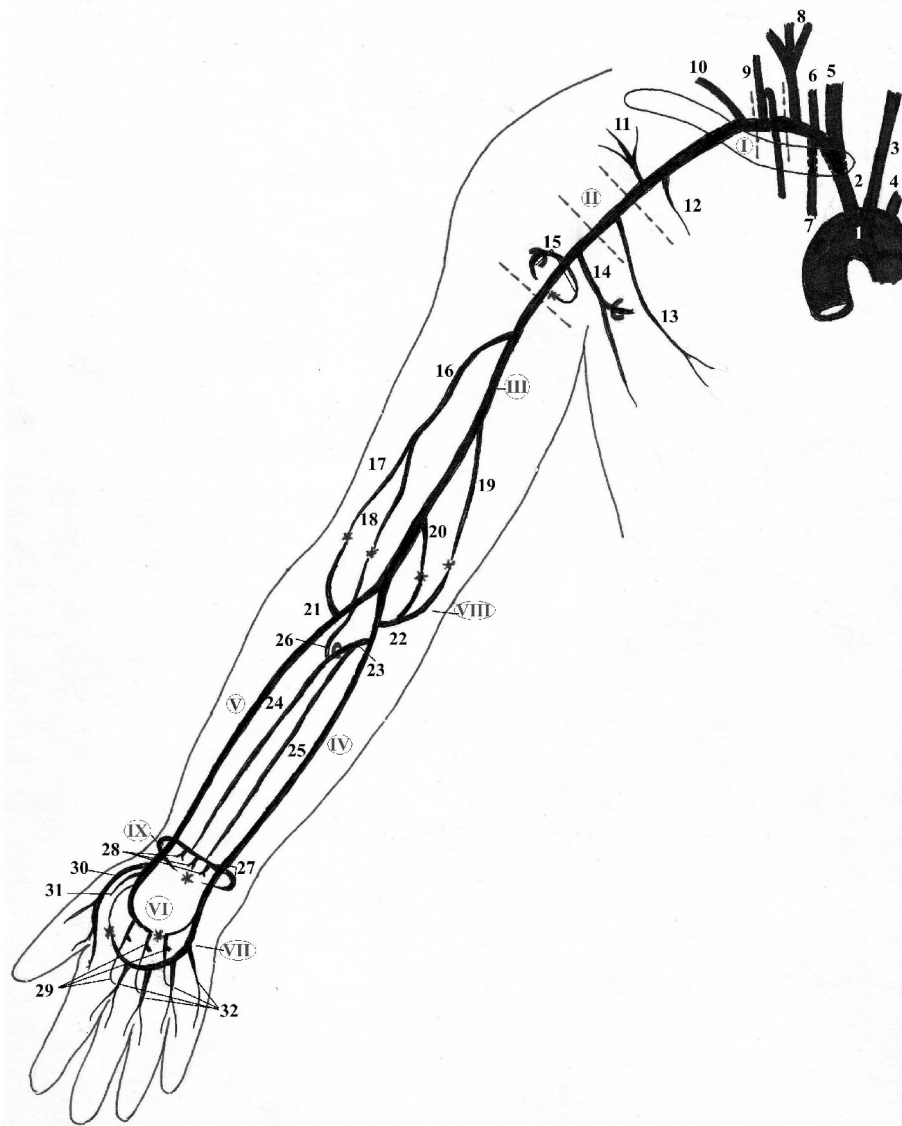RAMURILE AORTEI ABDOMINALE
ВЕТВИ БРЮШНОЙ АОРТЫ
BRANCHES OF THE ABDOMINAL AORTA



- 1 – truncus coeliacus;*
- 2 – arteria phrenica inferior sinistra;*
- 3 – arteria suprarenalis superior sinistra;*
- 4 – arteria gastrica sinistra;*
- 5 – arteria lienalis (splenica);*
- 6 – arteria suprarenalis media sinistra;*
- 7 – arteria suprarenalis inferior sinistra;*
- 8 – arteria renalis sinistra;*
- 9 – arteria lumbalis sinistra prima;*
- 10 – arteria testicularis / ovarica sinistra;*
- 11 – arteria lumbalis sinistra quarta;*
- 12 – arteria iliaca communis sinistra;*

- 13 – arteria sacralis mediana;*
- 14 – arteria iliaca communis dextra;*
- 15 – arteria mesenterica inferior;*
- 16 – arteria mesenterica superior;*
- 17 – arteria gastroduodenalis;*
- 18 – arteria hepatica propria;*
- 19 – arteria gastrica dextra;*
- 20 – arteria hepatica communis;*
- 21 – arteria suprarenalis superior dextra;*
- 22 – arteria phrenica inferior dextra.*

ARTERELE MEMBRULUI SUPERIOR
 АРТЕРИИ ВЕРХНЕЙ КОНЕЧНОСТИ
 ARTERIES OF THE UPPER LIMB

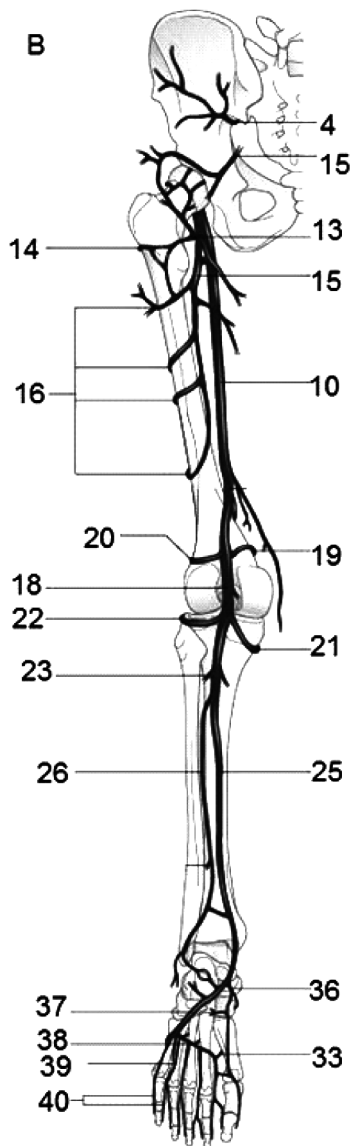
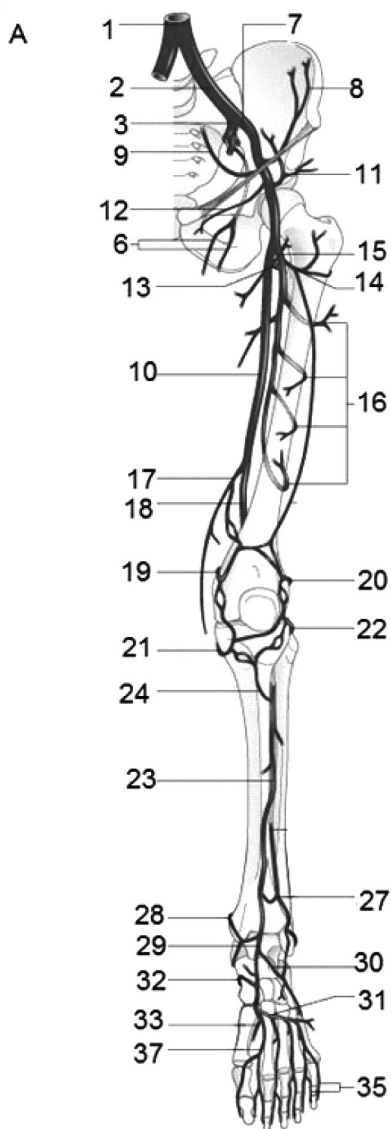


I – a. subclavia;
II – a. axillaris;
III – a. brachialis;
IV – a. ulnaris;
V – a. radialis;
VI – arcus palmaris profundus;
VII – arcus palmaris superficialis;
VIII – rete articulare cubiti;
IX – rete carpale dorsale.

1 – arcus aortae;
2 – truncus brachiocephalicus;
3 – a. carotis communis sinistra;
4 – a. subclavia sinistra;
5 – a. carotis communis dextra;
6 – a. vertebralis;
7 – a. thoracica interna;
8 – tr. thyrocervicalis;
9 – tr. costocervicalis;
10 – a. transversa colli;
11 – a. thoracoacromialis;
12 – a. thoracica superior;
13 – a. thoracica lateralis;
14 – a. subscapularis (a. circumflexa scapulae et a. thoracodorsalis);

15 – aa. circumflexae humeri anterior et posterior;
16 – a. profunda brachii;
17 – a. collateralis radialis;
18 – a. collateralis media;
19 – a. collateralis ulnaris superior;
20 – a. collateralis ulnaris inferior;
21 – a. recurrens radialis;
22 – a. recurrens ulnaris (rr. anterior et posterior);
23 – a. interossea communis;
24 – a. interossea posterior;
25 – a. interossea anterior;
26 – a. interossea recurrens;
27 – r. carpeus palmaris et r. carpeus dorsalis (rete carpale dorsale);
28 – aa. metacarpeae dorsales (aa. digitales dorsales);
29 – aa. metacarpeae palmares (aa. perforantes);
30 – a. metacarpea dorsalis prima;
31 – a. princeps pollicis;
32 – aa. digitales palmares communes (aa. digitales palmares propriae).

ARTERELE MEMBRULUI INFERIOR
АРТЕРИИ НИЖНЕЙ КОНЕЧНОСТИ
ARTERIES OF THE LOWER LIMB

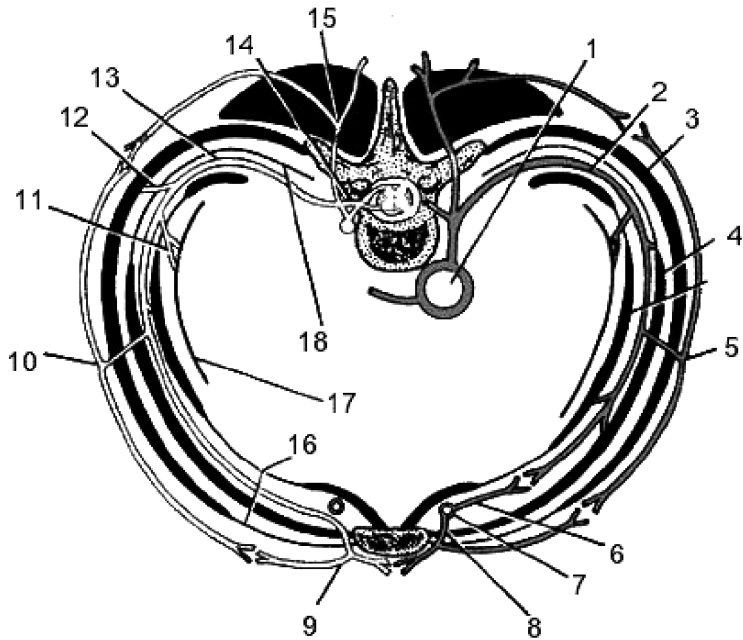


- 1 – *aorta*;
- 2 – *a. iliaca communis*;
- 3 – *a. iliaca interna*;
- 4 – *a. glutea superior*;
- 5 – *a. glutea inferior*;
- 6 – *a. obturatoria*;
- 7 – *a. iliaca externa*;
- 8 – *a. circumflexa ilium profunda*;
- 9 – *a. epigastrica inferior*;
- 10 – *a. femoralis*;
- 11 – *a. circumflexa ilium superficialis*;
- 12 – *aa. pudendae externae*;
- 13 – *a. circumflexa femoris medialis*;
- 14 – *a. circumflexa femoris lateralis*;
- 15 – *a. profunda femoris*;
- 16 – *aa. perforantes*;
- 17 – *a. descendens genus*;
- 18 – *a. poplitea*;
- 19 – *a. superior medialis genus*;
- 20 – *a. superior lateralis genus*;
- 21 – *a. inferior medialis genus*;
- 22 – *a. inferior lateralis genus*;
- 23 – *a. tibialis anterior*;
- 24 – *a. recurrens tibialis anterior*;
- 25 – *a. tibialis posterior*;
- 26 – *a. fibularis*; *a. peronea*;
- 27 – *a. malleolaris anterior lateralis*;
- 28 – *a. malleolaris anterior medialis*;
- 29 – *a. dorsalis pedis*;
- 30 – *a. tarsalis lateralis*;
- 31 – *a. arcuata*;
- 32 – *aa. tarsales mediales*;
- 33 – *a. plantaris profunda*;
- 34 – *aa. metatarsales dorsales*;
- 35 – *aa. digitales dorsales*;
- 36 – *a. plantaris medialis*;
- 37 – *a. plantaris lateralis*;
- 38 – *arcus plantaris profundus*;
- 39 – *aa. metatarsales plantares*;
- 40 – *aa. digitales plantares communes et aa. digitales plantares propriae*.

A – *facies anterior*;

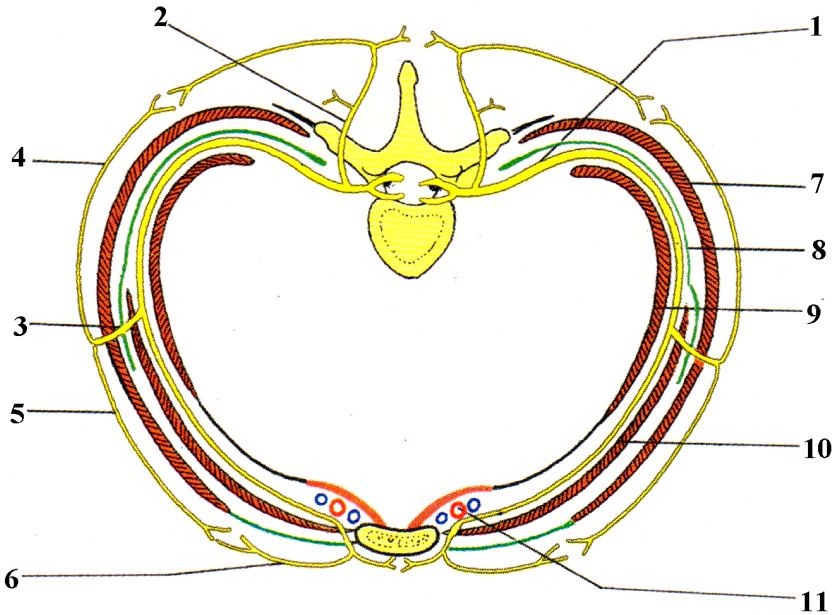
B – *facies posterior*.

VASELE ȘI NERVII PERETELUI TORACIC
 СОСУДЫ И НЕРВЫ СТЕНОК ГРУДНОЙ ПОЛОСТИ
 VESSELS AND NERVES OF THE THORACIC WALL



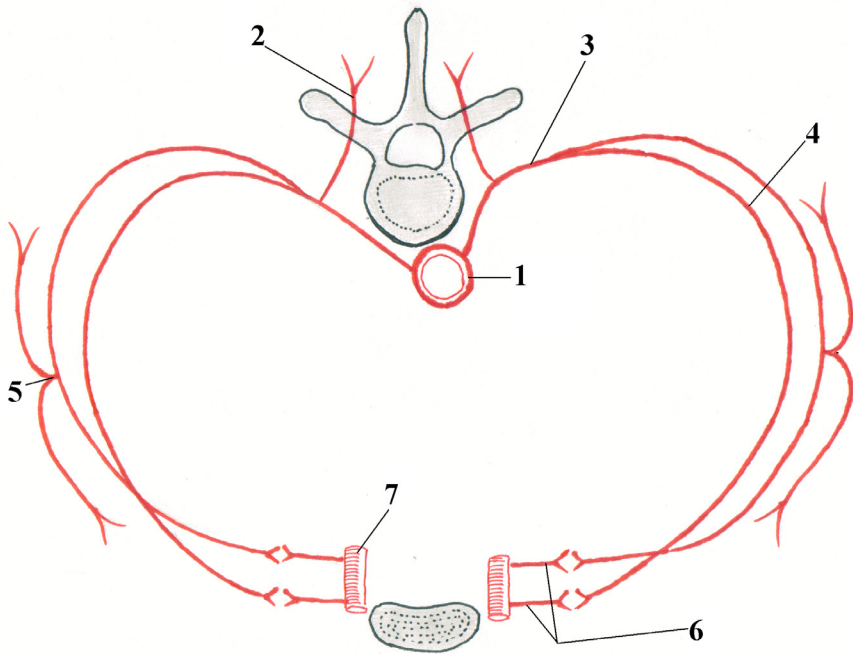
- 1 - aorta thoracica;
 2 - a. intercostalis posterior;
 3 - mm. intercostales externi;
 4 - mm. intercostales interni et subcostales;
 5, 10 - ramus cutaneus lateralis nervi intercostalis;
 6 - a. intercostalis anterior;
 7 - a. thoracica interna;
 8 - rami perforantes;
 9 - ramus cutaneus anterior nervi intercostalis;
 11 - rami ad pleuram parietalem;
 12 - rami musculares;
 13 - n. intercostalis;
 14 - n. spinalis;
 15 - ramus posterior nervi intercostalis;
 16 - membrana intercostalis anterior;
 17 - pleura parietalis;
 18 - membrana intercostalis posterior.

NERVII INTERCOSTALI ȘI RAMURILE LOR
МЕЖРЁБЕРНЫЕ НЕРВЫ И ИХ ВЕТВИ
THE INTERCOSTAL NERVES AND THEIR BRANCHES



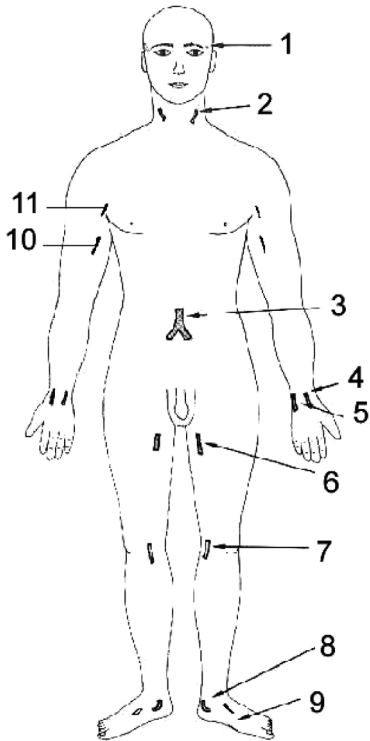
- 1 - *n. intercostalis;*
- 2 - *ramus posterior nervi intercostalis;*
- 3 - *ramus cutaneus lateralis nervi intercostalis;*
- 4 - *rami posteriores;*
- 5 - *rami anteriores;*
- 6 - *ramus cutaneus anterior nervi intercostalis;*
- 7 - *mm. intercostales externi;*
- 8 - *membrana intercostalis interna;*
- 9 - *mm. intercostales intimi et subcostales;*
- 10 - *mm. intercostales interni;*
- 11 - *a. et vv. intercostales anteriores.*

ARTERELE INTERCOSTALE ȘI RAMURILE LOR
МЕЖРЁБЕРНЫЕ АРТЕРИИ И ИХ ВЕТВИ
THE INTERCOSTAL ARTERIES AND THEIR BRANCHES

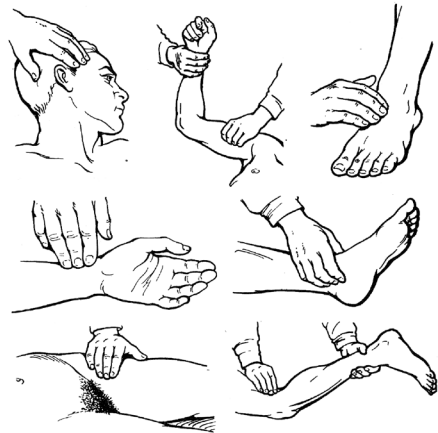

- 1 – aorta thoracica / pars thoracica aortae;**
- 2 – r. dorsalis;**
- 3 – a. intercostalis posterior;**
- 4 – r. collateralis;**
- 5 – r. cutaneus lateralis;**
- 6 – rr. intercostales anteriores;**
- 7 – a. thoracica interna.**

PROIEȚIA UNOR PUNCTE DE PALPARE A PULSULUI
ПРОЕКЦИЯ НЕКОТОРЫХ ТОЧЕК ПАЛЬПАЦИИ ПУЛЬСА
PROJECTION OF SOME POINTS OF PALPATION OF THE PULSE



(după В.К. Гостишев, 2003)



- 1 – a. temporalis superficialis;**
- 2 – a. carotis communis;**
- 3 – aorta abdominalis;**
- 4 – a. radialis;**
- 5 – a. ulnaris;**
- 6 – a. femoralis;**
- 7 – a. poplitea;**
- 8 – a. tibialis posterior;**
- 9 – a. dorsalis pedis;**
- 10 – a. brachialis;**
- 11 – a. axillaris.**

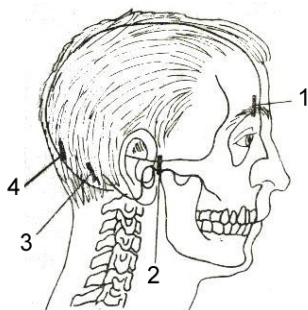
PUNCTELE DE PALPARE A UNOR ARTERE ȘI NERVI AI CAPULUI

(după N. Diaconescu și coaut., 1979)

ТОЧКИ ПАЛЬПАЦИИ НЕКОТОРЫХ АРТЕРИЙ И НЕРВОВ ГОЛОВЫ

POINTS OF PALPATION OF SOME ARTERIES

AND NERVES OF THE HEAD



- 1 - *a. supraorbitalis*;
- 2 - *a. temporalis superficialis*;
- 3 - *a. occipitalis*;
- 4 - *n. occipitalis major (Arnold)*.

PROIECȚIA UNOR PUNCTE DE PALPARE A PULSULUI

PE PERETELE ANTERIOR AL ABDOMENULUI

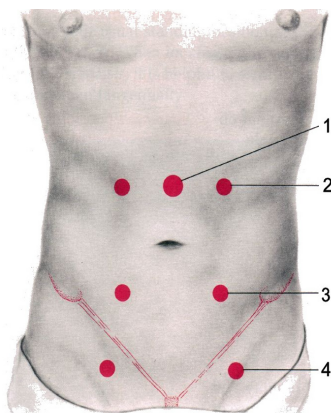
ȘI FAȚA ANTERIOARĂ A COAPSEI (după B. Bates, 1991)

ПРОЕКЦИЯ НЕКОТОРЫХ ТОЧЕК ПАЛЬПАЦИИ ПУЛЬСА

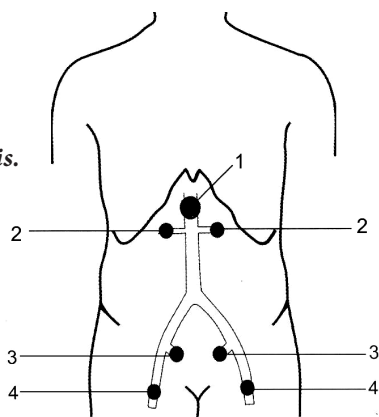
НА ПЕРЕДНЕЙ ПОВЕРХНОСТИ ЖИВОТА И БЕДРА

PROJECTION OF SOME POINTS OF PALPATION OF THE PULSE ON THE

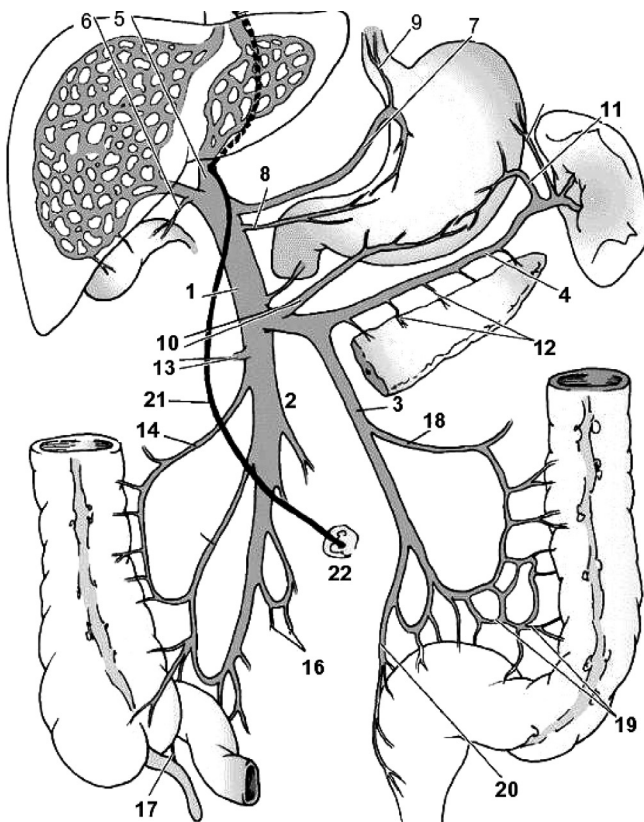
ANTERIOR SURFACE OF THE ABDOMEN AND OF THE THIGH



- 1 - *aorta*;
- 2 - *a. renalis*;
- 3 - *a. iliaca*;
- 4 - *a. femoralis*.



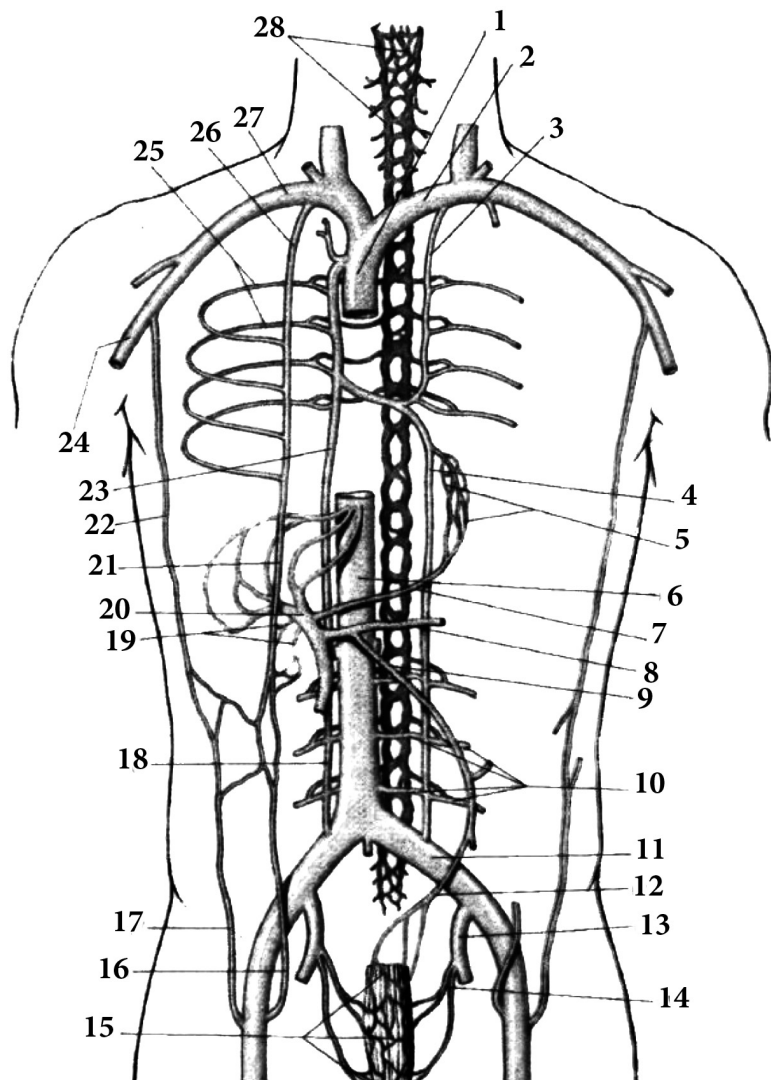
AFLUENȚII VENEI PORTE (*după Gray, 2005*)
ПРИТОКИ ВОРОТНОЙ ВЕНЫ
THE TRIBUTARIES OF THE PORTAL VEIN



- 1 - vena portae hepatis;
- 2 - vena mesenterica superior;
- 3 - vena mesenterica inferior;
- 4 - vena lienalis (splenica);
- 5 - ramus sinister;
- 6 - vena cystica;
- 7 - vena gastrica sinistra;
- 8 - vena gastrică dextra;
- 9 - venae oesophageales;
- 10 - vena gastroepiploica dextra;
- 11 - vena gastroepiploica sinistra;

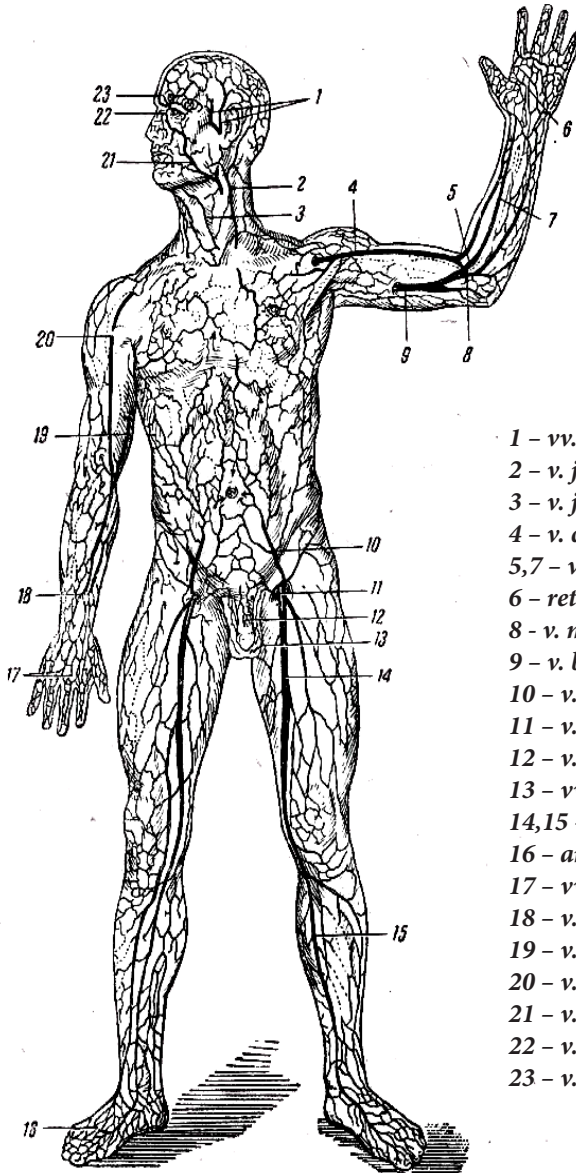
- 12 - venae pancreaticae;
- 13 - vena colica media;
- 14 - vena colica dextra;
- 15 - vena ilocolica;
- 16 - venae ilieales;
- 17 - vena appendicularis;
- 18 - vena colica sinistra;
- 19 - venae sigmoideae;
- 20 - vena rectalis superior;
- 21 - ligamentum teres hepatis;
- 22 - umbilicus.

ANASTOMOZELE DINTRE AFLUENȚII VENEI PORTĂ
 ȘI VENELOR CAVE SUPERIOARĂ ȘI INFERIOARĂ
 АНАСТОМОЗЫ МЕЖДУ ПРИТОКАМИ ВОРОТНОЙ,
 ВЕРХНЕЙ И НИЖНЕЙ ПОЛЫХ ВЕН
 ANASTOMOSES OF THE TRIBUTARIES OF THE PORTAL VEIN WITH
 THE TRIBUTARIES OF THE SUPERIOR AND INFERIOR VENA CAVA



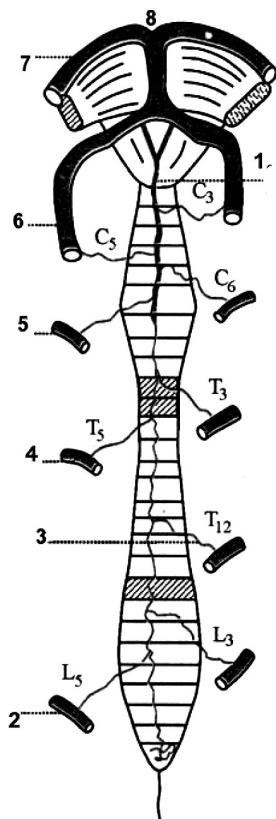
- 1 – *v.cava superior*;
- 2 – *v. brachiocephalica sinistra*;
- 3 – *v. hemiazygos accessoria*;
- 4 – *v hemiazygos*;
- 5 – *vv. oesophageales*;
- 6 – *v. cava inferior*;
- 7 – *v. gastrica dextra*;
- 8 – *v. lienalis*;
- 9 – *v. mesenterica inferior*;
- 10 – *vv. lumbales*;
- 11 – *v. iliaca communis*;
- 12 – *v. rectalis superior*;
- 13 – *v. iliaca interna*;
- 14 – *v. rectalis media*;
- 15 – *plexus venosus rectalis*;
- 16 – *v. epigastrica inferior*;
- 17 – *v. epigastrica superficialis*;
- 18 – *v. lumbalis ascendens*;
- 19 – *vv. paraumbilicales*;
- 20 – *v. portae*;
- 21 – *v. epigastrica superior*;
- 22 – *v. thoracoepigastrica*;
- 23 – *v. azygos*;
- 24 – *v. axillaris*;
- 25 – *vv. intercostales posteriores*;
- 26 – *v. thoracica interna*;
- 27 – *v. subclavia*;
- 28 – *plexus venosus vertebralis*.

VENELE SUBCUTANATE ALE CORPULUI UMAN
ПОДКОЖНЫЕ ВЕНЫ ТЕЛА ЧЕЛОВЕКА
SUBCUTANEOUS VEINS OF THE HUMAN BODY



- 1 - *vv. temporales superficiales;*
- 2 - *v. jugularis externa;*
- 3 - *v. jugularis anterior;*
- 4 - *v. cephalica;*
- 5,7 - *v. mediana antebrachii;*
- 6 - *rete venosum volare;*
- 8 - *v. mediana cubiti;*
- 9 - *v. basilica;*
- 10 - *v. epigastrica superficialis;*
- 11 - *v. pudenda externa;*
- 12 - *v. dorsalis penis subcutanea;*
- 13 - *vv. scrotales;*
- 14,15 - *v. saphena magna;*
- 16 - *arcus venosus dorsalis pedis;*
- 17 - *vv. metacarpales dorsales;*
- 18 - *v. cephalica;*
- 19 - *v. basilica;*
- 20 - *v. cephalica;*
- 21 - *v. facialis;*
- 22 - *v. angularis;*
- 23 - *v. supraorbitalis.*

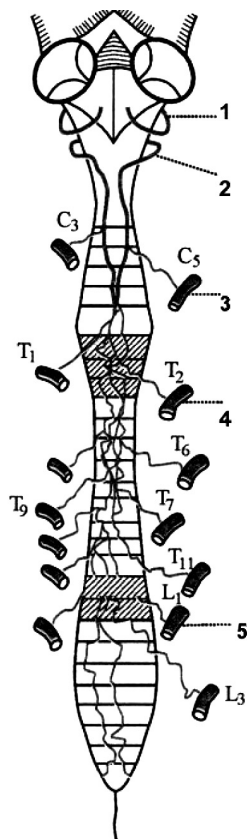
ARTEREE MĂDUVEI SPINĂRII
 АРТЕРИИ СПИННОГО МОЗГА
 ARTERIES OF THE SPINAL CORD



A

A

- 1 - arteria spinalis anterior;
- 2 - arteria lumbalis;
- 3 - arteria Adamkiewiczzi;
- 4 - arteria intercostalis posterior;
- 5 - arteria cervicalis ascendens;
- 6 - arteria vertebralis;
- 7 - arteria cerebri posterior;
- 8 - arteria basilaris.



B

B

- 1 - arteria inferior posterior cerebelli;
- 2 - arteriae spinales posteriores;
- 3 - arteria cervicalis ascendens;
- 4 - arteria intercostalis posterior;
- 5 - arteria lumbalis.

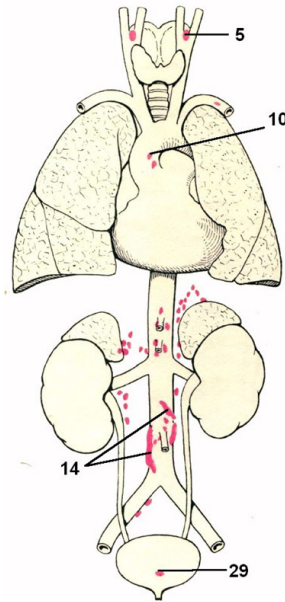
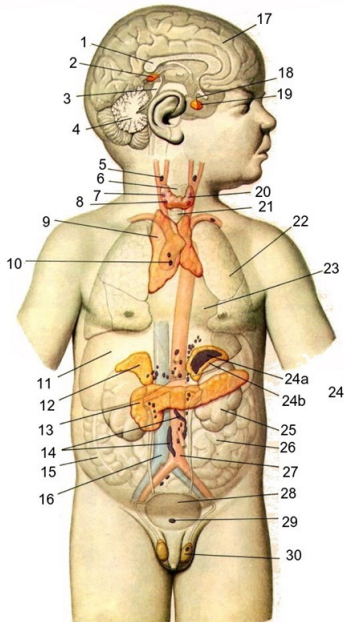
GLANDELE ENDOCRINE ȘI LOCALIZAREA PARAGANGLIONILOR

(după P.Д. Синельников, Я.Р. Синельников, 1990)

ЭНДОКРИННЫЕ ЖЕЛЕЗЫ И РАСПОЛОЖЕНИЕ

ХРОМАФФИННЫХ ПАРААНГЛИЕВ

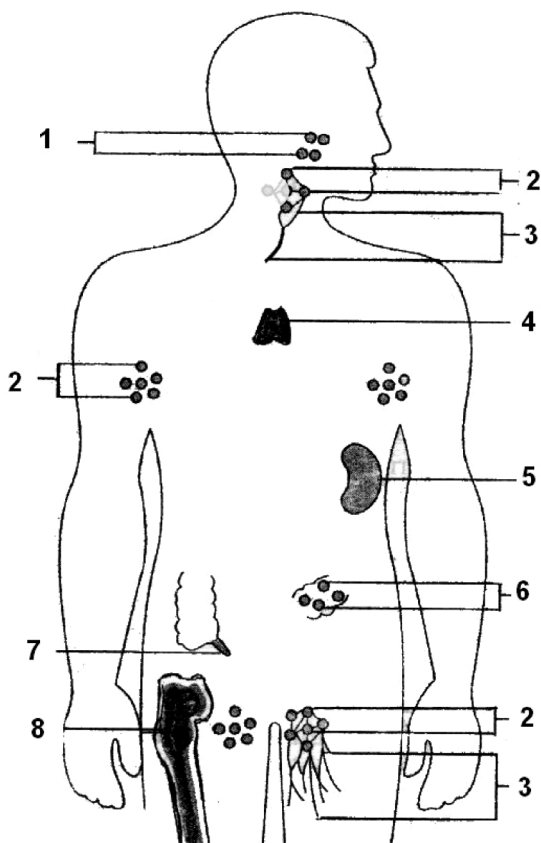
THE ENDOCRINE GLANDS AND LOCALIZATION OF THE CHROMAFFIN BODIES (PARAGANGLIA)



- 1 – corpus callosum;
- 2 – corpus pineale;
- 3 – tectum mesencephali;
- 4 – cerebellum;
- 5 – glomus caroticum;
- 6 – larynx;
- 7 – glandula parathyroidea superior;
- 8 – glandula parathyroidea inferior;
- 9 – thymus;
- 10 – corpora paraaortica;
- 11 – hepar;
- 12 – glandula suprarenalis dextra;
- 13 – pancreas;
- 14 – glomus aorticum;
- 15 – intestinum crassum;
- 16 – v. cava inferior;

- 17 – hemispherium cerebri;
- 18 – infundibulum;
- 19 – hypophysis;
- 20 – glandula thyroidea;
- 21 – trachea;
- 22 – pulmo;
- 23 – pericardium;
- 24 – glandula suprarenalis sinistra;
- 24 a – medulla;
- 24 b – cortex;
- 25 – ren;
- 26 – intestinum tenue;
- 27 – aorta;
- 28 – vesica urinaria;
- 29 – glomus coccygeum;
- 30 – testis.

ORGANELE SISTEMULUI LIMFOID
ОРГАНЫ ЛИМФОИДНОЙ СИСТЕМЫ
ORGANS OF THE LIMPHOID SYSTEM



- 1 - tonsillae;
- 2 - nodi lymphoidei;
- 3 - vasa lymphatica;
- 4 - thymus;
- 5 - lien;
- 6 - noduli lymphoidei aggregati (Peyeri);
- 7 - noduli lymphoidei aggregati appendicis vermiformis;
- 8 - medulla ossium rubra.

NOTE

NOTE

NOTE