State Medical and Pharmaceutical University "Nicolae Testemițanu"

Department of Internal Medicine

Medical clinic nr. 1

Ion NIKOLENKO, Tatiana DUMITRAŞ

PULMONARY FUNCTION TESTING AND CHEST IMAGING

(illustrated guide)

Chişinău 2011

State Medical and Pharmaceutical University "Nicolae Testemiţanu"

Department of Internal Medicine

Medical clinic nr. 1

Ion NIKOLENKO, Tatiana DUMITRAŞ

PULMONARY FUNCTION TESTING AND CHEST IMAGING

(illustrated guide)

Chişinău 2011

Elaborarea metodică a fost aprobată şi recomandată pentru editare de către Consiliului Metodic Central al USMF „Nicolae Testemiţanu" (Proces verbal nr. 3 din 8 aprilie 2011).

Recenzenţi: ***Ivan Butorov***, dr. habilitat, profesor universitar

Ion Ţîbîrnă, dr. habilitat, profesor universitar

Descrierea CIP a CAMEREI NAŢIONALE a CĂRŢII
Ion NIKOLENKO, Tatiana DUMITRAŞ
PULMONARY FUNCTION TESTING
AND CHEST IMAGING (illustrated guide)
– Ch.: "Vite-Jesc" SRL, 2011. – 52 p. 100 ex.
ISBN 978-9975-4155-5-2.
616.2(036)
N 64

Elaborarea metodică este destinată studenţilor.

Contents

Abbreviations

$A\text{-}aD_{O2}$ - Alveolar-arterial P_{O2} difference (gradient)

CT - Computered tomography

DL_{CO} - Diffusing capacity for carbon monoxide (mL/min/mm Hg)

EBUS - Endobronchial ultrasound

ERV - Expiratory reserve volume

FB - Fiberoptic bronchoscopy

$FEF_{25-75\%}$ - Mean forced expiratory flow during the middle of FVC

FEV_1 (L) - Forced expiratory volume in 1 sec, in liters

FEV_1 % FVC - Forced expiratory volume in 1 sec as percentage of FVC

FI_{O2} - Percentage of inspired O_2

FRC - Functional residual capacity

FVC - Forced vital capacity

[H+] - Hydrogen ion concentration (nanomole/L)

IC - Inspiratory capacity

IRV - Inspiratory reserve volume

MEF 50% FVC - Mid-expiratory flow at 50% of FVC

MEP - Maximal expiratory pressure (cm H_2O)

MIF 50% FVC - Mid-inspiratory flow at 50% of FVC

MIP - Maximal inspiratory pressure (cm H_2O)

MRI - Magnetic Resonance Imaging

MVV - Maximal voluntary ventilation

PA_{CO2} - Partial pressure of alveolar CO_2

PA_{O2} - Partial pressure of alveolar O_2

Pa_{CO2} - Partial pressure of arterial CO_2

Pa_{O2} - Partial pressure of arterial O_2

PB - Barometric pressure

P_{CO2} - Partial pressure of CO_2

PET - Positron emission tomography

PET_{CO2} - Partial pressure of end tidal CO_2

PEF - Peak expiratory flow (L/min)

PIO2 - Partial pressure of inspired O_2

P_{O2} - Partial pressure of O_2

PV - Partial pressure of mixed venous (pulmonary arterial) blood

PV_{O2} - Partial pressure of mixed venous O_2

PV_{CO2} - Partial pressure of mixed venous CO_2

Raw - Airway resistance

RV - Residual volume

SPN - Solitary pulmonary nodule

TBNA - Transbronchial needle aspiration

TLC - Total lung capacity

V - Ventilation (L/min)

VC - Vital capacity

VA - Alveolar ventilation (L/min)

VATS - Video-assisted thoracoscopic surgery

V_{CO2} - CO_2 production (L/min)

VD - Dead space volume

V_{O2} - O_2 consumption (L/min)

VT - Tidal volume

Introduction

Pulmonary function testing is a valuable tool for evaluating the respiratory system, representing an important adjunct to the patient history, various lung imaging studies, and invasive testing such as bronchoscopy and open-lung biopsy. The percentage of predicted normal is used to grade the severity of the abnormality. Practicing clinicians must become familiar with pulmonary function testing because it is often used in clinical medicine for evaluating respiratory symptoms such as dyspnea and cough, for stratifying preoperative risk, and for diagnosing common diseases such as asthma and chronic obstructive pulmonary disease.

Pulmonary function testing includes both simple spirometry and sophisticated physiologic testing.

Pulmonary ventilation

Static Lung Volumes and Capacities

Static lung volumes (see Fig. 1) reflect the elastic properties of the lungs and chest wall.

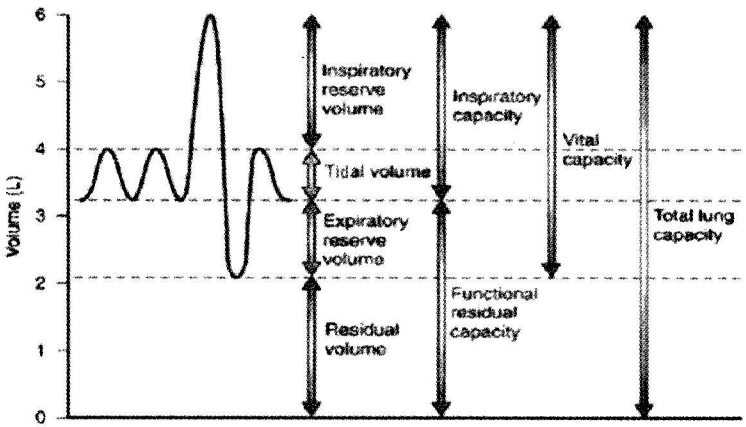

Figure 1. **Lung volumes.**

Total lung capacity

Total lung capacity (TLC) is the total volume of air within the chest after a maximum inspiration. TLC = VC + RV.

Vital capacity

Vital capacity (VC) is the maximum volume of air that can be expired slowly after a full inspiratory effort. Simple to perform, it is one of the most valuable measurements of pulmonary function. Because VC decreases as a restrictive lung disorder (e.g., pulmonary edema, interstitial fibrosis) worsens, it can be used along with the diffusing capacity to follow the course of such a disorder and its response to therapy. The VC also reflects the strength of the respiratory muscles and is often used to monitor the course of neuromuscular disorders.

Forced vital capacity

Forced vital capacity (FVC), similar to VC, is the volume of air expired with maximal force. It is usually measured along with expiratory flow rates in simple spirometry. The VC can be considerably greater than the FVC in patients with airway obstruction. During the FVC maneuver, terminal airways can close prematurely (i.e., before the true residual volume is reached), trapping gas distally and preventing its measurement by the spirometer.

Residual volume

Residual volume (RV) is the volume of air remaining in the lungs at the end of a maximal expiration. It is approximately 1000-1200 ml. This cannot be measured by simple spirometry.

Expiratory reserve volume

Expiratory reserve volume (ERV) is the maximal volume of air exhaled from end of expiration (~ 1000 -1400 ml).

Functional residual capacity

Functional residual capacity (FRC) is the volume of air in the lungs at the end of a normal expiration when all respiratory muscles are relaxed.

Loss of lung elastic recoil in emphysema increases FRC. Conversely, the increased lung stiffness in pulmonary edema, interstitial fibrosis, and other restrictive disorders decreases FRC. Kyphoscoliosis leads to a decrease in FRC and in other lung volumes because a stiff, noncompliant chest wall restricts lung expansion.

The FRC has two components: residual volume (RV) and expiratory reserve volume (ERV); ERV = FRC – RV. Changes in RV parallel those in the FRC with two exceptions: in restrictive lung and chest wall disorders, RV decreases less than

do the FRC and TLC, and in small airways disease, premature closure during expiration leads to air trapping, so that the RV is elevated while the FRC and FEV1 remain close to normal. In COPD and asthma, the RV increases more than the TLC does, resulting in some decrease in the VC. The characteristic abnormality seen in obesity is a decreased ERV, caused by a markedly decreased FRC with a relatively well-preserved RV.

Inspiratory capacity

Inspiratory capacity is the difference between TLC and FRC.

Inspiratory reserve volume

Inspiratory reserve volume (IRV) is the maximal volume of air inhaled from end of inspiration. IRV = VC - (TV + ERV).

Tidal volume

Tidal volume (VT) is the volume of air inhaled or exhaled during each respiratory cycle. (*Under normal resting conditions, this is approximately 500 ml*).

Dynamic Lung Volumes and Flow Rates

Dynamic lung volumes reflect the caliber and integrity of the airways. Spirometry records lung volume against time during an FVC maneuver.

Forced expiratory volume in 1 sec

Forced expiratory volume in 1 sec (FEV_1) is the volume of air forcefully expired during the first second after a full breath. This value is recorded both as an absolute value and as a percentage of the FVC (FEV_1/FVC). FEV_1 should be 75-85% of VC.

Mean forced expiratory flow during the middle of FVC

The mean forced expiratory flow during the middle half of the FVC ($FEF_{25-75\%}$) is the slope of the line that intersects the spirographic tracing at 25% and 75% of the FVC. The $FEF_{25-75\%}$ is less effort-dependent than the FEV_1 and is a more sensitive indicator of early airway obstruction.

Prolongation of expiratory flow rates is increased by bronchospasm (in asthma), impacted secretions (in bronchitis), and loss of lung elastic recoil (in emphysema). In fixed obstruction of the upper airway, flow is limited by the caliber of the narrowed segment rather than by dynamic compression, resulting in equal reduction of inspiratory and expiratory flow rates.

Ventilation

Ventilation (V) is the volume of air that passes into or out of the respiratory system per minute. = Rate x Tidal Volume.

Spirometry

Spirometry (Fig. 2 and 3) is the most commonly used lung function screening study. It generally should be the clinician's first option, with other studies being reserved for specific indications.

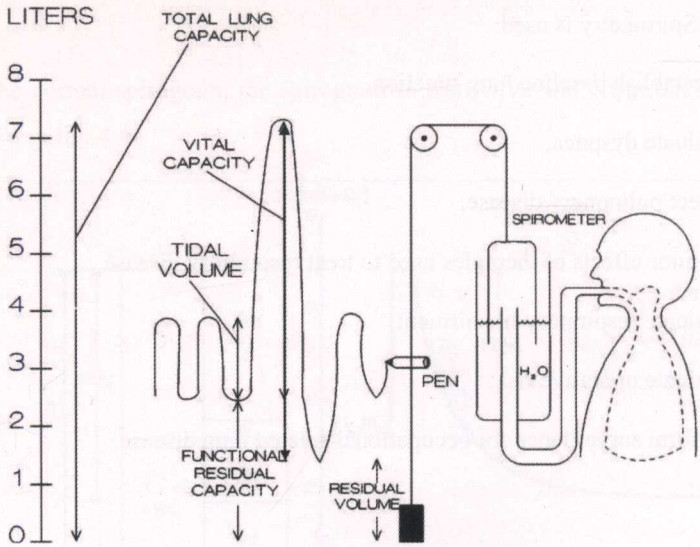

Figure 2. **Spirometry (schematic image).**

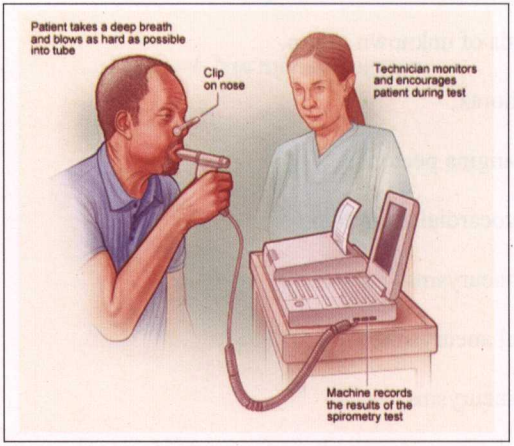

Figure 3. **Spirometric procedure.**

Indications

Spirometry is used:

- ✓ to establish baseline lung function,
- ✓ evaluate dyspnea,
- ✓ detect pulmonary disease,
- ✓ monitor effects of therapies used to treat respiratory disease,
- ✓ evaluate respiratory impairment,
- ✓ evaluate operative risk,
- ✓ perform surveillance for occupational-related lung disease.

Contraindications

Relative contraindications for spirometry include:

- ✓ hemoptysis of unknown origin,
- ✓ pneumothorax,
- ✓ unstable angina pectoris,
- ✓ recent myocardial infarction,
- ✓ thoracic aneurysms,
- ✓ abdominal aneurysms,
- ✓ cerebral aneurysms,
- ✓ recent eye surgery (increased intraocular pressure during forced expiration),
- ✓ recent abdominal or thoracic surgical procedures,

✓ patients with a history of syncope associated with forced exhalation.

The normal spirogram, the spirogram in restrictive and obstructive diseases are shown in fig. 4-6.

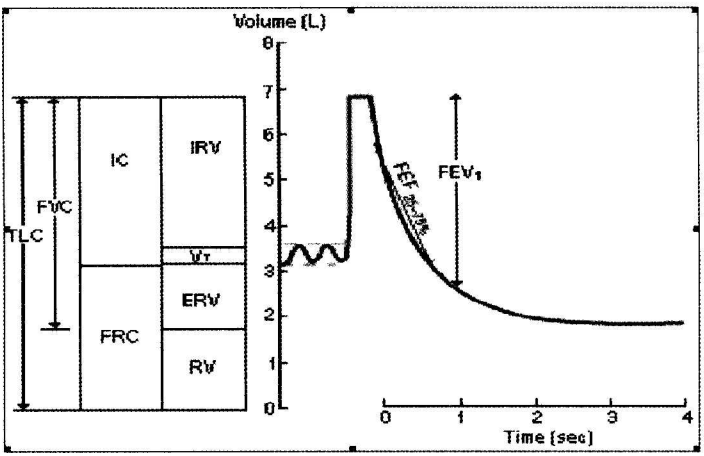

Figure 4. **Normal spirogram.**

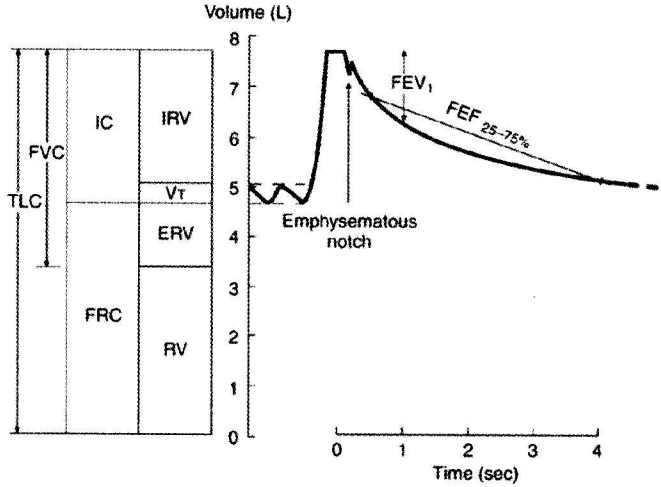

Figure 5. **Spirogram in obstructive disease.**

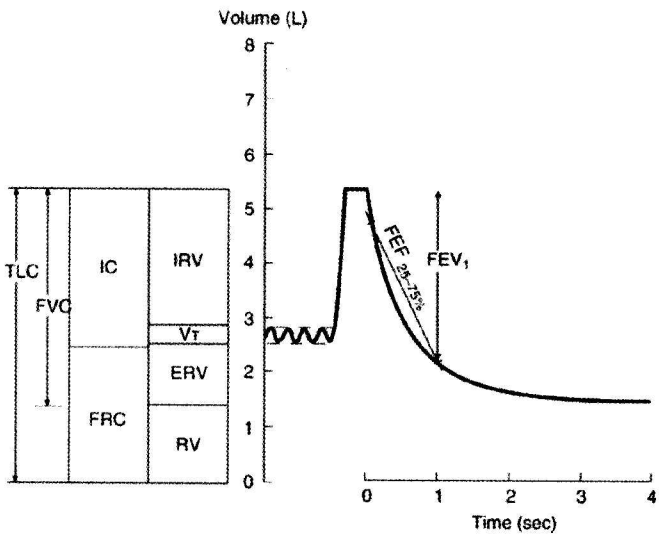

Figure 6. **Spirogram in restrictive disease.**

Interpretation of spirometry results

Most common respiratory disorders can be categorized as obstructive or restrictive on the basis of airflow and lung volumes (see Table 1).

Table 1. Most common respiratory disorders.

Characteristic Physiologic Changes Associated With Pulmonary Disorders			
Measure	**Obstructive Disorders**	**Restrictive Disorders**	**Mixed Disorders**
FEV_1/FVC	Decreased	Normal or increased	Decreased
FEV_1	Decreased	Decreased, normal, or increased	Decreased
FVC	Decreased or normal	Decreased	Decreased or normal
TLC	Normal or increased	Decreased	Decreased, normal, or increased
RV	Normal or increased	Decreased	Decreased, normal, or increased

The severity of obstructive and restrictive lung disorders is shown in Table 2.

Table 2. The severity of obstructive and restrictive lung disorders.

		Obstructive	**Restrictive**
Severity	**FEV_1/FVC (% predicted)**	**FEV_1 (% predicted)**	**TLC (% predicted)**
Normal	≥ 70	≥ 80	≥ 80
Mild	< 70	≥ 80	70–79
Moderate	< 70	$50 \leq FEV_1 < 80$	50–69
Severe	< 70	$30 \leq FEV_1 < 50$	< 50
Very severe	< 70	< 30 *or* < 50 with chronic respiratory failure	—

Flow-volume loops

In contrast to the spirogram, which displays airflow (in L) over time (in sec), the flow-volume loop (see Fig. 7) displays airflow (in L/sec) as it relates to lung volume (in L) during maximal inspiration from complete exhalation (residual volume [RV]) and during maximum expiration from complete inhalation (TLC). The principal advantage of the flow-volume loop is that it can show whether airflow is appropriate for a particular lung volume. For example, airflow is normally slower at low lung volumes. Because patients with pulmonary fibrosis have low lung volumes, airflow appears to be decreased if measured alone. However, when airflow is presented as a function of lung volume, it becomes apparent that airflow is actually higher than normal (as a result of the increased elastic recoil characteristic of fibrotic lungs).

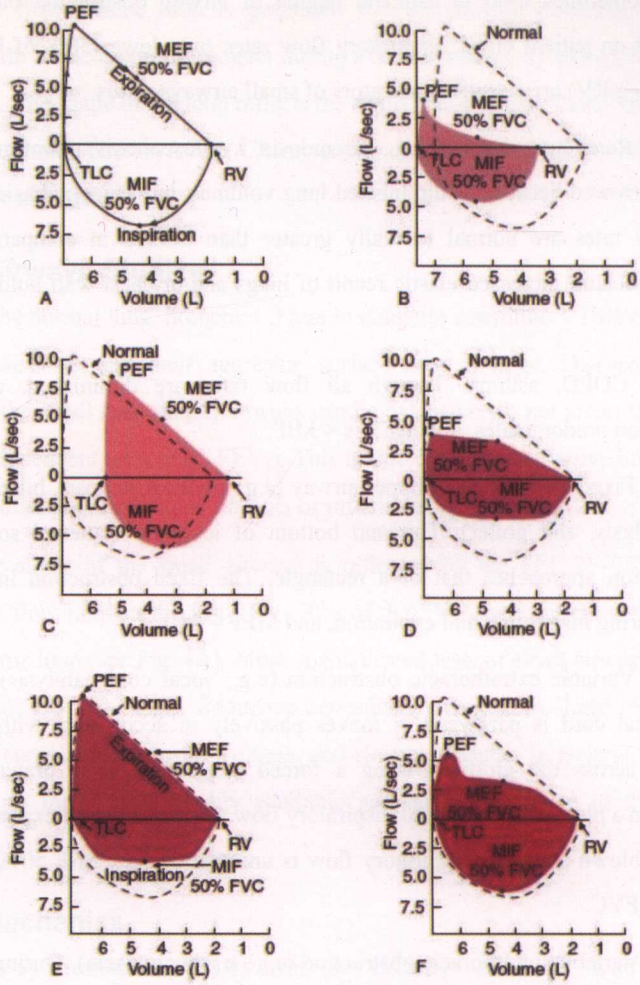

Figure 7. **Flow-volume loops.**

(A) Normal. Inspiratory limb of loop is symmetric and convex. Expiratory limb is linear. Flow rates at midpoint of VC are often measured. MIF 50% FVC is > MEF 50%FVC because of dynamic compression of the airways. Peak expiratory

flow is sometimes used to estimate degree of airway obstruction but is very dependent on patient effort. Expiratory flow rates over lower 50% of FVC (i.e., approaching RV) are sensitive indicators of small airways status.

(B) Restrictive disease (e.g., sarcoidosis, kyphoscoliosis). Configuration of loop is narrowed because of diminished lung volumes, but shape is basically as in (A). Flow rates are normal (actually greater than normal at comparable lung volumes because increased elastic recoil of lungs and/or chest wall holds airways open).

(C) COPD, asthma. Though all flow rates are diminished, expiratory prolongation predominates, and MEF is < MIF.

(D) Fixed obstruction of upper airway (e.g., tracheal stenosis, bilateral vocal cord paralysis, and goiter). Top and bottom of loop are flattened so that the configuration approaches that of a rectangle. The fixed obstruction limits flow equally during inspiration and expiration, and MEF = MIF.

(E) Variable extrathoracic obstruction (e.g., vocal cord paralysis). When a single vocal cord is paralyzed, it moves passively in accordance with pressure gradients across the glottis. During a forced inspiration, it is drawn inward, resulting in a plateau of decreased inspiratory flow. During a forced expiration, it is passively blown aside and expiratory flow is unimpaired, i.e., MIF 50%FVC is < MEF 50%FVC.

(F) Variable intrathoracic obstruction (e.g., tracheomalacia). During a forced inspiration, negative pleural pressure holds the "floppy" trachea open. With forced expiration, the loss of structural support results in narrowing of the trachea and a plateau of diminished flow (a brief period of maintained flow is seen before airway compression occurs).

The flow-volume loop is generated by continuously recording flow and volume with an electronic spirometer during a forced inspiratory and expiratory VC maneuver. The shape of the loop reflects the status of the lung volumes and airways throughout the respiratory cycle. Characteristic changes occur in restrictive and in obstructive disorders.

Small Airways Studies

In the normal lung, bronchi < 2 mm in diameter constitute < 10% of the total airway resistance, but their aggregate surface area is large. Disease affecting primarily the small (peripheral) airways can be extensive yet not affect the Raw or any tests dependent on it (e.g., FEV_1). This is true of early obstructive lung disease and interstitial granulomatous, fibrotic, or inflammatory disorders.

The status of the small airways is reflected by the FEF 25–75% and by expiratory flow rates in the last 25 to 50% of the FVC, best determined from the flow-volume loop (see Fig. 4A). More sophisticated tests of small airways function have been devised—e.g., frequency-dependent changes in lung compliance (dynamic compliance), closing volume, and closing capacity. In general, such tests add little to those more readily available and have little place in the clinical laboratory.

Lung Mechanics

Airway resistance (Raw) can be directly measured with a body plethysmograph (fig. 8), which determines the pressure required to produce a given flow. More commonly, however, Raw is inferred from dynamic lung volumes and expiratory flow rates, which can be obtained more easily.

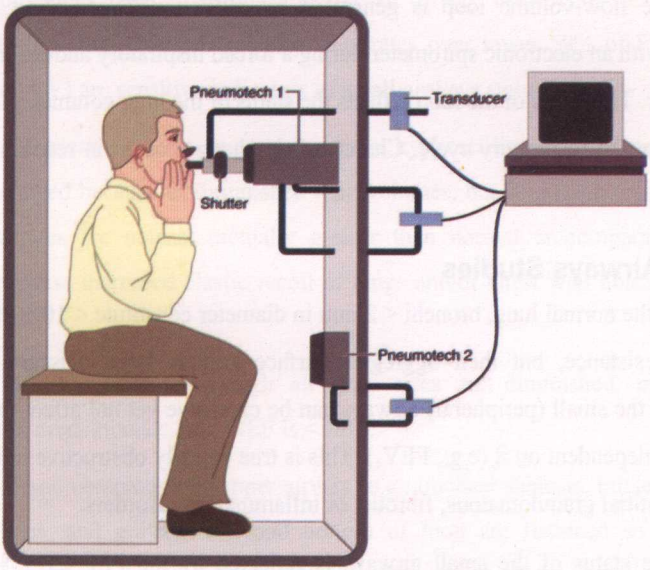

Figure 8. **Body plethysmography.**

Maximal inspiratory pressure (MIP) and maximal expiratory pressure (MEP) measure the strength of the respiratory muscles as the patient forcibly inhales and exhales, respectively, through a closed mouthpiece attached to a pressure gauge. Like the MVV (see above), maximal pressures are reduced in neuromuscular disorders (e.g., myasthenia gravis, muscular dystrophy, Guillain-Barré syndrome). These pressures, along with the VC, are often measured at the bedside of an intubated patient to predict the success of weaning from ventilatory support.

Diffusing Capacity

The diffusing capacity (Fig. 9) for carbon monoxide (DL_{CO}) can be determined from a single breath (DL_{COSB}). The patient inspires a known small amount of carbon monoxide (CO), holds his breath for 10 sec, and then exhales. A

sample of alveolar (end-expired) gas is analyzed for CO, and the amount absorbed during that breath is then calculated and expressed as mL/min/mm Hg.

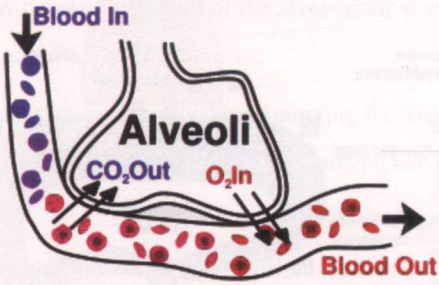

Figure 9. **The diffusing capacity of O_2 and CO_2**

(Gaseous exchange in the lung).

A low DL_{CO} probably reflects abnormal ventilation/perfusion ratios (V/Q) in diseased lungs rather than physical thickening of the alveolar-capillary membrane. However, this test relies on the avidity of Hb for CO and thus is affected by the volume of blood and the quantity of desaturated Hb in the lungs at the time of testing. The DL_{CO} is low in processes that destroy alveolar-capillary membranes (e.g., emphysema and interstitial inflammatory or fibrotic processes) and in severe anemia, in which less Hb is available to bind the inhaled CO. The DL_{CO} is artifactually low if the patient's Hb is already occupied by CO (e.g., if he smokes within several hours of the test). The DL_{CO} increases with polycythemia and with increased pulmonary blood flow, as may occur in early heart failure.

Gaseous exchange in the human body

The major objective of respiration is tissues supply with oxygen and elimination of carbon dioxide. The main stages of oxygen entering in tissues and carbon dioxide elimination are given in figure 10.

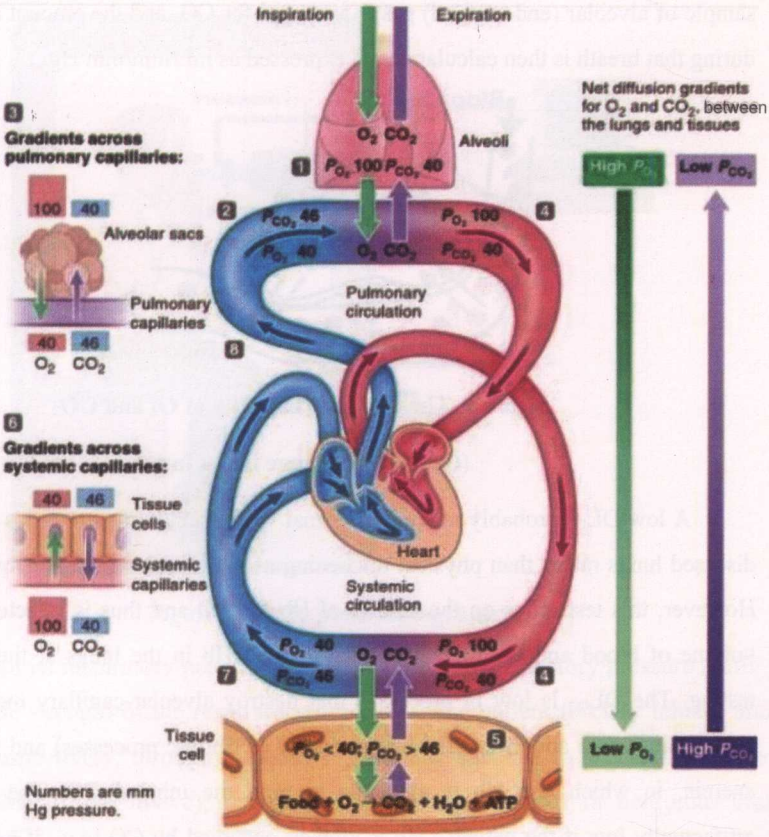

Figure 10. **Oxygen and CO_2 exchange across pulmonary and systemic capillaries caused by partial pressure gradients (See explanation in text below).**

Explanation for Fig. 10.

1. Alveolar PO_2 remains relatively high and alveolar PCO2 remains relatively low because a portion of the alveolar air is exchanged for fresh atmospheric air with each breath.

2. In contrast, the systemic venous blood entering the lungs is relatively low in O2 and high in CO_2, having given up O_2 and picked up CO_2 at systemic capillary level.

3. The partial pressure gradients established between the alveolar air and pulmonary capillary blood induce passive diffusion of O_2 into blood and CO_2 out of the blood until blood and alveolar partial pressures become equal.

4. The blood leaving the lungs is this relatively high in O_2 and low in CO_2. It arrives all the tissues with the same blood gas content as when it left the lungs.

5. The partial pressure of O_2 is relatively low and that of CO_2 is relatively high in the O_2 consuming CO_2 producing tissue cells.

6. Consequently, partial pressure gradients for gas exchange at the tissue level favor the passive movement of O_2 out of the blood into cells to support their metabolic requirements and also favor the simultaneous transfer of CO_2 into the blood.

7. Having equilibrated with the tissue cells, the blood leaving the tissues is relatively low in O_2 and high in CO_2.

8. The blood the returns to the lungs to once again fill up on O_2 and dump off CO_2.

The PaO_2 and $PaCO_2$ reflect the adequacy and efficiency of gas exchange between the lungs and venous blood.

Normal values of partial pressure of arterial blood oxygen (PaO_2) according to age are given in table 3.

Table 3. The normal values of PaO_2 according to age

Age (years)	Mean value of PaO_2 (mm Hg)	Variations
20-29	95	80-110
30-39	90	78-108
40-49	86	75-104
50-59	82	71-100
60-69	78	67-95

Normal values of $PaCO_2$ vary from 35 mm Hg to 45 mm Hg.

Chest imaging

X-ray techniques

X-ray techniques that are used to image the chest include:

- plain x-rays;
- fluoroscopy;
- high-resolution CT;
- helical (spiral) CT;
- CT angiography
- Magnetic Resonance Imaging

Plain Chest X-ray

The standard x-ray examination of the chest consists of a *frontal or posteroanterior (PA)* and *lateral* view. The frontal view is called a PA view because the patient stands with the anterior chest on the cassette and the back to the x-ray beam. The x-rays first hit the posterior and then the anterior chest before hitting the cassette. The cassette is 6 feet from the x-ray tube.

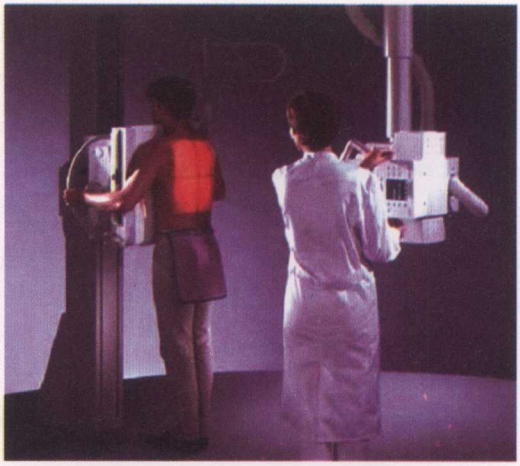

Figure 11. **The posteroanterior posture of standard chest X-ray examination**

The lateral film is taken the same way except the patient is standing with his or her side perpendicular to the x-ray cassette. Unless otherwise specified, a left lateral is taken.

An *anterioposterior (AP)* film of the chest is the usual technique when patients are too ill to leave the bedside. It is usually taken with the cassette behind the patient and the x-ray beam 40 (rather than 72) inches from the cassette, thus magnifying all structures.

An *apical lordotic* technique is used to evaluate the apices of the lungs. The x-ray beam is angled in a slightly upward projection, causing anterior thoracic structures to be projected above the posterior thoracic structures. The clavicle and first several sets of ribs are projected above the apices of the lung, allowing a good view of this area. It is particularly useful in evaluating the upper lobes for evidence of tuberculous disease.

The *lateral decubitus* technique is one in which the patient is placed lying on the cassette with either the left or right side dependent. It is most frequently used for evaluating the presence of free-moving pleural fluid. The usual technique is to have the patient lie on the side with the fluid and look for a radiodense fluid line along the dependent side. With small amounts of pleural fluid, it is helpful to have the patient lie with the normal side dependent and see if the diaphragmatic angle on the involved side becomes sharp, thus indicating the presence of a small, free-moving effusion.

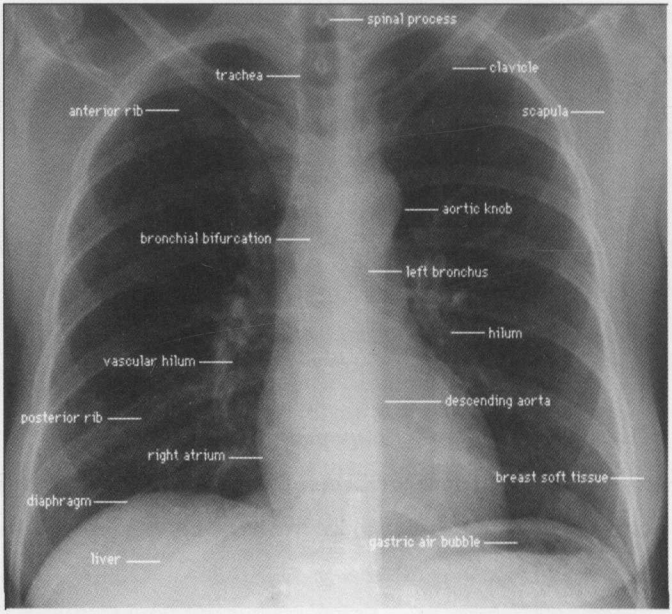

Figure 12. **Normal radiographic anatomy of the chest presented on the posteroanterior film**

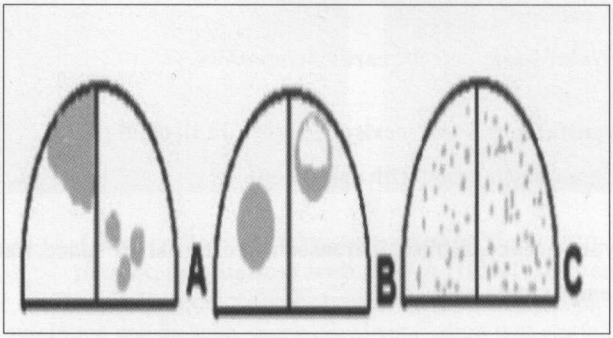

Figure 13. **The main chest X-ray signs described in different diseases**

Air-space shadow (opacity), Lobar/segmental, Atelectasis (figure 13 A, left part). Examples: lobar pneumonia, bronchogenic cancer.

Air-space shadow, (opacity) solitary; Air-space shadow, multifocal (figure 13 A, right part). Examples: bronchopneumonia, tuberculosis.

Pulmonary mass/noduli solitary; Pulmonary mass/noduli multiple – (figure 13 B, left part). Examples: tuberculosis, tumor, lung abscess.

Reticulonodular opacities, diffuse - (figure 13 C).
Examples: tuberculosis, sarcoidosis, interstitial pneumopathies.

Vascular contour, prominent, local; Vascular contour, prominent, diffuse.
Examples: pulmonary congestion due to left ventricle failure, pulmonary hypertension due to chronic lung disease.

Mediastinal shadow, enlarged.
Examples: mediastinal tumors, sarcoidosis.

Heart shadow, enlarged.
Examples: valvular heart defects, cardiomyopathies.

Pulmonary hyperlucency, local (cavity) - (figure 13 B, right part).
Examples: lung abscess, tumor with cavitation.

Pulmonary hyperlucency, diffuse, increased retrosternal air space, flat diaphragm – emphysema.

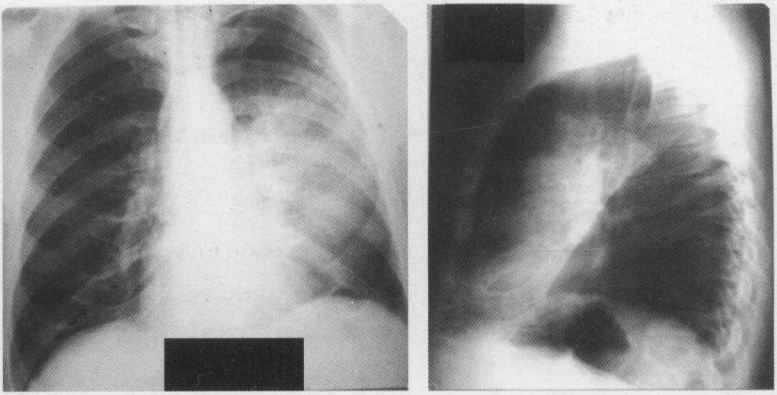

A **B**

Figure 14. **Lobar pneumonia in a 49-year-old patient**

A – posteroanerior chest X-ray on admission showing an alveolar opacity in a left middle pulmonary field.

B – left lateral view allows to localize the infiltrate exactly, that is left upper lobe.

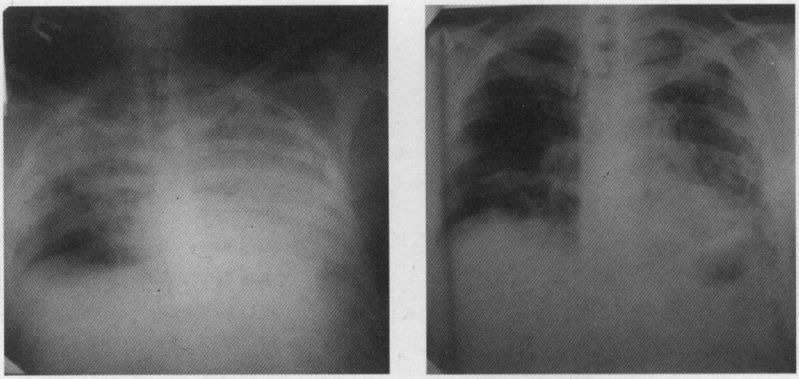

A B

Figure 15. **Chest radiographs (posteroanterior view) from a 28-year-old patient, hospitalized with 2009 A (H1N1) influenza.**

A – Day 3 of hospitalization, diffuse alveolar opacities reflecting adult respiratory distress syndrome can be seen, mechanical ventilation was started. B – Day 13 of hospitalization, significant radiological clearance of previous opacities is observed which coincided with clinical improvement.

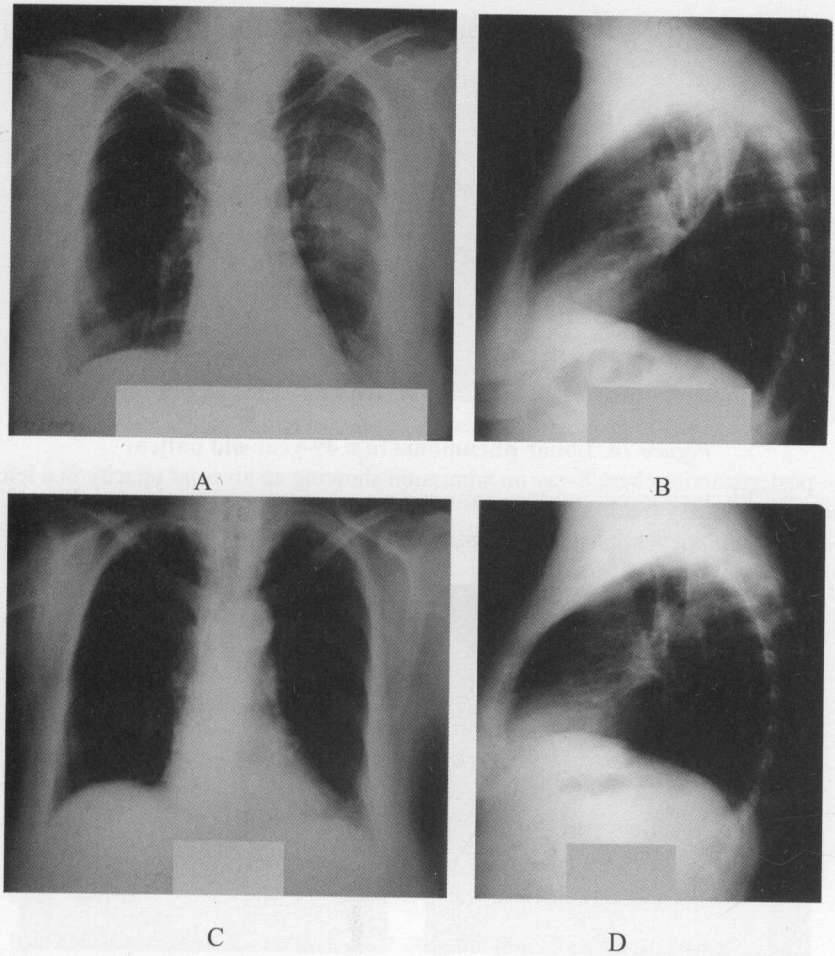

Figure 16. **Lobar pneumonia in a 70-year-old patient.** Chest X-ray on admission (A, B) showing a left upper lobe alveolar opacity. Chest X-ray after 10 day of combined antibacterial treatment (C, D) demonstrates a considerable radiological clearance of the infiltrate. A, C – posteroanterior view; B, D – left lateral view.

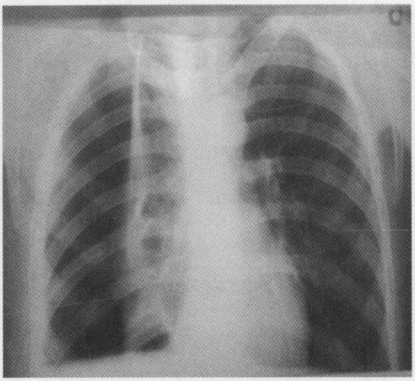

Figure 17. **Right-sided spontaneous pneumothorax on the posteroanterior view in a 28-year-old male patient. The right thoracic cavity is filled in part with free air and the collapsed right lung is indicated by arrows. The mediastinum is shifted to the opposite side.**

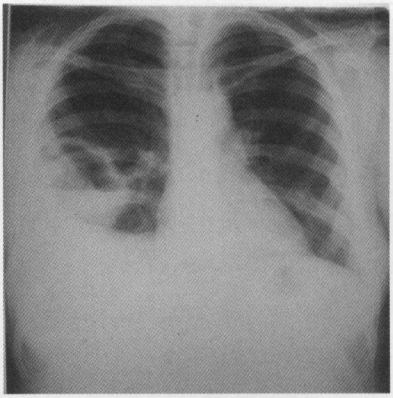

Figure 18. **A single cavitary lesion in the middle lobe with a relatively thick wall and an air-fluid level can be seen in this posteroanterior chest X-ray of a 40-year-old female patient. A concomitant right-sided empyema is present.**

Fluoroscopy

Fluoroscopy is an imaging technique commonly used by physicians to obtain real-time moving images of the internal structures of a patient through the use of a fluoroscope. In its simplest form, a fluoroscope consists of an X-ray source and fluorescent screen between which a patient is placed. However, modern fluoroscopes couple the screen to an X-ray image intensifier and video camera allowing the images to be recorded and played on a monitor.

Computered tomography

Computered tomography (CT) defines intrathoracic structures and abnormalities more clearly than does a chest x-ray. Conventional (planar) CT provides multiple 10-mm–thick cross-sectional images through the thorax. Its main advantage is wide availability. Disadvantages are motion artifact and limited detail from volume averaging of tissue within each 10-mm slice.

High-resolution CT (HRCT) provides 1-mm–thick cross-sectional images. HRCT is particularly helpful in evaluating interstitial lung diseases (e.g., lymphangitic carcinomatosis, sarcoid, and fibrosing alveolitis) and bronchiectasis.

Helical (spiral) CT provides multiplanar images of the entire chest as patients hold their breath for 8 to 10 sec while being moved continuously through the CT gantry. Helical CT is thought to be at least equivalent to conventional CT for most purposes. Its main advantages are speed, less radiation exposure, and an ability to construct 3-dimensional images. Software can also generate images of bronchial mucosa (virtual bronchoscopy). Its main disadvantages are less availability and the requirement for breath-holding, which can be difficult for patients with symptomatic pulmonary disease.

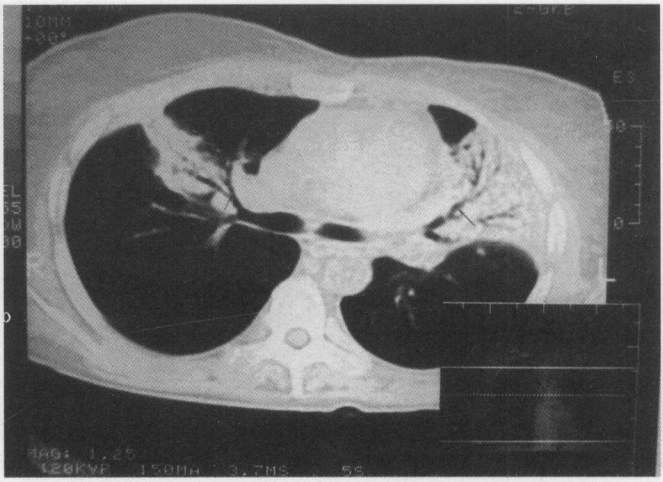

Figure 19. **Spiral CT of the chest of a 50-year-old male. Bilateral alveolar consolidation (opacities) in right upper superior lobe and left upper superior lobe can be seen. Air bronchograms inside the opacities are shown (arrows).**

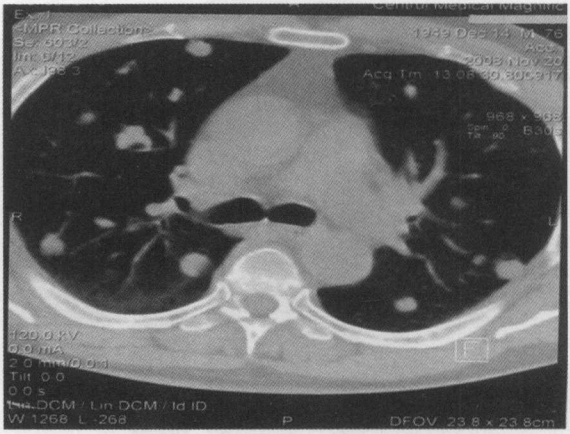

Figure 20. **Spiral CT of the chest. Bilateral metastases of different ages (round opacities) in a 49-year-old male suffering from osteosarcoma of the rib are shown.**

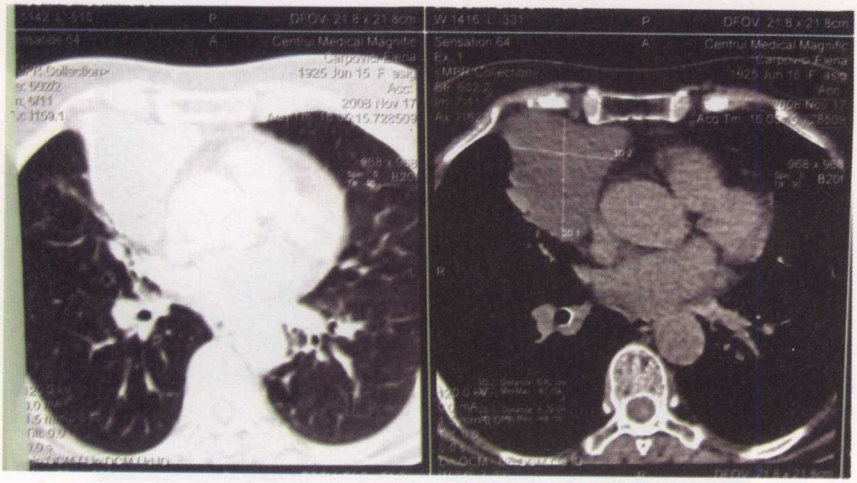

A B

Figure 21. **Spiral chest CT showing a celomic cyst of pericardium in an 80-year-old female.** A – pulmonary (parenchymatous) window; B – mediastinal window.

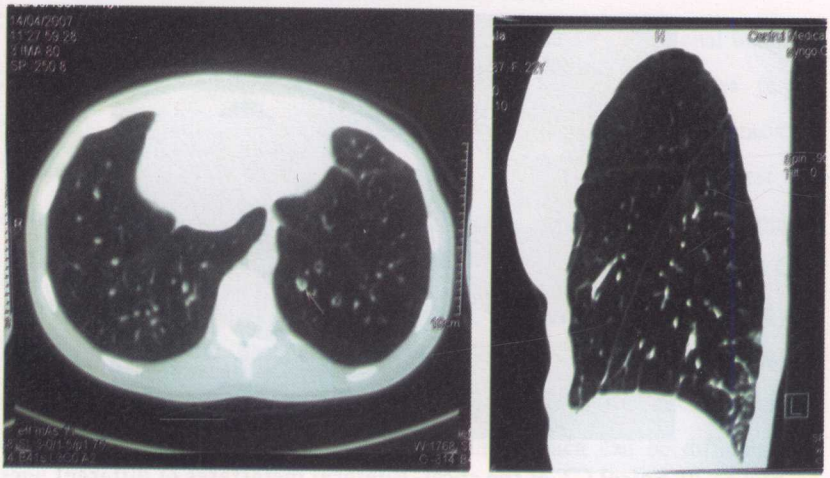

Figure 22. **Spiral chest CT in a 23-year-old female patient suffering from left lower lobe bronchiestasis.**

CT angiography

CT angiography is an alternative non-invasive test that provides very detailed images of blood vessels. CT angiography uses a bolus of intravenous contrast to highlight the pulmonary arteries, which is useful in diagnosis of pulmonary embolism. Dye load is comparable to conventional angiography, but the test is quicker and less invasive. Several studies have confirmed sufficient accuracy of CT angiography for the detection of pulmonary emboli, so it has largely replaced V/Q scanning and conventional pulmonary angiography (except in patients unable to tolerate contrast).

CT angiography does have some limitations. The most problematic obstacle is calcification. Calcium build-up in a vessel can be very hard to distinguish from the injected dye material, this can result in an inaccurate reconstructed three dimensional image. In addition, CT angiography does not yet offer the equivalent spatial resolution as conventional catheter angiography, thus catheter angiography is superior to CT angiography for the study of very small arteries. However, many vascular pathologies involve arteries that are well within the size range amenable to CT angiography.

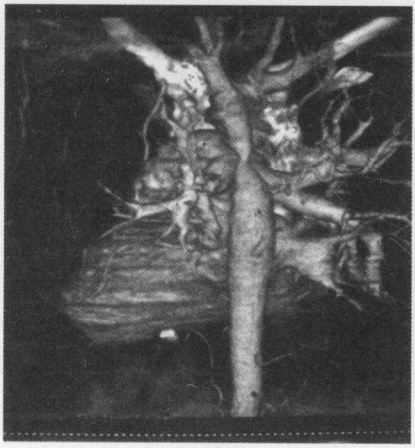

Figure 23. **CT angiography showing coarctation of descending aorta in an 18-year-old male patient.**

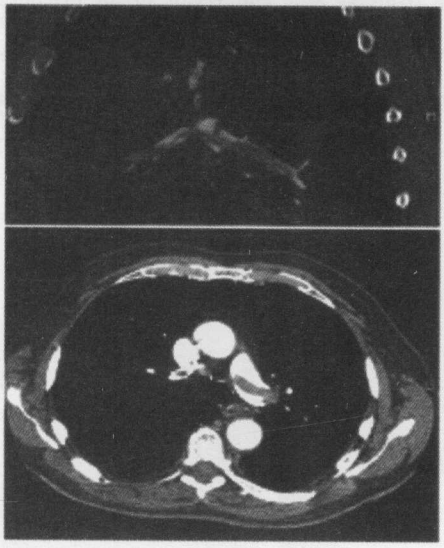

Figure 24. **CT pulmonary angiography shows a saddle embolus and a substantial thrombus in the lobar branches of both main pulmonary arteries.**

Magnetic Resonance Imaging (MRI)

The basis of the method is the phenomenon of nuclear magnetic resonance that is when certain anatomic nuclei are placed in a magnetic field and stimulated by radio waves of a particular frequency, they re-emit some of the absorbed energy in the form of radio signals. The potential applications of MRI to the diagnosis are numerous (see table 4). MRI has a relatively limited rôle in pulmonary imaging but is preferred over CT in specific circumstances, such as assessment of pancoast tumors, possible cysts, and other lesions that abut the chest wall.

Table 4. The main clinical indications for chest MRI

Indications	*Comment*
Cardiac function To evaluate patients for aortic dissection	MRI accurately measures cardiac function non-invasively.
Brachial plexus	MRI is the imaging of choice for all lesions invading brachial plexus.
Chest wall lesions	MRI is more accurate in determining the extent of chest wall invasion by tumor, compared with other imaging modalities.
Staging lung cancer	MRI is particularly useful in defining T_3 from T_4 lesions and is therefore better able to distinguish potentially operable from inoperable tumors.
Invasive mediastinal lesions	MRI is more useful in defining the extent of mediastinal or hilar lesions.

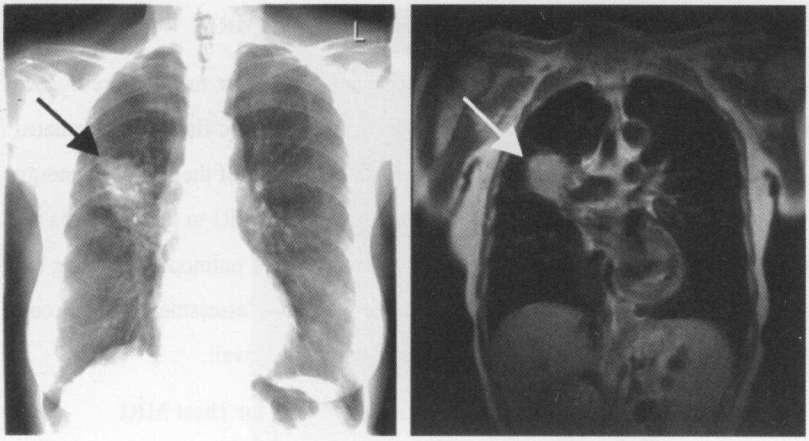

A B

Figure 25. **Chest x-ray (A) and MRI scan (B) of a 50-year-old female patient.** A large tumor originating from the upper right lobe of the lung can be seen (arrows). The patient was resected with an upper bilobectomy and systematic lymphadenectomy and the diagnosis of adenocarcinoma was confirmed.

Advantages include absence of radiation exposure, excellent visualization of vascular structures, lack of artifact from bone, and excellent soft-tissue contrast.

Disadvantages include respiratory and cardiac motion and the time it takes to do the procedure.

Nuclear scanning

Ventilation/perfusion scanning

Ventilation/perfusion (V/Q) scanning uses inhaled radionuclides to detect ventilation and IV radionuclides to detect perfusion. Areas of ventilation without perfusion, perfusion without ventilation, or matched increases and decreases in both can be detected with 6 to 8 views of the lungs. V/Q scanning is most commonly used for diagnosing pulmonary embolism but has largely been replaced by CT angiography.

Split-function ventilation scanning, in which the degree of ventilation is quantified for each lobe, is used to predict the effect of lobar or lung resection on pulmonary function; postsurgical forced expiratory volume in 1 sec (FEV_1) is estimated as the percentage of uptake of ventilation tracer in the healthy fraction of the lungs multiplied by preoperative FEV_1 (in liters). A value of < 0.8 L (or < 40% of that predicted for the patient) indicates limited pulmonary reserve and a high likelihood of unacceptably high perioperative morbidity and mortality.

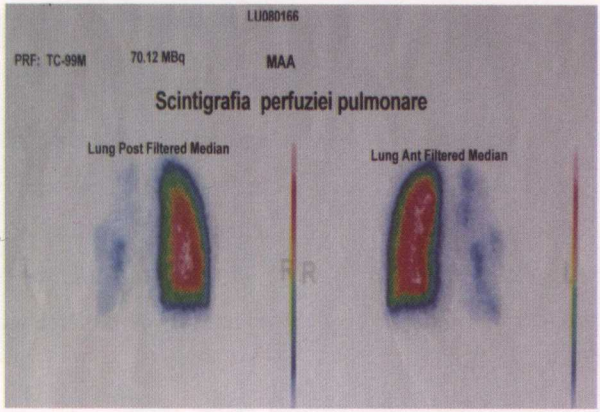

Figure 26. **A perfusion scanning of a 23-year-old patient suffering from Swyer-James- Macleod syndrome is shown.** (Swyer-James-Macleod syndrome is a disease that follows viral bronchiolitis with the characteristic radiological feature of unilateral hyperlucency due to loss of pulmonary vasculature and air trapping).

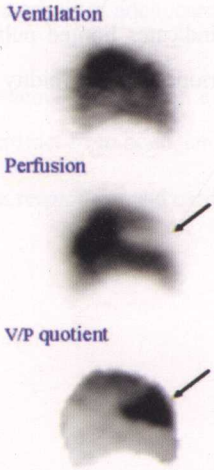

Figure 27. **Sagital slice of the left lung in a 70-year-old patient with pulmonary embolism. The perfusion defect is wedge-shaped (arrow). Ventilation is preserved. The abnormality is highlighted in the V/P quotient image (arrow).**

Positron emission tomography

Positron emission tomography (PET) takes advantage of the high glucose metabolism of tumor cells, so tumors can be easily identified. The sensitivity for the detection of lung cancer has been reported to be in the 95% range. Some benign processes, including several types of infectious lesions can simulate cancer with this test. For this reason, biopsy is required to confirm the diagnosis. PET scanning can also be used to find spread of disease outside of the chest.

By identifying unexpected distant metastases in 10-20% of patients, PET helps to avoid an operation. PET is also attractive since the whole body can be imaged in one session.

Current recommendations require confirmation of all PET-positive mediastinal nodes with mediastinoscopy. PET is also useful in guiding mediastinal biopsy, especially when disease is identified in a nodal region not accessible by mediastinoscopy alone.

PET scanning provides functional information and has been found to be useful for determining the diagnosis, stage, and prognosis of lung cancer.

Figure 28. **The PET scan of a lung cancer patient with a nodule in the right upper lobe.** The picture shows the bright yellow spot in the right upper lobe (arrow) and the 2nd spot in the hilum (arrow head). This information tells the surgeon that the disease has likely spread to this region.

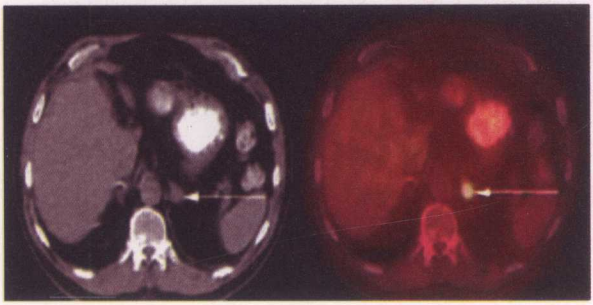

Figure 29. **CT (left) with Fusion PET image (right) on same patient.**

Notice that the adrenal gland (arrow) appears as a bright yellow spot on the FUSION image. This implies the disease has spread outside the chest.

Ultrasonography

The most important application of ultrasonography in pulmonary diseases is assessment of local pleural thickening caused by loculated empyema. Differention of liquid from solid pleural collections can be achieved easily with ultrasonography. The technique provides assessment of the amount of fluid loculated in pleural cavity and indicates the appropriate site of thoracocentesis. Pleural fluid in the subpulmonic area of the right hemithorax and collections of fluid in the subphrenic space (subphrenic abscess) can be also assessed.

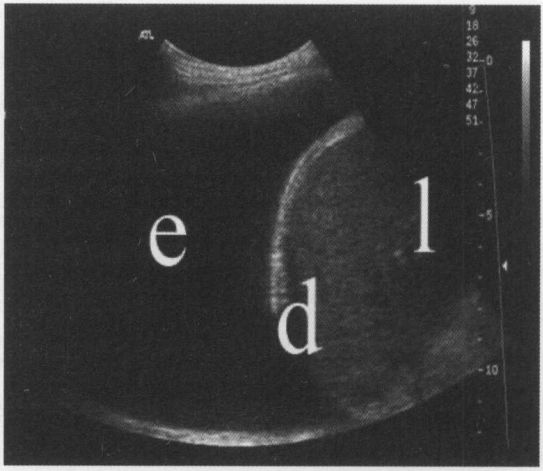

Figure 30. **Ultrasound image of a large right sided effusion. The top of the image represents the probe resting on the chest wall, the dark area (e) is the effusion which has completely displaced the lung. The bright band (d) is the diaphragm, with the liver (l) inferior (to the right)**

Endoscopic methods

Bronchoscopy

Bronchoscopy is a technique of visualizing the inside of the airways for diagnostic and therapeutic purposes. A bronchoscope is inserted into the airways, usually through the nose or mouth, or occasionally through a tracheostomy. This allows the practitioner to examine the patient's airways for abnormalities such as foreign bodies, bleeding, tumors, or inflammation. Specimens may be taken from inside the lungs.

Types

A. Rigid (rigid metal tubes with attached lighting devices)

1. Rigid bronchoscopy is used for retrieving foreign objects.
2. Massive hemoptysis, defined as loss of >600 mL of blood in 24 hours should be addressed with initiation of intravenous fluids and examination with rigid bronchoscopy

B. Flexible (fiberoptic)

A flexible bronchoscope contains a fiberoptic system that transmits an image from the tip of the instrument to an eyepiece or video camera at the opposite end. Using Bowden cables connected to a lever at the hand piece, the tip of the instrument can be oriented, allowing the practitioner to navigate the instrument into individual lobe or segment bronchi. Most flexible bronchoscopes also include a channel for suctioning or instrumentation, but these are significantly smaller than those in a rigid bronchoscope. Flexible bronchoscopy causes less discomfort for the patient than rigid bronchoscopy and the procedure can be performed easily and safely under moderate sedation. It is the technique of choice nowadays for most bronchoscopic procedures.

Purposes of bronchoscopy

A. Diagnostic:

- To view abnormalities of the airways
- To obtain tissue specimens of the lung in a variety of disorders. Specimens may be taken from inside the lungs by biopsy, bronchoalveolar lavage, or endobronchial brushing.
- To evaluate a person who has bleeding in the lungs, possible lung cancer, a chronic cough, and sarcoidosis.

B. Therapeutic:

- To remove secretions, blood, or foreign objects lodged in the airway
- Laser resection of tumors or benign tracheal and bronchial strictures
- Stent insertion to palliate extrinsic compression of the tracheobronchial lumen from either malignant or benign disease processes
- Bronchoscopy is also employed in percutaneous tracheostomy
- Tracheal intubation of patients with difficult airways is often performed using a flexible bronchoscope

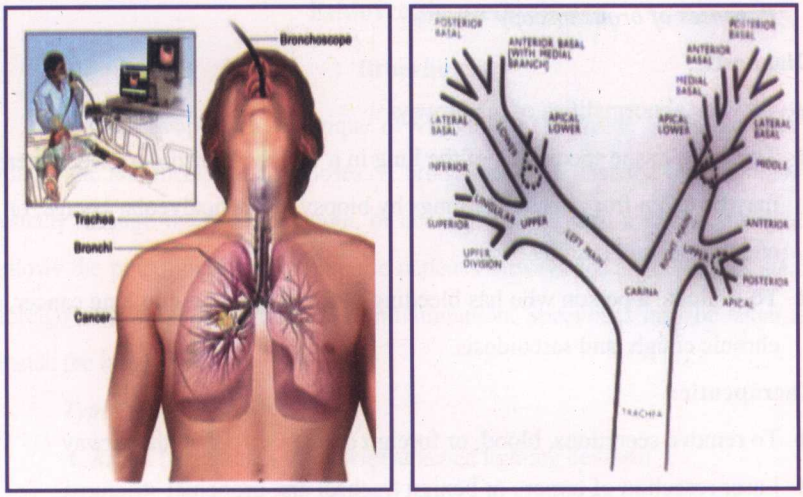

A B

Figure 31. **Bronchoscopy technique. A – schematic view of a video-assisted bronchoscopy. B - main branching of the bronchial tree, as visualized by the bronchoscopist operating at the head of the supine patient.**

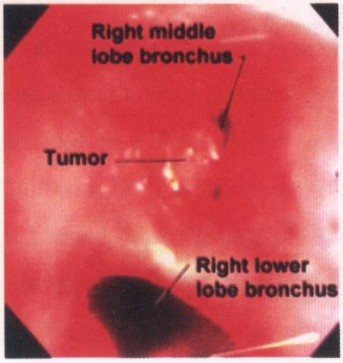

Figure 32. **Bronchoscopy view of a normal right lower lobe bronchus and tumor blocking the right middle lobe bronchus.**

Endobronchial ultrasound

During flexible fiberoptic bronchoscopy (FB), a solitary pulmonary nodule (SPN) is sampled by means of transbronchial needle aspiration (TBNA), brush, or transbronchial lung biopsy under fluoroscopy; and mediastinal lymph nodes are sampled using "blind" TBNA.

Endobronchial ultrasound (EBUS) was developed to help visualize the lesion at the time of biopsy in order to improve the diagnostic yield.

Figure 33. **Illustration demonstrating endobronchial ultrasound to guide a biopsy of a lymph node.**

There are two types of EBUS techniques:

1) Using a radial probe with a rotating transducer at the distal tip, which produces a 360 degrees image to the long axis of the bronchoscope; 2) using an

EBUS bronchoscope with a linear transducer at its distal tip, producing a 50 degrees image parallel to its long axis.

In biopsies of solitary pulmonary nodules < 2 cm using a radial probe, EBUS demonstrates a higher diagnostic yield than conventional FB techniques. With mediastinal and hilar nodal stations, except for the subcarina, EBUS shows a higher yield over blind TBNA.

Video-assisted thoracoscopic surgery

Video-assisted thoracoscopic surgery (VATS) is a type of thoracic surgery performed using a small video camera that is introduced into the patient's chest via a scope. The surgeon is able to view the instruments that are being used along with the anatomy on which the surgeon is operating. The camera and instruments are inserted through separate holes in the chest wall also known as "ports". These small ports are advantageous because the chance for infection and dehiscence are drastically reduced. This allows for a faster recovery by the patient and a greater chance for the wound to heal.

Operations that can be performed with VATS include:

- biopsy for diagnosis of pulmonary, pleural or mediastinal pathology;
- decortication for empyema;
- pleurodesis for recurrent pleural effusions or spontaneous pneumothorax;
- surgical stapler assisted wedge resection of lung masses;
- resection of mediastinal or pleural masses;
- thoracic sympathectomy for hyperhidrosis;
- operations for diaphragmatic hernias or paralysis;

- esophageal resection or resection of esophageal masses or diverticula; lobectomy/mediastinal lymphadenectomy for lung cancer.

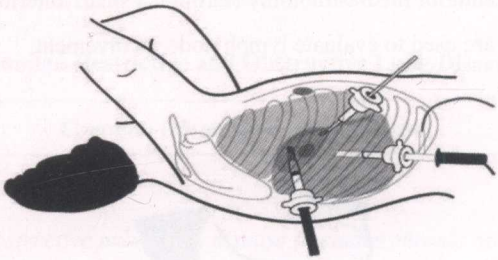

Figure 34. **Illustration demonstrating video-assisted thoracoscopy to perform a biopsy of a solitary pulmonary node.**

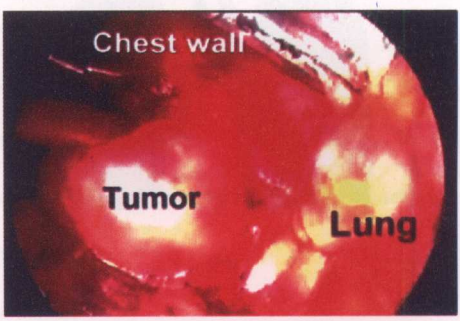

Figure 35. **The picture shows video-assisted thoracic surgery procedure for removal of a neurofibroma of the right chest located between the lung and chest wall.**

Mediastinoscopy

When radiologic studies are inconclusive or enlarged mediastinal lymph nodes greater than 1 cm are present, surgical techniques including cervical mediastinoscopy, anterior mediastinotomy (through a small anterior chest incision), and thoracoscopy are used to evaluate lymph node involvement.

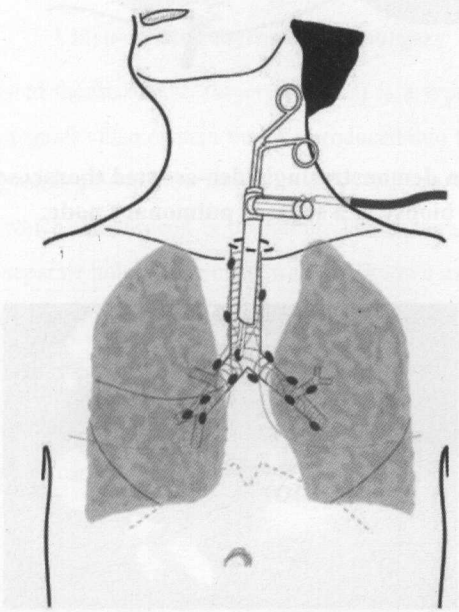

Figure 36. **Illustration demonstrating cervical mediastinoscopy to evaluate lymph node involvement by lung cancer.**

Mediastinoscopy is the gold standard for mediastinal staging with 89% sensitivity and 100% specificity for *non-small cell lung cancer*. Cervical mediastinoscopy can be performed as an outpatient procedure with minimal

complications. Anterior mediastinotomy can be used to evaluate lymph nodes that are less accessible by mediastinoscopy, particularly nodes in the left chest.

Appendix

Common Restrictive and Obstructive Lung Diseases

Common Obstructive Lung Diseases
● *Bronchial asthma* ● *Chronic obstructive pulmonary disease (includes chronic obstructive bronchitis, emphysema, and the overlap between them)* ● *Cystic fibrosis* ● *Emphysema*
Common Restrictive Lung Diseases
● *Beryllium disease* ● *Congestive heart failure* ● *Idiopathic pulmonary fibrosis* ● *Infectious inflammation (e.g., histoplasmosis, mycobacterium infection)* ● *Interstitial pneumonitis* ● *Neuromuscular diseases* ● *Sarcoidosis* ● *Thoracic deformities*

Further reading

1. American Association for Respiratory Care (AARC). Bronchoscopy assisting 2007 revision and update. *Respir Care* 2007; 52(1): 74-80.
2. Bajc M., Neilly J. B., Miniaty M., et al. European Association of Nuclear Medicine guidelines for ventilation/perfusion scintigraphy. *Eur J Nucl Med Imaging* 2009; 36: 1356-1370.
3. Beckh S., Bolcskei P.L., Lessnau K.D. Real-time chest ultrasonography: a comprehensive review for the pulmonologist. *Chest* 2002; 122: 1759-1773.
4. Botnaru V. Semiologia radiologică a toracelui. Chişinău, 2005. 399 p.
5. Botnaru V. Pneumologie. Chişinău, 2009. 732 p.
6. Choi Y.S., Shim Y.M., Kim J., et al. Mediastinoscopy in patients with clinical stage I Non-small Cell Lung Cancer. *Annals of Thoracic Surgery* 2003; 75(2): 364–366.
7. Corne J., Pointon K. Chest X-ray Made Easy. Elsevier Health Sciences, 2009, 184 pp.
8. Diacon A. H., Theron J., Bolliqer C. T. Trans thoracic ultrasound for pulmonologist. *Curr Opin Pulm Med* 2005; 11 (4): 307-312.
9. Ellis S. G. Interpreting Chest X-rays. Scion Publishing Ltd, 2010, 250 pp.
10. George R. B. Chest Medicine. Lippincott Williams & Wilkins, 2005, 652 pp.
11. Hansell D. M., Armstrong P., Lynch D. A., McAdams H.P. Imaging of Diseases of the Chest. Elsevier Health Sciences, 2005, 1272 pp.
12. Harrison's Principles of Internal Medicine. 17th Edition, 2008.
13. Jacob M., Bajraktarevic D. Ghid clinic pentru astmul bronşic. Târgu-Mureş, Farmamedia, 2009, 106 pp.
14. Mac Manus M. P., Hicks R. J. PET scanning in lung cancer: current status and future directions. *Semin Surg Oncol* 2003; 21: 149-155.

15. Marom E.M., Sarah S., James E.H., et al. T1 Lung Cancers: Sensitivity of Diagnosis with Fluorodeoxyglucose PET. *Radiology* 2002; 223: 453-459.

16. Martensen K. M. Radiographic image analysis. Elsevier Health Sciences, 2005, 540 pp.

17. Matcovschi S., Țernă Eudochia. Explorările funcționale ale sistemului respirator. Chișinău, 2002. 30 p.

18. Matcovschi S. Esențialul în pneumologie. Ghid multimedia. Ediție pe CD-ROM. Chișinău, 2006.

19. Murasugi M., Onuki T., Ikeda T., et al. The role of video-assisted thoracoscopic surgery in the diagnosis of the small peripheral pulmonary nodule. *Surg Endosc* 2001; 15: 734-736.

20. Ohno Y., Sugimura K., Hatabu H. MR imaging of lung cancer. *Eur J Radiol* 2002; 44: 172-181.

21. Parker M. S., Rosado-de-Christenson M. L., Abbott G. F. Teaching Atlas of Chest Imaging. New York, Thieme, 2006, 789 pp.

22. Parsons P. E., Heffner J. E. Pulmonary respiratory therapy secrets. Elsevier Health Sciences, 2001, 539 pp.

23. Schaefar-Procop C., Nietzel U., Venema H.W., et al. Digital chest radiography: an update on modern technology, dose containment and control of image quality. *Eur Radiol* 2008; 18: 1818-1830.

24. Sheski F.D., Mathur P.N. Endobronchial ultrasound. *Chest* 2008; 133 (1): 264-270.

25. The Merck Manual of Diagnostic and Therapy. 17th Edition, 1999.

26. Webb W.R., Higgins C. B. Thoracic imaging: pulmonary and cardiovasculary radiology. Lippincott Williams & Wilkins, 2010, 928 pp.